



Bilateral Uveitis in Silent Ulcerative Colitis: Case Report

Saba Hussein Alwais¹ Mohammed Hadi Alrikabi² Ahmed Salih Alshewered³

¹Rheumatology Department, Al-Kindy College of Medicine, Baghdad, Iraq

²Gastrointestinal Department, Gastroenterology and Hepatology Teaching Hospital, Medical City Complex, Ministry of Health, Baghdad, Iraq

³Radiotherapy Department, Misan radiation Oncology Center, Misan Health Directorate, Ministry of Health, Misan, Iraq

Address for correspondence Saba Hussein Alwais, Lecturer, Rheumatology Department, Al-Kindy College of Medicine, Baghdad, Iraq (e-mail: medicalresearch100@yahoo.com).

J Coloproctol 2023;43(1):49–51.

Abstract

Keywords

- ▶ silent inflammatory bowel diseases
- ▶ uveitis
- ▶ erythema nodosum
- ▶ oligoarthritis

Silent or subclinical inflammatory bowel diseases (IBD) is a relatively new term that has been used to describe individuals with asymptomatic active mucosal bowel inflammation, often unaware of their disease due to either the lack of or mild inflammatory symptoms. These patients are at risk for gastrointestinal and extra-gastrointestinal manifestations, with more advanced complications. In this article we intend to describe a case report of a patient with chronic history of many organ involvements including ocular, skin, and musculoskeletal, which was later placed under the umbrella of silent ulcerative colitis.

Introduction

Strictly, there is no single, globally accepted description of silent inflammatory bowel diseases (IBD), or even a list of distinguishable criteria to use in a conclusive diagnosis for this condition. However, silent IBD could be used for patients with undetected versions of these illnesses who fail to manifest and recognize clinical features during active phases.¹

Ulcerative colitis (UC) is an inflammatory systemic illness. Clinical manifestations of the UC are unrestricted to the gastrointestinal tract (GIT), there are massive involvement of other organs, such as ocular, skin, and articular, and occur in up to 45% of patients.²

Frequently, the eye is one of the most affected organs, usually by inflammation, such as episcleritis, uveitis and scleritis.

Uveitis is the inflammation of the uveal tract—the middle layer of the eye—which includes the iris, ciliary body, and choroid. It is considered the third highest reason of vision loss in Western countries.³

Case Presentation

A 31-years-old woman with long standing history of multiple systemic presentations. The first symptom, starting from 2016, being blurred vision of bilateral eye, which is associated with bilateral uveitis with glaucoma complication. A few months later, in 2017, she developed bilateral wrist joint arthritis, with 15 minutes of morning stiffness and arthralgias in both knees and shoulders. Furthermore, painful and tender red patches appeared on both shin bones, erythema nodosum, from 2016 to 2022 (year of diagnosis). Other manifestations of

received

October 24, 2022

accepted after revision

January 23, 2023

DOI <https://doi.org/10.1055/s-0043-1764191>.

ISSN 2237-9363.

© 2023. Sociedade Brasileira de Coloproctologia. All rights reserved.

This is an open access article published by Thieme under the terms of the Creative Commons Attribution-NonDerivative-NonCommercial-License, permitting copying and reproduction so long as the original work is given appropriate credit. Contents may not be used for commercial purposes, or adapted, remixed, transformed or built upon. (<https://creativecommons.org/licenses/by-nc-nd/4.0/>)

Thieme Revinter Publicações Ltda., Rua do Matoso 170, Rio de Janeiro, RJ, CEP 20270-135, Brazil

constitutional symptoms included generalized fatigue, low grade fever, and night sweats.

The patient consulted many physicians and specialists such as ophthalmologists, dermatologists, and rheumatologists with frequent investigations that had disclosed elevated inflammatory markers, including erythrocyte sedimentation rate (ESR), C-reactive protein (CRP) titers, and chronic anemia. In 2018, she received a diagnosis of psoriatic arthritis plus uveitis. Methotrexate (MTX) for psoriatic arthritis was prescribed based on family history of psoriasis. The patient has some questions and doubts regarding these medications, despite having a positive response to MTX for visual symptoms. In this case, is there a history of nasal cartilage pain & swelling?; laryngeal cartilage pain and tenderness?; what about family history of psoriasis?

Further examination established that there was no diagnosis of psoriasis, either personal or in her family history. Therefore, there was a reassessment of the presentation—bilateral uveitis + oligo arthritis + erythema nodosum + constitutional symptoms—focusing on the manifestations of a systemic condition that, until now, remained without explanation.

There was no history of connective tissue disease symptoms or signs, no inflammatory back pain, no psoriasis skin rash, no family history of dactylitis, inflammatory bowel disease symptoms or signs, tuberculosis (TB) contact, signs of Behçet disease, sarcoidosis symptoms or signs, Vogt Koyanagi Harada (VKH) symptoms or signs etc.

Therefore, the differential diagnosis were:

1. Relapsing polychondritis
2. Inflammatory bowel disease (silent or subclinical one)
3. TB
4. Idiopathic

Furthermore, new advanced investigations were performed:

- The HLA-B27 test was negative.
- The Interferon Gamma Release Assays (IGRA) test was negative.
- The computed tomography (CT) scan of the laryngotracheal cartilage tree was normal.

Meanwhile, the patient has been referred to a gastroenterologist for screening and colonoscopy intervention, which identified a diffuse colonic mucosal inflammation with loss of vascular pattern and ulceration. A biopsy disclosed left sided ulcerative colitis. Therefore, the definite diagnosis is of silent ulcerative colitis (UC) which was subclinical for approximately 7 years (► **Fig. 1**).

Finally, the patient responded well to the new medications list:

- Mesalazine 1000mg suppository, a single application;
- Prednisolone 20mg tab 1*1;
- Azathioprine 50mg 1*2;
- Mesalazine 1g sachet 1*2.

Discussion

Loss of clinical features in IBD create significant challenges. Patients with silent IBD have an evident of intestinal inflammatory modifications or even complications, such as abscesses and fistulae. These are either nonproduction obvious symptoms, like pain and bowel habit changes, and/or producible features. Furthermore, those patients may have undetected or prodromal illnesses due to underappreciated clinical features.^{4,5} It is important to discuss these issues, especially regarding asymptomatic IBD patients with the active illness.^{6,7}

The prevalence of silent IBD is wide and varied, upon the diagnostic criteria and used tests; the prevalence is between 19 and 57% for all IBD patients.⁸ Those with silent IBD are at a risk of nutritional iron deficiency, anemia, blindness, osteoporosis, and venous thromboembolism.

The development of silent IBD remains unclear. One theory suggests the causes of asymptomatic IBD are homozygous for a mutation (rs6795970) in the voltage gated sodium channel (VGSC) of the SCN10A gene.⁹ This mutation can lead to increased tolerance to somatosensory pain stimulation,¹⁰ which is when there is a mild to no pain presentation (hypoalgesic IBD). Another theory is that the genetic polymorphisms significantly impact pain perception in the gut, even when there is significant inflammation, due to the role of NaV1 in visceral pain. Furthermore, some authors suggest that some of silent IBD individuals are stoic slow manner disorder. Even when IBD is inactive, there is a risk of intestinal permeability, which can lead to subclinical inflammation, raised stool calprotectin, inflammatory cytokines, and dysbiosis—all of which are predictors of flare of disease.¹¹

Mucosal immune dysregulation has an important role in the alteration of the stomach's microbiota, as well as the disruption of the intestinal barrier function, which could drive the immune system to trigger a reaction to inflammatory processes.¹²

As a result, there are unmet requirements to determine additional environmental factors which impact the subclinical inflammatory process of IBD. There are some coincidental examination findings which were incidentally identified in the period of or just before the asymptomatic IBD diagnosis and can facilitate early diagnosis, including extraintestinal manifestations of IBD, like inflammatory back pain,¹³ chronic unexplained anemia, erythema nodosum, and venous thromboembolism,¹⁴ which are also correlated to previously unrecognized IBD.

Direct endoscopy can evaluate GIT, with mucosal biopsy being the preferred method for detection of IBD for many years.¹⁵

Furthermore, fecal calprotectin and serological inflammatory markers, such as CRP and ESR, can be sensitive tools for IBD-related activity like in colitis.¹⁶

The patient from the case described in this article suffered for many years from bilateral uveitis and glaucoma as extra-gastrointestinal manifestations (EIMs) of silent UC. Ocular involvement is more prevalent in the IBD's active phase. Cataracts and open angle glaucomas are considered late complications of long-standing ocular inflammation or the

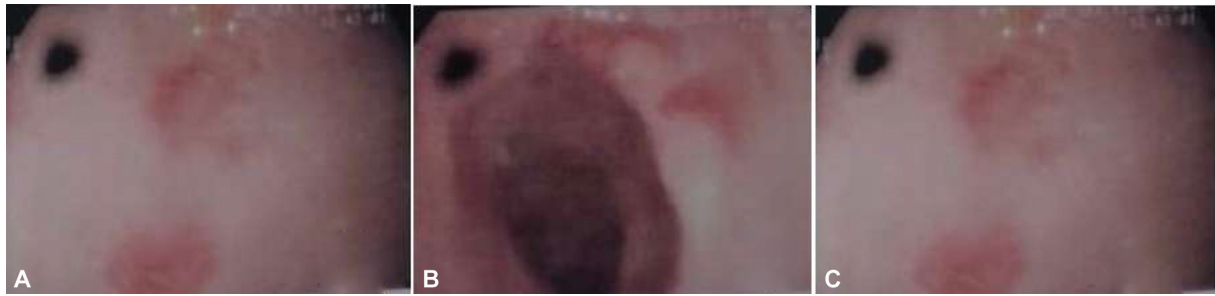


Fig. 1 Colonoscopy findings of left sided ulcerative colitis.

chronic use of specific medications.⁷ Furthermore, the EIMs of IBD can precede the onset of primary systemic colonic disease, and systematic anamnesis must be done in chronic uveitis of unknown reasons.¹⁷

In brief, silent IBD is a normally unnoticed clinical status that can portend a significant impact on the patients. There is still much to be learned about this entity, with more theories, targeted studies, and careful consideration regarding its etiology, consequences, and its associated symptomatology.

Conclusion

Arthritis, erythema nodosum, and uveitis are extra-gastrointestinal manifestations that occur mostly during an exacerbation of the inflammatory colonic symptoms of ulcerative colitis.

Conflict of Interests

The authors have no conflict of interests to declare.

References

- Coates MD, Binion DG. Silent Inflammatory Bowel Disease. *Crohn's Colitis* 2021;3(03):otab059
- Colia R, Corrado A, Cantatore FP. Rheumatologic and extraintestinal manifestations of inflammatory bowel diseases. *Ann Med* 2016;48(08):577–585
- You C, Sahawneh HF, Ma L, Kubaisi B, Schmidt A, Foster CS. A review and update on orphan drugs for the treatment of noninfectious uveitis. *Clin Ophthalmol* 2017;11:257–265
- Patil SA, Cross RK. Update in the management of extraintestinal manifestations of inflammatory bowel disease. *Curr Gastroenterol Rep* 2013;15(03):314
- Barratt SM, Leeds JS, Robinson K, Lobo AJ, McAlindon ME, Sanders DS. Prodromal irritable bowel syndrome may be responsible for delays in diagnosis in patients presenting with unrecognized Crohn's disease and celiac disease, but not ulcerative colitis. *Dig Dis Sci* 2011;56(11):3270–3275
- Howarth GF, Robinson MH, Jenkins D, Hardcastle JD, Logan RF. High prevalence of undetected ulcerative colitis: data from the Nottingham fecal occult blood screening trial. *Am J Gastroenterol* 2002;97(03):690–694
- Sakata T, Niwa Y, Goto H, et al. Asymptomatic inflammatory bowel disease with special reference to ulcerative colitis in apparently healthy persons. *Am J Gastroenterol* 2001;96(03):735–739
- Click B, Vargas EJ, Anderson AM, et al. Silent Crohn's disease: asymptomatic patients with elevated C-reactive protein are at risk for subsequent hospitalization. *Inflamm Bowel Dis* 2015;21(10):2254–2261
- Bhattacharya A, Rao BB, Koutroubakis IE, et al. Silent Crohn's disease predicts increased bowel damage during multiyear follow-up: the consequences of under-reporting active inflammation. *Inflamm Bowel Dis* 2016;22(11):2665–2671
- Gonzalez-Lopez E, Imamura Kawasawa Y, Walter V, et al. Homozygosity for the SCN10A polymorphism rs6795970 is associated with hypoalgesic inflammatory bowel disease phenotype. *Front Med (Lausanne)* 2018;5:324
- Duan G, Han C, Wang Q, et al. A SCN10A SNP biases human pain sensitivity. *Mol Pain* 2016;12:1–16
- Swanson GR, Kochman N, Amin J, et al. Disrupted Circadian Rest-Activity Cycles in Inflammatory Bowel Disease Are Associated With Aggressive Disease Phenotype, Subclinical Inflammation, and Dysbiosis. *Front Med (Lausanne)* 2022;8:770491
- Haraoui B, Krenbaum M. Emergence of Crohn's disease during treatment with the anti-tumor necrosis factor agent etanercept for ankylosing spondylitis: possible mechanisms of action. *Semin Arthritis Rheum* 2009;39(03):176–181
- Di Fabio F, Lykoudis P, Gordon PH. Thromboembolism in inflammatory bowel disease: an insidious association requiring a high degree of vigilance. *Semin Thromb Hemost* 2011;37(03):220–225
- Lichtenstein GR, Loftus EV, Isaacs KL, Regueiro MD, Gerson LB, Sands BE. ACG clinical guideline: management of Crohn's disease in adults. *Am J Gastroenterol* 2018;113(04):481–517
- Bjarnason I. The use of fecal calprotectin in inflammatory bowel disease. *Gastroenterol Hepatol (N Y)* 2017;13(01):53–56 (n y)
- Troncoso LL, Biancardi AL, de Moraes HV Jr, Zaltman C. Ophthalmic manifestations in patients with inflammatory bowel disease: A review. *World J Gastroenterol* 2017;23(32):5836–5848. Doi: 10.3748/wjg.v23.i32.5836