




# Juvenile Dermatomyositis and Diffuse Cutaneous Systemic Sclerosis Overlap

Hani Shatnawi<sup>1</sup> Dona Ailabouni<sup>2</sup> Ahmad Mohammad Shatnawi<sup>1</sup>  
Faisal Mohammad Hussain Makahleh<sup>3</sup> Bader AlBalawi<sup>4</sup> Rajaie Namas<sup>5</sup>

<sup>1</sup>Division of Rheumatology, Department of Internal Medicine, Princess Basma Hospital, Irbid, Jordan

<sup>2</sup>Department of Medicine, College of Medicine and Health sciences, United Arab Emirates University, Al Ain, Abu Dhabi, United Arab Emirates

<sup>3</sup>Department of Internal Medicine, Princess Basma Hospital, Irbid, Jordan

<sup>4</sup>Department of Pharmacy, Al Qurayyat Hospital, Saudi Arabia

<sup>5</sup>Division of Rheumatology, Department of Internal Medicine, Cleveland Clinic Abu Dhabi, United Arab Emirates

**Address for correspondence** Rajaie Namas, MD, Clinical Associate Professor, Section Head of Rheumatology, Department of Internal Medicine, Division of Rheumatology, Cleveland Clinic Abu Dhabi, Abu Dhabi, United Arab Emirates  
(e-mail: [namasr@clevelandclinicabudhabi.ae](mailto:namasr@clevelandclinicabudhabi.ae)).

Ibnosina J Med Biomed Sci 2023;15:42–48.

## Abstract

### Keywords

- ▶ juvenile dermatomyositis
- ▶ diffuse systemic sclerosis
- ▶ scleroderma
- ▶ Raynaud's phenomenon
- ▶ connective tissue disease
- ▶ overlap syndrome
- ▶ scleromyositis
- ▶ interstitial lung disease

The overlapping nature of autoimmune diseases makes diagnosing and stratifying prognosis extremely difficult. Scleromyositis, the most common overlap syndrome, is typically seen in adults and is rarely seen in children. An overlap syndrome like scleromyositis would have clinical features of at least two connective tissue diseases (juvenile dermatomyositis and systemic sclerosis). Furthermore, the presence of anti-PM/Scl antibodies is critical. We describe a patient who presented with widespread skin tightening, hoarseness of voice, dysphagia, and muscle weakness that had been present for 6 months. The patient was diagnosed with overlap juvenile scleromyositis (scleroderma-dermatomyositis overlap). In practice, distinguishing this syndrome from dermatomyositis and scleroderma is critical.

## Introduction

Systemic sclerosis (SSc), mixed connective tissue disease (MCTD), and systemic lupus erythematosus (SLE) may all share symptoms in common with dermatomyositis (DM) and polymyositis (PM). When compared to juvenile dermatomy-

ositis (JDM), overlap syndromes are thought to have more significant comorbidities. We present a typical case of overlap between scleroderma and dermatomyositis associated with interstitial lung disease (ILD), focusing on the disease's clinical characteristics, immunological profile, and therapeutic response to immunosuppressive therapy.

DOI <https://doi.org/10.1055/s-0043-1763492>.  
ISSN 1947-489X.

© 2023. The Libyan Biotechnology Research Center. All rights reserved.

This is an open access article published by Thieme under the terms of the Creative Commons Attribution-NonDerivative-NonCommercial-License, permitting copying and reproduction so long as the original work is given appropriate credit. Contents may not be used for commercial purposes, or adapted, remixed, transformed or built upon. (<https://creativecommons.org/licenses/by-nc-nd/4.0/>)

Thieme Medical and Scientific Publishers Pvt. Ltd., A-12, 2nd Floor, Sector 2, Noida-201301 UP, India

JDM is a common idiopathic inflammatory myopathy in children. According to a global survey, the most common symptoms of sclerodermomyositis (scleroderma-dermatomyositis overlap) are sclerodactyly, Raynaud's phenomenon, and digital ulcerations of fingers, myalgia or arthralgia, puffy fingers, usually slight sclerodermiform masklike facies, dysphagia (esophageal dysmotility), and in about 30% of patient's ILD.<sup>1</sup> Periorbital edema and erythema, Gottron's papules and sign, and erythematous and poikilodermatous lesions on the trunk and arms (also known as the "shawl sign") are all signs of dermatomyositis. Any type of inflammatory myopathy, including synthetase syndrome and dermatomyositis, can cause chronic hyperkeratotic eczematous changes in the hands (mechanic hands). Their presence in sclerodermatomyositis patients would support the group's association with autoimmune myositis, but this symptom does not appear to be specific or diagnostic for this overlap. These findings include relatively acute disease onset, constitutional symptoms (e.g., fever and weight loss), myositis, Raynaud's phenomenon, arthritis that is generally nonerosive, and ILD. Additionally, they will experience typical DM cutaneous eruptions.<sup>2</sup>

Our patient meets the Bohan and Peter criteria for possible dermatomyositis diagnosis.<sup>3</sup> This criteria aid in the diagnosis of dermatomyositis but does not specifically rule out overlap syndrome. As of now, there are no specific diagnostic criteria for juvenile scleromyositis. Anti-PM/Scl autoantibodies are found in PM, dermatomyositis, SSc, and systemic autoimmune disease overlap syndromes. PM-1 is an important epitope of the PM/Scl complex, and antibodies to PM-1 can be detected using a validated enzyme-linked immunosorbent assay (ELISA).<sup>4</sup> Antinuclear antibodies (ANA) were found to be elevated in scleromyositis patients in addition to anti-PM/Scl antibodies. A cohort study found that more than 70% of patients tested positive for ANA. Those who had overlap syndrome and anti-PM-Scl antibody positivity also had a significantly higher HLA-DRB1 haplotype.<sup>5</sup>

## Case Presentation

### History

A previously athletic and healthy 16-year-old Jordanian adolescent boy, accompanied by his father, was referred to the rheumatology clinic with a 6-month history of progressive generalized muscle weakness, weight loss, hoarseness of voice, swallowing difficulties with solids, and skin tightening. He initially experienced bilateral ankle pain with exercise, which was relieved in part by rest and anti-inflammatory medication. He was examined by a physical therapist, who diagnosed him with an ankle sprain.

The joint symptoms worsened over the next few weeks, affecting the knees, elbows, wrists, and hands, and interfering with his daily activities. It also included an unintentional 13-kg weight loss over the course of 4 weeks due to sudden inability to swallow solid foods and liquids. The patient experienced a cold sensation as well as skin discoloration involving the digits in January 2022, which was caused by

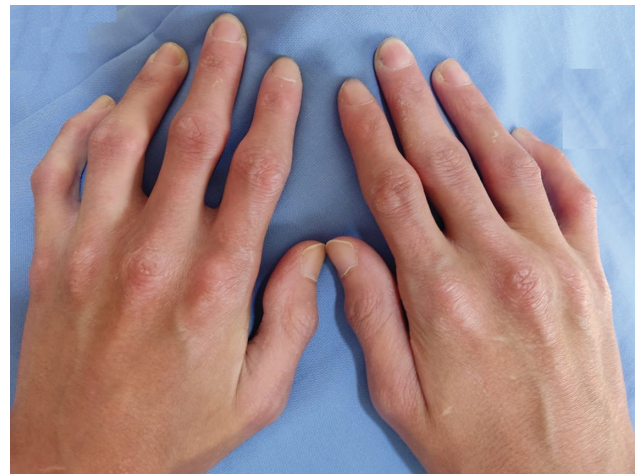cold exposure. The discoloration of the digits is described as white, followed by blue and purplish, which is consistent with the phenomenon of triphasic notes.

Later, he noticed hoarseness in his voice, which is associated with solid-food dysphagia. He also reports skin dryness, particularly on the digits, skin tightening on the dorsal aspect of the hands, forearms, arms, and face, and a decrease in oral aperture. He reports no recurring cough, shortness of breath, or wheezing. He has no history of gastrointestinal symptoms such as heartburn or changes in bowel habits. He does not smoke or consume alcohol. There is no family history of CTD. There have been no previous surgeries or medication administrations.

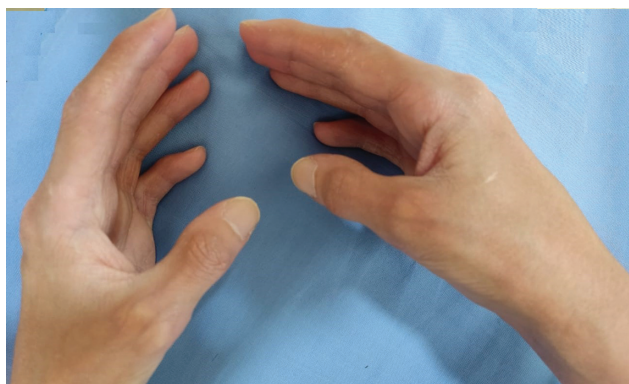### Physical Examination

On general examination, the patient was lethargic but attentive to commands, and his voice was noticeably hoarse. His vital signs were normal, and his body mass index (BMI) was 15.8. He has a narrower (4 cm) oral aperture and thicker skin on his face (►Fig. 1). On skin examination, he had a shawl sign and a V sign on his chest. Muscle wasting was also observed (►Fig. 2). Salt-and-pepper rash involving the elbows (►Fig. 3) and elbow dryness (►Fig. 4) were observed. Musculoskeletal examination revealed muscle wasting on the dorsal aspect of his hands. ►Fig. 5 shows pulp loss and diffuse puffiness and thickness. ►Fig. 6 shows that there was sclerodactyly, skin thickening, and Gottron's papules.

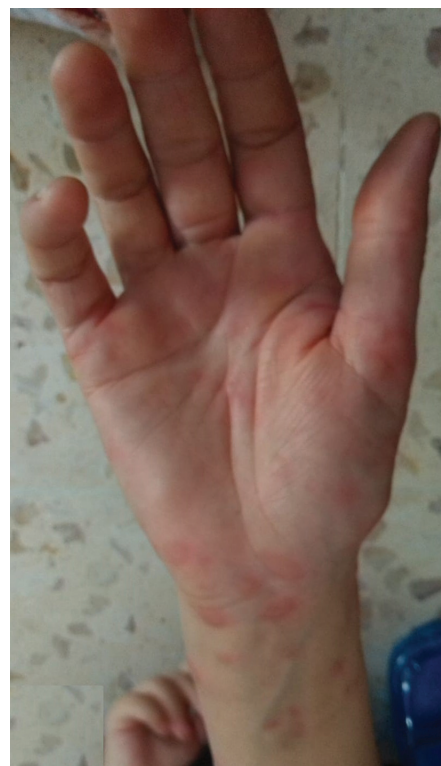In addition, he had a 5-degree flexion contracture and a limited range of motion in his elbows. Flexion contracture at the proximal interphalangeal (PIP) and distal interphalangeal (DIP), as well as fissuring and skin dryness, was present involving the second, third, and fourth digits (►Fig. 6). The upper extremities had a power of 4/5, while the proximal extremities had a power of 3/5. The patient was unable to stand from the seated position without assistance or without using his upper extremities. Cervical flexors and extensors were noticeably weak. The modified Rodnan skin score



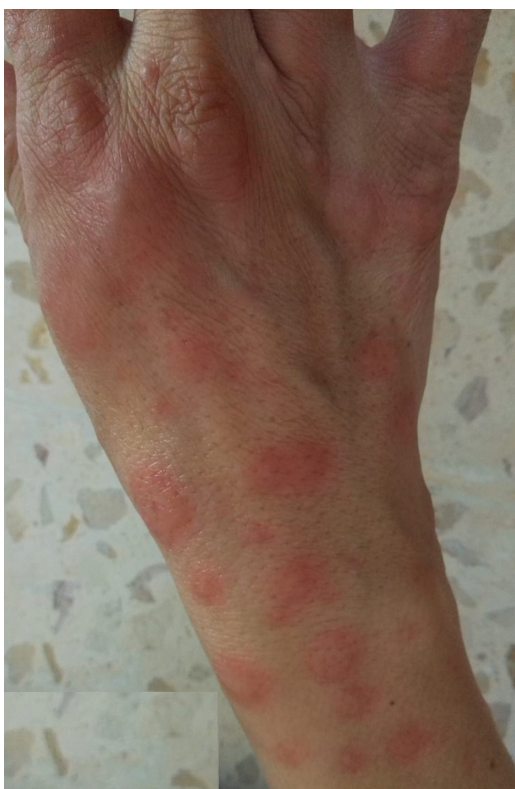**Fig. 1** Images of the patient hands showing thickening of the skin distal to the metacarpophalangeal joints (MCP), interosseous muscle wasting and hyperkeratosis, scaly eruption of the skin involving the MCPs, and proximal interphalangeal joints.



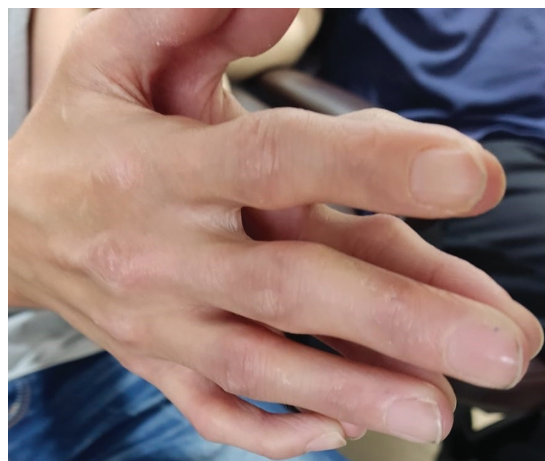**Fig. 2** Images of the patient hands showing a nonpruritic, hyperkeratotic, and scaly eruption on the ulnar side of the thumb and radial side of other fingers.



**Fig. 4** Raised pruritic erythematous skin eruption involving the volar aspect of the palm, wrist, and forearm.



**Fig. 3** Raised erythematous pruritic skin eruption involving the dorsal aspect of the right hand.



**Fig. 5** Images of the patient hands showing thickening of the skin distal to the metacarpophalangeal joints (MCP), interosseous muscle wasting and hyperkeratosis, scaly eruption of the skin involving the MCPs and proximal interphalangeal joints.

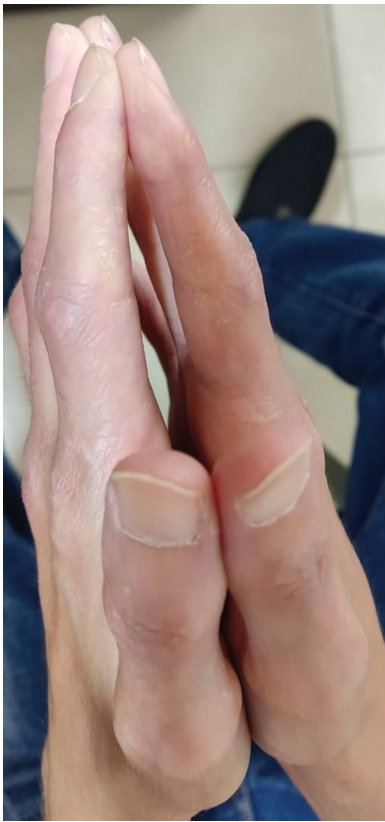(MRSS) was 14. A pulmonary examination showed bibasilar crackles. The rest of the physical examination was unremarkable.

**Investigations**

Initial autoimmune workup included a complete blood count (CBC), liver function tests, lipids, metabolic chemistry, ferritin, glucose, erythrocyte sedimentation rate (ESR), and vitamins. ESR was 34 mm/h (reference range: <20 mm/h), creatinine kinase (CK) was 2,217 μ/L (reference range: 20–

200 μ/L), and immunofluorescence-ANA (1:280) was positive. Extractable nuclear antigen antibodies, including anti-Sjogren’s Syndrome A (SSA), anti-Sjogren’s Syndrome B (SSB), Jo-1 Ab, Scl-70, anti-centromere Ab, Anti-smith-Ab, Sm/RNP, and RNP antibodies were unremarkable. Normal Complement 3 (C3) and Complement 4 (C4) complements as well as dsDNA. The abnormal serum protein electrophoresis (SPEP)





**Fig. 6** Image of the patient's hands showing thinning of the skin consistent with sclerodactyly in addition to dryness and cracking of the skin over the radial aspect of the digits with tapering of the digits.

revealed a polyclonal pattern, but the rest of the autoimmune workup was unremarkable. He had thrombocytosis, but his hemoglobin was normal, and the rest of CBC was unremarkable. Lactate dehydrogenase (LDH) was high at 873  $\mu\text{L}$  (reference range: 1.9–2.65  $\mu\text{L}$ ) and there were elevated levels of aspartate transaminase (AST) at 82.4  $\mu\text{L}$  (reference range: 0–37  $\mu\text{L}$ ) and alanine transaminase (ALT) at 71.7  $\mu\text{L}$  (reference range: 0–42  $\mu\text{L}$ ).

High-resolution computed tomography (CT) of the chest revealed bibasilar fibrosis, which was consistent with the nonspecific interstitial pneumonia (NSIP) pattern. A connective tissue disease, specifically SSc, was suspected clinically. A cardiac echo revealed an ejection fraction of 65%, no valvular abnormalities, and a normal right ventricular systolic pressure. An ultrasound of the abdomen revealed mild hepatomegaly, and a large spleen of 11.5 cm. An upper endoscopy revealed no abnormalities except for weak esophageal peristalsis. A videofluoroscopic swallowing study revealed delayed triggering of the swallow reflex.

### Treatment

After reviewing his blood work, he was started on 40 mg of oral prednisolone and 5 mg of amlodipine daily, with a 10-day follow-up. At his follow-up appointment, he was given a course of intravenous (IV) rituximab 1,000 mg spaced by 2 weeks, followed by mycophenolic acid 500 mg twice a day for maintenance.

The patient was eventually weaned off steroids after 4 months of follow-up appointments and can now stand without assistance. Furthermore, his hoarseness of voice, muscle power, and appetite improved. However, there were some noticeable skin rashes and photosensitivity, and CK levels dropped to 1,399/L within 2 months and eventually normalized.

### Discussion

Improved treatment and prognosis for sclerodermatomyositis patients may result from a better understanding of the similarities and differences in clinical and biologic features, as well as outcome. A case-control univariate analysis revealed that 10% of patients with sclerodermatomyositis had a positive PM-Scl Ab. It also revealed that heart involvement, renal crisis, and reduced forced vital capacity (FVC) are far more common in patients with myopathy than in controls. Heart involvement could include conductive abnormalities, left ventricular ejection fraction <60%, or congestive heart failure.<sup>6</sup> In all, 7.3% of the 1,728 patients in a different univariate analysis from the Australian Scleroderma Cohort Study had an SSc overlap. Additionally, Asians were more likely to exhibit this overlap, which had a younger onset and a smaller cutaneous SSc. The frequency of pulmonary hypertension or ILD was similar for all three factors.<sup>7</sup>

PM-SSc overlap was found in 5.9% of the Nijmegen SSc cohort. The mortality rate in this study was 50% owing primarily to cardiac disease. It is important to remember that the prevalence of pulmonary fibrosis was significantly higher in overlap patients. Furthermore, they demonstrated that in muscle biopsies, the PM-SSc overlap is characterized by necrotizing muscle fibers and inflammation.<sup>8</sup> Juvenile scleromyositis treatment protocols vary, but may include corticosteroids, methotrexate, disease-modifying agents such as cyclosporin, IV immunoglobulins (IVIG), or anti-tumor necrosis factor alpha (anti-TNF-alpha) blockers may be used in refractory cases.<sup>9</sup>

Managing those patients over time requires a multidisciplinary approach. Furthermore, monitoring the pulmonary function is critical in scleromyositis patients who also suffer from ILD. However, some of these patients may develop myocardial involvement, which necessitates regular echocardiograms to detect any cardiac involvement. It is clinically relevant because studies have shown that when it comes to cardiac involvement, scleromyositis has a worse prognosis than SSc alone.<sup>8</sup> **Table 1** summarizes the case reports with similar clinical presentation to our patient.<sup>10,11</sup>

Some tests were not performed on this patient due to financial constraints. This includes a muscle biopsy and a full myositis panel.

### Conclusion

In summary, this study highlights the importance of increasing awareness of overlap syndromes, specifically, juvenile scleromyositis. Furthermore, this case report is about a 16-year-old adolescent boy with juvenile scleromyositis, as well

Table 1

Patient	Age of diagnosis (y)/gender/ethnicity	Clinical presentation	Autoimmune workup	Chest imaging	Treatment	Follow-up	Reference
1.	16/male/Middle Eastern	6 mo muscle weakness, hoarseness and diffuse skin tightening, Raynaud's phenomenon (RP), and dysphagia to solids.	If ANA is positive, elevated liver and muscle enzymes	HRCT revealed bibasilar lung fibrosis (NSIP pattern)	IV rituximab Oral mycophenolate Oral glucocorticoids	Clinical and serological improvements occurred within 6 wk of starting treatments. The patient can now stand without assistance	-
2.	8/male/White	Diffuse hand swelling, tight skin, and contractures of the metacarpophalangeal, proximal interphalangeal, and distal interphalangeal joints as well as the wrists. His muscle strength was normal. Gottron's papules with cracking of the tips of fingers and toes	Anti-PM/Scl antibodies were found in a panel of myositis antibody profile	Not available	Not available	At the age of 14, the treatment was stopped. She was followed for 7 y after treatment was stopped and remained asymptomatic	10
3.	12/female/African American	Arthralgias, proximal muscle weakness, heliotrope rash, periungual telangiectases, Gottron's papules, skin tightness, and thinning of the subcutaneous digital tissue	Anti-PM/Scl antibodies were found in the myositis antibody profile	Not available	Not available	Not available	10
4.	14/female/White	Proximal muscle, calcinosis cutis involving the fingers and hands. She subsequently developed sclerodactyly and skin tightness around her mouth	Elevated muscle enzymes, and positive anti-PM/Scl antibodies	Not available	Her disease was resistant to IVIG + methotrexate + glucocorticoids and was commenced on IV rituximab	She stopped taking her medication when she was 17 y old. She was doing well 2 y later, with only mild RP and residual sclerodactyly	10
5.	11/female/African American	Muscle weakness, Gottron's papules, and a heliotrope rash. She subsequently developed bilateral parotid swelling, and tight, overlying hyperpigmented skin, recurrence of periungual telangiectasias, and elbow calcinosis	Elevated muscle enzymes and positive anti-SSA and anti-PM/Scl antibodies	Not available	Methotrexate	Treatment was discontinued at age 14 after she had been asymptomatic for 12 mo	10
6.	15/female/NA	Recurrent fever; productive cough, dyspnea, proximal muscle weakness of the lower limbs, with functional limitations, weight loss, dysphonia, and swallowing difficulties	Elevated acute-phase reactants, liver enzymes, LDH, and muscle enzymes. Positive anti-PM/Scl antibodies	Chest radiograph revealed a heterogeneous opacity in the right lower pulmonary lobe and an atelectatic band at this level, with diaphragm traction	Glucocorticoids, and immunosuppressive agents	Significant clinical muscle power improvement, and amelioration of swallowing and phonation. She regained mobility and maintained orthostatic position and walked for short distances. Serum CK normalized and serum inflammatory markers became unremarkable	11

Abbreviations: ANA, antinuclear antibodies; CK, creatine kinase; HRCT, high-resolution computed tomography; IV, intravenous; IVIG, intravenous immunoglobulins; LDH, lactate dehydrogenase; NSIP, nonspecific interstitial pneumonia.

as the clinical manifestations and treatment options. Our patient was commenced on a titration dose of oral prednisolone and IV rituximab and, later, on mycophenolic acid for maintenance. Patients with this overlap syndrome can develop ILD, and their pulmonary function must be monitored throughout the course of the disease. Depending on the clinical manifestations, a multidisciplinary approach is require to manage such patients.

#### Author Contributions

All authors contributed to the clinical care, data collection, manuscript drafting and revision. They all approved its final version.

#### Compliance with Ethical Principles

Written informed consent was obtained from the patient and parents for publication of the submitted article.

#### Funding and Sponsorship

None.

#### Conflict of Interest

None declared.

#### References

- Jablonska S, Chorzelski TP, Blaszczyk M, Jarzabek-Chorzelska M, Kumar V, Beutner EH. Scleroderma/polymyositis overlap syndromes and their immunologic markers. *Clin Dermatol* 1992;10(04):457–472
- Christiphor-Stine L, Amato AA, Vleugels RA, Targoff IN, Shefner JM, Callen J, Curtis MR. Diagnosis and differential diagnosis of dermatomyositis and polymyositis in adults. *UpToDate*. <https://www.uptodate.com/contents/diagnosis-and-differential-diagnosis-of-dermatomyositis-and-polymyositis-in-adults#>. Published February 24, 2022. Accessed August 9, 2022
- Oldroyd A, Chinoy H. Recent developments in classification criteria and diagnosis guidelines for idiopathic inflammatory myopathies. *Curr Opin Rheumatol* 2018;30(06):606–613
- D'Aoust J, Hudson M, Tatibouet S, et al; Canadian Scleroderma Research Group. Clinical and serologic correlates of anti-PM/Scl antibodies in systemic sclerosis: a multicenter study of 763 patients. *Arthritis Rheumatol* 2014;66(06):1608–1615
- Wedderburn LR, McHugh NJ, Chinoy H, et al; Juvenile Dermatomyositis Research Group (JDRG) HLA class II haplotype and autoantibody associations in children with juvenile dermatomyositis and juvenile dermatomyositis-scleroderma overlap. *Rheumatology (Oxford)* 2007;46(12):1786–1791
- Ranque B, Bérezné A, Le-Guern V, et al. Myopathies related to systemic sclerosis: a case-control study of associated clinical and immunological features. *Scand J Rheumatol* 2010;39(06):498–505
- Fairley JL, Hansen D, Proudman S, et al; Australian Scleroderma Interest Group. Clinical features of systemic sclerosis-mixed connective tissue disease and systemic sclerosis overlap syndromes. *Arthritis Care Res (Hoboken)* 2021;73(05):732–741
- Bhansing KJ, Lammens M, Knaapen HK, van Riel PL, van Engelen BG, Vonk MC. Scleroderma-polymyositis overlap syndrome versus idiopathic polymyositis and systemic sclerosis: a descriptive study on clinical features and myopathology. *Arthritis Res Ther* 2014;16(03):R111
- Iaccarino L, Gatto M, Bettio S, et al. Overlap connective tissue disease syndromes. *Autoimmun Rev* 2013;12(03):363–373
- Fotis L, Baszis KW, White AJ, French AR. Four cases of anti-PM/SCL antibody-positive juvenile overlap syndrome with features of myositis and systemic sclerosis. *J Rheumatol* 2016;43(09):1768–1769
- Popescu NA, Manea D, Capitanescu G, Cinteza E, Ionescu MD, Balgradean M. Respiratory failure in a rare case of juvenile dermatomyositis: systemic scleroderma overlap syndrome. *Maedica (Buchar)* 2020;15(03):394–400