

Metastatic Ewing's Sarcoma in Right Colon

Sunil Raviraj Kothakota¹ Srinivas Nistala¹ Satish Babu Boddepli²

¹Department of Gastroenterology, Medicover Hospital, Visakhapatnam, Andhra Pradesh, India

²Department of Gastroenterology, Apollo Hospital, Visakhapatnam, Andhra Pradesh, India

Address for correspondence Sunil Raviraj Kothakota, DNB, Department of Gastroenterology, Medicover Hospital, Visakhapatnam 695029, Andhra Pradesh, India (e-mail: ksrdnb@gmail.com).

J Digest Endosc 2023;14:60–61.

A 36-year-old man underwent chemoradiotherapy followed by surgery for Ewing's sarcoma of paranasal sinuses. Post-treatment he recovered well. Two years later he presented with abdomen pain, vomiting, and melena. Contrast-enhanced computed tomography of abdomen showed mass lesion in right colon, involving cecum and ascending colon along with abdomen lymphadenopathy and ascites (►Fig. 1). Colonoscopy was performed that detected large ulceroproliferative growth with luminal

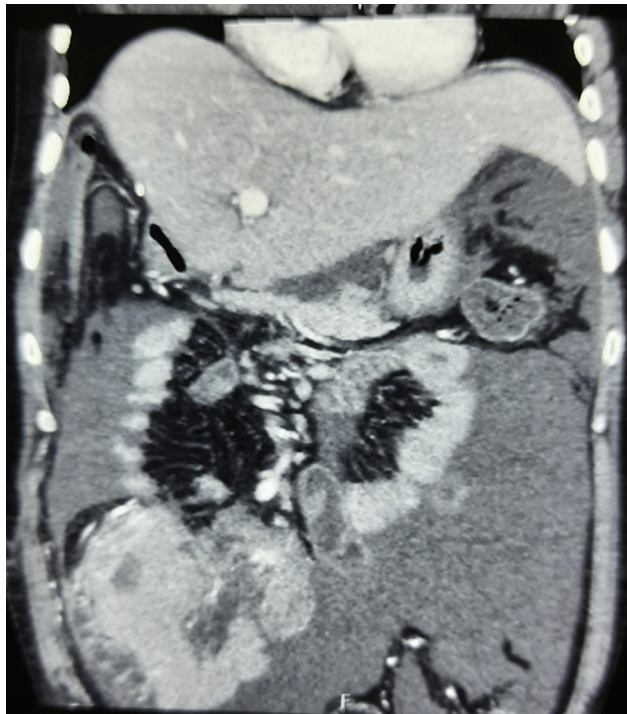

Fig. 1 Contrast-enhanced computed tomography of abdomen showed mass lesion in right colon, involving cecum and ascending colon along with abdomen lymphadenopathy and ascites.

narrowing in ascending colon, which could not negotiate scope further to visualize cecum (►Fig. 2). Endoscopically lesion was looking like adenocarcinoma; however, histopathology examination was suggestive of metastatic round cell tumor. In the background of Ewing's tumor in the past, immunohistopathology examination was done and CD-99 and vimentin were found strongly positive (►Figs. 3 and 4) with high K_i-index (90%) suggestive of colonic Ewing's sarcoma. Patient was managed with right hemicolectomy plus ileocecal anastomosis followed by chemotherapy.

Ewing's sarcoma is a malignant tumor that primarily involves bone and soft tissue. Among extraosseous tumors, the most common sites of disease are trunk, extremities, head and neck, and retroperitoneum. However, involvement of colon is rare.¹ Management of Ewing's sarcoma has

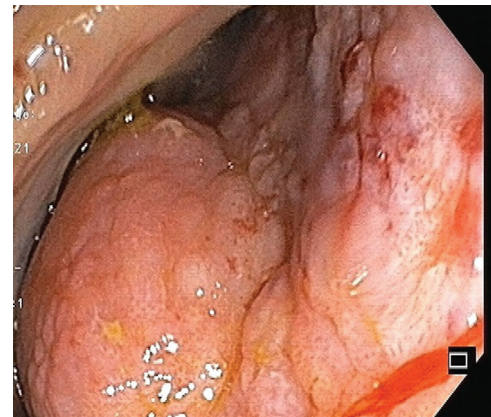


Fig. 2 Colonoscopy showing large growth in ascending colon.

article published online
March 1, 2023

DOI <https://doi.org/10.1055/s-0043-1762573>.
ISSN 0976-5042.

© 2023. The Author(s).

This is an open access article published by Thieme under the terms of the Creative Commons Attribution License, permitting unrestricted use, distribution, and reproduction so long as the original work is properly cited. (<https://creativecommons.org/licenses/by/4.0/>)

Thieme Medical and Scientific Publishers Pvt. Ltd., A-12, 2nd Floor, Sector 2, Noida-201301 UP, India

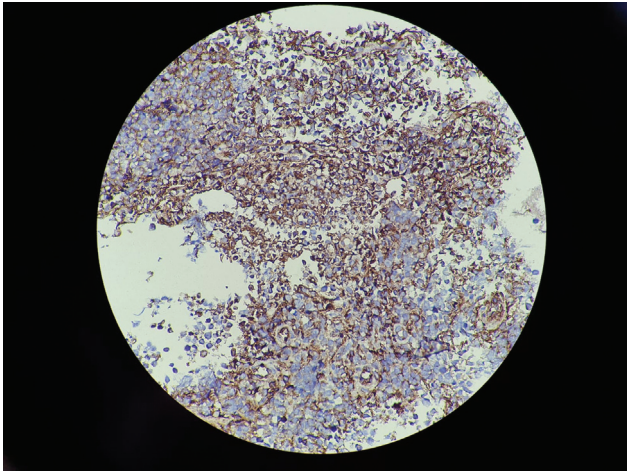


Fig. 3 Strongly positive CD-99 on immunohistochemistry.

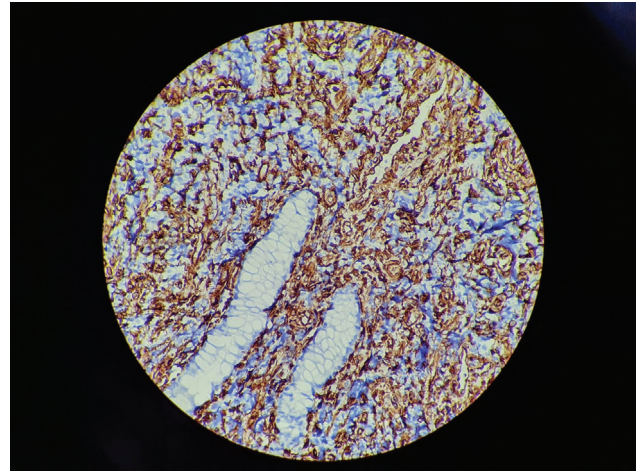


Fig. 4 Strongly positive vimentin on immunohistochemistry.

evolved over the last few decades to the present treatment involving multiagent chemotherapy combined with surgery and/or radiotherapy. Combination chemotherapy has traditionally included vincristine, doxorubicin, cyclophosphamide, and dactinomycin.² Our case was treated with surgical resection of tumor mass followed by chemotherapy. Intestinal metastasis of Ewing's tumor without lung and liver involvement is very rare. Very few cases of colonic Ewing's tumor were reported in literature.^{1,3} To the best of our knowledge, only eight cases of colorectal Ewing's sarcoma have been reported with only three cases reported in right colon.³

Informed Consent

Informed consent was obtained from patient.

Funding

None.

Conflict of Interest

None declared.

References

- 1 Parcesepe P, Giordano G, Zanella C, et al. Colonic Ewing sarcoma/PNET associated with liver metastases: a systematic review and case report. *Pathol Res Pract* 2019;215(02):387–391
- 2 Tiwari A, Gupta H, Jain S, Kapoor G. Outcome of multimodality treatment of Ewing's sarcoma of the extremities. *Indian J Orthop* 2010;44(04):378–383
- 3 Modi S, Vasdev N, Gupta P, Goyal H. Ewing sarcoma arising in colon and ovary—two rare sites of presentation. *Indian J Pathol Microbiol* 2022;65(02):433–436