



Society of Chest Imaging and Interventions Consensus Guidelines for the Interventional Radiology Management of Hemoptysis

Rajat Singh¹ Santhosh Babu K.B.¹ Priyanka Naranje² Junaid Kazimi² Pawan K. Garg³
Daksh Chandra⁴ Bhavesh A. Popat^{5,6,7} Nitin S. Shetty⁴ Ujjwal Gors⁸ Leena Robinson Vimala⁹
Pushpinder S. Khera³ Aparna Irodi⁹ Suyash Kulkarni⁴ Shyamkumar N. Keshava¹ Ashu S. Bhalla²

¹ Department of Interventional Radiology, Division of Clinical Radiology, Christian Medical College, Vellore, Tamil Nadu, India

² Department of Radio-Diagnosis and Interventional Radiology, All India Institute of Medical Sciences, New Delhi, India

³ Department of Diagnostic and Interventional Radiology, All India Institute of Medical Sciences, Jodhpur, Jodhpur, Rajasthan, India

⁴ Interventional Radiology Department, Tata Memorial Centre, Homi Bhabha National Institute, Mumbai, Maharashtra, India

⁵ Department of Interventional Radiology, Hinduja Hospital, Mumbai, Maharashtra, India

⁶ Department of Interventional Radiology, Breach Candy Hospital, Mumbai, Maharashtra, India

Address for correspondence Shyamkumar N. Keshava, DMRD, DNB, FICR, FRANZCR (Australia), FRCR (UK), Department of Interventional Radiology, Division of Clinical Radiology, Christian Medical College, Vellore, Tamil Nadu 632002, India (e-mail: shyamkumar.n.keshava@gmail.com).

⁷ Department of Interventional Radiology, Saifee Hospital, Mumbai, Maharashtra, India

⁸ Department of Radiodiagnosis, Postgraduate Institute of Medical Education and Research, Chandigarh, India

⁹ Department of Radiodiagnosis, Division of Clinical Radiology, Christian Medical College, Vellore, Tamil Nadu, India

Indian J Radiol Imaging 2023;33:361–372.

Abstract

Keywords

- ▶ interventional radiology
- ▶ bronchial artery embolization
- ▶ guidelines
- ▶ hemoptysis
- ▶ life-threatening hemoptysis

The recommendations from the Society of Chest Imaging and Interventions expert group comprehensively cover all the aspects of management of hemoptysis, highlighting the role of diagnostic and interventional radiology. The diversity existing in etiopathology, imaging findings, and management of hemoptysis has been addressed. The management algorithm recommends the options for effective treatment while minimizing the chances of recurrence, based on the best evidence available and opinion from the experts.

Introduction

Hemoptysis refers to the expectoration of blood, originating from the lower respiratory tract. It is an alarming symptom for patients and is challenging to diagnose and treat. Imaging is essential to identify the cause and site of hemoptysis, which could be parenchymal, airway related, or vascular. The

pulmonary arteries and bronchial arteries (BAs) constitute the dual arterial system of the lungs, of which pulmonary arteries contribute to 90% of arterial supply.¹ However, BAs are responsible for hemoptysis in more than 90% of cases.² Based on geographical location, the causes of hemoptysis can be variable and it can also turn fatal if left untreated.

article published online
April 10, 2023

DOI <https://doi.org/10.1055/s-0043-1762552>.
ISSN 0971-3026.

© 2023. Indian Radiological Association. All rights reserved.
This is an open access article published by Thieme under the terms of the Creative Commons Attribution-NonDerivative-NonCommercial-License, permitting copying and reproduction so long as the original work is given appropriate credit. Contents may not be used for commercial purposes, or adapted, remixed, transformed or built upon. (<https://creativecommons.org/licenses/by-nc-nd/4.0/>)
Thieme Medical and Scientific Publishers Pvt. Ltd., A-12, 2nd Floor, Sector 2, Noida-201301 UP, India

In 2020, the American College of Radiology (ACR) updated its guidelines for diagnostic and treatment strategies for hemoptysis.³ In 2020, the Cardiovascular and Interventional Radiological Society of Europe published standard of practice guidelines on BA embolization (BAE).¹ Kaufman and Kwan reviewed the literature on BAE in seminars in interventional radiology (IR).⁴ Hemoptysis is a relatively common symptom accounting for a significant portion of pulmonary clinic outpatient visits (6.8%) and inpatients' admissions (11%) as well as thoracic surgery referrals (38%).⁵ We propose guidelines from the Society of Chest Imaging and Interventions (SCII) based on the updated literature and the opinions of the experts taking cognizance of issues, especially in tuberculosis (TB) endemic regions.

Methods

The mandate of formulating the SCII guidelines for management of hemoptysis was given to two experts in the field, who subsequently formed a committee of experts from multiple institutions across India. After initial brainstorming, questions were framed. All relevant literature was reviewed in various aspects including clinical presentation, etiopathology, clinical evaluation, imaging, bronchoscopy, options of management, IR, and follow-up. The scope for future studies was also considered.

The committee members were asked to work on specific sections of life-threatening hemoptysis. The key components of the guidelines were statements in response to pertinent questions in the evaluation and management of life-threatening hemoptysis. The level of evidence used were as per the 2020 American Heart Association Guidelines for Cardiopulmonary Resuscitation and Emergency Cardiovascular Care (UpToDate grading guide).⁶ The article was completed after several online discussions and revisions.

1. Clinical Presentation and Severity Assessment

Hemoptysis was previously classified as mild, moderate, and massive predominantly based on the volume of the blood expectorated. However, volume alone cannot be used to assess the severity.^{5,7,8}

1A. Why is it important to define life-threatening hemoptysis?

The definition of life-threatening hemoptysis shows wide variation across literature due to a lack of generalized consensus.⁸ (Level B-NR)

Remarks:

Conventionally, massive hemoptysis was defined by the volume of blood expectorated.¹ Criteria based purely on the volume of blood cannot be precisely used since quantifying the amount of expectorated blood is challenging. Additionally, small amounts of hemoptysis in patients with the underlying cardiorespiratory disease may be enough to endanger life, particularly if expectorated blood obstructs a major airway or there is very little residual functional lung tissue.^{5,7,8}

1B. What is life-threatening hemoptysis?

Life-threatening hemoptysis may be defined as any hemoptysis that is > 150 mL in volume in 24 hours or hemoptysis at a rate of 100 mL/h, and hemoptysis that causes airway obstruction/respiratory failure/hemodynamic instability requiring blood transfusions.^{5,7-9} (Level A)

Remarks:

Non-life-threatening hemoptysis is defined as the hemoptysis that does not satisfy the above criteria. Non-life-threatening hemoptysis can also be divided into streaky and non-streaky hemoptysis.^{5,7,8} This article will mainly deal with life-threatening and non-streaky hemoptysis.

Life-threatening hemoptysis is rare, accounting for 4.8 to 14% of the patients who present with hemoptysis.⁵ Life-threatening hemoptysis is a respiratory emergency, associated with a high mortality rate of 50 to 100%. Patient dies because of asphyxiation and not exsanguination. However, when optimal diagnosis and treatment are provided, mortality is less than 20%.¹

1C. What is pseudohemoptysis?

Pseudohemoptysis is the one which may be mistaken for hemoptysis, wherein the source of hemorrhage is other than the lungs, like the upper gastrointestinal tract or the upper respiratory tract (mouth, nose, or throat).¹ (Level B -NR)

Remarks:

Careful history and inspection of the nasopharynx can mostly determine whether the bleeding originates from the respiratory tract (alkaline, bright red, foamy blood, breathing difficulty, the sensation of warmth in the thorax) or the gastrointestinal tract (hematinized blood, acidic pH, food particles, abdominal pain, nausea).¹

2. Etiology and Pathology

2A. What is the most common cause of hemoptysis?

The causes of hemoptysis are variable depending on geographical locations, patient risk factors, and age.^{8,10-12} (Level B- NR)

TB is the most common cause of hemoptysis in India and other TB endemic countries.

Remarks:

Hemoptysis can result from several causes. In TB endemic regions, the most common cause of hemoptysis is TB, accounting for 65 to 79% of cases.¹⁰⁻¹² This includes active tuberculous infection, chronic sequelae, bronchiectasis, and superadded infection with underlying TB sequelae.

In developed countries, few studies have mentioned bronchial neoplasms (primary and secondary) (19–28%) as the most common cause, while other studies have mentioned bronchiectasis (31–57%) as the most common cause.^{8,13-15} The other less common etiologies include fungal infection, non-tubercular mycobacterial infection, chronic lung disease, vascular lesions like pulmonary arteriovenous malformations (AVMs), vasculitis, trauma, and iatrogenic. In some cases, the diagnosis remains cryptogenic.

The pathophysiology for the bleeding includes chronic inflammation, hypoxia-induced neoangiogenesis, and fragile

vessel formation. There may also be direct injury or invasion of the blood vessel by tumor or infection.

The source of hemoptysis can be the airway, parenchyma, or vessels.¹⁶ The airway sources include bronchiectasis, neoplasms, bronchitis, foreign body, etc. Parenchymal causes include infections (TB, fungal, and other pneumonias). Vascular causes include pulmonary AVMs, Rasmussen's aneurysm, bronchopulmonary fistula, vasculitis, etc.

2B. Which is the most common vascular source of hemoptysis?

The bronchial arterial system is the source of hemoptysis in most cases.^{1,17} (Level B-NR)

Remarks:

Pulmonary circulation is the main blood supply to the lung and participates in oxygenation while bronchial circulation is the main "nutrient" supply to the lung and adjacent structure. In most cases, the source of hemoptysis is BAs (90%) followed by nonbronchial systemic arteries or collaterals (NBSAs or NBCAs) (5%) and pulmonary arteries (5%).^{1,17}

In cases of chronic inflammation and hypoxia, BAs and/or NBSAs hypertrophy to supply that part of the lung parenchyma. Since these are under systemic arterial pressure, they can spontaneously rupture and lead to hemoptysis. Less commonly the pulmonary arteries are directly injured or invaded by the inflammatory or neoplastic pathology and can lead to hemoptysis.

3. Clinical Evaluation

3A. What is the role of history taking in a case of hemoptysis?

A good history allows narrowing of the differential diagnosis for the cause of hemoptysis and hence appropriate management. (Level – C-EO)

Remarks:

The volume and frequency of hemoptysis, whether blood is coughed up with sputum or is frank blood should be asked. In addition, symptoms such as fever, chills, and weight loss would help discern an underlying infection. History of active or recent pulmonary TB must be asked for in all cases.¹⁸

History of smoking must be asked for. Any history of nonsteroidal anti-inflammatory agents, antiplatelet, and anticoagulant usage is important.¹⁹ History of substance abuse (especially injectables) would indicate possible right-sided infective endocarditis.¹⁹

Systemic autoimmune and granulomatous disorders such as rheumatoid arthritis, Goodpasture's syndrome, and granulomatosis with polyangiitis must be ruled out by asking for a history of joint pain, skin rash, hematuria, and epistaxis.^{18,19}

3B. What are the important components of a bedside clinical examination for a patient presenting with hemoptysis?

A well-directed physical examination builds upon the information gathered from the history to segregate patients who require emergent embolization from those

for whom it can be done early on a nonemergent basis. (Level C-EO)

Remarks:

Assessment of the patient, whether he/she is in respiratory distress (having tachypnea, cyanosis, struggling to speak, disoriented, and using accessory muscles of respiration) or is comfortable during the examination is essential. The severity of anemia needs to be evaluated. The sputum if present must be assessed for color (white vs. yellow) and amount of blood (tinge of hemorrhage vs. mostly bloody).¹⁸⁻²⁰

Nose and upper aerodigestive tract examination can rule out any local cause of bleeding from these sites. The presence of telangiectasias in perioral location, tongue, or buccal mucosa can suggest hereditary hemorrhagic telangiectasia (HHT).¹⁹ Skin petechiae, ecchymosis, and bruising would suggest an underlying coagulopathy. Skin rashes can indicate vasculitis and systemic lupus erythematosus.^{18,19} Auscultation should focus on murmurs, wheeze, bruit, or bronchial breathing.^{19,20} Presence of calf swelling with associated signs of deep venous thrombosis (calf tenderness and warmth) would indicate venous thrombosis with likely pulmonary embolism or infarction.^{18,20}

3C: What are the important laboratory investigations which should be done?

The lab investigations will depend on the clinical presentation including severity and associated symptoms. (Level C-EO)

Remarks:

In life-threatening hemoptysis, one of the most important blood investigations to be done is the blood cross-matching and typing.¹⁸⁻²⁰ Since many of these patients require transfusions of whole blood and blood products such as fresh frozen plasma.

In addition complete blood count, prothrombin time (with international normalized ratio), arterial blood gas analysis (to assess and monitor hypoxemia and acidosis), serum electrolytes, and kidney function tests should be sent for.¹⁸⁻²⁰ The latter are especially important to assess the degree of hypovolemic prerenal azotemia and as a prerequisite for the patient to undergo a contrast study such as computed tomography (CT) angiography (CTA) and/or digital subtraction angiography (DSA) in due course.

Sputum culture and gram staining are important to look for the etiology of infection.^{18,19} Echocardiography should be done if a valvular, cardiac, or pulmonary arterial cause is suspected.^{18,19} Specific tests to rule out autoimmune diseases are to be considered in the appropriate clinical scenario.¹⁸⁻²⁰

4. Imaging Evaluation

4A. What are the various imaging modalities that can be used for the evaluation of hemoptysis?

Chest radiography (CXR), bronchoscopy, multidetector CT (MDCT), MDCT angiography (MDCTA), and DSA can be used for hemoptysis evaluation.²¹ (Level A).

Remarks:

The CXR is a universally available basic modality, that could be performed even bedside. CTA is a noninvasive and useful imaging modality for hemoptysis which allows the evaluation of the lung parenchyma, airways, and thoracic vessels. In addition to identifying the vascular source of bleeding, it can also detect the underlying abnormalities like bronchiectasis, pulmonary infections, lung cancer, etc.

CTA prior to embolization facilitates the identification of hypertrophied BAs and NBSAs.

4B. Which imaging modality is best suited for evaluating a vitally stable patient with hemoptysis and what is the imaging protocol?

CTA is best suited for evaluating the cause and source of bleeding. CT is rated as “usually appropriate” for both life-threatening and non-life-threatening hemoptysis in the ACR appropriateness criteria.²¹ (Level A)

Remarks:

CTA of the thorax can be carried out during a single breath hold in most patients, by using a 16 and above detector row scanners. A contrast-enhanced study is mandatory for identifying pulmonary and systemic arterial vessels. Image acquisition should extend from the inferior portion of the neck to include the supra-aortic great vessels, to the level of renal arteries, corresponding approximately to the vertebral body of L2, to include the infra-diaphragmatic arteries. CT may be done without breath hold if patient dyspneic.

Another advantage of CT is it may indicate comfort of patient in supine position to plan angiography/embolization. If patient is not able to lie supine, angiography may have to be done with patient in other position. For example, oblique position.

Combined protocols (for pulmonary and systemic circulation):

It is possible to obtain opacification of both aortic and pulmonary systems in a single acquisition to allow simultaneous evaluation without additional exposure to multiple scans. This is achieved by using split bolus techniques for contrast administration or prolonged administration of contrast.

The benefit of opacification of pulmonary vessels is that in addition to detecting the pulmonary arterial causes of hemoptysis (like pseudoaneurysms), the dilated pulmonary arterial or venous branches (corresponding to areas of shunting) can also be well seen, aiding in the exact localization of bleeding.^{22,23} In case of an emergency or contraindication to contrast, noncontrast CT chest with high-resolution (HRCT) reconstruction can be done. Routine contrast-enhanced CT (CECT) chest should be avoided. The use of reconstructions allows easy differentiations between pulmonary arteries, veins, and systemic arteries.

Protocol for biphasic contrast injection (split-bolus) with added modifications²⁴:

Slice thickness for reconstruction:	≤ 1.5 mm
kVp:	Dual energy (80 kVp and 140 kVp) (if available)
mAs:	Automated tube current modulation
Rate of contrast injection (if available):	3/4th contrast at 5 mL/s 1/4th contrast at 3 mL/s Saline chase at 3 mL/s
ROI position:	Ascending aorta
Threshold HU:	100 HU
Time delay/phase of acquisition:	5 s after bolus trigger time
Reconstruction:	Axial image reconstruction at 1.5 mm slice thickness and increment of 1.2 mm at standard mediastinal and lung windows

The above imaging guidelines are desirable for cases with hemoptysis; however, if the equipment is unavailable then the best imaging protocol should be selected from what is available, aiming to achieve good opacification of the systemic as well pulmonary arteries.

4C. What are the different imaging findings that need to be looked for in cases with hemoptysis?

Imaging findings aid in localizing the site of the bleed, ascertaining causes, and identifying abnormal vessels.

Remarks:

CXR: CXR can help in localizing the side of bleeding and can help identify focal or diffuse lung involvement. However, the sensitivity of CXR is low.¹

Non-CECT/HRCT: Blood in the alveoli manifests as ground-glass opacity or consolidation which can be regarded as areas of parenchymal hemorrhage in patients presenting with hemoptysis. In subacute hemorrhage, septal lines may also be present as macrophages enter the area and migrate to lymphatic vessels in the interlobular septa to remove the blood products.

CT may detect blood products in large or small airways. Blood products in the bronchial tree may manifest as detectable filling defects. In larger airways, these filling defects show higher attenuation (> 40 HU), which allows them to be distinguished from mucus. Obstruction of larger airways with blood products may result in atelectasis.²⁴

Blood in distal airways manifests as centrilobular nodules with a tree-in-bud appearance.

A diffuse pattern of pulmonary parenchymal hemorrhage is suggestive of a systemic process, and patients with this pattern are typically poor candidates for targeted interventions.

In contrast, focal findings of parenchymal hemorrhage can be used to localize bleeding to a specific lesion or vascular territory. Both parenchymal and aspirated blood can be nodular, but findings of smaller well-defined clustered tree-in-bud centrilobular nodules favor aspiration from a

proximal source, whereas regional or diffuse centrilobular ground-glass opacities are more suggestive of parenchymal bleeding.¹ The severity of hemoptysis may not be proportional to the extent of abnormality detected on imaging. Underlying lesions in the lungs, like bronchiectasis, cavities, active infection, or malignancy, should be looked for.

CECT/CTA

Preprocedure evaluation with CTA not only helps in reducing the procedure time which is essential during the treatment of unstable patients but also reduces the contrast load and fluoroscopy radiation dose for patients and operators.¹ During the evaluation, the IR team should look for the possible cause of bleeding and localize the site of hemorrhage within the lung parenchyma at plain CT. Contrast images should be reviewed carefully which may reveal the following findings¹:

1. Hypertrophic tortuous BAs (diameter > 2.0 mm) or NBSAs/NBSCs. NBSAs including intercostal arteries, branches of internal mammary arteries, inferior phrenic arteries, other subclavian branches like costocervical and thoracodorsal arteries should also be looked for.
2. Neovascularization or peribronchial hypervascularity.
3. Contrast extravasation.
4. BA aneurysm/pseudoaneurysm.
5. Pleural thickening > 3 mm adjacent to a parenchymal abnormality with dilated non-BA
6. Pulmonary artery aneurysms (PAAs) and AVMs.
7. Systemic to pulmonary vasculature shunting (SPS), especially in multicentric parenchymal lung disease. These shunts can be from BAs or NBSAs/NBSCs to the pulmonary artery (more frequently) or vein. Imaging signs include:
 - (a) Nontapering pulmonary artery sign.
 - (b) Clustering of vessels sign.
 - (c) Significant differential attenuation sign (> 25 HU difference in attenuation between segmental pulmonary arteries of shunting side and normal nonshunting side).^{1,24}

DSA: It is now done only as part of endovascular treatment.

4D. What are the potential pulmonary arterial abnormalities that need to be looked for on CT in patients with hemoptysis?

The pulmonary arterial abnormalities that need to be evaluated include aneurysms and AVMs.^{25,26}

Remarks:

PAAs are rare and can be congenital or acquired. Pseudoaneurysms can occur in association with lung abscesses, septic emboli, bronchiectasis, lung neoplasms, after trauma from Swan-Ganz catheter placement, chronic cavitary TB (Rasmussen's aneurysm), and fungal infection (in immunosuppressed conditions like diabetes).^{27,28} Rasmussen aneurysm is a specific entity secondary to TB, which is less common than initially thought.²⁹⁻³¹ With the recent coronavirus disease 2019 (COVID-19) epidemic, fungal PAAs were reported.^{32,33} Other rare causes with underlying vas-

cular abnormalities are Marfan's syndrome, Ehlers-Danlos disease, and Behçet's disease.³⁴ The pulmonary AVMs may be isolated or syndromic like HHT.³⁵

5. Bronchoscopy

5A. What is the scope for using bronchoscopy in the management of hemoptysis?

Bronchoscopy can be used for lateralization of bleeding, clot extraction, direct instillation of medications and cold saline solution for hemorrhage, balloon tamponade, ablation of hemorrhagic arteries, and for selective intubation to maintain airway patency.^{2,9} (Level A).

For detailed information, kindly refer to relevant articles on bronchoscopy as the topic is beyond the scope of current recommendations.

Remarks: In unstable patients, where transfer is unsafe and intubation and lung isolation are of the utmost importance, flexible bronchoscopy (FB) is the procedure of choice and can be performed at the bedside.¹ FB can also be used to collect samples for cytology and microbiology. However, rigid bronchoscopy is more effective; provides quick evacuation of large obstructing blood clots and superior airway stabilization, but requires an operating room and general anaesthesia, and does not visualize the distal airways.²¹

5B. What is the best timing for bronchoscopic evaluation for hemoptysis?

The source of active bleeding is most likely to be located when bronchoscopy is performed during active hemoptysis (in 73–93% of cases) or within 24 to 48 hours of cessation.³⁶ (Level B-NR)

5C. What is the role of rigid bronchoscopy and flexible fiberoptic bronchoscopy (FFB) in the treatment of life-threatening hemoptysis?

Remarks:

FFB is frequently used due to its easier availability, ease of procedure, and no requirement of general anaesthesia. FFB is employed routinely with rigid bronchoscopy being reserved for specific situations. Rigid bronchoscopy is useful for securing airway patency and safeguarding ventilation, thereby preventing asphyxia. It also helps in better suction of blood clots and secretions through its large working channel and improved visualization of the airways. It also provides effective tamponade of accessible bleeding sites and allows isolation of the nonaffected lung. Also, bronchial blocking is easier to perform through the wider lumen of a rigid bronchoscope. In endoluminal lesions, central or peripheral, within the reach of the rigid scope, local coagulation therapy (laser, electrocautery, argon plasma coagulation) can also be done.³⁷

6. Overall Management Options

6A. What should be the initial management of hemoptysis?

The initial management of hemoptysis depends upon the severity of hemoptysis. For life-threatening hemoptysis,

management starts with airway management, hemodynamic stabilization, and then control of the source of bleeding. For non-life-threatening hemoptysis, management begins with the evaluation of etiology and its treatment.^{16,38,39} (Level B-NR)

Remarks:

Life-threatening hemoptysis is associated with high mortality rates as already described in question 1B. Hemoptysis management is multidisciplinary and involves pulmonologists, interventional radiologists, intensivists, and thoracic surgeons.

Airway management is the first step in preventing the aspiration of blood into the normal side of the airways and lungs. If the hemoptysis side is known, the involved side is to be placed in the dependent position. For persistent hemoptysis, various methods to isolate the diseased lung include selective bronchial intubation, bronchial blocker using balloon tamponade, and double-lumen endotracheal intubation.^{16,39,40}

The *hemodynamic stabilization* runs parallel to airway management and includes volume replacement and blood transfusion (including fresh frozen plasma or platelets). Stopping of any anticoagulant/antiplatelet drugs and reversal agents if available. Some studies suggest the use of intravenous tranexamic acids as well.³⁹

6B. What should be the definitive management of hemoptysis after initial stabilization?

Further management of hemoptysis depends upon the source of bleeding including vascular embolization, bronchoscopic management, and surgery.^{9,16,39,40} (Level A)

Remarks:

Vascular embolization

BAE is the mainstay of treatment for the vascular and parenchymal sources of bleeding. It consists of embolization of hypertrophied and abnormal BAs and/or NBSAs supplying the diseased airway or lung parenchyma. Pulmonary artery embolization is sometimes needed if the source of bleeding is pulmonary artery branches.

Bronchoscopic management

Bronchoscopic management of hemoptysis is useful if bleeding is from the airways as discussed in question 5.

Surgical management

Surgery is useful for young patients with localized disease involving a single lobe or less (like in a case of single aspergilloma or localized bronchiectasis) and provides the definitive treatment. BAE and bronchoscopy may be useful in these patients as bridge therapy if patients present with life-threatening hemoptysis. Preoperative embolization may be useful to reduce blood loss in cases of aspergilloma surgery.⁴⁰

Surgery is unlikely to be useful in diffuse disease, because of associated high morbidity and mortality, especially in case of emergency surgery. The mortality ranges from 20 to 40% if surgery is performed during active hemoptysis and 10 to 18% when performed electively.^{16,38,39} Postsurgery, morbidity ranges from 18 to 30%.^{16,38,39}

7. Interventional Radiology Management

7A. When should the bronchial artery embolization procedure be scheduled?

BAE is recommended in life-threatening/massive hemoptysis after initial stabilization of patients. (Level A)

It is recommended that even in patients with non-massive (non-life-threatening) hemoptysis, and CTA showing hypertrophied arteries, embolization should be performed early. This will result in a shortening of hospital stay and the subsequent recurrence rates as well. (Level A)

Remarks:

The need for an emergent embolization in life-threatening/massive hemoptysis is clear.

However, in cases of nonmassive hemoptysis, it is debatable whether embolization should be performed early (within 24 hours) or can be delayed and confined to cases that have a failure of medical therapy. Recent studies have demonstrated that early embolization is beneficial as it not only reduces the hospital stay but also lessens the likelihood of recurrence.^{9,41} The possible explanation for higher recurrence rates in patients with delayed embolization is that hemostatic agents used for conservative medical therapy induce clot formation in the bleeding small vessels or shunts. Hence, when an angiogram is performed subsequently, these arteries are likely to be missed. The clot formed being temporary (vs. embolization agent) recanalizes, resulting in earlier recurrence.

7B. Should BAE be performed in active infections?

It is recommended to perform BAE in life-threatening hemoptysis and/or when initial medical management fails to control hemoptysis. (Level C-LD)

Remarks:

Active TB is one of the most common causes of hemoptysis. Hemoptysis can also be encountered in bacterial/fungal infections.^{42,43} In active infections, the main source of bleeding is peripheral small vessels and abnormal BAs that are not significantly hypertrophied. In life-threatening/persistent hemoptysis even these normal-sized BAs leading to abnormal lung can be embolized.

7C. How is the BAE procedure performed?

BAE is an established, safe, and effective procedure for the control of hemoptysis.

A. What are the access routes?

The transfemoral route is recommended for access to BAs. Femoral access is secured by 5F/6F short sheath (11 cm), or a long sheath (45 cm) can be used in the case of tortuous iliac arteries and abdominal aorta. (Level B-NR)

Transradial access may be used in cases of difficult cannulation of NBSAs or ectopic arteries, arising from subclavian branches. (Level C-LD)

Remarks: Transfemoral access was used for access while performing BAE by most authors in the literature review.¹⁰

Few cases are described wherein axillary artery,⁴⁴ transbrachial artery,⁴³ and radial artery⁴⁵ are used. Radial access should be reserved for systemic collaterals and ectopic BAs arising from subclavian arteries and their branches with difficult access via the femoral route. In patients with tortuous or atherosclerotic iliac arteries and aorta, radial access is an acceptable route. *Brachial arterial access may be considered in cases of small caliber radial artery or failed access of radial artery.*

B. What Diagnostic angiograms should be performed and what catheters should be used?

Flush aortogram: Flush aortogram is reserved for cases in which the CTA is not done prior to the procedure (pregnancy, life-threatening bleed when patient is directly taken up for procedure).

Remarks: Preprocedure CTA is used for mapping the abnormal orthoptic/ectopic BAs and NBSAs and it obviates the need for performing the flush aortogram. For improved assessment of the hypertrophied vessels, an optimized CTA using the split bolus protocol described earlier can be performed.^{22,23}

Selective catheterization: After identification of abnormal BAs or nonsystemic bronchial collaterals, selective catheterization of these vessels is performed using a 4F/5F end-hole diagnostic catheter.

Choice of diagnostic catheters:

- 5Fr RDC/Shepherd's hook or Cobra catheter are routinely used to access BAs.
- 4/5Fr RC 1/Sim1 may also be used.
- 5Fr Picard/4Fr Vert catheters are used for accessing the NBSAs from subclavian arteries.

After careful control of the diagnostic catheter at the ostium of BA, selective angiogram is performed with hand injection (2–3 mL/s).^{17,46}

Superselective catheterization: A hydrophilic low-profile 2.7 to 2.9 Fr. Microcatheter (MC), with an internal diameter of 0.0165 to 0.027 inches is preferred for super selective catheterization. The MC should be advanced within the culprit artery beyond any nontarget branch but not too far to prevent occlusion at the tip. (Level B-NR)

Remarks:

Superselective catheterization enables bypassing of spinal arteries/radiculomedullary branches and catheterization of smaller, more distal, and torturous arteries; thereby providing better overall hemoptysis control and lesser risk of complications.^{17,43,47,48} In case of non-accessibility of shunt or pseudoaneurysm located distally due to tortuous anatomy by MC, proximal particle embolization may achieve occlusion of these shunts or pseudoaneurysm.

An absolute contraindication to embolization is a demonstration of abnormal communication with spinal arteries, coronary arteries, or vertebral arteries. For prevention of nontarget embolization to radiculomedullary branches, the catheter tip should be positioned beyond the pedicle and a large particle size > 700 μm should be used. Spinal arterial supply does not originate directly from the BA but can

originate from the intercostal portion of an intercostobronchial artery.⁴⁹

C. What is the choice of embolizing agents?

Polyvinyl alcohol (PVA) particles are the preferred agent for embolization. (Level B-NR)

Glue (n-butyl-2-cyanoacrylate [NBCA]) is less preferred; however, it is the choice of agent when encountering a large tortuous BA with rapid forward flow (e.g., in cases of bronchiectasis) or in case of recurrent bleed with recanalization. Gelfoam, microcoils, and Embospheres are other agents that can be used in selective cases. EVOH- based embolizing agents (Onyx) should be used in cases of refractory massive hemoptysis where conventional particle embolization has failed.⁵⁰

D. What is the technique for injecting PVA?

Under fluoroscopic guidance, gradual injection of the PVA particles mixed with iodinated water-soluble contrast should be performed using roadmap to ensure continuous forward flow and identify any early reflux. Careful injection of the embolizing material should be done in a pulsatile manner and flushing of the residual material using saline injections should be done. Stasis or reflux of injected particles indicates the endpoint for embolization. (Level C-EO)

7D. What polyvinyl alcohol particle size should be used? Is there any indication for Embospheres?

The appropriate size of PVA particle for BAE is 330 to 500 μm. Large-size particles > 700 μm are used when large pulmonary arterial or venous shunts are present. (Level B-NR)

Remarks: The most used particle size of PVA is 220 to 550 μm in size.^{10,46,51,52} Size less than 300 μm may cause nontarget embolization and occlude regular blood supply of the bronchi, esophagus, and vasa vasorum of the pulmonary artery or aorta with increased risk of excessive tissue ischemia and necrosis.⁵³ The presence of spinal cord feeders arising from the BA also seems to be less critical when using larger sized (700–900 μm) particles.^{52,54} However, large size particles may occlude the index artery more proximally and which could lead to recurrent hemoptysis from systemic collaterals.

Microsphere particles are more uniform in size and in penetration characteristics than PVA, and their smooth hydrophilic coated surface is less prone to clumping within catheters. Any calibrated microsphere particles (300–900 μm) can be used.^{10,55} The cost, however, is the limiting factor.

7E. Is there any role of gel foam even in low resource settings?

Small quantities of gelatin in the form of a pledget or thick slurry can be placed after particulate agents to complete the embolization, but its use as a sole agent is not recommended.^{56,57} (Level C-LD)

7F. Is there any role of glue?

Glue (NBCA) can be used when encountered with large tortuous BA with rapid forward flow (e.g., in cases of

bronchiectasis) or in case of recurrent bleeding with recanalization. (Level B-NR)

Remarks: In experienced hands, glue has shown a better hemoptysis control rate than PVA.^{47,56} Typically, 1:2 to 1:4 NBCA to lipiodol dilution should be used.⁴⁷ NBCA is not recommended for the treatment of hemoptysis until the operator has gained significant familiarity with its behavior as forward passage into the pulmonary tree is the real risk.

7G. Is there any role of coils as embolic agents?

Coil embolization is reserved in cases of BA pseudoaneurysms and for embolization of large systemic artery-to-pulmonary artery shunts. (Level C-LD)

Remarks: Coil embolization would prevent future BAE for recurrent hemoptysis due to proximal embolization and the development of challenging collateral vessels.^{58,59}

However, high-packing-density coil deployment, using hydrogel-polymer-coated or high thrombogenic coils may be still used in recurrent hemoptysis⁶⁰ to protect spinal supply⁶¹ and distal circulation, to occlude actively bleeding vessels as in pseudoaneurysms, or to occlude large bronchial-to-pulmonary shunts.^{17,43}

7H. In the case of multiple arteries, which arteries should be embolized?

We recommend all abnormal arteries should be embolized in descending order of severity until the maximum contrast limit is reached. (Level B-NR)

Remarks: The remaining arteries can be embolized in subsequent sessions. Assessment for prioritizing abnormal arteries can be done on size, identification of SPS, and side of bleed in cases of bilateral disease. It is safe to use 1.5 to 2 mL/kg contrast; may extend up to 3 mL/kg. The number of arteries to be embolized is limited by contrast dosage and fluoroscopy time. There is no evidence of a direct correlation between post-embolization syndrome and the number of arteries embolized. No single radiology society guideline could be found on the maximum volume of contrast that can be administered in a single examination or on a single day. However, a bodyweight-based upper dose limit is desirable which can be considered 3 mL/kg in adults and older children; and 1.5 to 2 mL/kg in neonates and infants.^{62,63}

7I. What should be the management in cases of pulmonary source of bleed?

The pulmonary source of bleed should be treated by embolization. (Level C-LD)

Remarks: The pulmonary artery accounts for 5% of cases of hemoptysis of which pulmonary artery pseudoaneurysm or arteriopathy accounts for the majority of cases. Mechanical embolizing agents (coils/plugs) are the commonly used material for the embolization of diseased pulmonary arteries. Pulmonary angiogram is performed when there is evidence of a possible source of bleeding on CTA. The indication for these can be demonstration of pseudoaneurysm/aneurysm on CTA, or in case of recurrent or uncontrolled hemoptysis.^{43,44}

7J. What are the recommendations in special situations such as:

- (1) Hemoptysis in patients with major aortopulmonary collaterals arteries (MAPCAs) with additional pulmonary pathology—TB, sequelae, and bronchiectasis?

Nonessential communicating MAPCAs supplying diseased segments can be embolized. (Level C-LD)

Remarks:

MAPCAs represent nonregressed systemic-to-pulmonary embryologic connections from the aorta or its branches to the pulmonary arterial vasculature. MAPCAs augment pulmonary flow in cardiac lesions with compromised antegrade pulmonary arterial blood flow, such as pulmonary atresia with ventricular septal defect, tetralogy of Fallot, and other cardiac diseases. Communicating MAPCAs (i. e., nonessential MAPCAs) terminate by forming an anastomosis with distal pulmonary arteries. Noncommunicating MAPCAs (i. e., essential MAPCAs) form the sole blood supply to the lung segment in the absence of a native pulmonary artery blood supply.⁶⁴ Communicating MAPCAs supplying abnormal lung segments/dilated bronchi can be embolized with due caution.

- (2) What should be the option in patients of hemoptysis with pulmonary artery narrowing?

Hypertrophied BAs can be cautiously embolized in cases of pulmonary artery narrowing in life-threatening hemoptysis. (Level C-LD)

Remarks: The main concern in such a situation is the development of pulmonary infarct. Hence, precise preprocedure evaluation for localizing the site of bleed and culprit artery by bronchoscopy and CTA is advised followed by superselective embolization of the culprit arterial branches.^{65,66} In the case of dual supply, it is safe to embolize, otherwise partial embolization can be done as a life-saving measure.

7K. What are the common complications?

Immediate procedure-related complications that may occur are subintimal dissection or perforation of the BA, or non-target embolization such as spinal cord infarction, myocardial infarction, bronchial infarction, and stroke. (Level B-NR)

Remarks:

Major complications of the BAE procedure reported in literature (in varying incidences) include spinal cord infarction (0.2–6.5%), myocardial infarction, bronchial infarction, esophagobronchial fistula, and stroke.^{10,67} Minor complications include post-embolization syndrome (pain, fever, leukocytosis [1.7–31%]), transient chest pain (in up to 91%), and dysphagia, both usually self-limiting, but symptoms may last for up to 2 weeks.¹

8. Outcomes and Follow-Up

8A What are the predictors of poor prognosis in patients with life-threatening hemoptysis?

Poor prognostic factors in patients are bilateral or diffuse pulmonary pathology, malignancy especially if advanced, need for mechanical ventilation, especially in single lung,

pulmonary artery as the source of hemorrhage, hypotension, aspergilloma, chronic alcohol intake, aspiration of blood into the opposite lung, and poor performance status.^{68,69} (Level B-NR)

Remarks:

Patients presenting with life-threatening hemoptysis have a poor prognosis with 7 to 30% of them succumbing to hemoptysis.^{68,69}

8B. How is the outcome of BAE measured?

The outcome of BAE is measured in terms of technical and clinical success. The immediate technical success varies from 81 to 100%. The immediate clinical success of embolization is in ranges from 70 to 99% whereas the recurrence rate of hemoptysis ranges from 9.8 to 57.5%.^{43,70,71} (Level B-NR)

Remarks:

Technical success is defined as success in cannulating and embolizing all abnormal BAs and NBSAs. The main reasons for technical failure include patient-related factors such as noncooperation or condition not permitting BAE, tortuous course, spasm dissection, ostial stenosis, and acute angulation of culprit artery.^{43,70,71}

Clinical success of BAE can be measured in terms of (1) immediate clinical success, (2) recurrence rates of hemoptysis, and (3) long-term hemoptysis control.

Complete remission or significant decrease in hemoptysis within 24 hours of BAE or within the same admission period is considered an immediate clinical success.¹⁰

Hemoptysis which recurs after discharge and requires either medical management, hospital admission, or repeat intervention is termed recurrence. Recurrences can be early if hemoptysis occurs within 2 weeks to 3 months post-embolization and late if occurring after 3 months. The recurrence rate tends to increase as time progresses. The median time for hemoptysis recurrence varies from 6 months to 1 year.¹⁰

8C. What are the factors associated with early and late recurrence after BAE and how is the recurrence of hemoptysis managed?

Factors associated with early and late recurrence are different. Early recurrences are usually related to incomplete embolization. Late recurrences may be caused by recanalization of arteries which were embolized earlier or due to the progression of underlying disease. Repeating BAE helps in hemoptysis control in both early and late recurrence.^{10,71-74} (Level B-NR)

Remarks: The technical factor associated with early recurrence is incomplete embolization as all culprit arteries were not searched for or embolized in the first session, including nonbronchial systemic vessels.

Higher late recurrence rates are seen in patients with aspergillomas, active TB, reactivation TB, and multidrug-resistant TB.^{5,48,73,74} Other risk factors include lung cancer, cystic fibrosis, idiopathic bronchiectasis, and diabetes mellitus.⁵ Patients with persistent or recurrent hemoptysis despite maximum medical management and multiple repeat embolization sessions will need surgery.^{10,70}

8D. What are the imaging features associated with the likelihood of recurrence?

Remarks:

Presence of cavitation, necrosis or aspergilloma on imaging, lung densities which involve two or more quadrants on chest radiograph, presence of bronchopulmonary shunts, and NBAs are imaging features associated with higher recurrence rates. No significant association between pleural thickening and recurrence is seen.^{10,68,69,71,73}

8E. How are the patients of hemoptysis followed up after BAE?

Patients are followed up in the intervention clinic after BAE. No data is available on the protocol of follow-up. (Level C-EO)

Remarks:

Typically, the first visit is planned after a week. Subsequent visits are at 1, 3, 6, and 12 months post-BAE and yearly thereafter. The need for imaging is determined by the underlying disease. If there is no recurrence of hemoptysis, a chest radiograph may suffice. Significant bleeding may require MDCTA.

8F. What are the factors affecting survival after BAE?

Early survival after BAE is affected by the completeness of initial BAE; however, primary determinant of long-term survival is the underlying disease process itself.⁶¹ (Level B-NR)

Remarks:

BAE with appropriate planning targeting the BAs and NBSAs is effective in controlling the life-threatening hemoptysis. In addition, the benign nature of the disease influences a long-term survival.

Algorithm

Algorithm is provided in ►Fig. 1.

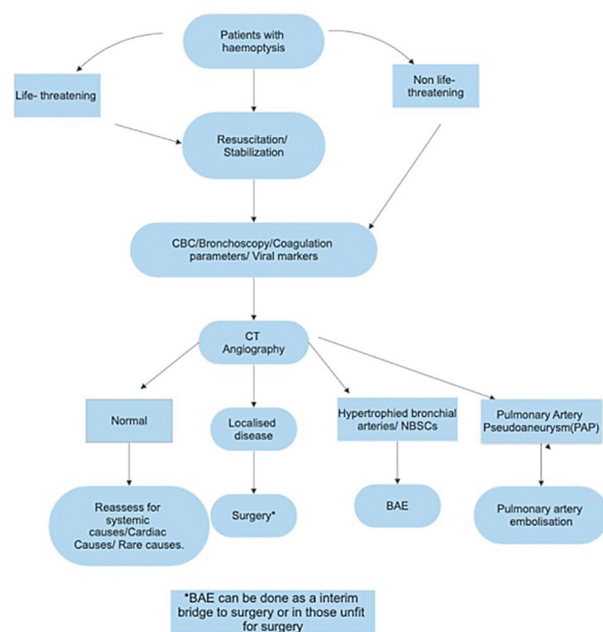


Fig. 1 Summary of the proposed workflow of hemoptysis patient presenting to the hospital.

Limitations

Among the patients who present with life-threatening hemoptysis, there is significant diversity in the causes, the pattern of involvement of BAs or other systemic collaterals, and the natural history of the disease. Hemoptysis is often episodic in nature. In addition, as a multipronged multidisciplinary treatment is undertaken, it is difficult to assess the outcome of BAE alone. What is perceived as successful BAE with cessation of hemoptysis could in fact be due to spontaneous improvement or be related to other measures undertaken.

An exact comparison of the outcomes between surgery and BAE is not possible, due to the differences in the case selection and principles of treatment. There is a lack of “ideal” double-blinded case–control comparison studies in this regard which may also not be feasible in the future.

Future Directives

Updates are needed in determining the major causes of hemoptysis and the emerging role of chronic invasive fungal infections needs to be addressed. Guidelines for treatment options in specific disease entities that cause hemoptysis are also a felt need. Although hemoptysis related to COVID infection sequel is presumed to be transient as the epidemic resolves, we need to be prepared in such situations as well.

Long-term follow-up of patients undergoing BAE and strategies to maximize both short- and long-term outcomes must be devised.

The role of artificial intelligence and machine learning in the imaging evaluation of patients with hemoptysis and in decision-making regarding treatment options is worth exploring.

Conclusion

Life-threatening hemoptysis as the name indicates can potentially have a grave prognosis due to airway obstruction and asphyxia or cardiovascular collapse, if not promptly treated. The causes of hemoptysis can be varied. BAs and NBSAs are more often the culprit vessels, rather than pulmonary arteries.

Hemoptysis management needs a multidisciplinary team, targeting airway management, hemodynamic stabilization, identifying the source of bleeding, and control of the bleeding.

CTA where both pulmonary and systemic arteries are together evaluated plays a vital role in assessing the cause of hemoptysis and planning IR treatment.

Emergency BAE, preferably with PVA particles has a clear-cut role in managing life-threatening hemoptysis, while its role in non-life-threatening hemoptysis is emerging.

There is a need to study the strategies to optimize both short- and long-term outcomes in patients undergoing BAE. Artificial intelligence and machine learning may also play a role in the future.

Funding

None.

Conflict of Interest

None declared.

Acknowledgment

We would like to acknowledge the sincere efforts for of Dr. Kirti Anna Koikkara in helping with framing of the manuscript.

References

- 1 CIRSE Standards of Practice on Bronchial Artery Embolisation | SpringerLink [Internet]. Accessed October 3, 2022 at: <https://link.springer.com/article/10.1007/s00270-022-03127-w>
- 2 Rémy J, Rémy-Jardin M, Voisin C. Endovascular management of bronchial bleeding. *Endovasc Manag Bronchial Bleeding*. 1992; 57:667–723
- 3 Olsen KM, Manouchehr-Pour S, Donnelly EF, et al. Expert Panel on Thoracic Imaging. ACR Appropriateness Criteria® Hemoptysis. *J Am Coll Radiol* 2020;17(5S):S148–59
- 4 Kaufman CS, Kwan SW. Bronchial artery embolization. *Semin Intervent Radiol* 2022;39(03):210–217
- 5 Radchenko C, Alraiyes AH, Shojaee S. A systematic approach to the management of massive hemoptysis. *J Thorac Dis* 2017;9 (Suppl 10):S1069–S1086
- 6 Magid DJ, Aziz K, Cheng A, et al. Part 2: evidence evaluation and guidelines development: 2020 American Heart Association Guidelines for Cardiopulmonary Resuscitation and Emergency Cardiovascular Care. *Circulation* 2020;142(16_Suppl_2, suppl_2): S358–S365
- 7 Cordovilla R, Bollo de Miguel E, Nuñez Ares A, Cosano Povedano FJ, Herráez Ortega I, Jiménez Merchán R. Diagnosis and treatment of hemoptysis [in Spanish]. *Arch Bronconeumol* 2016;52(07): 368–377
- 8 Etiology of hemoptysis in adults - UpToDate [Internet]. Accessed October 5, 2022 at: https://www.uptodate.com/contents/etiology-of-hemoptysis-in-adults?search=hemoptysis&source=search_result&selectedTitle=2~150&usage_type=default&display_rank=2#H11004209
- 9 Fartoukh M, Demoule A, Sanchez O, et al; ARTEMHYS trial group. Randomised trial of first-line bronchial artery embolisation for non-severe haemoptysis of mild abundance. *BMJ Open Respir Res* 2021;8(01):e000949
- 10 Panda A, Bhalla AS, Goyal A. Bronchial artery embolization in hemoptysis: a systematic review. *Diagn Interv Radiol* 2017;23 (04):307–317
- 11 Prasad R, Garg R, Singhal S, Srivastava P. Lessons from patients with hemoptysis attending a chest clinic in India. *Ann Thorac Med* 2009;4(01):10–12
- 12 Bhalla A, Pannu AK, Suri V. Etiology and outcome of moderate-to-massive hemoptysis: experience from a tertiary care center of North India. *Int J Mycobacteriol* 2017;6(03):307–310
- 13 Mondoni M, Carlucci P, Job S, et al. Observational, multicentre study on the epidemiology of haemoptysis. *Eur Respir J* 2018;51 (01):1701813
- 14 Hsiao EI, Kirsch CM, Kagawa FT, Wehner JH, Jensen WA, Baxter RB. Utility of fiberoptic bronchoscopy before bronchial artery embolization for massive hemoptysis. *Am J Roentgenol* 2001;177(04): 861–867
- 15 Revel MP, Fournier LS, Hennebicque AS, et al. Can CT replace bronchoscopy in the detection of the site and cause of bleeding in patients with large or massive hemoptysis? *Am J Roentgenol* 2002;179(05):1217–1224

- 16 Deshwal H, Sinha A, Mehta AC. Life-threatening hemoptysis. *Semin Respir Crit Care Med* 2021;42(01):145–159
- 17 Sidhu M, Wieseler K, Burdick TR, Shaw DWW. Bronchial artery embolization for hemoptysis. *Semin Intervent Radiol* 2008;25(03):310–318
- 18 Evaluation and management of life-threatening hemoptysis - UpToDate [Internet]. Accessed October 5, 2022 at: <https://www.uptodate.com/contents/evaluation-and-management-of-life-threatening-hemoptysis>
- 19 Jean-Baptiste E. Clinical assessment and management of massive hemoptysis. *Crit Care Med* 2000;28(05):1642–1647
- 20 Evaluation of hemoptysis - Differential diagnosis of symptoms | BMJ Best Practice US [Internet]. Accessed October 5, 2022 at: <https://bestpractice.bmj.com/topics/en-us/1039>
- 21 Larici AR, Franchi P, Occhipinti M, et al. Diagnosis and management of hemoptysis. *Diagn Interv Radiol* 2014;20(04):299–309
- 22 Imaging findings as predictors of the site of bleeding in patients with hemoptysis: Comparison between split-bolus dual-energy CT angiography and digital subtraction angiography [Internet]. Accessed October 6, 2022 at: <http://www.dirjournal.org/en/imaging-findings-as-predictors-of-the-site-of-bleeding-in-patients-with-hemoptysis-comparison-between-split-bolus-dual-energy-ct-angiography-and-digital-subtraction-angiography-132385>
- 23 Meena P, Bhalla AS, Goyal A, et al. Single-phase split-bolus dual energy computed tomography angiography for evaluation of hemoptysis: a novel application. *J Thorac Imaging* 2018;33(06):366–376
- 24 Marquis KM, Raptis CA, Rajput MZ, et al. CT for evaluation of hemoptysis. *Radiographics* 2021;41(03):742–761
- 25 Kandathil A, Chamrathy M. Pulmonary vascular anatomy & anatomical variants. *Cardiovasc Diagn Ther* 2018;8(03):201–207
- 26 Jerbi I souissi A Jemli, A Ben fatma, S Marouen, S. Pulmonary artery aneurysms and pseudo aneurysms: a rare but potentially fatal finding [Internet]. ECR 2022 EPOS. European Congress of Radiology - ECR 2022; 2022. Accessed October 8, 2022 at: <https://epos.myesr.org/poster/esr/ecr2022/C-14775>
- 27 Ferretti GR, Thony F, Link KM, et al. False aneurysm of the pulmonary artery induced by a Swan-Ganz catheter: clinical presentation and radiologic management. *AJR Am J Roentgenol* 1996;167(04):941–945
- 28 Shin S, Shin TB, Choi H, et al. Peripheral pulmonary arterial pseudoaneurysms: therapeutic implications of endovascular treatment and angiographic classifications. *Radiology* 2010;256(02):656–664
- 29 Chatterjee K, Colaco B, Colaco C, Hellman M, Meena N. Rasmussen's aneurysm: a forgotten scourge. *Respir Med Case Rep* 2015;16:74–76
- 30 Irodi A, Keshava SN. Rasmussen's aneurysm – undue importance to an uncommon entity? *Br J Radiol* 2009;82(980):698
- 31 Santelli ED, Katz DS, Goldschmidt AM, Thomas HA. Embolization of multiple Rasmussen aneurysms as a treatment of hemoptysis. *Radiology* 1994;193(02):396–398
- 32 Pruthi H, Muthu V, Bhujade H, et al. Pulmonary artery pseudoaneurysm in COVID-19-associated pulmonary mucormycosis: case series and systematic review of the literature. *Mycopathologia* 2022;187(01):31–37
- 33 Santhosh Babu KBM, Kumar Muthukumar M, Vinu Moses M, et al. Role of endovascular interventions in the management of COVID-19 patients presenting with massive hemorrhage: a single-center experience. *Vasc Dis Manag* 2022;19(08):3–5
- 34 Erkan F, Gül A, Tasali E. Pulmonary manifestations of Behçet's disease. *Thorax* 2001;56(07):572–578
- 35 Martinez-Pitre PJ, Khan YS. Pulmonary Arteriovenous Malformation (AVMs). In: *StatPearls* [Internet]. Treasure Island, FL: StatPearls Publishing; 2022
- 36 Mondoni M, Carlucci P, Cipolla G, et al. Bronchoscopy to assess patients with hemoptysis: which is the optimal timing? *BMC Pulm Med* 2019;19(01):36
- 37 Mehta AK, Chamyal PC. Haemoptysis - indications for bronchoscopy. *Med J Armed Forces India* 1994;50(02):123–125
- 38 Kathuria H, Hollingsworth HM, Vilvendhan R, Reardon C. Management of life-threatening hemoptysis. *J Intensive Care* 2020;8(01):23
- 39 Parrot A, Tavolaro S, Voiriot G, et al. Management of severe hemoptysis. *Expert Rev Respir Med* 2018;12(10):817–829
- 40 Goyal A, Khan IA, Kumar A, et al. Chest-wall collateral embolization to reduce surgical blood loss in peripheral aspergillomas. *Thorac Cardiovasc Surg* 2022;70(07):589–595
- 41 Park SJ, Lee S, Lee HN, Cho Y. Early versus delayed bronchial artery embolization for non-massive hemoptysis. *Eur Radiol* 2023;33(01):116–124
- 42 Shera TA, Bhalla AS, Naranje P, et al. Role of computed tomography angiography in the evaluation of haemoptysis in children: decoding the abnormal vessels. *Indian J Med Res* 2022;155(3&4):356–363
- 43 Bhalla A, Kandasamy D, Veedu P, Mohan A, Gamanagatti S. A retrospective analysis of 334 cases of hemoptysis treated by bronchial artery embolization. *Oman Med J* 2015;30(02):119–128
- 44 Agmy GM, Wafy SM, Mohamed SAA, Gad YA, Mustafa H, Abd El-Aziz AES. Bronchial and nonbronchial systemic artery embolization in management of hemoptysis: experience with 348 patients. *Int Sch Res Notices* 2013;26:e263259
- 45 Lee Y, Lee M, Hur S, et al. Bronchial and non-bronchial systemic artery embolization with transradial access in patients with hemoptysis. *Diagn Interv Radiol* 2022;28(04):359–363
- 46 Almeida J, Leal C, Figueiredo L. Evaluation of the bronchial arteries: normal findings, hypertrophy and embolization in patients with hemoptysis. *Insights Imaging* 2020;11(01):70
- 47 Woo S, Yoon CJ, Chung JW, et al. Bronchial artery embolization to control hemoptysis: comparison of N-butyl-2-cyanoacrylate and polyvinyl alcohol particles. *Radiology* 2013;269(02):594–602
- 48 Shin BS, Jeon GS, Lee SA, Park MH. Bronchial artery embolisation for the management of haemoptysis in patients with pulmonary tuberculosis. *Int J Tuberc Lung Dis* 2011;15(08):1093–1098
- 49 Befera NT, Ronald J, Kim CY, Smith TP. Spinal arterial blood supply does not arise from the bronchial arteries: a detailed analysis of angiographic studies performed for hemoptysis. *J Vasc Interv Radiol* 2019;30(11):1736–1742
- 50 Mattay RR, Shlansky-Goldberg R, Pukenas BA. Recurrent massive hemoptysis in a patient with cystic fibrosis: balloon assisted Onyx embolization after bronchial artery coil recanalization. *CVIR Endovasc* 2021;4(01):4
- 51 Hahn S, Kim YJ, Kwon W, Cha SW, Lee WY. Comparison of the effectiveness of embolic agents for bronchial artery embolization: gelfoam versus polyvinyl alcohol. *Korean J Radiol* 2010;11(05):542–546
- 52 Kucukay F, Topcuoglu OM, Alpar A, Altay ÇM, Kucukay MB, Ozbulbul NI. Bronchial Artery embolization with large sized (700-900. µm) Tris-acryl microspheres (Embosphere) for massive hemoptysis: long-term results (clinical research). *Cardiovasc Intervent Radiol* 2018;41(02):225–230
- 53 van den Berg JC. Bronchial artery embolization. In: *Vascular Embolotherapy*. Berlin: Springer; 2006:263–277
- 54 Khalil A, Fedida B, Parrot A, Haddad S, Fartoukh M, Carette MF. Severe hemoptysis: from diagnosis to embolization. *Diagn Interv Imaging* 2015;96(7-8):775–788
- 55 Corr PD. Bronchial artery embolization for life-threatening hemoptysis using tris-acryl microspheres: short-term result. *Cardiovasc Intervent Radiol* 2005;28(04):439–441
- 56 Monroe EJ, Pierce DB, Ingraham CR, Johnson GE, Shivaram GM, Valji K. An interventionalist's guide to hemoptysis in cystic fibrosis. *Radiographics* 2018;38(02):624–641
- 57 Yoon W, Kim JK, Kim YH, Chung TW, Kang HK. Bronchial and nonbronchial systemic artery embolization for life-threatening hemoptysis: a comprehensive review. *Radiographics* 2002;22(06):1395–1409

- 58 McPherson S. Bronchial artery embolization. In: Kessel D, Ray C, eds. *Transcatheter Embolization and Therapy* [Internet]. London: Springer; 2009:349–361
- 59 Ishikawa H, Hara M, Ryuge M, et al. Efficacy and safety of super selective bronchial artery coil embolisation for haemoptysis: a single-centre retrospective observational study. *BMJ Open* 2017; 7(02):e014805
- 60 Ryuge M, Hara M, Hiroe T, et al. Mechanisms of recurrent haemoptysis after super-selective bronchial artery coil embolisation: a single-centre retrospective observational study. *Eur Radiol* 2019;29(02):707–715
- 61 Frood R, Karthik S, Mirsadraee S, Clifton I, Flood K, McPherson SJ. Bronchial artery embolisation for massive haemoptysis: immediate and long-term outcomes—a retrospective study. *Pulm Ther* 2020;6(01):107–117
- 62 ACR Manual on Contrast Media. Version 10.1. Reston, VA: American College of Radiology; 2015
- 63 Aoun J, Nicolas D, Brown JR, Jaber BL. Maximum allowable contrast dose and prevention of acute kidney injury following cardiovascular procedures. *Curr Opin Nephrol Hypertens* 2018;27(02):121–129
- 64 Alex A, Ayyappan A, Valakkada J, Kramadhari H, Sasikumar D, Menon S. Major aortopulmonary collateral arteries. *Radiol Cardiothorac Imaging* 2022;4(01):e210157
- 65 Kang MK, Kang DK, Hwang YH. Isolated unilateral pulmonary artery agenesis presenting with massive hemoptysis. *Respirol Case Rep* 2019;8(02):e00511
- 66 Bhalla AS, Gupta P, Mukund A, Kabra SK, Kumar A. Pulmonary artery narrowing: a less known cause for massive hemoptysis. *Oman Med J* 2013;28(02):e044
- 67 Stroke and myocardial infarction following bronchial artery embolization in a cystic fibrosis patient - PubMed [Internet]. Accessed October 8, 2022 at: <https://pubmed.ncbi.nlm.nih.gov/27939048/>
- 68 Fartoukh M, Khoshnood B, Parrot A, et al. Early prediction of in-hospital mortality of patients with hemoptysis: an approach to defining severe hemoptysis. *Respiration* 2012;83(02):106–114
- 69 Ong TH, Eng P. Massive hemoptysis requiring intensive care. *Intensive Care Med* 2003;29(02):317–320
- 70 Ramakantan R, Bandekar VG, Gandhi MS, Aulakh BG, Deshmukh HL. Massive hemoptysis due to pulmonary tuberculosis: control with bronchial artery embolization. *Radiology* 1996;200(03):691–694
- 71 Chan VL, So LKY, Lam JYM, et al. Major haemoptysis in Hong Kong: aetiologies, angiographic findings and outcomes of bronchial artery embolisation. *Int J Tuberc Lung Dis* 2009;13(09):1167–1173
- 72 Anuradha C, Shyamkumar NK, Vinu M, Babu NRSS, Christopher DJ. Outcomes of bronchial artery embolization for life-threatening hemoptysis due to tuberculosis and post-tuberculosis sequelae. *Diagn Interv Radiol* 2012;18(01):96–101
- 73 Hwang HG, Lee HS, Choi JS, Seo KH, Kim YH, Na JO. Risk factors influencing rebleeding after bronchial artery embolization on the management of hemoptysis associated with pulmonary tuberculosis. *Tuberc Respir Dis (Seoul)* 2013;74(03):111–119
- 74 van den Heuvel MM, Els Z, Koegelenberg CF, Naidu KM, Bolliger CT, Diacon AH. Risk factors for recurrence of haemoptysis following bronchial artery embolisation for life-threatening haemoptysis. *Int J Tuberc Lung Dis* 2007;11(08):909–914