

Advanced MR imaging features of uncontrolled phenylketonuria in an adult patient

Recursos avançados de imagem de RM de fenilcetonúria descontrolada em um paciente adulto

Alper Ayasli¹  Hayri Ogul²  Omer Onbas² 

¹ Duzce University, Medical Faculty, Department of Neurology, Duzce, Turkey.

² Duzce University, Medical Faculty, Department of Radiology, Duzce, Turkey.

Address for correspondence Hayri Ogul (email: drhogul@gmail.com).

Arq. Neuropsiquiatr. 2023;81(1):99–100.

A 29-year-old male was brought to the neurology department with a complaint of vomiting for one month. He had known mental retardation, epilepsy, and chronic hypocalcemia. His relatives said that the patient was diagnosed with

phenylketonuria in childhood. As a result of further radiological examination, cranial MR images were compatible with phenylketonuria (→Figure 1A-F). Although our case is very rare, it is worth reminding that phenylketonuria can be

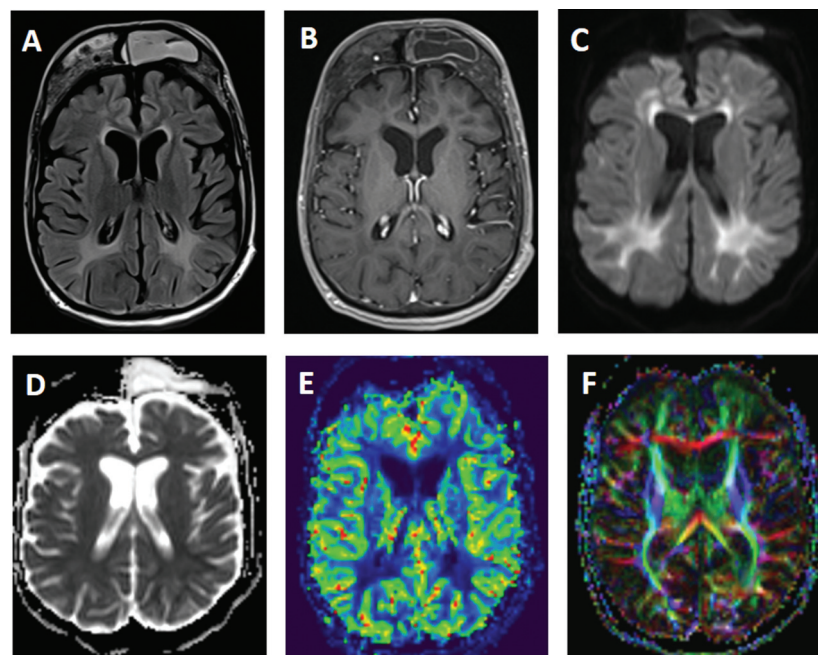


Figure 1 Axial fluid attenuation inversion recovery (A) MR image shows extensively increased periventricular white matter signal abnormalities in both cerebral hemispheres. No contrast-enhancing lesion is observed in post-contrast T1-weighted (B) MR imaging. Axial fluid attenuation inversion recovery and post-contrast T1-weighted MR images also demonstrate a prominent hyperostosis of the frontal bone. Diffusion weight imaging (C) shows bright signals in the periventricular white matter representing restricted diffusion with slightly hypointense ADC map (D). rCBF perfusion (E) MR reveals slightly hypoperfused white matter areas. Diffusion tensor imaging (F) shows thinning white matter fibers.

received
August 1, 2022
received in its final form
September 12, 2022
accepted after revision
October 2, 2022

DOI <https://doi.org/10.1055/s-0043-1761293>.
ISSN 0004-282X.

© 2023. Academia Brasileira de Neurologia. All rights reserved. This is an open access article published by Thieme under the terms of the Creative Commons Attribution 4.0 International License, permitting copying and reproduction so long as the original work is given appropriate credit (<https://creativecommons.org/licenses/by/4.0/>).
Thieme Revinter Publicações Ltda., Rua do Matoso 170, Rio de Janeiro, RJ, CEP 20270-135, Brazil

diagnosed in adulthood¹ and to emphasize that phenylketonuria is also present in the differential diagnosis of leukoencephalopathy.

Authors' Contributions

HO: wrote the initial draft of the manuscript; AA: contributed to interpretation of the data and assisted in the preparation of the manuscript. All authors read and approved the final version of the manuscript and agree to be accountable for all aspects of the work in ensuring that questions related to the accuracy or integrity of any

part of the work will be appropriately investigated and resolved.

Conflict of Interest

There is no conflict of interest to declare.

References

- 1 Chen S, Zhu M, Hao Y, Feng J, Zhang Y. Effect of delayed diagnosis of phenylketonuria with imaging findings of bilateral diffuse symmetric white matter lesions: A case report and literature review. *Front Neurol* 2019;10(04):1040