




# Tissue Damage Caused by Diclofenac Intramuscular Injection: The Nicolau Syndrome

Afzal Anees<sup>1</sup> Yaqoob Hassan<sup>1</sup>  Zainab Yusufali Motiwala<sup>1</sup> Isna Rafat Khan<sup>1</sup>

<sup>1</sup>Department of Surgery, Jawaharlal Nehru Medical College, Aligarh Muslim University, Aligarh, India

Address for correspondence Yaqoob Hassan, MBBS, MS, Department of Surgery, Jawaharlal Nehru Medical College, Aligarh Muslim University, Aligarh 202002, India (e-mail: dryaqoobwani@gmail.com).

Ibносина J Med Biomed Sci 2023;15:99–101.

## Abstract

**Introduction** Nicolau syndrome is an extremely rare complication following intramuscular administration of drugs leading to tissue damage and necrosis.

**Case Report** In this case, the patient received the injection from an untrained quack surgeon (*Jarrah*) due to an improper intramuscular injection technique. A 45-year-old female complained of pain and blackish discoloration of the skin over the left buttock after receiving an intramuscular diclofenac injection.<sup>4</sup> The patient was managed by administering intravenous antibiotics and analgesics, followed by surgical debridement. Flap reconstruction was done after granulation tissue formation.

**Conclusion** Healthcare should be sought from appropriately trained and licensed professionals. Patients should be well educated on this. Pain, erythema, and discoloration should be recognized as red flags of the Nicolau syndrome so that it can be addressed promptly to avoid complications.

## Keywords

- ▶ injection
- ▶ diclofenac
- ▶ Nicolau syndrome
- ▶ intramuscular

## Introduction

Nicolau syndrome is an extremely rare complication following intramuscular administration of drugs leading to tissue damage and necrosis. Initially, it was believed to occur because of bismuth salt injection. However, other drugs have now been reported as a cause of ulceration and scarring of the skin, subcutaneous fat, and muscle. Late complications include contracture and deformity of limb.<sup>1</sup> Multiple theories suggest the syndrome's pathogenesis, ranging from inflammation caused by perivascular injection to embolism due to intra-arterial injection leading to occlusion.<sup>2</sup> It could also be caused by arterial perforation leading to thrombosis or secondary sympathetic vasospasm, resulting in ischemic necrosis.

This case is novel as this is an unusual presentation, and the patient received the injection from an untrained quack surgeon (*Jarrah*) due to an improper intramuscular injection

technique. Such a case could have been prevented if the medical and paramedical staff had been given the right training and patients had been educated about receiving healthcare from trained personnel.

## Case Report

A 45-year-old female presented to Jawaharlal Nehru Medical College with complaints of pain and blackish skin discoloration over the left buttock for 5 days. The patient experienced pain 10 days back in the right iliac fossa, for which he received a diclofenac injection in the gluteal region by a *Jarrah*. The pain was insidious in onset and progressive in nature, severe in intensity, dull aching in character, and nonradiating pain. On examination, a 10 × 15 cm necrotic tender patch with well-defined margins and yellowish purulent discharge was seen, as shown in ▶ **Fig. 1**. The patch was

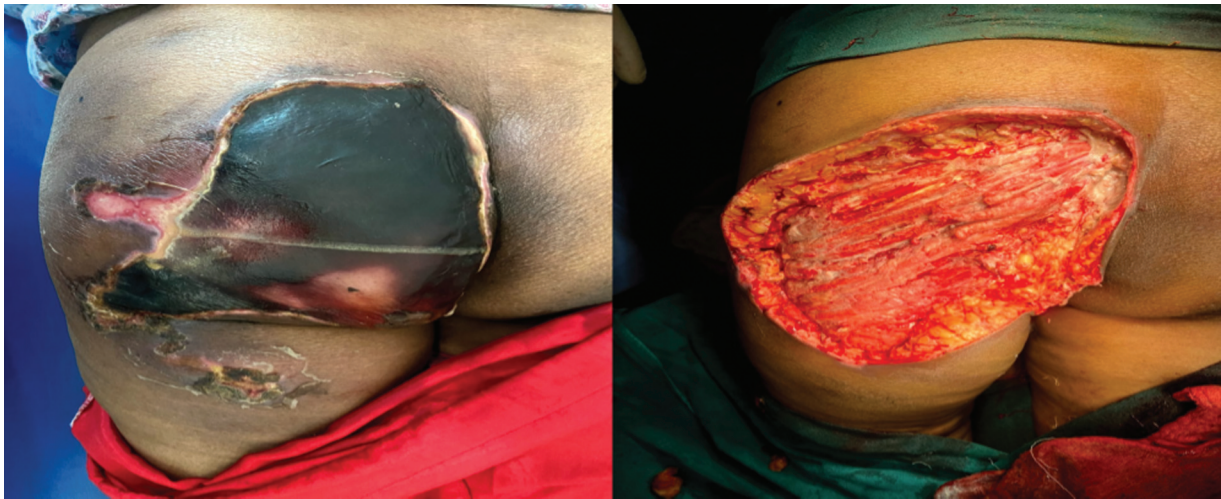article published online  
February 23, 2023

DOI <https://doi.org/10.1055/s-0043-1761214>.  
ISSN 1947-489X.

© 2023. The Libyan Biotechnology Research Center. All rights reserved.

This is an open access article published by Thieme under the terms of the Creative Commons Attribution-NonDerivative-NonCommercial-License, permitting copying and reproduction so long as the original work is given appropriate credit. Contents may not be used for commercial purposes, or adapted, remixed, transformed or built upon. (<https://creativecommons.org/licenses/by-nc-nd/4.0/>)

Thieme Medical and Scientific Publishers Pvt. Ltd., A-12, 2nd Floor, Sector 2, Noida-201301 UP, India



**Fig. 1** A necrotic patch seen in the left gluteal region after intramuscular injection followed by debridement.

seen in the right gluteal region, extending to the posterior mid-thigh region.

The neurovascular bundle of the lower limb was intact. There was no generalized and regional lymphadenopathy. There was no history of trauma, another drug intake, or systemic illness.

On investigation, a complete blood count revealed leukocytosis with a white blood cell count of 13,000/dL and microcytic hypochromic anemia with a hemoglobin count of 7.8 g/dL. Remaining tests like biochemical, serological, chest-X-ray, kidney, and liver function tests were unremarkable. The discharge revealed the growth of *Escherichia coli* on a culture that was sensitive to piperacillin.

The administration of intravenous antibiotics like piperacillin, tazobactam, and metronidazole managed the patient. Intravenous analgesics were also administered, followed by surgical debridement of necrotic and gangrenous tissue. Post-debridement, the patient was managed initially conservatively till granulation formation followed by flap reconstruction from the posterior thigh.

## Discussion

Nicolau syndrome is an unusual complication due to intramuscular injection that leads to tissue damage and necrosis of skin, subcutaneous tissue, muscle, and fat. This syndrome is extremely rare, which is why only approximately 85 papers have been published to the best of our knowledge on extensive literature review.

Pathogenesis of Nicolau syndrome due to nonsteroidal anti-inflammatory drugs is the decreased prostaglandin production due to cyclooxygenase inhibition that has induced necrosis. Although the syndrome's pathogenesis is not completely understood, lipophilic drugs are reported to cause fat embolism, while cytotoxic drugs cause inflammation and ischemia.<sup>3</sup> The sequelae of periarticular injections are understood as ischemia, while intra-arterial is occlusion and embolism. In our case, diclofenac has most probably led to ischemic necrosis due to the inhibition of prostaglandin production and the cyclooxygenase pathway. Kim et al suggested that the clinical

features should be divided into three stages. The first stage is characterized by pain and erythema, followed by the second phase with a tender indurated plaque with a livedo reticular pattern, and the third phase of necrosis and ulceration.<sup>4</sup> Another study reported that post-injection in the buttock, there was pain, discoloration of the limb and abdomen, paralysis of the lower limb, decreased urinary output, and altered sensorium.<sup>5</sup> Nischal et al reported that the patient experienced dull aching pain and cyanotic patches on the skin post-injection.<sup>6</sup> In our case, the patient complained of redness and pain in the left gluteal region.

Lie et al reported that the discharge from the wound yielded *Pseudomonas aeruginosa*, while in our case the culture revealed the growth of *Escherichia coli*.<sup>2</sup> Studies show that color Doppler done in such cases is usually normal.<sup>7</sup> When a histopathological examination is done, it reveals perivascular lymphocytic infiltration with fibrin clots in the vessel's lumen and focal collagen degeneration.<sup>5</sup>

There has been a variable management plan for such patients ranging from conservative to surgical debridement. Conservative management has been effective if the patient presents early with no complications, including using a cold compress, analgesics, and antibiotics. The case described by Nischal et al was managed by debridement and reconstruction with a flap from the anterior thigh.<sup>8</sup> Our patient presented with necrosis and gangrene, for which intravenous antibiotics, analgesics, and surgical debridement with reconstruction were the mainstay of treatment.

Necrosis and ulceration are the main early complications, followed by deformities and contractures being the late ones. In our case, this syndrome primarily developed due to the administration of the drug by a *Jarrah* who is not trained for the same. This unforeseen complication is preventable if the right technique for intramuscular injection is used. These include the Z-track technique, aspiration of a syringe to check if the needle is not in an artery, change of site of injection in case of regular administration, and giving small doses in a single shot.<sup>9</sup> Healthcare providers must be trained to administer intramuscular injections in the muscular plane.

## Conclusion

Patients must be educated regarding the importance of receiving healthcare from trained personnel. Patients must be informed regarding the red flags of the syndrome, like pain, erythema, and discoloration, at the time of drug administration so that it can be managed as early as possible and the development of complications can be prevented.

### Authors' Contribution

Authors contributed to preparation of the case report and approved its finally revised version.

### Patient's Consent

The authors confirm that an informed consent was provided by the patient. All efforts were made for totally anonymous reporting.

### Compliance with Ethical Principles

No prior ethical approval is required for single cases reports. Informed consent has been taken from the patient and can be sent to the editor.

### Funding and Sponsorship

None.

### Conflict of Interest

None declared.

## References

- 1 Corazza M, Capozzi O, Virgili A. Five cases of livedo-like dermatitis (Nicolau's syndrome) due to bismuth salts and various other non-steroidal anti-inflammatory drugs. *J Eur Acad Dermatol Venereol* 2001;15(06):585–588
- 2 Lie C, Leung F, Chow SP. Nicolau syndrome following intramuscular diclofenac administration: a case report. *J Orthop Surg (Hong Kong)* 2006;14(01):104–107
- 3 Ezzedine K, Vadoud-Seyedi J, Heenen M. Nicolau syndrome following diclofenac administration. *Br J Dermatol* 2004;150(02):385–387
- 4 Kim KK, Chae DS. Nicolau syndrome: A literature review. *World J Dermatol* 2015;4(02):103
- 5 De Sousa R, Dang A, Rataboli PV. Nicolau syndrome following intramuscular benzathine penicillin. *J Postgrad Med* 2008;54(04):332–334
- 6 Nischal K, Basavaraj H, Swaroop M, Agrawal D, Sathyanarayana B, Umashankar N. Nicolau syndrome: an iatrogenic cutaneous necrosis. *J Cutan Aesthet Surg* 2009;2(02):92–95
- 7 Senel E. Nicolau syndrome as an avoidable complication. *J Family Community Med* 2012;19(01):52–53
- 8 Desai K, Warade AC, Jha AK, Pattankar S. Injection-related iatrogenic peripheral nerve injuries: surgical experience of 354 operated cases. *Neurol India* 2019;67(Supplement):S82–S91
- 9 Pullen, Richard LJR. RN, EDD. Administering medication by the Z-track method. *Nursing* 2005;35(07):24