



Cable Ties: Poor Man's Top Closure System

Aditya Narayan Choudhary¹ Sanjeev Kumar¹

¹Plastic Surgery, Heritage Institute of Medical Sciences, Varanasi, Uttar Pradesh, India

Address for correspondence Aditya Narayan Choudhary, MCh, Plastic Surgery, Heritage Institute of Medical Sciences, Varanasi 221311, Uttar Pradesh, India (e-mail: drsanjeev23@yahoo.com).

Indian J Plast Surg 2023;56:182–184.

Abstract

Scalp electrical burns unsuitable for primary closure after debridement have traditionally been treated by modalities that cause significant morbidity and are aesthetically inferior to tension-free primary wound closure. Due to advances in research on the biomechanical properties of skin, various devices for skin stretching and safe wound closure have been reported in the literature that are expensive and inaccessible to poor people in the developing countries. We present our experience using cable ties as an effective, easy to use, readily available, and inexpensive top closure system.

Keywords

- ▶ electric burn
- ▶ top closure
- ▶ cable ties

Introduction

Electric burn wounds of scalp not amenable to primary closure following debridement have traditionally been managed by skin grafts, local flaps, tissue expansion, free flaps, and closure by secondary intention, but the traditional methods have following limitations:

1. Cause considerable morbidity
2. Carry risks associated with lengthy healing time
3. Are costly to the patient and
4. Aesthetically inferior in comparison to tensionless primary wound closure.

Due to advances in research into the biomechanical characteristics of skin, various devices for skin stretching and secure wound closure have been reported in literature including Hirschowitz device,¹ Wisebands,² the TopClosure 3S system,³ the EASApproxi device,⁴ the shoelace technique,⁵ and the DermaClose system.⁶ Except for the shoelace technique, the devices mentioned are expensive and beyond reach of a poor person in a developing country.

We hereby present our experience with use of cable ties as a top closure system that is effective, easily applicable, readily available, and inexpensive.

Case Presentation

A 27-year-old male presented to us with alleged history of high-tension electric burn to the scalp. He gave history of loss of consciousness. There was no history of ENT bleeding, seizures, or vomiting. He was taken to a local setup where he and the wound were managed conservatively for 20 days before referring to us. On examination, the patient was conscious and oriented with stable vitals. There was a 10 × 7 cm irregular wound over the frontal region of scalp (▶ Fig. 1). The bone was exposed and purulent discharge was noted. The exit wound was noted in the right sole and was healing well.

Pus was sent for culture and sensitivity for initiation of appropriate antibiotics. Flap coverage for the scalp wound was advised but was denied by the patient due to financial reasons. Taking inspiration from use of Ty-Raps in closure of fasciotomy wounds by Govaert and van Helden,⁷ a similar modality of treatment was proposed to the patient. After taking valid, informed, and written consent, preparations were made. Cable ties were procured and sterilized using ethylene oxide. Cable tie units were prepared consisting of two cable ties, one of which was secured to the wound margins using nylon 3-0 suture and the other tie was passed

article published online
April 10, 2023

DOI <https://doi.org/10.1055/s-0043-1761179>.
ISSN 0970-0358.

© 2023. Association of Plastic Surgeons of India. All rights reserved. This is an open access article published by Thieme under the terms of the Creative Commons Attribution-NonDerivative-NonCommercial-License, permitting copying and reproduction so long as the original work is given appropriate credit. Contents may not be used for commercial purposes, or adapted, remixed, transformed or built upon. (<https://creativecommons.org/licenses/by-nc-nd/4.0/>)
Thieme Medical and Scientific Publishers Pvt. Ltd., A-12, 2nd Floor, Sector 2, Noida-201301 UP, India

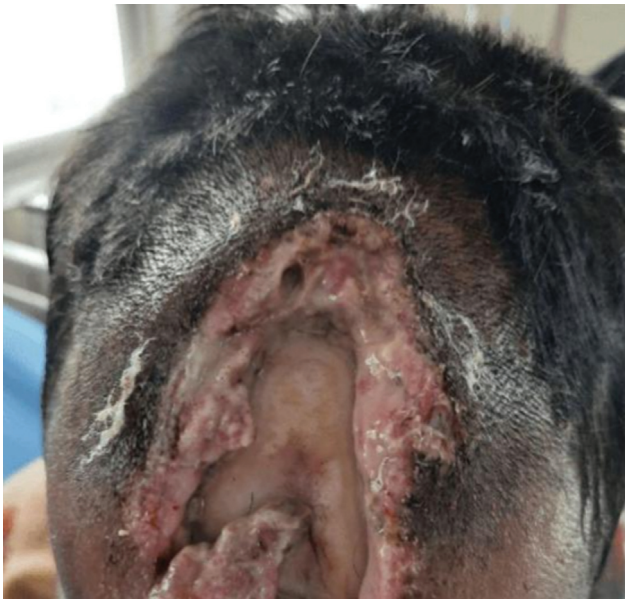

Fig. 1 Wound at presentation.

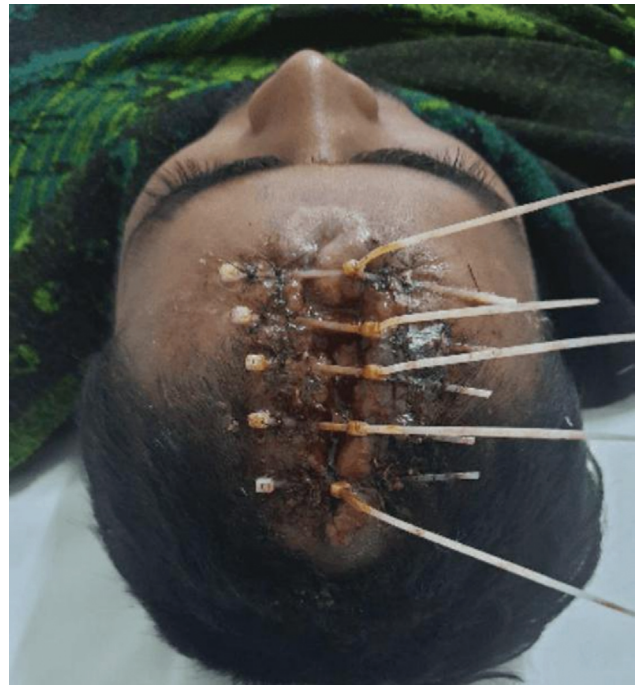

Fig. 4 Wound edge approximation.

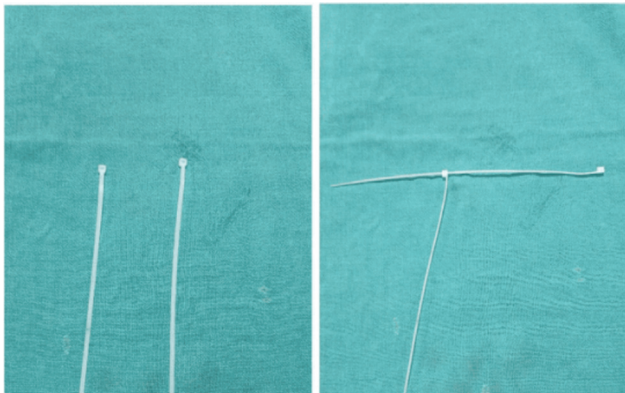


Fig. 2 Cable tie system.

from the pointing end of the first tie in such a manner that it could move only in a single direction over the integrated gear rack, leading to wound closure (► **Fig. 2**).

After wound debridement, multiple such units were fixed 2 cm from the wound margins at an interval of 2 cm from each other (► **Fig. 3**). The units were tightened daily till wound edge approximation was achieved in a week (► **Figs. 4 and 5**). The units were left in place for another week and were then removed after noting wound healing.

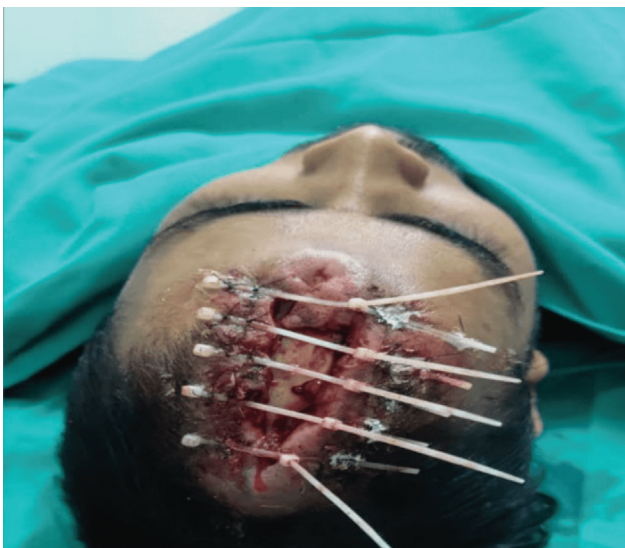

Fig. 3 Cable tie fixation to wound margins.

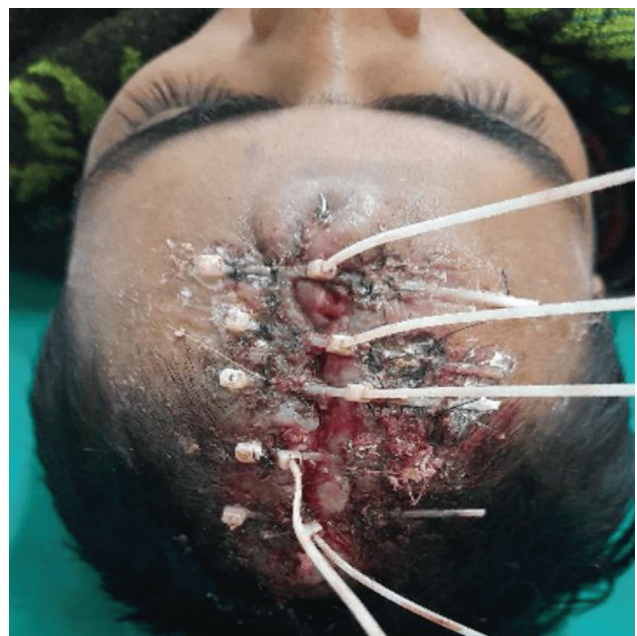

Fig. 5 Wound edge apposition.



Fig. 6 Follow-up at 2 months.

Two months following the procedure, patient presented with adequate wound healing with an acceptable scar and noticeable hair growth (→ **Fig. 6**).

Discussion

Cable ties are basically nylon tapes with an integrated gear rack and a small case with a ratchet at one end. Once the other end of the tie has been pulled through the case past the ratchet, it can only be pulled tighter due to the gear rack. Therapeutic use of Ty-Raps has been reported as early as 1976⁸ and has since been used for the internal fixation of (periprosthetic) femur fractures⁹ and even anal fistula.¹⁰

Like other top closure devices, it makes use of creep and stress relaxation for enabling wound closure. The advantages of using cable ties are as follows:

1. Easy availability
2. Low cost (Rs 130 for a bundle of 100)
3. No ischemia, necrosis, or donor site morbidity

4. Avoidance of alopecia, thus more aesthetic
5. Allows gradual wound closure allowing simultaneous management of infection and regular wound toileting.

Thus, cable ties may be considered as a viable alternative to available skin expansion systems in resource-poor settings.

Further studies are needed to thoroughly evaluate this system for wounds of different varieties and sites.

Conflict of Interest

None declared.

References

- 1 Hirshowitz B, Lindenbaum E, Har-Shai Y. A skin-stretching device for the harnessing of the viscoelastic properties of skin. *Plast Reconstr Surg* 1993;92(02):260–270
- 2 Barnea Y, Gur E, Amir A, et al. Delayed primary closure of fasciotomy wounds with Wisebands, a skin- and soft tissue-stretch device. *Injury* 2006;37(06):561–566
- 3 Topaz M, Carmel NN, Silberman A, Li MS, Li YZ. The TopClosure® 3S system, for skin stretching and a secure wound closure. *Eur J Plast Surg* 2012;35(07):533–543
- 4 Song M, Zhang Z, Liu T, et al. EASApprox® skin-stretching system: a secure and effective method to achieve wound closure. *Exp Ther Med* 2017;14(01):531–538
- 5 Berman SS, Schilling JD, McIntyre KE, Hunter GC, Bernhard VM. Shoelace technique for delayed primary closure of fasciotomies. *Am J Surg* 1994;167(04):435–436
- 6 Manista GC, Dennis A, Kaminsky M. Surgical management of compartment syndrome and the gradual closure of a fasciotomy wound using a DermaClose device. *Trauma Case Rep* 2018;14:1–4
- 7 Govaert GA, van Helden S. Ty-raps in trauma: a novel closing technique of extremity fasciotomy wounds. *J Trauma* 2010;69(04):972–975
- 8 Partridge A. Nylon straps for internal fixation of bone. *Lancet* 1976;2(7997):1252
- 9 de Ridder VA, de Lange S, Koomen AR, Heatley FW. Partridge osteosynthesis: a prospective clinical study on the use of nylon cerclage bands and plates in the treatment of periprosthetic femoral shaft fractures. *J Orthop Trauma* 2001;15(01):61–65
- 10 Gurer A, Ozlem N, Gokakin AK, Ozdogan M, Kulacoglu H, Aydin R. A novel material in seton treatment of fistula-in-ano. *Am J Surg* 2007;193(06):794–796