




# Surgery of a Giant Coronary Sinus Aneurysm Resulting from a Coronary Artery Fistula

Nawras Diab<sup>1</sup> Mohamed Barghout<sup>1</sup> Sami Kueri<sup>1</sup> Martin Soschynski<sup>2</sup> Matthias Siepe<sup>3</sup>

<sup>1</sup>Department of Cardiovascular Surgery, Albert-Ludwigs-Universität Freiburg, Freiburg im Breisgau, Germany

<sup>2</sup>Department of Diagnostic and Interventional Radiology, Medical Center, Faculty of Medicine, University of Freiburg, Albert-Ludwigs-Universität Freiburg, Freiburg im Breisgau, Germany

<sup>3</sup>Department of Cardiac Surgery, Cardiovascular Center, Inselspital Universitätsspital Bern, Bern, Switzerland

**Address for correspondence** Dr. med Nawras Diab, Department of Cardiovascular Surgery, Albert-Ludwigs-Universität Freiburg, Suedring 15, Freiburg im Breisgau 79098, Germany (e-mail: nawras.diab@uniklinik-freiburg.de).

Thorac Cardiovasc Surg Rep 2023;12:e7–e9.

## Abstract

Coronary artery fistula (CAF), complicated by the aneurysmal formation of the coronary sinus (CS), is a very rare form of CAF. Here we report a case of a 60-year-old woman with a giant aneurysm of the CS resulting from the right coronary artery (RCA) fistula. The patient was highly symptomatic with dyspnea due to compression of cardiac chambers. CS reconstruction was performed using a pericardial patch after directly closing the fistula from the RCA to the CS.

## Keywords

- ▶ aneurysm
- ▶ Coronary Sinus
- ▶ Fistula

## Introduction

Coronary artery fistula (CAF) is a relatively rare anomalous communication between the coronary arteries and the cardiac chambers or other vessels. Although most patients are asymptomatic, myocardial ischemia due to the coronary steal phenomenon could be its first presentation.<sup>1</sup> Here, we report a case of a 60-year-old woman who presented with exertional dyspnea, fatigue, and atrial fibrillation. She was diagnosed with right CAF and coronary sinus aneurysm.

## Case Description

A 60-year-old woman with no significant medical history was admitted to a referral hospital due to shortness of breath and palpitation. Physical examination was unremarkable. The initial electrocardiogram showed atrial fibrillation but no signs of ischemia. Further investigation with contrast-enhanced computed tomography (CT) visualized an ectatic

right coronary artery (RCA) measuring 10 × 10 mm over the entire course through the right atrioventricular groove, a coronary fistula (CF) of the right posterolateral artery after a tortuous course into the coronary sinus (CS) near the inferior atrial septum, as well as a severe dilatation of the CS to 9.5 × 4.5 cm over a length of approximately 13 cm (▶ **Fig. 1**). The magnitude of this dilatation led to a significant narrowing of cardiac structures and pressurized the left ventricle as well. The patient was transferred to our hospital, where complementary diagnostics were performed. An invasive coronary angiography (CA) showed aneurysmal dilatation of the RCA with distal convolute and normal left coronary arteries. The echocardiography studies confirmed the finding and showed a moderate functional mitral valve regurgitation because of annular dilatation and eventually due to external pressure on the base of the left ventricle.

The procedure was performed in full sternotomy and with cardiopulmonary bypass (CPB) through central aortic cannulation and selective cannulation of the superior vena cava, and percutaneous cannulation of the inferior vena

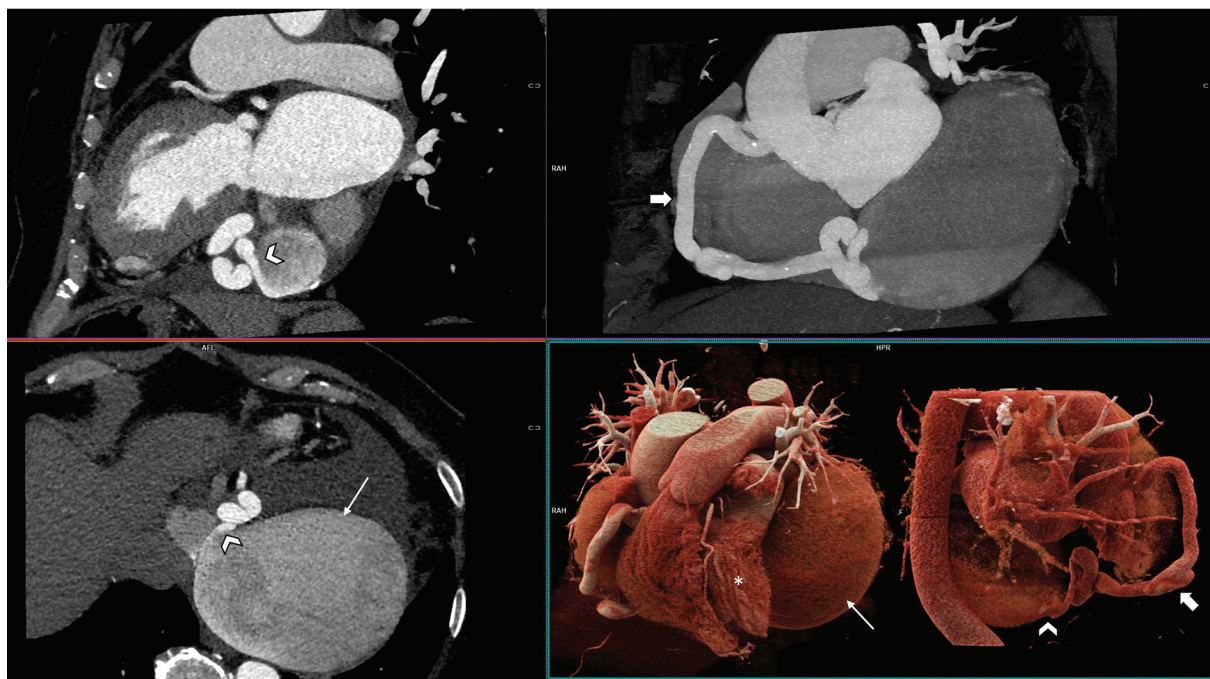
received  
October 22, 2022  
accepted  
November 8, 2022

DOI <https://doi.org/10.1055/s-0043-1760751>.  
ISSN 2194-7635.

© 2023. The Author(s).

This is an open access article published by Thieme under the terms of the Creative Commons Attribution-NonDerivative-NonCommercial-License, permitting copying and reproduction so long as the original work is given appropriate credit. Contents may not be used for commercial purposes, or adapted, remixed, transformed or built upon. (<https://creativecommons.org/licenses/by-nc-nd/4.0/>)

Georg Thieme Verlag KG, Rüdigerstraße 14, 70469 Stuttgart, Germany



**Fig. 1** Computer tomography angiography of the coronary arteries with contrast material. (A) Multiplanar reconstructions show the orifice of the fistula into the coronary sinus (arrowhead). (B) A dilated tortuous right coronary artery (RCA; thick arrow). (C) The right posterolateral branch (PL) of the RCA enters the massively aneurysmatic coronary venous sinus (orifice: arrowhead; sinus: thin arrow) near the inferior atrial septum as a coronary fistula with an orifice of  $3 \times 8$  mm. (D) Three-dimensional volume rendering image shows the aneurysmatic coronary venous sinus (thin arrow) from a left anterior oblique view and the course of the RCA (thick arrow) with its PL branch draining into the coronary sinus from a posterior view. The left ventricle (star) is compressed by the aneurysmatic coronary sinus.

cava (IVC) through the right femoral vein in case of cross-clamping and disconnection the IVC, if necessary, to offer maximal exposure of the dorsal side of the heart. The increased pressure in the CS led to the formation of remarkable epicardial varicose of the left sided coronary veins. After CPB initiation and exposure to the giant CS (**Fig. 2A**), the RCA was circumferentially dissected and encircled with Silastic tapes and a tourniquet. The fistula was identified after opening the CS through tourniquet release and closure on the RCA. The fistula was closed with direct sutures (**Fig. 2B**). The CS ostium was inspected and showed no stenosis. A reconstruction of the CS with a bovine pericardial patch in a tunnel-shaped was performed (**Fig. 2C**), and the aneurysm sac was closed. Pulmonary vein isolation using radiofrequency ablation and closure of the left atrium appendage using a clip were done as a concomitant procedure. The mitral valve was repaired via annuloplasty. Due to newly detected moderate regurgitation, the tricuspid valve was also repaired using annuloplasty. After disconnection of the CPB and a long period of hemostasis, the patient was transferred to the intensive care unit with an open chest because of blood oozing. The thorax was successfully closed the next day, and the postoperative course was uneventful. Two weeks later, the patient was discharged from the hospital in good general condition. Six months after the procedure, the patient has no dyspnea or palpitation. The 24 hours electrocardiogram showed no evidence of atrial fibrillation. In addition, echocardiography revealed normal pump function.

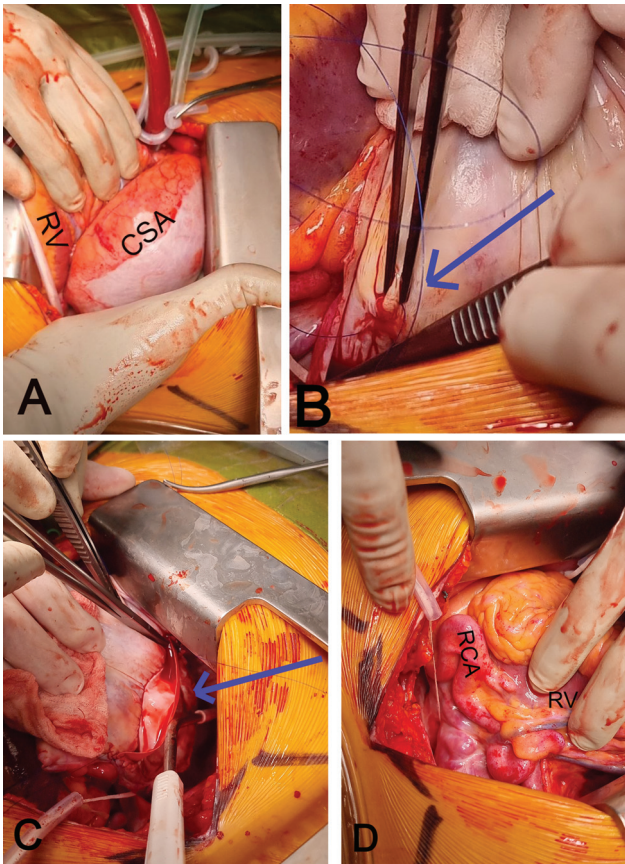
## Conclusion

CAF is a rare abnormal connection between a coronary artery or one of its branches and a cardiac chamber or other vascular structures. The reported general population incidence is 0.0002%,<sup>1</sup> in which just 7% of CAF drain into the CS.<sup>2</sup> This connection between RCA and CS may lead to an aneurysmal formation of the CS in the coexistence of CS ostium stenosis,<sup>3</sup> which was not present in this patient. A rare form of CS aneurysm associated with multiple venous anomalies has also been reported.<sup>4</sup>

Most CAF are asymptomatic, and clinical presentation is related to size, shunt, progression, and location. CAF with big shunts may present with myocardial ischemia or infarction due to stealing phenomena, and others could lead to a severe dilatation of the vascular structure, which in big sizes could impress the cardiac chambers.

Echocardiography is a fast, noninvasive, and reliable tool for providing sufficient information about the CAF, especially shunt hemodynamics and the existence of CS ostium stenosis. However, in the case of CS aneurysms, complementary studies such as CT angiography and CA are strongly recommended to establish the diagnosis and plan the best available approach, considering that giant aneurysms of CS may be misdiagnosed with extracardiac mediastinal tumors.<sup>5</sup>

In our case, the fistula drains directly to the SC, leading to the SC's severe aneurysmal formation, which in turn compresses the left ventricle partly, causing shortness of breath.



**Fig. 2** Intraoperative images. (A) Coronary sinus aneurysm (CSA). (B) Closing the right coronary artery (RCA) fistula into the CS with a direct suture (arrow). (C) Reconstruction of the CS using a bovine pericardial patch (arrow). (D) Dilated tortuous RCA. RV, right ventricle. (RV = right ventricle, CSA = Coronary sinus Aneurysm).

The goal of the treatment is to close the shunt with the preservation of normal coronary flow. Surgical and interventional closure presents the currently available options. In isolated CAF, interventional closure using a cover stent has been reported,<sup>6</sup> and surgery via direct external ligation without CPB.

In CAF complicated with big aneurysms, surgery was the best option since closing the shunt alone will not relieve

the symptoms resulting from mass impact. In the surgical approach, CPB is needed if closing the fistula is anticipated from within the recipient chamber,<sup>7</sup> and a reconstruction of the CS is aimed in our case.

Taken together, the very rare combination of CAF to the CS and an aneurysm of the CS might best be corrected with surgical closure of the CAF and reconstruction of the CS.

#### Acknowledgment

The authors acknowledge support by the Open Access Publication Fund of the University of Freiburg.

#### Conflict of Interest

None.

#### References

- Buccheri D, Chirco PR, Geraci S, Caramanno G, Cortese B. Coronary artery fistulae: anatomy, diagnosis and management strategies. *Heart Lung Circ* 2018;27(08):940–951 <http://www.heartlungcirc.org/article/S1443950618300295/fulltext> cited 2022Feb5 [Internet]
- Dodge-Khatami A, Mavroudis C, Backer CL. Congenital Heart Surgery Nomenclature and Database Project: anomalies of the coronary arteries. *Ann Thorac Surg* 2000;69(4, Suppl):S270–S297 <https://pubmed.ncbi.nlm.nih.gov/10798435/> cited 2022Feb5 [Internet]
- Pu L, Li R, Yang Y, Liu G, Wang Y. Right coronary artery coronary sinus fistula with coronary sinus ostium stenosis. *Echocardiography* 2017;34(07):1102–1104
- Song G, Du M, Ren W, Zhou K, Sun L. Coronary sinus aneurysm associated with multiple venous anomalies. *BMC Cardiovasc Disord* 2017;17(01):95 <https://bmccardiovascdisord.biomedcentral.com/articles/10.1186/s12872-017-0532-3> cited 2022Feb5 [Internet]
- Hori S, Saito S, Kato T, et al. Giant coronary sinus aneurysm misdiagnosed as an extracardiac mediastinal tumor. *Gen Thorac Cardiovasc Surg* 2021;69(08):1236–1239 [Internet]
- Witte LS, Bouma BJ, Straver B, et al. Closing a right coronary artery fistula draining into the coronary sinus using a covered stent in the coronary sinus. *JACC Case Rep* 2021;3(14):1589–1593
- Liberthson RR, Sagar K, Berkoben JP, Weintraub RM, Levine FH. Congenital coronary arteriovenous fistula. Report of 13 patients, review of the literature and delineation of management. *Circulation* 1979;59(05):849–854 <https://pubmed.ncbi.nlm.nih.gov/428095/> cited 2022Feb6 [Internet]