


Medial Femoral Condyle Corticoperiosteal Flap for Failed Total Wrist Fusions

Richard Tee, MBBS, PhD, FRACS¹ Jason N. Harvey, MBBS, FRACS^{1,2} Stephen K. Tham, MBBS, FRACS^{1,3,4}
Eugene T. Ek, MBBS, PhD, FRACS^{1,3,5} 

¹Division of Hand Surgery, Department of Orthopaedic Surgery, Dandenong Hospital, Monash Health, Melbourne, Victoria, Australia

²Orthosport Victoria, Richmond, Melbourne, Victoria, Australia

³Department of Surgery, Monash Medical Centre, Monash University, Melbourne, Victoria, Australia

⁴Victorian Hand Surgery Associates, Fitzroy, Melbourne, Victoria, Australia

⁵Melbourne Orthopaedic Group, Windsor, Melbourne, Victoria, Australia

Address for correspondence Eugene T. Ek, MBBS, PhD, FRACS, Melbourne Orthopaedic Group, 33 The Avenue, Windsor, 3181, Melbourne, Victoria, Australia (e-mail: eugene.ek@mog.com.au).

J Wrist Surg 2023;12:288–294.

Abstract

Keywords

- ▶ medial femoral condyle flap
- ▶ MFC
- ▶ nonunion
- ▶ wrist
- ▶ radiocarpal
- ▶ fusion
- ▶ arthrodesis
- ▶ corticoperiosteal flap
- ▶ bone graft

Background Recalcitrant nonunion following total wrist arthrodesis is a rare but challenging problem. Most commonly, in the setting of failed fusion after multiple attempts of refixation and cancellous bone grafting, the underlying cause for the failure is invariably multifactorial and is often associated with a range of host issues in addition to poor local soft-tissue and bony vascularity. The vascularized medial femoral condyle corticoperiosteal (MFC-CP) flap has been shown to be a viable option in a variety of similar settings, which provides vascularity and rich osteogenic progenitor cells to a nonunion site, with relatively low morbidity. While its utility has been described for many other anatomical locations throughout the body, its use for the treatment of failed total wrist fusions has not been previously described in detail in the literature.

Methods In this article, we outline in detail the surgical technique for MFC-CP flap for the management of recalcitrant aseptic nonunions following failed total wrist arthrodesis. We discuss indications and contraindications, pearls and pitfalls, and potential complications of this technique.

Results Two illustrative cases are presented of patients with recalcitrant nonunions following multiple failed total wrist fusions.

Conclusion When all avenues have been exhausted, a free vascularized corticoperiosteal flap from the MFC is a sound alternative solution to achieve union, especially when biological healing has been compromised. We have been able to achieve good clinical outcomes and reliable fusion in this difficult patient population.

Nonunion after total wrist arthrodesis is uncommon with modern implants and techniques.¹ However, in the small group of patients that do not unite, revision surgery with reparation radial–carpal interface, nonvascularized cancellous bone grafting, and rigid spanning fixation is usually

successful. In rare instances, recalcitrant nonunion occurs despite multiple attempts at refixation and nonvascularized bone grafting.² While various vascularized bone flaps have been used for the management of such situations, in recent times the medial femoral condyle corticoperiosteal (MFC-CP)

received

April 16, 2022

accepted after revision

December 3, 2022

article published online

January 20, 2023

© 2023, Thieme. All rights reserved.
Thieme Medical Publishers, Inc.,
333 Seventh Avenue, 18th Floor,
New York, NY 10001, USA

DOI <https://doi.org/10.1055/s-0043-1760737>.
ISSN 2163-3916.

flap has become increasingly popular given its success in a variety of settings, especially recalcitrant nonunions.³⁻⁶

Vascularized periosteal flaps have the potential to address local vascularity issues and deliver abundant osteogenic progenitor cells to the wrist, which is often compromised from prior periosteal stripping and deficiency of a wrist capsule.^{5,7} The main advantage of the MFC-CP flap over other bone flaps is the ease of inset over the nonunion site, with usually a small area of bone deficiency. In comparison, other bone flaps, such as a free fibula, are often too bulky for this purpose.³ Other advantages include relatively low donor-site morbidity, short harvest time (~45 minutes), and the availability of abundant cancellous bone graft from the same donor site.⁸

In the wrist, Henry previously reported on six cases of distal radius nonunion managed with an MFC-CP flap, including two cases of osteomyelitis-related nonunions, with good success.⁹ To our knowledge, the role of the MFC-CP flap has not been previously reported in the literature; therefore, here we describe our technique of using the MFC-CP flap for management of recalcitrant aseptic nonunion following total wrist fusions.

Materials and Methods

Indications and Contraindications

Indications for the MFC-CP include multiple failed attempts of fusion of the radiocarpal joint despite rigid and stable spanning fixation of the wrist and adequate nonvascularized bone grafting. Nonunion is typically considered as failure of bridging bone across the radiocarpal joint to at least the distal row, after at least 6 months from the index surgery. The MFC-CP flap can fill in relatively small bony defects of less than 2 cm. Contraindications include active infection, past history of peripheral vascular disease involving the upper extremity, and preoperative angiography demonstrating poor or absent radial and ulna arterial flow. The knee donor site should be free of previous trauma.

Surgical Anatomy

The blood supply of the MFC is derived from the descending genicular artery (DGA) and the superomedial genicular artery (SGA) (►Fig. 1). Cadaveric studies show that the DGA is present in 89% of limbs, while the SGA is the dominant blood supply to MFC in approximately 11% of cases.¹⁰ Vascular studies have demonstrated that up to 13.7 cm of the medial femur periosteum proximal to the joint line is reliably supplied by the DGA.¹¹

The DGA, when present, arises from the superficial femoral artery approximately 14 cm from the tibiofemoral joint line just prior to its entry into the adductor hiatus.¹⁰ In the majority, it gives rise to three branches, namely the osteoarticular branch, the muscular branch, and the saphenous branch (►Fig. 1). Its branching pattern has been detailed in an anatomical study by García-Pumarino and Franco.¹² Its implication relates to the chimerism it allows—osteoarticular branch for medial femoral trochlea (MFT) flap (used for proximal scaphoid and lunate reconstruction), muscular branch allows a muscle component (vastus medialis) to be harvested with the flap, and a saphenous branch, which allows

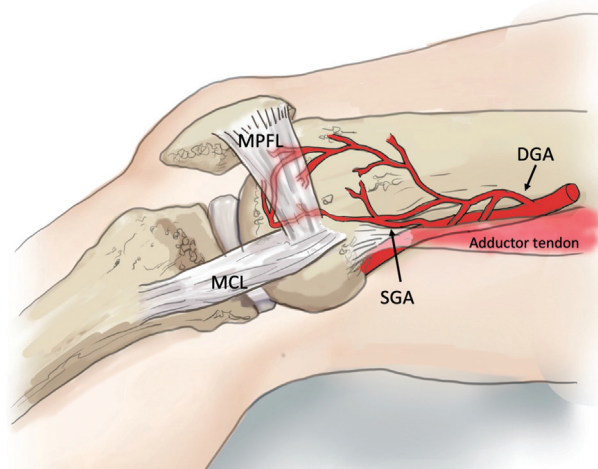


Fig. 1 Vascular anatomy and vital knee-stabilizing structures of the medial femoral condyle. The two main blood supply are the descending genicular artery (DGA), which originates from the superficial femoral artery, and the superomedial genicular artery (SGA), which arises from the popliteal artery through the adductor tendon. The medial collateral ligament (MCL) needs to be preserved when harvesting the periosteal flap. The medial patellofemoral ligament (MPFL) is a key stabilizing structure of the patella and is divided to access the distal portion of the periosteal flap.

for the harvest of a medial knee skin paddle. It should be noted that the branch pattern may not consistently allow for the chimeric flap to be harvest, as, on some occasions, the branches may arise directly from the superficial femoral artery.¹⁰

In a minority of cases, the SGA is the dominant blood supply to the region.¹⁰ Del Piñal et al encountered this anatomical variant in two of six cases reported.³ The SGA tends to have a shorter pedicle (3 cm), and dissection is more tedious, as it originates from the popliteal artery coursing through the adductor magnus tendon (►Fig. 1).

Finally, knowledge of the vital stabilizing structures around the knee is required to avoid iatrogenic donor-site morbidity. The medial patellofemoral ligament (MPFL) originates from the medial epicondyle and distal to the adductor tubercle and inserts to the superior half of the medial patella. This ligament plays an important role in patellofemoral tracking during knee during flexion and prevents lateral subluxation. The medial collateral ligament (MCL) originates from approximately 1 cm distal to the adductor tubercle and inserts into the medial tibia and stabilizes the knee to valgus stress (►Fig. 1).

Surgical Technique

Preoperative Examination and Imaging

The donor knee should be examined for any previous trauma that could potentially compromise the blood supply to the flap. We routinely perform a computed tomography (CT) angiogram to assess the recipient vessels around the wrist.

Flap Raising Technique

The patient is placed in a supine position. Using the ipsilateral knee allows for a two-team approach, with the flap-harvest team standing on the opposite side of the table. The leg is placed in a semi-frog leg position, with support

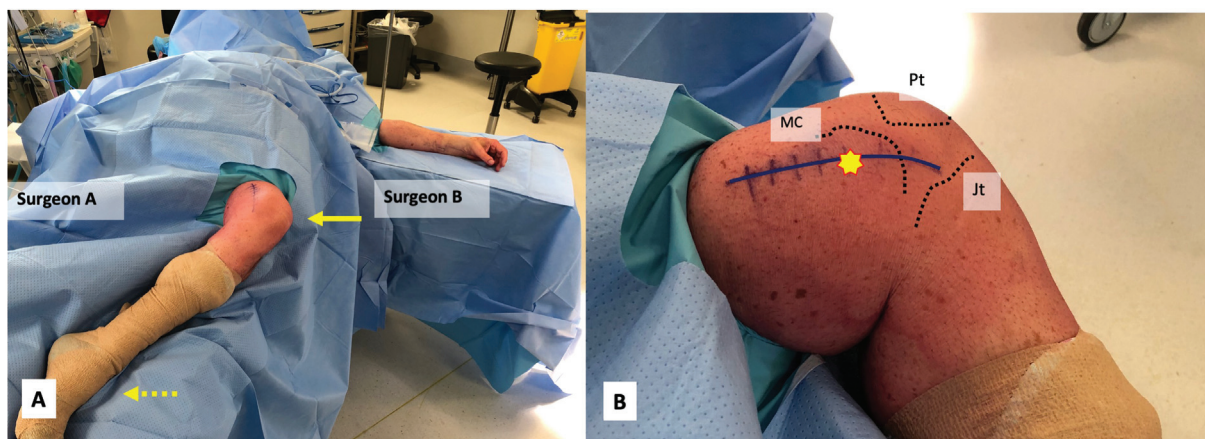


Fig. 2 Positioning of the patient and topical landmarks for incision. (A) Ipsilateral knee as donor allows surgeon A to harvest the flap from the opposite side of surgeon B, so simultaneous preparation can be performed. The leg is placed in a semi-frog leg position, with support (dash line arrow) preventing the foot from slipping and keeping it bent. A side support is placed to prevent the hip from abducting away from the surgeon (solid line arrow). (B) Topical landmarks for planning the incision. Patella (Pt) and medial condyle of the femur (MC). The incision is made in line with the distal femur centered over the medial epicondyle (star) and extending to the knee joint line (Jt).

preventing the foot from slipping and keeping the knee bent. A side support is placed to prevent the hip from abducting away from the surgeon (►Fig. 2A). A high thigh tourniquet is placed and the leg elevated but not exsanguinated before inflating the tourniquet to 300 mm Hg.

The topical landmarks for the flap include the medial condyle, the patella, and the knee joint line. A curvilinear incision is made along the length of the distal femur, centered over the medial epicondyle and extended toward the tibiofemoral joint line (►Fig. 2B).

The skin incision is deepened down to the deep fascia. Incision through the deep fascia exposes the vastus medialis muscle. The muscle is elevated and a Hohmann retractor is placed underneath the muscle and over the femur to allow exposure of the periosteal branches over the MFC and the medial intermuscular septum (►Fig. 3). The MPFL is identified and divided longitudinally in its midsubstance to aid primary repair upon closure. Both ends of the ligament are retracted to expose the more distal end of the medial condyle. The MCL insertion is left intact and not elevated to preserve knee stability.

The vascular pedicle can then be retrogradely dissected by elevating the vastus medialis from the medial intermuscular septum as proximal as required until its origin at the superficial femoral artery is reached. The pedicle can be skeletonized and prepared to the point it enters the periosteum.

The dimension of the recipient-site bone defect (including the area and depth) is determined and templated, and the corticoperiosteal flap is designed. The intended location of the corticocancellous component is marked. The largest possible area of periosteum is taken (►Fig. 3). The periosteum is elevated carefully toward the marked corticocancellous portion. The desired corticocancellous portion is then measured and carefully cut using a sagittal saw (using the blade tip to estimate the depth), followed by an osteotome to carefully elevate the depth intended without fragmenting the cancellous bone (►Fig. 4A, B). The pedicle may be ligated at this stage and mobilized to allow easier access to the

proximal osteotomy. Supplemental cancellous bone graft is also harvested from the MFC through the osteotomy and used to fill any defects in the wrist (►Fig. 4A).

Upon closure of the donor site, hemostasis is carefully performed. The exposed bony defect is covered with bone wax to minimize bleeding. The MPFL is primarily repaired with 1 Vicryl, and a 10-Fr drain tube is placed in the subvastus region and the incision is made in layers.

Preparation of the Recipient Site

The upper limb is exsanguinated with an Esmarch bandage and the tourniquet is inflated. The previous longitudinal incision is utilized and subcutaneous flaps are developed after exposure of the extensor retinaculum (►Fig. 5A). The retinaculum is then divided between the second and fourth

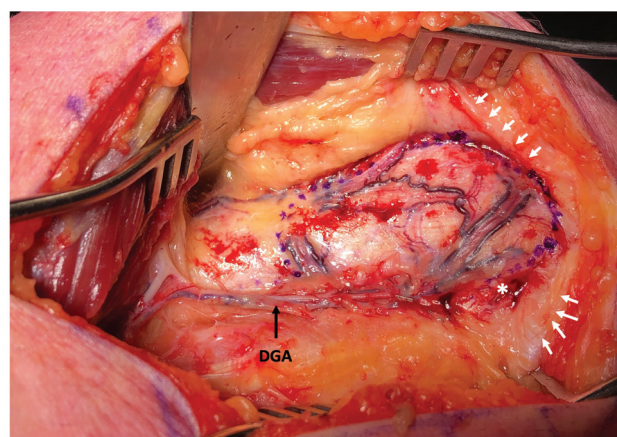


Fig. 3 Exposure of the medial supracondylar region of the femur. A blunt Hohmann retractor is placed over the femur to retract the vastus medialis muscle. The white arrows show the divided ends of the medial patellofemoral ligament (MPFL). The white asterisk indicates the location of the medial collateral ligament (MCL) insertion. The black arrow indicates the course of the descending genicular artery (DGA) running along the medial intermuscular septum and adductor tendon, which is the pedicle for the MFC-CP flap. The purple dotted line indicates the outline of the periosteal flap to be harvested.

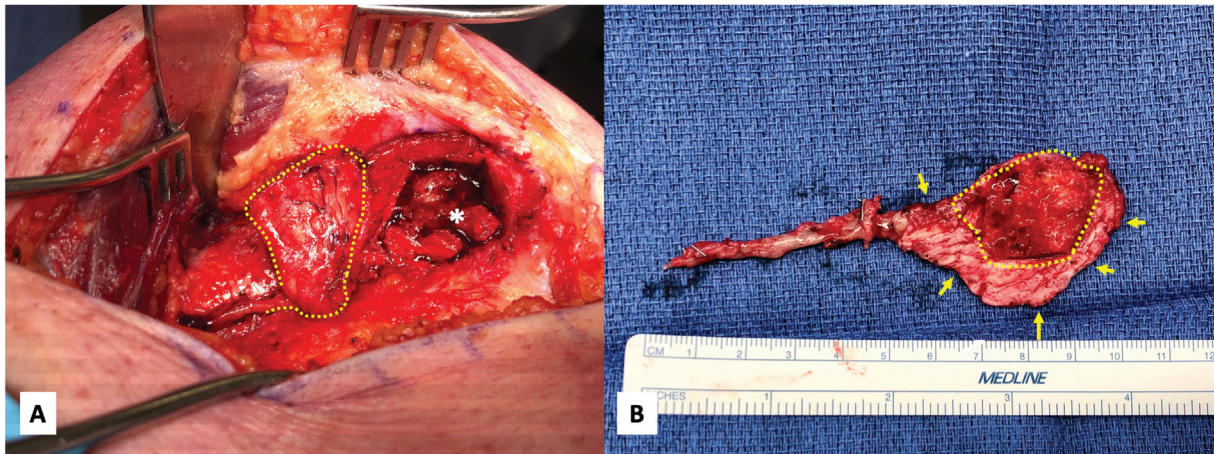


Fig. 4 The harvest of the corticocancellous portion of the medial femoral condyle corticoperiosteal (MFC-CP) flap. (A) The flap (dash line) has been elevated from the medial condyle. The asterisk (*) indicates the donor site with cancellous bone graft available for harvest. (B) Arrows indicates the edges of the periosteal part of the flap. The dash line indicates the corticocancellous portion of the flap designed to fit over the nonunion site.

compartment and the extensor tendons are retracted to expose the radiocarpal joint. Any in situ hardware is subsequently removed.

Careful preparation of both the distal radius metaphysis and the carpus is performed to expose viable cancellous surfaces for adequate fusion. We frequently use high-speed burrs to decorticate any remaining articular surfaces and debride avascular sclerotic bone (→ Fig. 5B). Often, the use of an oscillating saw is helpful in obtaining coplanar surfaces on

both the distal radius and the carpus that can be compressed, especially if the midcarpal joint has been partially fused. Harvested cancellous bone graft is then impacted into any defect and into the space between the radius and carpus.

The wrist is then stabilized using a spanning total wrist plate extending from the distal radius to either the third or second metacarpal, depending on whether there is adequate bone stock to achieve fixation, given previous surgeries. Often, fixation to the second metacarpal is necessary as

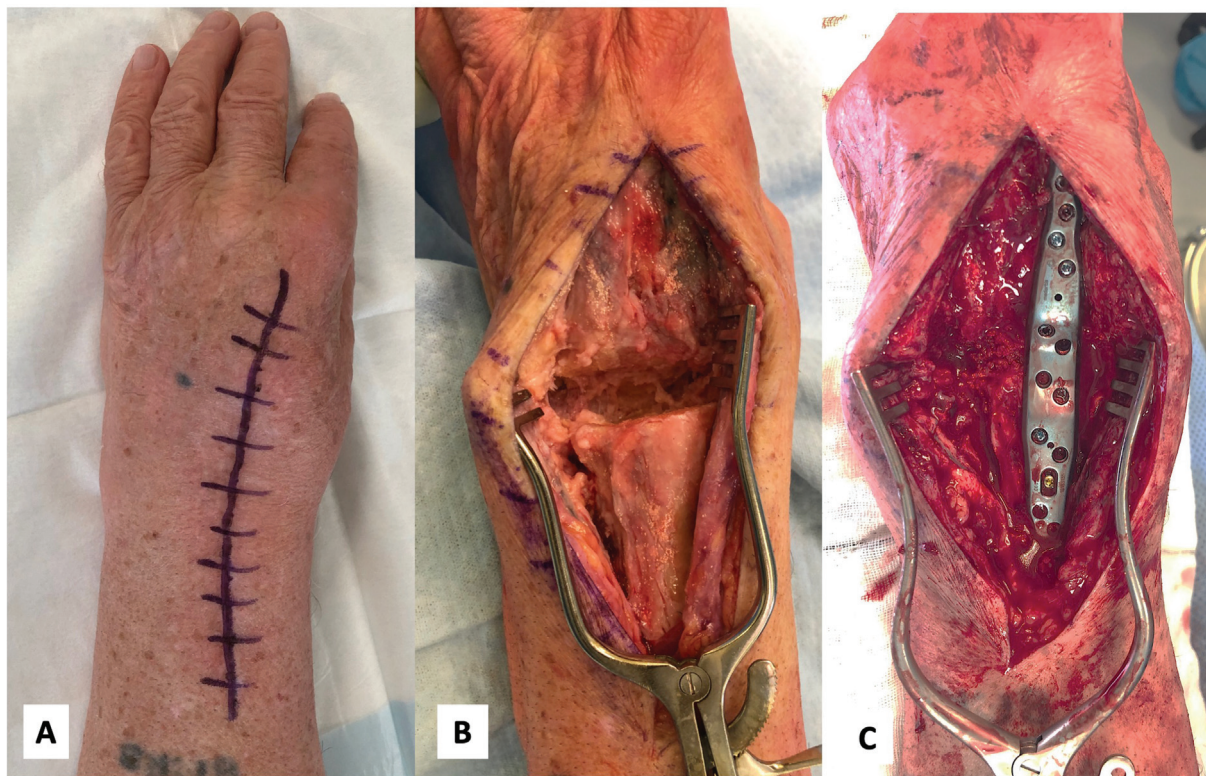


Fig. 5 Preparation of the wrist. (A) The previous longitudinal incision is utilized. (B) Careful preparation of both the distal radius metaphysis and the carpus is performed to ensure exposure of viable cancellous surfaces for adequate fusion. (C) A spanning total wrist plate extending from the distal radius to the second or third metacarpal ensuring there is adequate bone stock to achieve fixation, keeping in mind previous fixations.

previous attempts may have compromised the third metacarpal (►Fig. 5C). Attempt should be made to achieve as much compression as possible across the radiocarpal region.

Inset of the Flap

The corticoperiosteal flap is placed over the radius and carpus, ensuring that maximal coverage is obtained by the flap over the bony surfaces that need to fuse (►Fig. 6). The goal is to have the corticocancellous component of the flap over the radiocarpal joint. This can be secured and compressed using a 2.0mm compression screw. Using 3–0 Monocryl, the periosteal component of the flap is secured to the surrounding soft tissues.

Microsurgical arterial anastomosis is then performed in an end-to-side manner to the radial artery in the anatomical snuff box. The venae comitantes (VC) of the pedicle is anastomosed to either the VC of the radial artery or the cephalic vein or its branches. Milking test is performed to ensure patency of the vessels, and the periosteal flap is checked for bleeding. The extensor tendons are repositioned

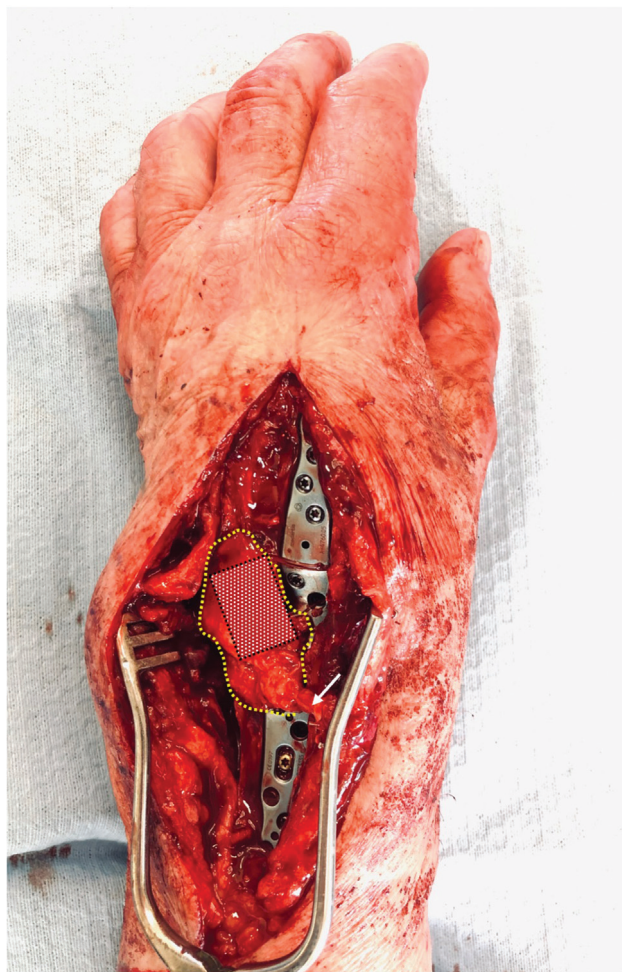


Fig. 6 Inset of the MFC-CP flap. The corticoperiosteal flap (dash line) is placed over the radius and carpus, ensuring that maximal coverage is obtained by the flap over the bony surfaces that need to fuse. The corticocancellous component (red box) of the flap is spread over the radiocarpal joint. The white arrow indicates the pedicle that is anastomosed to the radial artery in the anatomical snuff box.

over the wrist and the extensor retinaculum is not repaired. The incision is closed in layers and the wrist is immobilized with a volar splint.

Postoperative Management

Twenty-four hours of intravenous cephalosporin is given as prophylaxis beginning perioperatively. A skin paddle is not routinely harvested for monitoring since it can be quite voluminous. The size of the vein is usually too small for a Cook Doppler probe, without risking kinking or compression of the pedicle. The drain tube in the knee is usually removed on postoperative day 2 and the patient is allowed to mobilize and weight bear as tolerated, usually with a single crutch.

The wrist is immobilized for 8 weeks in a volar splint. Initially, the patient is placed into a plaster volar splint, which is converted to a removable thermoplastic volar splint after the 10- to 14-day wound review. Actively finger movements are encouraged to minimize the risk of stiffness. Routine X-rays are performed postoperatively and union is confirmed by CT scan beginning at 8 weeks. If not achieved at that time, CT scans of the wrist are repeated every 6 weeks thereafter until clear bony fusion is observed.

Results

Case Example 1

A 54-year-old woman presented after three failed attempts at wrist fusion following multiple complications after distal radius fracture fixation, including the development of chronic osteomyelitis (►Fig. 7A). Her background medical history was a significant contributing factor, which included a history of alcohol abuse with liver cirrhosis. After the deep infection had been eradicated with intravenous antibiotics and the use of an external fixator (►Fig. 7B), multiple attempts to obtain fusion of the wrist were performed, including use of dorsal plate fixation and two attempts with Steinmann pins, all with supplemental nonvascularized bone graft (►Fig. 7C, D). Reconstruction using an MFC-CP flap and a spanning wrist fusion plate was eventually performed (►Fig. 7E). At 3-month follow-up, the patient was pain-free and had significantly improved wrist function. Complete bony fusion of the wrist was confirmed on CT scan at 6 months (►Fig. 7F).

Case Example 2

A 65-year-old man presented after three failed attempts of total wrist fusion on the background of originally sustaining a transscaphoid perilunate fracture dislocation 7 years ago, which subsequently developed secondary posttraumatic arthritis and scaphoid nonunion advanced collapse. Prior to his presentation to us, he had undergone three attempted fusions of the wrist with nonvascularized bone graft from the iliac crest, with the first two spanning across to the third metacarpal. After failure of the second fusion, a third attempt was made to the second metacarpal. The hardware was subsequently removed due to significant loosening of the metacarpal fixation and a low-grade infection was excluded (►Fig. 8A). The patient subsequently had an MFC-CP flap

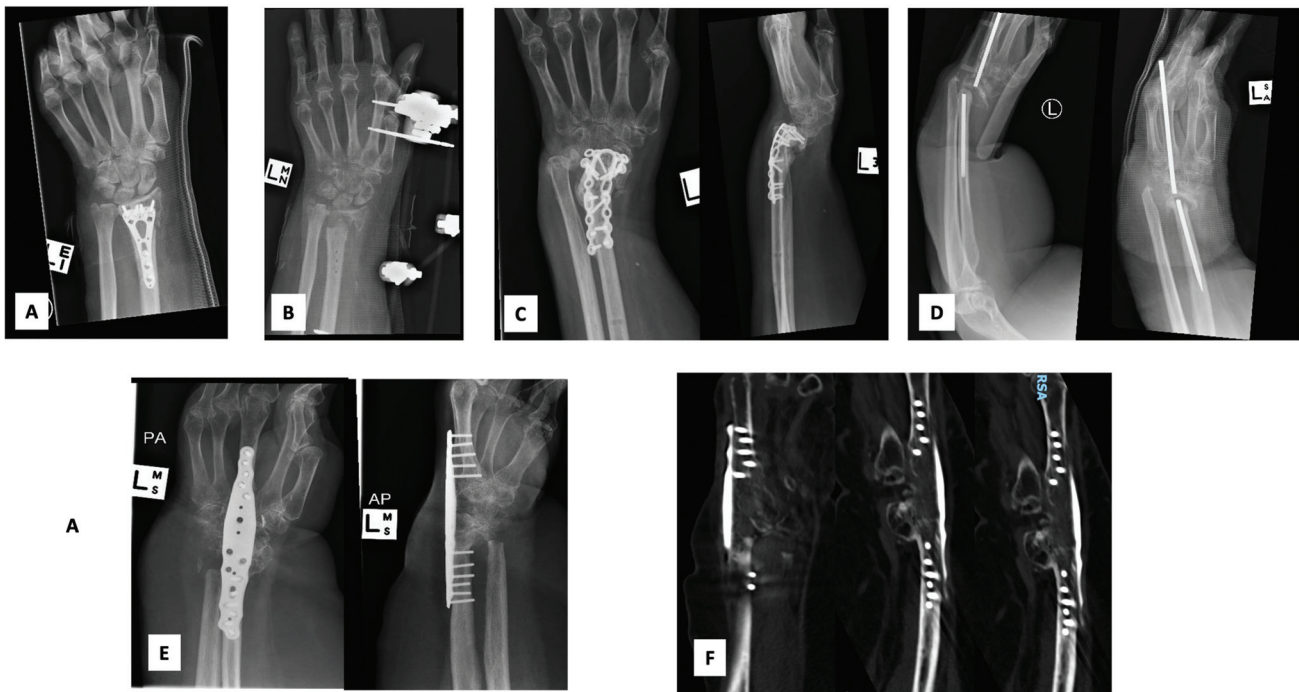


Fig. 7 Case 1: a 54-year-old woman. (A) Initial distal radius fracture reduction and internal fixation with a volar locking plate. (B) The wrist became infected and the hardware was removed and an external fixator was applied. (C) Revision fusion with iliac crest bone graft failed. (D) Another attempt at wrist fusion with Steinmann pin also failed. (E) Definitive reconstruction with an MFC-CP flap and a spanning wrist fusion plate was performed. (F) Complete bony union of the wrist was confirmed on CT scan at 6 months.

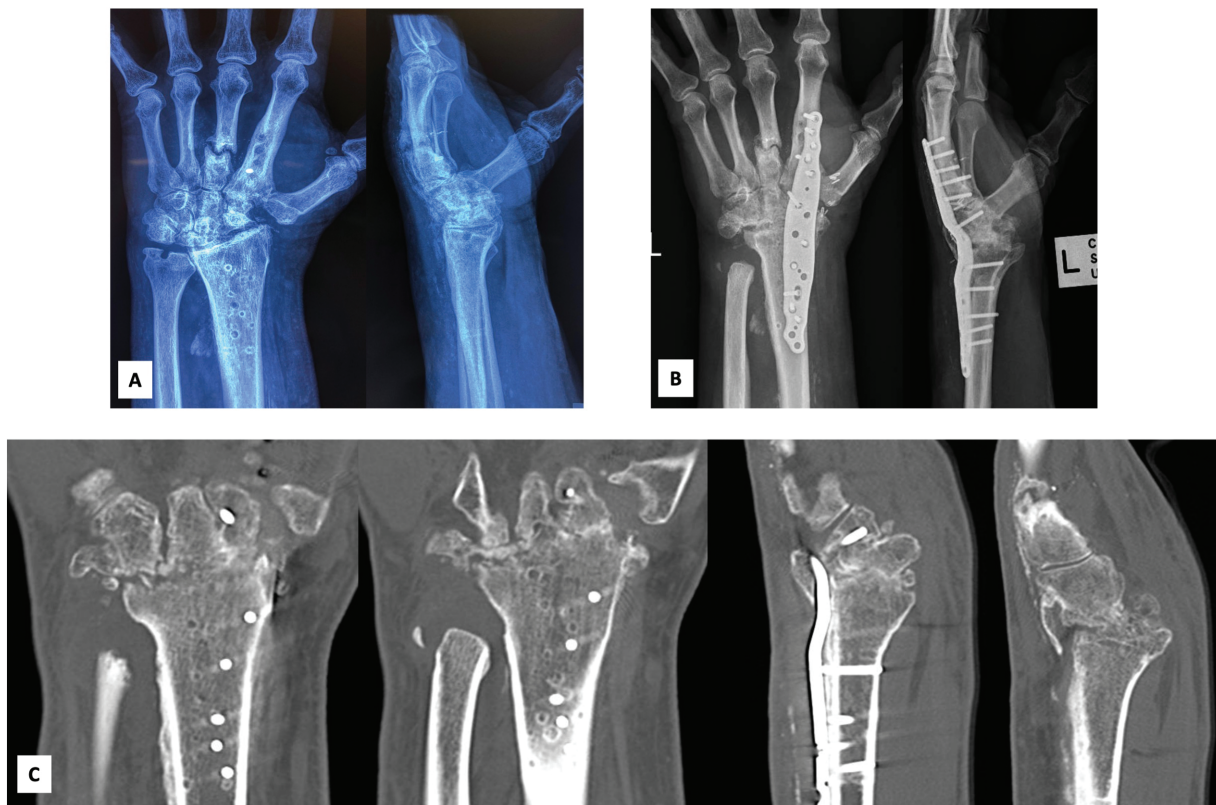


Fig. 8 Case 2: a 65-year-old man. (A) Initial presentation to our institution after three failed attempts of total wrist fusion. Note previous fixation to the third and second metacarpals. (B) The patient subsequently underwent revision spanning fixation to the second metacarpal and a free MFC-CP flap. (C) At 4 months, CT scan confirmed bony union across the radiocarpal joint in both the coronal and sagittal planes.

with stable spanning fixation to the second metacarpal (►Fig. 8B). At the same time, a Darrach procedure was also performed due to symptomatic distal radioulnar joint arthrosis (►Fig. 8B). The patient regained pain-free use of his left wrist after 3 months, and bony union across the radiocarpal joint was confirmed on CT scan at 4 months (►Fig. 8C).

Discussion

Pearls and Pitfalls

It is vital that all modifiable host factors are corrected prior to surgery, e.g., cessation of smoking and diabetes control. Low-grade infection as the cause of nonunion should be excluded. Careful preparation of the bony surfaces is crucial, removing any sclerotic and nonviable bone and exposing bleeding cancellous bone. Sufficient cancellous bone graft should be harvested to fill in any defects at the radiocarpal joint; however, excessive harvest may risk iatrogenic fracture of the femur.⁸ Stable fixation must be achieved. Maximal area of periosteum should be harvested to allow adequate coverage of the carpus and distal radius. Pedicle length should be sufficient to reach the radial artery at the anatomical snuff box.

Complications

In a recent systematic review, the complication rate of MFC flap was approximately 10%, ranging from minor postoperative seromas, hematomas and suture abscess, to serious complications such as supracondylar femur fracture.^{8,13} The large majority of complications were related to issues around the knee (15/25), with all cases related to MFT flaps. Furthermore, cases with persistent paresthesia were associated with skin paddle harvest resulting in injury to the saphenous nerve. Thus, excluding the MFT flaps and MFCs that harvest skin paddles, the overall morbidity of MFC (with or without periosteum) is low.⁸ Interestingly, the theoretical risk of knee instability has not been reported. The rare but serious complication of femur fracture is likely related to the excessive amount of bone harvested.¹³

Conclusion

Recalcitrant nonunion following radiocarpal fusion is rare but a challenging problem. When all avenues have been exhausted, a vascularized corticoperiosteal flap is a sound alternative solution to achieve union, especially when biological healing has been compromised. It has been our

experience that the MFC-CP flap is technically easy to harvest with relatively consistent anatomy and has been shown to have minimal donor-site morbidity. We have been able to achieve good clinical outcomes and reliable fusion in this difficult patient population.

Conflict of Interest

None declared.

References

- 1 Ruskin JB, Shah HA, Congiusta DV, Ahmed IH, Vosbikian MM. Union of radiocarpal fusion with and without proximal row carpectomy: a systematic review. *J Hand Surg Am* 2021;46(03):200–208
- 2 González del Pino J, Bartolomé del Valle E, Graña GL, Villanova JF. Free vascularized fibular grafts have a high union rate in atrophic nonunions. *Clin Orthop Relat Res* 2004;419(419):38–45
- 3 Del Piñal F, García-Bernal FJ, Regalado J, Ayala H, Cagigal L, Studer A. Vascularised corticoperiosteal grafts from the medial femoral condyle for difficult non-unions of the upper limb. *J Hand Surg Eur Vol* 2007;32(02):135–142
- 4 Choudry UH, Bakri K, Moran SL, Karacor Z, Shin AY. The vascularized medial femoral condyle periosteal bone flap for the treatment of recalcitrant bony nonunions. *Ann Plast Surg* 2008;60(02):174–180
- 5 Doi K, Sakai K. Vascularized periosteal bone graft from the supracondylar region of the femur. *Microsurgery* 1994;15(05):305–315
- 6 Deng AD, Innocenti M, Arora R, Gabl M, Tang JB. Vascularized small-bone transfers for fracture nonunion and bony defects. *Clin Plast Surg* 2020;47(04):501–520
- 7 Roberts SJ, van Gastel N, Carmeliet G, Luyten FP. Uncovering the periosteum for skeletal regeneration: the stem cell that lies beneath. *Bone* 2015;70:10–18
- 8 Giladi AM, Rinkinen JR, Higgins JP, Iorio ML. Donor-site morbidity of vascularized bone flaps from the distal femur: a systematic review. *Plast Reconstr Surg* 2018;142(03):363e–372e
- 9 Henry M. Vascularized medial femoral condyle bone graft for resistant nonunion of the distal radius. *J Hand Surg Asian Pac Vol* 2017;22(01):23–28
- 10 Yamamoto H, Jones DB Jr, Moran SL, Bishop AT, Shin AY. The arterial anatomy of the medial femoral condyle and its clinical implications. *J Hand Surg Eur Vol* 2010;35(07):569–574
- 11 Iorio ML, Masden DL, Higgins JP. The limits of medial femoral condyle corticoperiosteal flaps. *J Hand Surg Am* 2011;36(10):1592–1596
- 12 García-Pumarino R, Franco JM. Anatomical variability of descending genicular artery. *Ann Plast Surg* 2014;73(05):607–611
- 13 Haines M, Baba M, Stewart DA. Iatrogenic femur fracture following medial femoral condyle flap harvest. *J Hand Surg Am* 2020;45(09):885.e1–885.e3