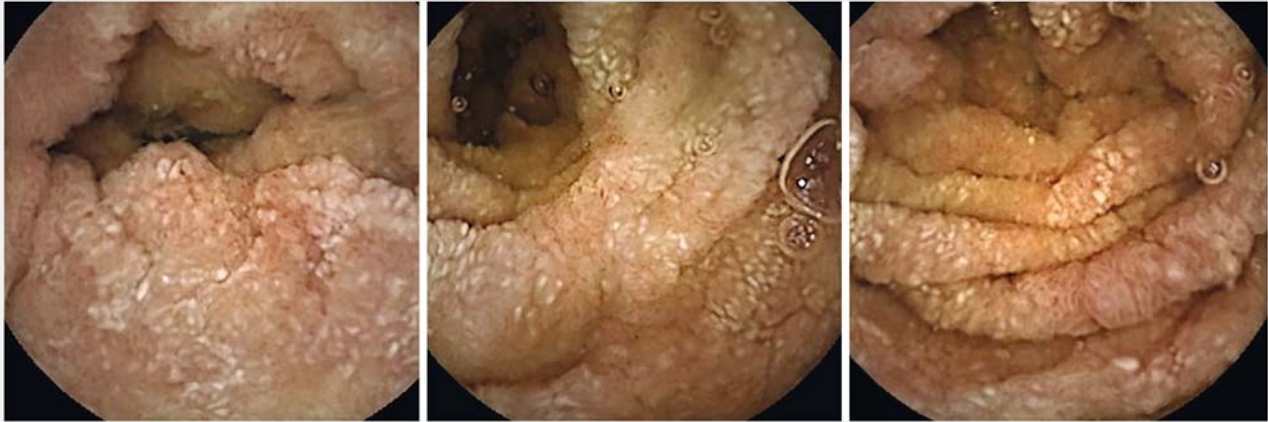

## Video capsule endoscopy diagnosis of Takayasu's arteritis

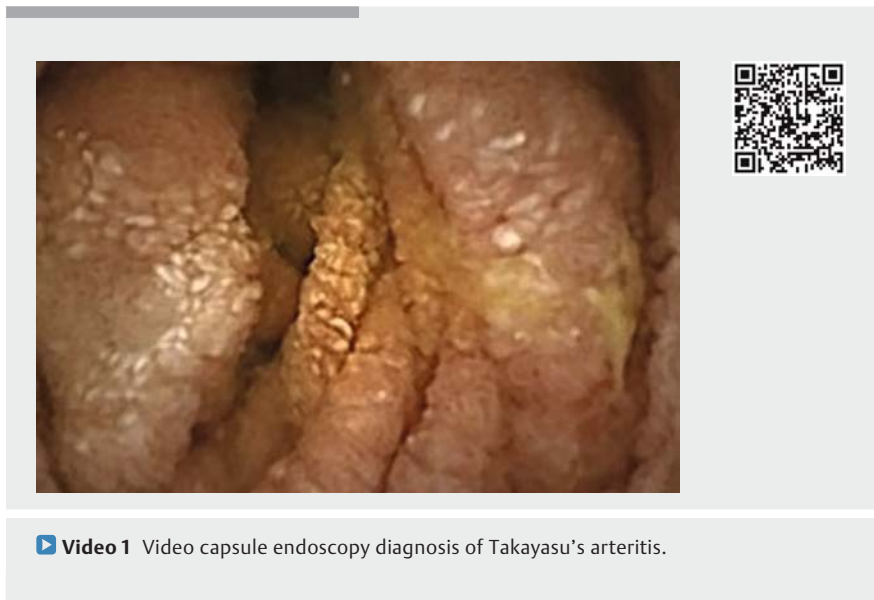

► **Fig. 1** Video capsule endoscopy images. Diffuse and continuous involvement of the jejunal mucosa was seen, with edema, reddish patches, and erosions.

An asymptomatic 62-year-old woman presented for a routine annual examination and was found to have elevated sedimentation rate and C-reactive protein. Physical examination was normal except for a difference in blood pressure between arms (120/74 on the right and 110/76 on the left). Computed tomography (CT) scan demonstrated an aortitis, and positron emission tomography–CT scan confirmed the presence of active inflammatory disease. She received prednisone 40 mg daily for 30 days, but discontinued the treatment because of multiple side effects.

One year later, she presented with severe intermittent abdominal pain, which was worst when lying flat. She had anorexia and lost several pounds. Results from ultrasonography and basic laboratory studies were unremarkable other than elevation of acute phase reactants and anemia. Upper gastrointestinal endoscopy revealed gastritis. Colonoscopy showed patchy submucosal hemorrhagic lesions in the right colon.

Capsule endoscopy showed diffuse and continuous involvement of the jejunal mucosa, with edema, reddish patches, and erosions (► **Fig. 1**, ► **Video 1**). Is-



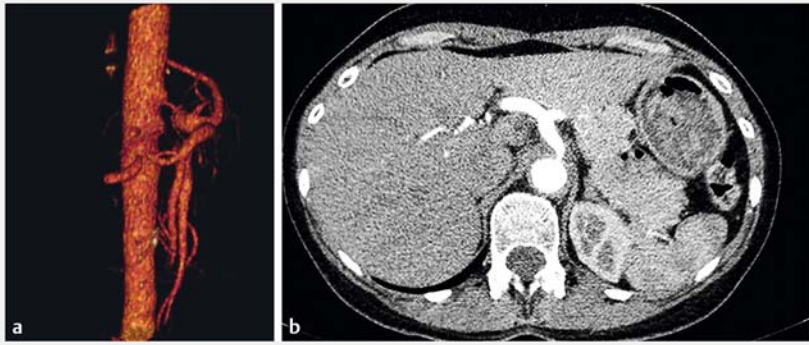
► **Video 1** Video capsule endoscopy diagnosis of Takayasu's arteritis.

chemic manifestation of a large vessel vasculitis (Takayasu's arteritis) was suspected.

CT angiogram revealed a dramatic distribution of vascular disease: severe stenosis of the celiac artery, 99% occlusion of the superior mesenteric artery, 50%–60% occlusion of the inferior mesenteric artery, significant stenosis of the right

renal artery, and 70%–80% occlusion of the left renal artery (► **Fig. 2**).

Takayasu's arteritis is a chronic inflammatory disorder primarily located in the aorta and its major branches, with recent updates of the classification criteria including large mesenteric vessels [1]. It is a disease of young women, although a mild course may become clinically overt



► **Fig. 2** Imaging showed a dramatic distribution of vascular disease: severe stenosis of the celiac artery, 99% occlusion of the superior mesenteric artery, 50%–60% occlusion of the inferior mesenteric artery, significant stenosis of the right renal artery, and 70%–80% occlusion of the left renal artery. **a** Computed tomography (CT) angiogram; **b** CT scan showing aortitis.

beyond the age of 40, which is one of the major criteria. It is a rare disease (1–3 patients per million per year) [1]. Gastrointestinal involvement is observed in organs that are dependent on the large branches of the abdominal aorta, such as the upper mesenteric artery [2, 3]. To our knowledge, this is the first report of Takayasu's arteritis diagnosed by video capsule endoscopy.

Endoscopy\_UCTN\_Code\_CCL\_1AC\_2AH

### Competing interests

None

### The authors

**Carolina Olano, Henry Cohen**

Clínica de Gastroenterología, Universidad de la República, Montevideo, Uruguay

### Corresponding author

**Carolina Olano, MD**

Hospital de Clínicas, Av. Italia S/n CP, 11600 Montevideo, Uruguay  
 Fax: +598-2-4872572  
 carolinaolanoouruguay@gmail.com

### References

- [1] Mueller-Ladner U. Vasculitides of the gastrointestinal tract. *Best Pract Res Clin Gastroenterol* 2001; 15: 59–82
- [2] Hoffman GS. Takayasu arteritis: lessons from the American National Institutes of Health Services. *Int J Cardiol* 1996 (Suppl. 54): S99–S102
- [3] Vanoli M, Miani S, Amft N et al. Takayasu's arteritis in Italian patients. *Clin Exp Rheumatol* 1995; 13: 45–50

### Bibliography

DOI <https://doi.org/10.1055/s-0043-122879>  
 Published online: 15.12.2017  
*Endoscopy* 2018; 50: E52–E53  
 © Georg Thieme Verlag KG  
 Stuttgart · New York  
 ISSN 0013-726X

### ENDOSCOPY E-VIDEOS

<https://eref.thieme.de/e-videos>



*Endoscopy E-Videos* is a free access online section, reporting on interesting cases and new techniques in gastroenterological endoscopy. All papers include a high quality video and all contributions are freely accessible online.

This section has its own submission website at <https://mc.manuscriptcentral.com/e-videos>