

# Impact of Papillary Muscle Infarction on Ischemic Mitral Regurgitation Assessed by Magnetic Resonance Imaging

## Einfluss eines Papillarmuskelfarktes auf die Entstehung einer ischämischen Mitralklappeninsuffizienz in der MRT

### Authors

Christiane Bretschneider<sup>1</sup>, Hannah-Klara Heinrich<sup>2</sup>, Achim Seeger<sup>3</sup>, Christof Burgstahler<sup>4</sup>, Stephan Miller<sup>3</sup>, Ulrich Kramer<sup>2</sup>, Meinrad Gawaz<sup>5</sup>, Konstantin Nikolaou<sup>2</sup>, Bernhard Klumpp<sup>2</sup>

### Affiliations

- 1 Radiology, Klinikum Frankfurt Höchst GmbH, Frankfurt am Main, Germany
- 2 Diagnostic and interventional Radiology, Universitätsklinikum Tübingen, Tuebingen, Germany
- 3 Radiologiepraxis Tuebingen, Radiologiepraxis Tuebingen, Germany
- 4 Sports Medicine, Universitätsklinikum Tübingen, Tuebingen, Germany
- 5 Cardiology, Universitätsklinikum Tübingen, Tuebingen, Germany

### Key words

LGE MRI, ischemic mitral regurgitation, myocardial infarction, papillary muscle

received 20.03.2017

accepted 06.06.2017

### Bibliography

DOI <https://doi.org/10.1055/s-0043-115121>

Published online: 3.11.2017 | Fortschr Röntgenstr 2018; 190: 42–50 © Georg Thieme Verlag KG, Stuttgart · New York, ISSN 1438-9029

### Correspondence

Dr. Bernhard Klumpp

Diagnostic and Interventional Radiology, Eberhard-Karls-University Tuebingen, Hoppe-Seyler-Str. 3, 72076 Tuebingen, Germany

Tel.: ++49/70 71/298 72 17

Fax: ++49/70 71/29 55 71

[bernhard.klumpp@med.uni-tuebingen.de](mailto:bernhard.klumpp@med.uni-tuebingen.de)

### ZUSAMMENFASSUNG

**Zielsetzung** Die ischämische Mitralklappeninsuffizienz ist ein negativer Prädiktor für eine Herzinsuffizienz und für eine hierdurch bedingte erhöhte Mortalität von Patienten mit chronischem Myokardinfarkt (MI). Ein kausaler Zusammenhang zwischen Papillarmuskelfarkt (PMI) und ischämisch bedingter Mitralklappeninsuffizienz ist unsicher. Ziel der vorgestellten Studie war es, den Zusammenhang von PMI in der MRT und Mitralklappeninsuffizienz sowie linksventrikulärer Funktion zu untersuchen.

**Material und Methodik** 48 Patienten mit chronischem MI und aktuellem MRT und Echokardiografie wurden retrospektiv eingeschlossen. Lokalisation und Ausmaß des MI in der MRT wurden mit der linksventrikulären Funktion in der MRT und der Mitralklappeninsuffizienz in der Echokardiografie korreliert. Vorhandensein, Lokalisation und Ausmaß eines PMI in der Late-Gadolinium Enhancement (LGE-) MRT wurden mit diesen Funktionsparametern korreliert und mit Patienten mit chronischem MI ohne PMI verglichen.

**Ergebnisse** Bei 11 von 48 Patienten (23 %) konnte mittels LGE-MRT ein PMI nachgewiesen werden. Eine ischämische Mitralklappeninsuffizienz bestand bei 8/11 Patienten mit PMI (73 %) und bei 22/37 Patienten mit MI ohne PMI (59 %). Es ergab sich kein signifikanter Unterschied hinsichtlich Lokalisation und Ausmaß des MI und der Mitralklappeninsuffizienz zwischen Patienten mit und ohne PMI. Bei 4/4 Patienten mit vollständigem und bei 4/7 Patienten mit partiellem PMI bestand eine Mitralklappeninsuffizienz. Das mittlere enddiastolische Volumen war bei Patienten mit Mitralklappeninsuffizienz erhöht.

**Schlussfolgerung** Es ergibt sich kein eindeutiger Zusammenhang zwischen dem Vorhandensein eines PMI und der Entwicklung einer ischämischen Mitralklappeninsuffizienz. Bei Patienten mit vollständigem PMI scheint aufgrund einer Unterbrechung der Kontinuität vitalen Gewebes des Papillarmuskel-Chorda-Mitralklappen Komplex ein erhöhtes Risiko für das Auftreten einer ischämischen Mitralklappeninsuffizienz zu bestehen. Der Schweregrad der Mitralklappeninsuffizienz ist im Vergleich zu Patienten mit partiellem oder ohne PMI nicht erhöht.

### Kernaussagen

- Kein Zusammenhang zwischen Vorhandensein eines Papillarmuskelfarktes und ischämischer Mitralklappeninsuffizienz
- Vollständiger Papillarmuskelfarkt führt zu Funktionsstörung und ist mit ischämischer Mitralklappeninsuffizienz assoziiert
- Schweregrad der Mitralklappeninsuffizienz bei vollständigem Papillarmuskelfarkt nicht höher

### ABSTRACT

**Objective** Ischemic mitral regurgitation is a predictor of heart failure resulting in increased mortality in patients with chronic myocardial infarction. It is uncertain whether the presence of papillary muscle (PM) infarction contributes to

the development of mitral regurgitation in patients with chronic myocardial infarction (MI). The aim of the present study was to assess the correlation of PM infarction depicted by MRI with mitral regurgitation and left ventricular function.

**Methods and Materials** 48 patients with chronic MI and recent MRI and echocardiography were retrospectively included. The location and extent of MI depicted by MRI were correlated with left ventricular function assessed by MRI and mitral regurgitation assessed by echocardiography. The presence, location and extent of PM infarction depicted by late gadolinium enhancement (LGE-) MRI were correlated with functional parameters and compared with patients with chronic MI but no PM involvement.

**Results** PM infarction was found in 11 of 48 patients (23%) using LGE-MRI. 8/11 patients (73%) with PM infarction and 22/37 patients (59%) without PM involvement in MI had ischemic mitral regurgitation. There was no significant difference between location, extent of MI and presence of mitral regurgitation between patients with and without PM involvement in myocardial infarction. In 4/4 patients with complete and in 4/7 patients with partial PM infarction, mitral regurgi-

tation was present. The normalized mean left ventricular end-diastolic volume was increased in patients with ischemic mitral regurgitation.

**Conclusion** The presence of PM infarction does not correlate with ischemic mitral regurgitation. In patients with complete PM infarction and consequent discontinuity of viable tissue in the PM-chorda-mitral valve complex, the probability of developing ischemic mitral regurgitation seems to be increased. However, the severity of mitral regurgitation is not increased compared to patients with partial or no PM infarction.

#### Key points

- No correlation between ischemic mitral regurgitation and presence of papillary muscle infarction
- Complete papillary muscle infarction results in dysfunction associated with ischemic mitral regurgitation
- Severity of mitral regurgitation not increased in patients with complete PM infarction

#### Citation Format

- Bretschneider C, Heinrich H, Seeger A et al. Impact of Papillary Muscle Infarction on Ischemic Mitral Regurgitation Assessed by Magnetic Resonance Imaging. *Fortschr Röntgenstr* 2018; 190: 42–50

## Introduction

Myocardial infarction (MI) is frequently associated with ischemic mitral regurgitation [1]. Acute mitral regurgitation necessitating immediate surgery due to complete or sequential papillary muscle (PM) rupture is a rare major adverse cardiac event [2, 3]. In the majority of patients, ischemic mitral regurgitation develops gradually due to remodeling of the ischemic myocardium and altered hemodynamic conditions in the left ventricle [4]. Additionally, PM infarction may contribute to the development of ischemic mitral regurgitation by tethering of the chordae and subsequent dysfunction of the PM-chorda-mitral valve complex [5]. Ischemic mitral regurgitation is associated with cardiac morbidity and mortality and is therefore regarded as an unfavorable prognostic factor [6].

Although PM viability is regarded as a prognostic factor when considering mitral valve replacement or repair, its impact on the development of ischemic mitral regurgitation is uncertain [3, 7–10]. In comparison to intraoperative findings, the extent of PM damage is frequently underestimated by echocardiography [11]. Thus, patients with ischemic mitral regurgitation may benefit from magnetic resonance imaging (MRI) prior to mitral valve repair or replacement as it provides reliable information on left ventricular function, myocardial viability and PM morphology [8, 12–14].

The aim of the presented study was to correlate the frequency of PM involvement depicted by LGE MRI in patients with chronic MI with the presence and extent of ischemic mitral regurgitation assessed by echocardiography.

## Method and Materials

### Patient group

280 patients with MI depicted by LGE-MRI undergoing cardiac MRI for clinical reasons were retrospectively screened. Ultimately 48 patients met the inclusion criteria. Patient characteristics and medication are tabulated in ► **Table 1**.

### Inclusion criteria

The inclusion criteria were: proven single event of MI clearly related to one cardiac region and more than three months prior to cardiac MRI, current echocardiography and patient age between 18 and 80 years.

### Exclusion criteria

The exclusion criteria were: aortic valve insufficiency grade 2 or higher, MI involving more than one cardiac region, known mitral valve leaflet pathology, ventricular or atrial septum defect, and general contraindications for MRI.

Ultimately 48 patients meeting the inclusion criteria could be included retrospectively. The reason for the exclusion of 232 patients was incompleteness of essential data: unknown date of MI, no CK values of acute MI on record, no contemporary echocardiography, no assessment of mitral valve function on record.

### Patient characteristics

Clinical data including arterial hypertension, hyperlipoproteinemia, diabetes mellitus, nicotine consumption and body mass

► **Table 1** Risk factors for myocardial infarction and cardiac-related medication in the study group.

► **Tab. 1** Risikofaktoren für einen Myokardinfarkt und medikamentöse Therapie der Studienpopulation.

	29 patients with mitral regurgitation	19 patients without mitral regurgitation	p-value
age (years)	59.9 ± 11.8	63 ± 9.2	0.36
male sex	24	17	0.55
female sex	5	2	0.55
arterial hypertension	20	15	0.46
diabetes mellitus	5	4	0.75
nicotine abuse	16	9	0.61
familial disposition	13	8	0.86
hyperlipoproteinemia	19	11	0.61
BMI (kg/m <sup>2</sup> )	25.6 ± 2.6	25 ± 3	0.77
CK <sub>max</sub> (U/l)	1835.8 ± 1912.5	1347 ± 1622.7	0.37
thrombocyte aggregation inhibitor	27	18	0.84
vitamin K antagonist	1	4	0.07
beta blocker	27	17	0.69
Ca antagonist	1	0	0.56
ACE inhibitor	21	15	0.62
angiotensin antag.	4	3	0.86
antianginosum	5	4	0.75
diuretic	17	10	0.69
CSE inhibitor	27	19	0.34
other	21	10	0.18

Most patients were treated with a combination of antihypertensive and anticoagulant drugs. Non-cardiac-related medication indicated as other includes medication for diabetes, thyroid dysfunction, reflux esophagitis, and gout. BMI – body mass index, CK – creatine kinase, MI – myocardial infarction, Ca – calcium, ACE – angiotensin converting enzyme, CSE – cholesterol synthesis enzyme, angiotensin antag – angiotensin antagonists. Antianginosum refers to nitrate.

Die meisten Patienten wurden mit einer Kombination aus blutdrucksenkenden und gerinnungshemmenden Medikamenten behandelt. Die nicht Herz bezogene Medikation wird untere sonstige angegeben und beinhaltet Medikamente zur Behandlung von Diabetes, Schilddrüsenfunktionsstörungen, Refluxösophagitis, Gicht. BMI – Body Mass Index, CK – Creatinkinase, MI – Myokardinfarkt, Ca – Kalzium, ACE – Angiotensin Converting Enzyme, CSE – Cholesterol Synthesis Enzyme, angiotensin antag – Angiotensin Antagonisten. Antianginosum bezieht sich auf Nitrate.

index (BMI) were recorded according to the patient file. The maximum serum creatinine kinase (CK<sub>max</sub>) recorded during acute MI was correlated with the extent of chronic MI depicted by LGE MRI. CK<sub>max</sub> was defined as the highest creatine kinase value on record measured in blood samples taken from the patient during hospitalization for acute myocardial infarction. The CK<sub>max</sub> value was considered representative for the size of the MI.

## MR imaging

All MR examinations were performed on a 1.5 T imager (Magnetom Sonata / Avanto Siemens Healthineers, Erlangen, Germany), using a dedicated multichannel receiver coil. The MR imaging protocol included cine steady-state free-precession (SSFP) sequences in a 4-chamber view, 2-chamber view as well as in short-axis views from mitral valve to apex. The sequence parameters were as follows: TR 39.9 ms, TE 1.12 ms, slice thickness 6 mm, field of view

300 – 360 mm, flip angle 70°, matrix 192\*100 and a T1w inversion recovery (IR) GRE sequence in corresponding slice location and orientation to the cine SSFP sequences (TR 11 ms, TE 44 ms, slice thickness 6 mm, flip angle 25°, baseline matrix 265) 15 minutes after intravenous contrast medium (0.15 mmol Gadobutrol/kg bodyweight, Bayer Vital, Leverkusen, Germany) injection. By using an inversion time localizer sequence, the individual inversion time (TI) was determined to optimally suppress the signal from the normal myocardium. The mean interval between MI and MR examination was 1051 ± 1728 days. The mean interval between MRI and echocardiography was 81 ± 71 days.

## Image interpretation

MR images were assessed by two independent experienced readers for the presence, extent and location of PM infarction (CB: eight years of cardiac MRI experience, BK: thirteen years of cardiac

MRI experience). Quantitative assessment of left ventricular function and size of the MI was performed by two readers in consensus (CB, HH).

### Left ventricular function

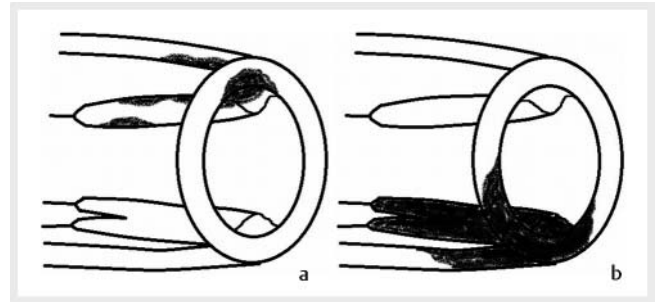
Dedicated software (ARGUS<sup>®</sup>, Siemens Healthineers, Erlangen, Germany) was used for post-processing and determination of cardiac functional parameters (ejection fraction (EF), end-diastolic volume (EDV), end-systolic volume (ESV), stroke volume (SV)). For the assessment of functional parameters, the modified Simpson's rule was used, based on the manually segmented left ventricular contours in end-diastolic and end-systolic short-axis images [15]. All parameters are given as normalized values (normalized on patient's body surface area (BSA)).

### Myocardial viability

Image evaluation included detection of PM involvement and transmural extent of MI. The myocardium was defined as infarcted if regional late contrast enhancement was observed 15 minutes after the injection of contrast medium. PM involvement was assessed regarding the extent and location. PM infarction was differentiated as anterior and posterior papillary muscle infarction and complete or partial infarction (► Fig. 1). Hyperenhancement on LGE images of the whole cross-sectional area of the involved PM was classified as complete papillary muscle infarction since viability of the PM-chorda unit was not preserved in its continuity (► Fig. 1b). Hyperenhancement of a part of the cross-sectional area of the involved PM was classified as partial papillary muscle infarction with preserved continuity of the viability of the PM-chorda unit (► Fig. 1a). Hyperenhancement of the PM surface only was not regarded as PM infarction as this could arise from enhancement of the normal endocardium which is also present in patients without MI. For quantitative assessment of MI, manual planimetry of hyperenhancement representing MI on LGE images was performed on all slices on which MI was identified and multiplied by the distance between the slice center positions to calculate volumes [15].

### Statistical analysis

Data were statistically evaluated using dedicated software (JMP, SAS Institute Inc., North Carolina, USA). If not otherwise indicated, results are given as mean ± standard deviation. To test for a correlation of PM infarction and MI size as well as CK<sub>max</sub>, both parameters were compared in patients with and without PM involvement. As data did not show normal distribution, logarithmic values were used. To compare patients with and without PM involvement, Student's t-test was applied. The correlation index for CK<sub>max</sub> values and MI size depicted by LGE was calculated. Left ventricular functional parameters including EF, EDV, ESV, and SV were compared to test for differences between patients with and without PM involvement. Functional parameters were normalized to body surface to reduce a bias arising from patient size. To test for differences in left ventricular function and patient age, Student's t-test was applied. These functional parameters were also compared for patients with and without mitral regurgitation to analyze the impact of ischemic mitral regurgitation on left



► Fig. 1 a The schematic drawing depicts a partial infarction of the anterior PM (black) with preserved continuity of viable tissue on the base of a subendocardial MI of the anterior wall. b The schematic drawing depicts complete infarction of the posterior PM on the base of a transmural MI of the posterior wall. The continuity of viable tissue in the PM-chorda-mitral valve complex is not preserved.

► Abb. 1 a Die Schemazeichnung zeigt einen teilweisen Infarkt des vorderen Papillarmuskels (schwarz) mit erhaltener Kontinuität vitalen Gewebes auf dem Boden eines subendokardialen Vorderwandinfarkts. b Die Schemazeichnung zeigt einen vollständigen Infarkt des hinteren Papillarmuskels auf dem Boden eines transmuralen Hinterwandinfarkts. Die Kontinuität vitalen Gewebes der Papillarmuskel-Chorda-Mitralklappen Einheit ist nicht erhalten.

ventricular function assessed by MRI. To test for differences in the frequency and degree of ischemic mitral regurgitation and transmural extent of MI between patients with and without PM infarction, the Mann-Whitney U-test was applied. P-values < 0.05 were considered significant.

## Results

The mean age was 59.4 ± 13.2 years for patients with PM infarction and 62 ± 10.1 years for patients without PM infarction, p = 0.55, which is not a significant difference.

### Left ventricular function

Results of the functional analysis are tabulated in ► Table 2, 3. There are no significant differences for patients with and without PM infarction regarding left ventricular function. The mean left ventricular ESV is moderately increased in patients with PM infarction (► Table 2). In contrast, the comparison of functional parameters between patients with and without mitral regurgitation reveals a significantly increased ESV in patients with mitral regurgitation whereas the other parameters do not differ significantly (► Table 3). The degree of ischemic mitral regurgitation did not differ significantly between patients with and without PM involvement (► Table 2). However, regarding only patients with PM infarction, ischemic mitral regurgitation is present in four of four patients (100%) with complete PM infarction, whereas ischemic mitral regurgitation in patients with partial PM infarction is present in four of seven patients (57%). Ischemic mitral regurgitation was found in 22 of 37 patients without PM infarction (59%).

► **Table 2** There is no significant difference regarding frequency and degree of ischemic mitral regurgitation as well as size and transmurality of myocardial infarction and CK<sub>max</sub> values between patients with (PM+) and without (PM-) papillary muscle involvement. The comparison of the left ventricular function parameters indicates no significant difference. Only the mean left ventricular endsystolic volume is moderately increased in patients with papillary muscle involvement.

► **Tab. 2** Es besteht kein signifikanter Unterschied bezüglich Häufigkeit und Grad der Mitralinsuffizienz sowie der Infarktgröße und Transmuralität sowie der CK<sub>max</sub> Werte zwischen Patienten mit (PM+) und ohne (PM-) Papillarmuskel Beteiligung. Der Vergleich der linksventrikulären Funktionsparameter zeigt keinen signifikanten Unterschied, lediglich das linksventrikuläre endsystolische Volumen ist bei Patienten mit PM Infarkt leicht erhöht.

	PM infarction	no PM infarction	p-value
mitral regurgitation	8 (73%)	22 (59%)	0.44
grade 1	5	15	0.690
grade 1 – 2	3	4	0.205
grade 2	0	3	0.103
EDV (ml)/ BSA	79 ± 31	66 ± 20	0.205
ESV (ml)/ BSA	50 ± 25	38 ± 18	0.069
EF (%)	50 ± 11	52 ± 10	0.424
SV (ml)/ BSA	40 ± 9	36 ± 9	0.194
MI size (ml)	14.7 ± 12.8	12.1 ± 8.1	
logarithmic MI size	2.5 ± 0.7	2.2 ± 0.3	0.351
transmural MI	8	22	0.440
CK <sub>max</sub> (U/l)	1924 ± 2344	1551 ± 1628	0.835

► **Table 3** The mean left ventricular ESV is significantly increased in patients with ischemic mitral regurgitation compared to patients without mitral regurgitation. There is no significant difference regarding the other functional parameters.

► **Tab. 3** Das mittlere linksventrikuläre ESV ist bei Patienten mit ischämischer Mitralinsuffizienz signifikant erhöht gegenüber Patienten ohne Mitralinsuffizienz. Die übrigen Funktionsparameter weisen keine statistisch signifikanten Unterschiede auf.

	mitral regurgitation	no mitral regurgitation	p-value
EDV (ml)/ BSA	69 ± 28	69 ± 13	0.94
ESV (ml)/ BSA	47 ± 23	32 ± 10	0.007
EF (%)	50 ± 9	54 ± 11	0.120
SV (ml)/ BSA	37 ± 9	37 ± 8	0.94

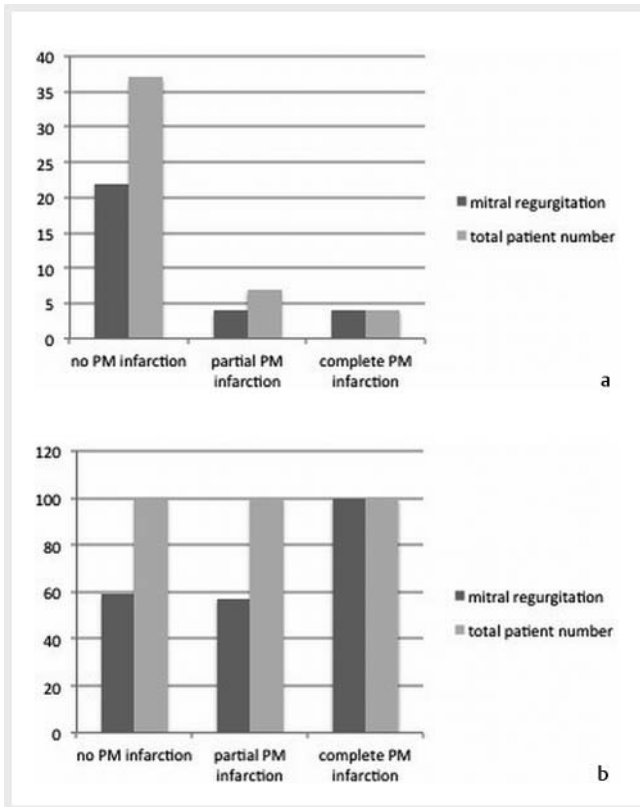
## Myocardial viability

Results of the myocardial viability analysis are tabulated in ► **Table 2**. PM infarction depicted by LGE was found in 11 of 48 patients (► **Fig. 2–4**). Neither the size of the MI depicted by LGE MRI nor transmural extent nor CK<sub>max</sub> values differed significantly between patients with and without PM involvement (► **Table 2**). A moderate correlation of  $r = 0.407$  ( $p = 0.0045$ ) was found between mean CK<sub>max</sub> and mean infarction size. The distribution and extent of papillary muscle infarction are tabulated in ► **Table 4**.

## Discussion

Ischemic mitral regurgitation is associated with increased morbidity and mortality and is consequently regarded as an unfavorable prognostic factor [6]. Whether ischemic mitral regurgitation arises from dysfunction of the mitral valve complex due to PM infarction or is an effect of left ventricular remodeling is uncertain [5]. In the present study no difference between patients with and without PM infarction could be found regarding frequency and degree of ischemic mitral regurgitation as well as left ventricular function and myocardial viability. Patients with MI of the complete cross-sectional area of PM were more frequently affected by ischemic mitral regurgitation than patients with only partial PM infarction although there was no difference in its severity. Patients with partial PM infarction did not differ from patients with MI other than a lack of PM involvement regarding ischemic mitral regurgitation.

Compared to results published by Tanimoto et al. [17] reporting a prevalence of 40%, PM infarction was observed less frequently in the present study with a prevalence of 23%. These results are more in line with a frequency of 19–32% as published in autopsy studies [18]. As PM involvement correlates with the size of the MI, the explanation for the higher prevalence of PM infarction in the Tanimoto study is probably the larger size of MI reflected by markedly higher CK<sub>max</sub> values. Tanimoto et al. conclude that ischemic mitral regurgitation is brought about by left ventricular remodeling, and there is no evidence of a contribution of PM infarction. However, they assessed only the presence of PM infarction and the size of the MI, whereas the present study analyzed the extent of PM infarction in order to assess its impact on



► **Fig. 2** **a** Frequency of ischemic mitral regurgitation correlated with the number of patients with complete, partial and no PM infarction indicated as number of patients. **b** Proportion of patients with ischemic mitral regurgitation indicated as percentage of 100% for each group (complete, partial and no PM infarction).

► **Abb. 2** **a** Häufigkeit der ischämischen Mitralinsuffizienz bei Patienten mit vollständigem, teilweisen und keinem Papillarmuskelfarkt angegeben als Patientenzahl. **b** Anteil der Patienten mit ischämischer Mitralinsuffizienz angegeben als Prozentsatz von 100% für jede Patientengruppe (vollständiger, teilweiser, kein Papillarmuskelfarkt).

PM and mitral valve function. In all four patients with complete PM infarction (► **Fig. 4**), mitral regurgitation was present, compared to only four of seven patients with partial PM infarction (► **Fig. 3**). The difference between patients with MI of the complete cross-sectional area and patients with only partial PM infarction suggests a correlation with the development of ischemic mitral regurgitation. As there is no difference in the frequency of ischemic mitral regurgitation between patients with partial PM infarction (57%) and patients without PM involvement (59%), the presence of partial PM infarction but preserved viable mitral-chorda-papillary muscle continuity seems to have no adverse effect on mitral valve function. These results suggest a functional impairment of the mitral-chorda-papillary muscle complex if no viable continuity is preserved due to complete PM infarction although the necrotic PM is still in place. As the degree of ischemic mitral regurgitation did not differ between patients with complete, partial or no PM infarction, complete PM infarction seems to be associated with an increased prevalence of mitral regurgitation but does not result in high-grade mitral regurgitation. A potential rea-

► **Table 4** The distribution analysis of PM infarction indicates a preference for the posterior PM which is more frequently affected. In two patients both the anterior and posterior PM were affected thus resulting in four patients with anterior PM and nine patients with posterior PM involvement and in summary eleven patients with PM infarction.

► **Tab. 4** Die Verteilungsanalyse zeigt eine Bevorzugung des hinteren PM der häufiger betroffen ist. Bei zwei Patienten sind sowohl der hintere wie auch der vordere PM betroffen wodurch sich eine Gesamtzahl von elf Patienten mit PM Infarkt bei vier Patienten mit vorderer und neun Patienten mit hinterer PM Beteiligung ergibt.

	anterior PM	posterior PM
patients	4 (36%)	9 (82%)
complete MI	0	4 (44%)
partial MI	4 (100%)	5 (56%)
mitral regurgitation	2 (50%)	5 (56%)

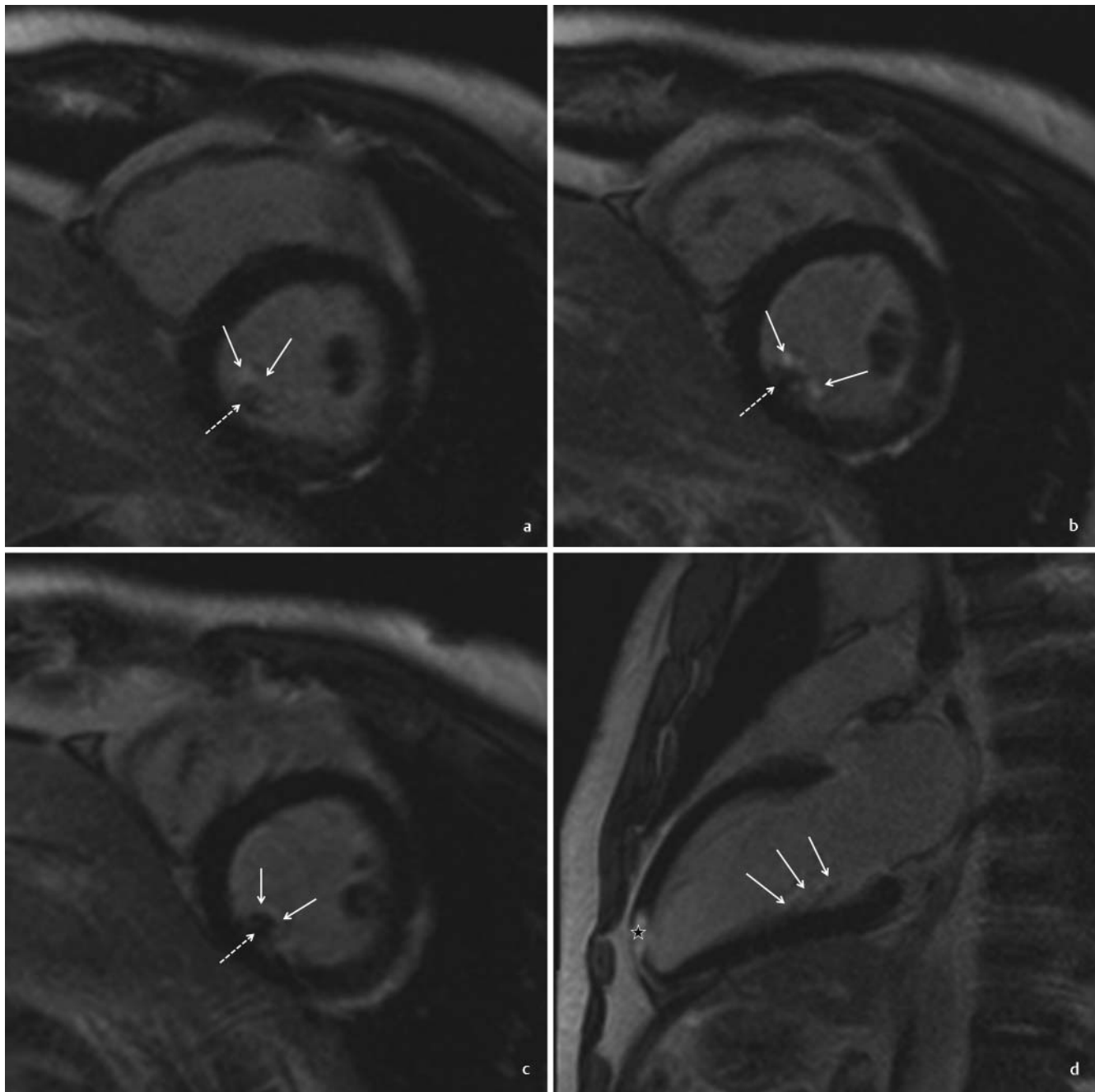
son is that complete PM infarction impairs the function of the PM-chorda-mitral valve complex due to discontinuity of viable tissue but the fact that the necrotic tissue is still in place provides residual function, thus preventing high-grade mitral regurgitation which in contrast occurs in the event of PM rupture.

These findings are supported by the fact that preservation of the sub-valvular apparatus and papillary muscle continuity contributes to the improvement of the prognosis in patients with ischemic mitral regurgitation [19]. Consequently, LGE-MRI could be a suitable approach for identifying patients at risk for the development of ischemic mitral valve regurgitation, based on the extent of PM involvement [11].

In contrast to the current literature, the size of the MI as well as  $CK_{max}$  did not differ significantly between patients with and without PM involvement although both were slightly higher in patients with PM involvement [20]. This might be a result of the number of patients with PM involvement being too small to reach significance.

Ischemic mitral regurgitation was found in 73% of patients with PM infarction and in 59% of patients with MI but no sign of PM involvement. Ischemic mitral regurgitation after MI is frequently observed and is usually mild [8, 21, 22]. In our study group, second-grade mitral regurgitation was found in 3 of 29 patients with ischemic mitral regurgitation compared to 10% in the published data [8]. Yet, in patients with ischemic mitral regurgitation, even a mild degree of mitral regurgitation is strongly associated with an unfavorable prognosis. On the other hand, mild mitral regurgitation is frequently observed in about 45% of people older than 50 years [23]. Consequently, difficulties in differentiating between ischemic mitral regurgitation after MI and preexisting mitral regurgitation may arise as the mean age of patients was 61 years and mitral regurgitation could therefore be expected in a significant percentage.

Ischemic mitral regurgitation is believed to initiate myocardial remodeling associated with left ventricular dilatation due to increased diastolic wall stress and decreased contractility with a



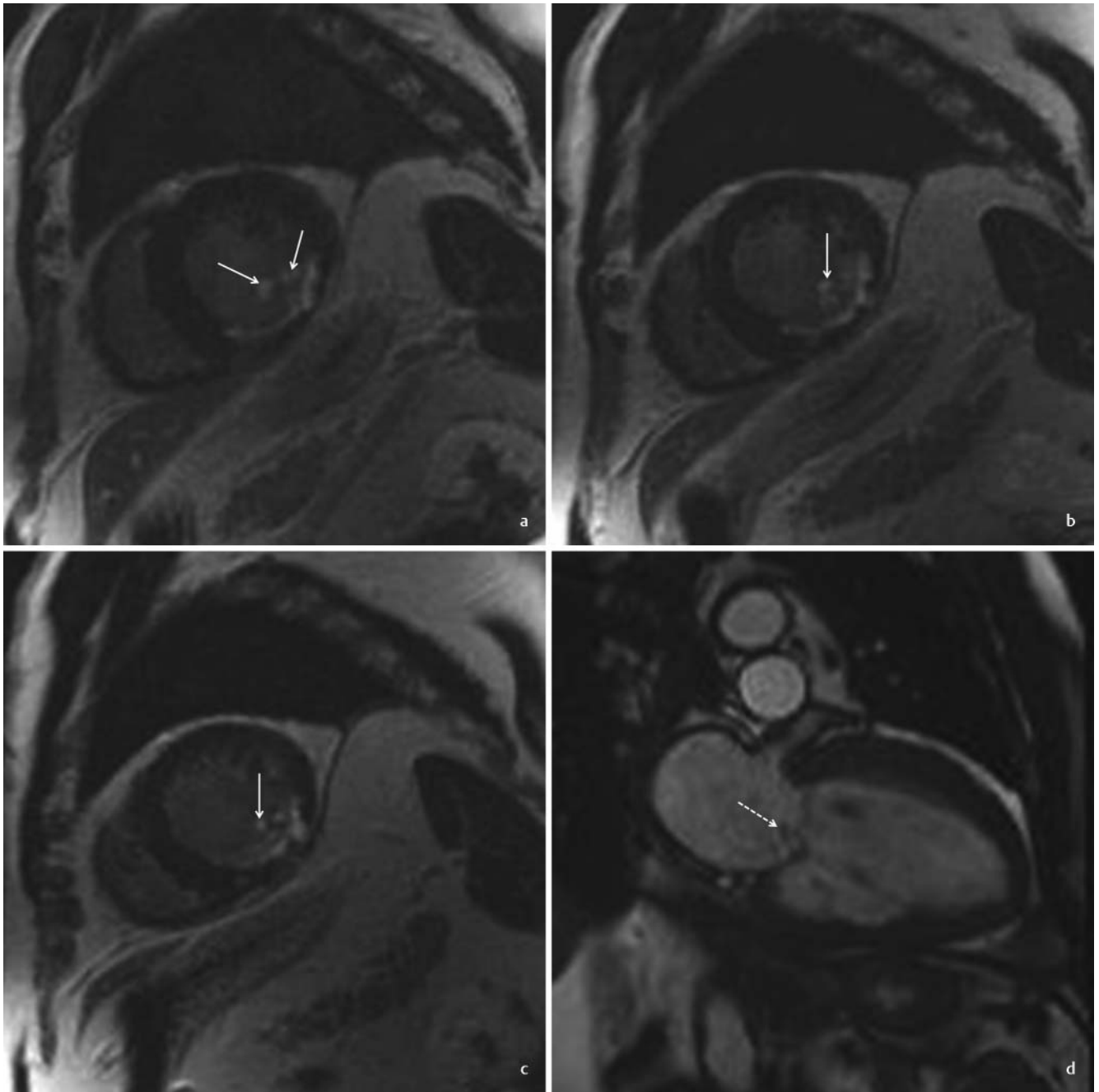
► **Fig. 3** LGE short-axis views **a–c** and long-axis view **d** acquired in a 44-year-old male patient with transmural myocardial infarction of the apex (**d**, asterisk). The posterior papillary muscle exhibits superficial contrast enhancement (**a–d**, arrows) with a viable core (**a–c**, dashed arrows) representing partial ischemic necrosis.

► **Abb. 3** Die LGE Kurzachsenschnitte **a–c** und Langachsenschnitt **d** eines 44-jährigen Patienten zeigen einen transmuralen Myokardinfarkt der Herzspitze (**d**, Stern). Der hintere Papillarmuskel weist eine oberflächlich vermehrte Kontrastmittelaufnahme (**a–c**, Pfeile) bedingt durch ischämische Nekrose mit einem intakten Kern (**a–c**, gestrichelte Pfeile) auf.

consecutively increased end-systolic volume [24, 25]. Our results are in concordance with these reports, as the end-systolic volume was significantly increased in patients with ischemic mitral regurgitation.

Published data indicate that PM infarction is usually the result of ischemia of the inferior and inferolateral left ventricular myocardium [17, 26]. Due to the vascular anatomy of the PM, the

anterior PM is much less frequently affected [11, 27]. The posterior PM was also more frequently affected, with nine patients compared to four with anterior PM involvement. Yet, the difference was lower compared to the published data, which referred however to a rupture of the PM, reporting a three-fold higher frequency.



► **Fig. 4** LGE short-axis views **a–c** and cine SSFP long-axis view **d** acquired in a 74-year-old male patient with transmural myocardial infarction of the inferior and inferolateral wall. The posterior papillary muscle exhibits contrast enhancement in all parts (**a–c**, arrows) representing complete ischemic necrosis. A first grade mitral regurgitation is displayed by a central systolic regurgitation jet on the cine SSFP image (**d**, dashed arrow).

► **Abb. 4** Die LGE Kurzachsenschnitte **a–c** und der cine SSFP Langachsenschnitt **d** eines 74-jährigen Patienten mit transmuralem Myokardinfarkt der inferioren und inferolateralen Wand zeigen eine vollständige ischämische Nekrose des hinteren Papillarmuskels (**a–c**, Pfeile). Der systolische Regurgitationsjet in der cine SSFP Bildgebung (**d**, gestrichelter Pfeil) zeigt eine erstgradige Mitralinsuffizienz.

The limitations of our study are the small number of patients identified to have PM infarction, thus restricting the potential to derive statistically valid conclusions regarding the contribution of PM infarction to the development of ischemic mitral regurgitation and to differentiate between ischemic mitral regurgitation due to left ventricular remodeling after MI. Secondly, there is no surgical or histopathological confirmation for the presence of PM infarction

depicted by LGE MRI. However, as the published data give evidence of an excellent correlation of LGE imaging of myocardial viability for the presence and extent of MI with histopathological results, this constitutes a minor limitation and justifies the assumption that LGE of PM represents ischemic necrosis due to MI [12, 28, 29]. Moreover, no patients with high-grade mitral regurgitation were included, thus representing a statistical bias.



High-grade mitral regurgitation in PM infarction usually results from acute PM rupture and is a major adverse cardiac event [30]. As it is a rare event necessitating immediate mitral valve repair or replacement, these patients are not referred to MRI. In the case of limited PM infarction, especially if restricted to the superficial part, difficulties may arise with respect to the differentiation of this from normal enhancement of the endocardium on LGE images.

In conclusion, there is no difference in the overall frequency of ischemic mitral regurgitation between patients with and without PM infarction. Compared to patients with partial or no PM infarction, the frequency of mitral regurgitation is increased in patients with complete PM infarction, but the severity does not differ. A potential reason is the impaired PM function due to the discontinuity of viable tissue in spite of preserved continuity of the PM-chorda-mitral valve complex resulting in increased frequency of light ischemic mitral regurgitation.

### Conflict of Interest

The authors declare that they have no conflict of interest.

### References

- [1] Lehmann KG, Francis CK, Dodge HT. Mitral regurgitation in early myocardial infarction. Incidence, clinical detection, and prognostic implications. TIMI Study Group. *Ann Intern Med* 1992; 117: 10–17
- [2] Schroeter T, Lehmann S, Misfeld M et al. Clinical outcome after mitral valve surgery due to ischemic papillary muscle rupture. *Ann Thorac Surg* 2013; 95: 820–824
- [3] De Canniere D, Vandenbossche JL, Nouar E et al. Clinical implications of preserving subvalvular apparatus during mitral valve replacement for acute ischemic papillary muscle rupture. *Ann Thorac Surg* 2016; 102: 305–308
- [4] Kalra K, Wang Q, McIver BV et al. Temporal changes in interpapillary muscle dynamics as an active indicator of mitral valve and left ventricular interaction in ischemic mitral regurgitation. *J Am Coll Cardiol* 2014; 64: 1867–1879
- [5] Bursi F, Enriquez-Sarano M, Jacobsen SJ et al. Mitral regurgitation after myocardial infarction: a review. *Am J Med* 2006; 119: 103–112
- [6] Grigioni F, Enriquez-Sarano M, Zehr KJ et al. Ischemic mitral regurgitation: long-term outcome and prognostic implications with quantitative Doppler assessment. *Circulation* 2001; 103: 1759–1764
- [7] Lancelotti P, Marwick T, Pierard LA. How to manage ischemic mitral regurgitation. *Heart* 2008; 94: 1497–1502
- [8] Nappi F, Nenna A, Spadaccio C et al. Predictive factors of long-term results following valve repair in ischemic mitral valve prolapse. *Int J Cardiol* 2016; 204: 218–228
- [9] Agricola E, Oppizzi M, Pisani A et al. Ischemic mitral regurgitation: mechanisms and echocardiographic classification. *Eur J Echocardiogr* 2008; 9: 207–221
- [10] David TE. Papillary muscle-annular continuity: is it important? *J Card Surg* 1994; 9: 252–254
- [11] Bouma W, Wijdh-den Hamer IJ, Koene BM et al. Long-term survival after mitral valve surgery for post-myocardial infarction papillary muscle rupture. *J Cardiothorac Surg* 2015; 10: 11
- [12] Kim RJ, Fieno DS, Parrish TB et al. Relationship of MRI delayed contrast enhancement to irreversible injury, infarct age, and contractile function. *Circulation* 1999; 100: 1992–2002
- [13] Kim RJ, Wu E, Rafael A et al. The use of contrast-enhanced magnetic resonance imaging to identify reversible myocardial dysfunction. *N Engl J Med* 2000; 343: 1445–1453
- [14] Hombach V, Grebe O, Merkle N et al. Sequelae of acute myocardial infarction regarding cardiac structure and function and their prognostic significance as assessed by magnetic resonance imaging. *Eur Heart J* 2005; 26: 549–557
- [15] Groth M, Muellerleile K, Klink T et al. Improved agreement between experienced and inexperienced observers using a standardized evaluation protocol for cardiac volumetry and infarct size measurement. *Fortschr Röntgenstr* 2012; 184: 1131–1137
- [16] Zoghbi WA, Enriquez-Sarano M, Foster E et al. Recommendations for evaluation of the severity of native valvular regurgitation with two-dimensional and Doppler echocardiography. *J Am Soc Echocardiogr* 2003; 16: 777–802
- [17] Tanimoto T, Imanishi T, Kitabata H et al. Prevalence and clinical significance of papillary muscle infarction detected by late gadolinium-enhanced magnetic resonance imaging in patients with ST-segment elevation myocardial infarction. *Circulation* 2010; 122: 2281–2287
- [18] Sugiura M, Ohkawa S, Kamata C et al. A clinicopathological study on the papillary muscle dysfunction. *Jpn Heart J* 1977; 18: 178–190
- [19] Wakasa S, Matsui Y. Benefits from submitral procedures for ischemic mitral regurgitation. *Gen Thorac Cardiovasc Surg* 2014; 62: 511–515
- [20] Steuer J, Bjerner T, Duvernoy O et al. Visualisation and quantification of peri-operative myocardial infarction after coronary artery bypass surgery with contrast-enhanced magnetic resonance imaging. *Eur Heart J* 2004; 25: 1293–1299
- [21] Bursi F, Enriquez-Sarano M, Nkomo VT et al. Heart failure and death after myocardial infarction in the community: the emerging role of mitral regurgitation. *Circulation* 2005; 111: 295–301
- [22] Feinberg MS, Schwammenthal E, Shlizerman L et al. Prognostic significance of mild mitral regurgitation by color Doppler echocardiography in acute myocardial infarction. *Am J Cardiol* 2000; 86: 903–907
- [23] Klein AL, Burstow DJ, Tajik AJ et al. Age-related prevalence of valvular regurgitation in normal subjects: a comprehensive color flow examination of 118 volunteers. *J Am Soc Echocardiogr* 1990; 3: 54–63
- [24] Spinale FG, Ishihara K, Zile M et al. Structural basis for changes in left ventricular function and geometry because of chronic mitral regurgitation and after correction of volume overload. *J Thorac Cardiovasc Surg* 1993; 106: 1147–1157
- [25] Corin WJ, Monrad ES, Murakami T et al. The relationship of afterload to ejection performance in chronic mitral regurgitation. *Circulation* 1987; 76: 59–67
- [26] Barbour DJ, Roberts WC. Rupture of a left ventricular papillary muscle during acute myocardial infarction: analysis of 22 necropsy patients. *J Am Coll Cardiol* 1986; 8: 558–565
- [27] Madu EC, D'Cruz IA. The vital role of papillary muscles in mitral and ventricular function: echocardiographic insights. *Clin Cardiol* 1997; 20: 93–98
- [28] Fieno DS, Kim RJ, Chen EL et al. Contrast enhanced magnetic resonance imaging of myocardium at risk: distinction between reversible and irreversible injury throughout infarct healing. *J Am Coll Cardiol* 2000; 36: 1985–1991
- [29] Kim RJ, Shah DJ. Fundamental concepts in myocardial viability assessment revisited: when knowing how much is “alive” is not enough. *Heart* 2004; 90: 137–140
- [30] French JK, Hellkamp AS, Armstrong PW et al. Mechanical complications after percutaneous coronary artery intervention in ST-elevation myocardial infarction (from APEX-AMI). *Am J Cardiol* 2010; 105: 59–63