

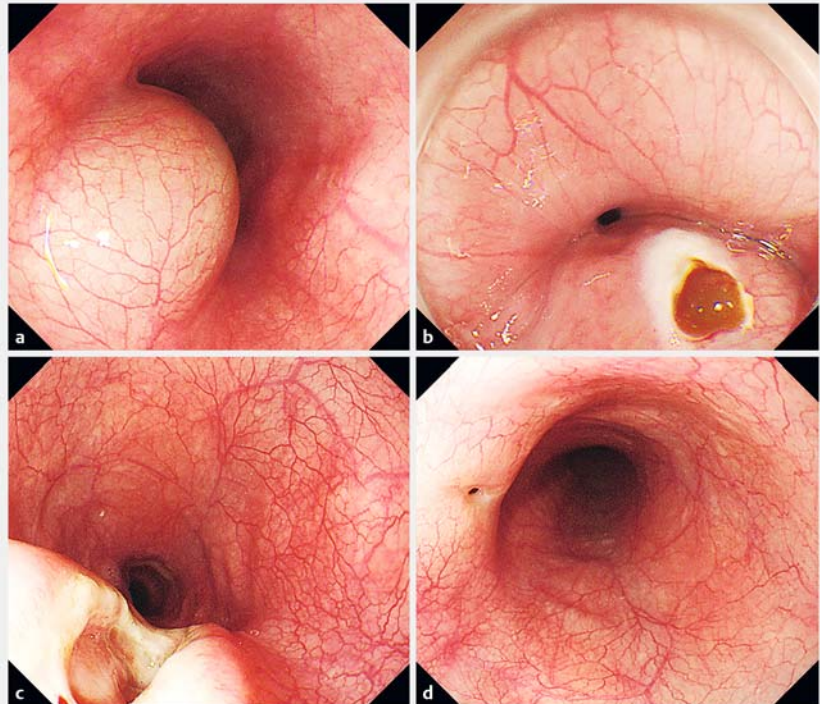
Endoscopic treatment of an esophageal duplication cyst

A 34-year-old woman was referred to our hospital because of the development of dysphagia and weight loss. Esophagogastroduodenoscopy (EGD) showed a submucosal tumor in the middle of the esophagus (► **Fig. 1 a**) and endoscopic ultrasonography (EUS) revealed a bilobed cystic lesion within the submucosal layer. Computed tomography (CT) of the chest showed a well-defined, bilobed, cystic mass in the mediastinum.

We performed endoscopic fenestration of the cyst. After we had made an initial incision with a needle knife (Olympus, Tokyo, Japan), brownish liquid contents flowed out of the cyst (► **Fig. 1 b**). The cyst was fenestrated with an insulation-tip knife (Olympus) (► **Fig. 1 c**; ► **Video 1**). The patient's symptoms completely disappeared and there was no evidence of recurrence on repeat EGD 2 months after the procedure (► **Fig. 1 d**).

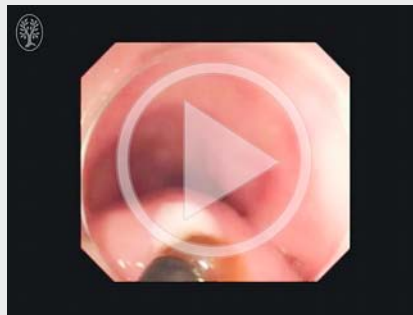
Duplication cysts of the esophagus are rare congenital anomalies that arise from an error in early embryonic development [1]. Duplication cysts are usually asymptomatic and, in most cases, are detected incidentally on a routine EGD. Abu-Zaid et al. previously reported a patient with an esophageal duplication cyst, which was treated by surgical excision [2]; however, treatment for this condition is currently moving from thoracotomy to endoscopic treatments [1]. Endoscopic treatments are considered when EUS demonstrates that cysts are localized within the submucosal layer and do not communicate with the deep muscular layer. Small esophageal duplication cysts can be completely resected with a standard polypectomy snare [3]. For larger cysts, careful fenestration with an insulation-tip knife is safe and effective [4].

Endoscopy_UCTN_Code_TTT_1AO_2AN



► **Fig. 1** Esophagogastroduodenoscopy images showing: **a** a submucosal tumor in the middle of the esophagus; **b** brownish liquid contents flowing out of the cyst after the initial incision; **c** the cyst following fenestration with an insulation-tip knife; **d** no evidence of recurrence 2 months after the procedure.

► VIDEO 1



► **Video 1:** Esophagogastroduodenoscopy showing a submucosal tumor in the middle of the esophagus, from which brownish liquid contents flowed after an initial incision had been made with a needle knife. The cyst was then fenestrated with an insulation-tip knife.

Competing interests

None

The Authors

**Jun Nishikawa¹, Misato Nagao², Ryo Ogawa²,
Sho Sasaki², Atsushi Goto², Takeshi
Okamoto², Isao Sakaida²**

- 1 Department of Laboratory Science,
Yamaguchi University Graduate School
Medicine, Ube, Japan
- 2 Department of Gastroenterology and
Hepatology, Yamaguchi University Graduate
School of Medicine, Ube, Japan

Corresponding author

Jun Nishikawa, MD, PhD

Department of Laboratory Science,
Yamaguchi University Graduate School of
Medicine, Minamikogushi 1-1-1 Ube,
Yamaguchi 755-8505, Japan
Fax: +81-83-6222835
junnis@yamaguchi-u.ac.jp

References

- [1] Wiechowska-Kozłowska A, Wunsch E, Majewski M et al. Esophageal duplication cysts: endosonographic findings in asymptomatic patients. *World J Gastroenterol* 2012; 18: 1270–1272

- [2] Abu-Zaid A, Azzam A. Images in clinical medicine. Esophageal duplication cyst. *NEJM* 2014; 371: e36
- [3] Joyce AM, Zhang PJ, Kochman ML. Complete endoscopic resection of an esophageal duplication cyst (with video). *Gastrointest Endosc* 2006; 64: 288–289
- [4] Ivekovic H, Jouret-Mourin A, Deprez PH. Endoscopic fenestration of esophageal duplication cysts. *Endoscopy* 2012; 44 (Suppl. 02): E404–E405

Bibliography

DOI <http://dx.doi.org/10.1055/s-0043-102395>
Endoscopy 2017; 49: E107–E108
 © Georg Thieme Verlag KG
 Stuttgart · New York
 ISSN 0013-726X