

Retrospective Evaluation of Percutaneous Access for TEVAR and EVAR: Time to Make it the Standard Approach?

Retrospektive Analyse des perkutanen Zuganges für TEVAR und EVAR: Zeit für den perkutanen Zugang als Standardvorgehen?

Authors

Rohit Philip Thomas¹, Tobias Kowald¹, Bernhard Schmuck¹, Osama Eldergash¹, Andreas Klausen², Valentin Dikov³, Jerry Easo³, Ajay Chavan¹

Affiliations

- 1 Institute for Diagnostic and Interventional Radiology, Klinikum Oldenburg AöR, Oldenburg, Germany
- 2 Department of Anaesthesia, Intensive care medicine, Emergency medicine and Pain therapy, University Hospital, Klinikum Oldenburg AöR, Oldenburg, Germany
- 3 Department of Cardiac Surgery, University Hospital, Klinikum Oldenburg AöR, Oldenburg, Germany

Key words

endovascular aortic repair, EVAR, TEVAR, percutaneous access

received 22.7.2016

accepted 28.12.2016

Bibliography

DOI <http://dx.doi.org/10.1055/s-0043-101387>

Published online: 2017 | Fortschr Röntgenstr 2017; 189: 347–355

© Georg Thieme Verlag KG Stuttgart · New York

ISSN 1438-9029

Correspondence

Dr. Rohit Philip Thomas
Institute for Diagnostic and Interventional Radiology,
Klinikum Oldenburg AöR
Rahel-Straus-Straße 10
26133 Oldenburg
Germany
Tel.: ++49/441/40 37 75 66
rohit0904@gmail.com

ZUSAMMENFASSUNG

Zielsetzung Überprüfung der Sicherheit von perkutanen endovaskulären aortalen Prozeduren und des Einflusses von Zugangscharakteristika auf Komplikationen.

Material und Methoden Alle Patienten, welche sich von Januar 2010 bis Mai 2016 einer perkutanen TEVAR, EVAR und FEVAR Prozedur unterzogen haben, wurden retrospektiv ausgewertet in Bezug auf die Komplikationshäufigkeiten unter Berücksichtigung der Zugangscharakteristika wie Gefäßdurchmesser, Ausmaß vorhandener Gefäßverkalkungen, Abstand Hautoberfläche zum Zugangsgefäß sowie des Verhältnisses von Gefäßdurchmesser zum Einführbesteck. Hämostase mit oder ohne manuelle Kompression innerhalb von

15 Minuten nach Gefäßnahtverschluss wurde als primäre Hämostase definiert.

Ergebnisse Insgesamt wurden 92 Patienten mit 142 femoralen Zugängen in die Studie eingeschlossen. Die Mediane Nachbeobachtungszeit betrug 28,13 Monaten (range 2,5–76,7 Monate; Mittel 32,39, SD 21,66 Monate). Die Größe des Einführsystems variierte zwischen 12 und 25F. Eine primäre Hämostase wurde in 97,1 % (138/142) der femoralen Zugänge erreicht; vier Zugänge (2,8 %) mussten chirurgisch verschlossen werden; bei allen 4 Zugängen waren die Einführbestecke $\geq 18F$, zwei der vier Leisten waren voroperiert. Spätkomplikationen waren Leistenhämatome ($n = 7$), Wundinfekt ($n = 1$), Skrotalhämatom ($n = 1$), Pseudoaneurysmen ($n = 4$) sowie Nachblutungen ($n = 4$), diese wurden bei 17 Zugangswegen (11,9 %) beobachtet, wovon 13 rein konservativ behandelt werden konnten. Auf Grund der niedrigen Komplikationsrate ergaben sich keine Zusammenhänge zwischen den Zugangscharakteristika und den stattgehabten Komplikationen.

Zusammenfassung Perkutane Stentgraftimplantationen sind unabhängig von der Größe des verwendeten Einführsystems und der vorliegenden Aortenpathologie sicher durchführbar. Es besteht eine hohe technische Erfolgsrate bei einer niedrigen Komplikationsrate. Ein Versagen des Nahtverschlussystems ist häufiger bei verwendeten Einführsystemen $\geq 18F$. Die Mehrzahl der Spätkomplikationen kann konservativ behandelt werden.

Kernaussagen:

- Perkutane Stentgraftimplantationen sind sicher durchführbar
- Die technische Erfolgsrate ist hoch und die Komplikationsrate niedrig
- Ein Versagen des Nahtverschlussystems im Einzelfall bedarf der chirurgischen Intervention

ABSTRACT

Introduction To evaluate the safety of percutaneous endovascular aortic repair and the relationship of access site characteristics to complications

Materials and Methods All patients undergoing percutaneous TEVAR, EVAR and FEVAR procedures from January 2010 to May 2016 were retrospectively analysed for incidence of complications and their relationship to various access site characteristics like access artery size, degree of vessel calcification, skin to artery distance and sheath to artery ratio. Hemostasis occurring within 15 min after suture closure with or without manual compression was defined as primary hemostasis.

Results 92 patients with 142 femoral access sites were included in the study. Median follow-up was 28.13 months (range 2.5–76.7 months, Mean 32.39, SD – 21.66 months). Introducer system size ranged from 12F to 25F. Primary haemostasis was achieved in 97.1 % (138/142) of the total femoral access sites. Four access sites (2.8 %) had to be closed

surgically; in all 4 cases the introducer systems was $\geq 18F$. Two of these access sites had been operated upon previously. Late complications including inguinal hematoma ($n = 7$), wound infection ($n = 1$), scrotal hematoma ($n = 1$), pseudoaneurysm ($n = 4$) and late bleeding ($n = 4$) occurred in 17 access sites (11.9%), of which 13 were managed conservatively. On account of the low complication rate, no correlation between the evaluated variables and observed complications could be established.

Conclusion Percutaneous endovascular aortic repair is feasible and safe irrespective of the size of the introducer sheath and the nature of aorto-iliac pathology. The technical success rate is high and the incidence of complications is low. Early complications are most often asso-

ciated with sheath sizes $\geq 18F$. The majority of the late complications can be treated conservatively.

Key points:

- Percutaneous endovascular aortic repair is feasible and safe.
- Technical success rate is high and complication rate is low.
- Vascular closure device failure in the occasional patient may necessitate surgical intervention.

Citation Format

- Thomas RP, Kowald T, Schmuck B et al. Retrospective Evaluation of Percutaneous Access for TEVAR and EVAR: Time to Make it the Standard Approach?. *Fortschr Röntgenstr* 2017; 189: 347–355

Introduction

Over the last two decades endovascular techniques have revolutionized the management of aortoiliac diseases. Endovascular repair of the thoracic (TEVAR) and the abdominal (EVAR) aorta often requires a large femoral access ranging from 14–26F [1]. Even today many centers still resort to femoral arteriotomy for endograft implantation. However, femoral arterial exposure is associated with possible complications like hematoma, seroma, lymphocele, infection and scar formation [2].

The Prostar XL as well as the Perclose Proglide devices (Abbott Vascular, Santa Clara, CA, USA) are presently the main suture mediated vascular closure devices (VCD) for the closure of femoral access sites larger than 10F. Various factors that could influence a poor outcome include groin scarring, calcification, vessel size, obesity as well as size of the introducer system [2–9].

The aim of the study was to retrospectively evaluate the safety of percutaneous endovascular aortic repair and to analyze the relationship of access site characteristics to complications for TEVAR, EVAR, and fenestrated endograft (FEVAR) procedures.

Materials and Methods

All percutaneous TEVAR, EVAR and FEVAR procedures performed in our institution from January 2010 to May 2016 were retrospectively identified via a query of the radiological information system (RIS) and included in the study cohort. Clinical information was obtained from the hospital information system (KIS, Cerner Medico, Cerner Germany). The hospital PACS system (Centricity PACS, GE Healthcare, Barrington, IL, USA) was used for evaluating the radiological images.

The patient demographics including age, gender and incidence of comorbidities like cardiovascular diseases, diabetes mellitus, hypertension and any history of previous groin surgery (inguinal hernia repair/vascular surgery involving the femoral vessels or the distal external iliac artery) were retrospectively collected from the admission data.

For assessing access site characteristics, the skin to common femoral artery distance in mm, the maximum diameter of common femoral artery and the degree of vessel calcification were retrospectively recorded from the pre-interventional CT examination. The above measurements were done as standard at a level approximately 1.5 cm cranial to the femoral bifurcation. The thickness of the subcutaneous tissue was determined by measur-

ing the distance from the skin to the common femoral artery. The degree of calcification was measured in the CT angiogram and divided into three categories according to the percentage of calcification in relation to the total wall circumference. These were graded as: grade I (<25%), grade II (26–50%) and grade III (>50%) (► Fig. 1). The location of the calcification, whether anterior or posterior, was not taken into consideration. In order to obtain the sheath size in mm, the outer French size was divided by 3. A ratio between the introducer sheath size and the common femoral artery in mm was then calculated. The introducer sheath size in all patients referred to the outer diameter.

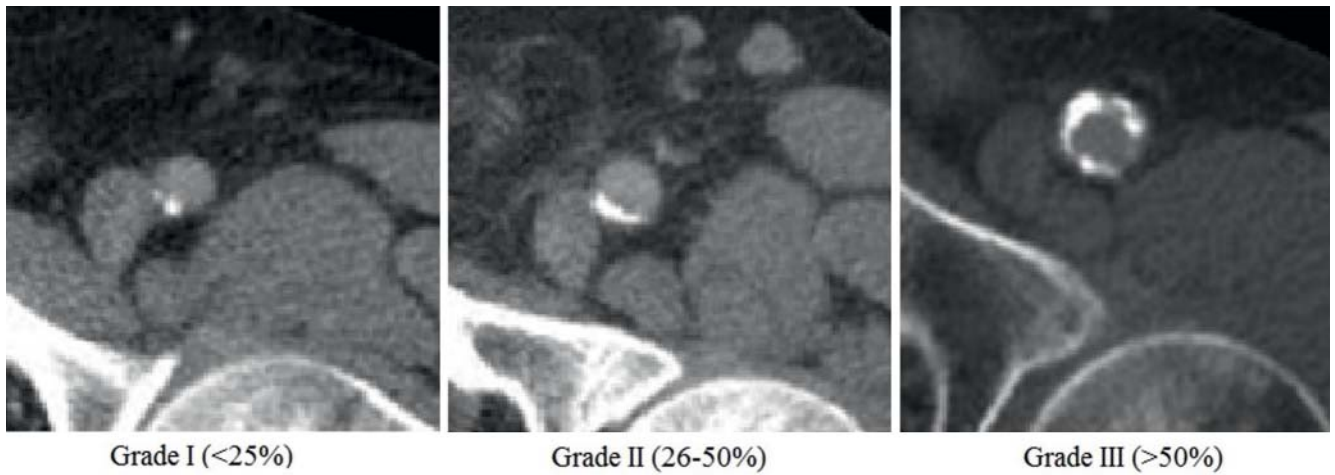
Percutaneous closure was defined as technically successful if satisfactory hemostasis was achieved either immediately after suture closure or within 15 minutes thereafter when supplemented merely by manual compression. Technical failure requiring surgical intervention was defined as persistent bleeding from the access site despite suture closure and manual compression ≥ 15 minutes.

Early complications were defined as those occurring during the procedure including failed primary hemostasis, while late complications referred to any event on further follow-up after primary hemostasis and after transfer of the patient from the angio suite.

The various complications were analyzed in relation to access vessel characteristics. All calculations in relation to vessel characteristics were analyzed per access site. Statistical package for Social Sciences for Windows (SPSS-Version 23, Chicago, IL, USA) was used for data processing and statistical analyses. The confidence interval (CI) of the incidence of complications in relation to the calcification score was estimated using the Pearson-Clopper method. The statistical analyses of the data were performed with the help of the Division of Epidemiology and Biometry, Department of Health Services Research, Faculty of Medicine and Health Sciences, Carl von Ossietzky University, Oldenburg.

Procedural details

Patients with anatomy unsuitable for TEVAR/EVAR/FEVAR, groin infection, coagulopathy, active systemic infection, connective tissue disorders or uncontrolled bleeding were excluded from the study group. In total, 10 patients underwent femoral arterial exposure during the study period. Of these, 5 patients were treated at the beginning of 2010 when we had just begun using the percutaneous approach. The involved surgeon wasn't confident about the safety of this approach and insisted on surgical expo-



Grade I (<25%)

Grade II (26-50%)

Grade III (>50%)

- ▶ **Fig. 1** Grades of calcification of the common femoral artery.
- ▶ **Abb. 1** Verkalkungsgrad der Arteria femoralis communis.

sure. The same holds true for the other 5 patients distributed over the remaining period. These were patients with fenestrated or branched endografts and the visiting proctor insisted on surgical exposure. Unsuitable anatomy of the access site was not a reason for resorting to surgical exposure.

Thoracic endografts with diameters between 24 and 44 mm and abdominal endografts with proximal diameters between 23 and 36 mm (all of varying length) were available around the clock. The available iliac limbs had diameters ranging between 10 and 24 mm.

Anticoagulants and anti-platelet agents were discontinued 5 days prior to elective procedures; this time span was bridged with subcutaneous low molecular weight heparin. Coagulation parameters in emergency patients were corrected with vitamin K or FFP (fresh frozen plasma). Antibiotic prophylaxis was carried out in all patients.

Intravenous heparin was administered (100 IU/kg) as a bolus during the procedure. Following endograft implantation, intravenous weight-proportional heparin infusion was continued for 24 hours except in cases with rupture. Oral acetyl salicylic acid (100 mg) or, alternatively, previous anticoagulant/anti-platelet therapy was started between 2 and 4 days after the procedure.

Altogether 4 interventional radiologists (IR), each with more than 5 years of experience with percutaneous interventions, performed the procedures. At least two of them were present in the majority of the cases, with the exception of emergency cases performed outside normal working hours.

All procedures were performed in the angiography suite (Siemens Axiom Artis) of the radiology department, which is a hygiene class II procedure room, but not a hybrid operating room (OR). Unpacked sterile surgical instruments were available in the procedure room. A surgeon and OR assistant were immediately reachable by telephone but were not constantly present in the angiography suite. In addition, a surgical team and a fully equipped OR were on standby to intervene, if necessary.

All thoracic endografts involving a large femoral access as well as the procedures for ruptured aneurysms were performed under general anesthesia (81 patients, 88%). With the introduction of low profile stent graft systems for infrarenal aortic aneurysms (Incraft, Cordis), 11 patients (12%) received the stent graft under local anesthesia since April 2015. For local anesthesia a dose of approximately 20 ml of lidocaine (2%) was used for each site.

Using the pubic symphysis and the anterior superior iliac spine (which define the course of the inguinal ligament), the preoperative CT scan (for the femoral bifurcation) as well as fluoroscopy for orientation, a standard femoral puncture at a 45 degree angle was performed under palpation without ultrasound guidance, a 5F sheath was initially introduced and a satisfactory puncture position was confirmed by a quick angiogram. In the solitary case with superficial femoral artery puncture, the 5F sheath was left in-situ and the common femoral artery was re-punctured under angiographic guidance. The sheath in the superficial femoral artery was removed at the end of the procedure and the access to the superficial femoral artery closed using a VCD (Exoseal 5F, Cordis).

After successful puncture of the common femoral artery, the subcutaneous tissue at the puncture site was prepared and widened along the sheath with the help of a needle holder. Two Prostar XL closure devices per site were then deployed at a 45 degree rotational angle with respect to each other over a standard hydrophilic coated (Terumo Corporation, Tokyo, Japan) guide wire. The Prostar XL (10F) device consists of a sheath, which contains two pairs of suture needles, a needle guide, which accurately controls the needles around the puncture site, and a rotating barrel, which receives the deployed needles (▶ **Fig. 2**). The sutures are drawn through the vessel wall from inside and externalized with the help of the needles (▶ **Fig. 3**).

After pre-placement of the sutures, a 10F sheath was introduced, over which a 0.035 inch super-stiff guide wire (Back-up Meier (Boston Scientific Corporation, Marlborough, MA, USA) or Lunderquist (Cook Medical, Bjaeverskov, Denmark)) was advanced into the thoracic aorta with the help of a diagnostic cath-

eter. Staged dilatation of the arteriotomy was performed up to 12F to reduce the traumatic effects of direct insertion of the stent graft.

After endograft implantation, the pre-placed sutures were knotted according to the technique suggested by the manufacturer. Manual compression was applied a few centimeters above the puncture site by the assistant, the endograft introducer sys-

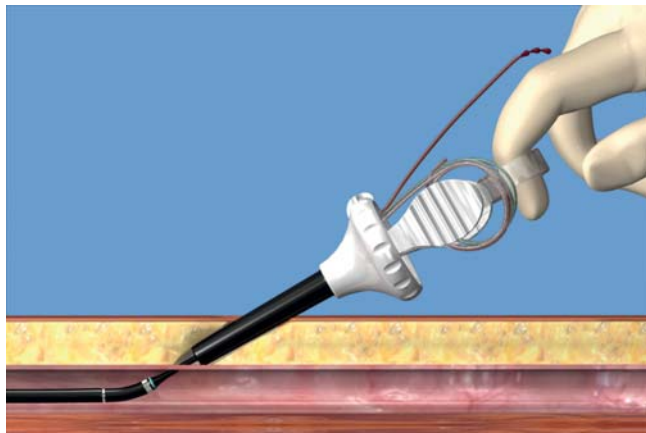
tem was removed and the sutures were pulled tight and closed by the IR. Since 2013, a guide wire (0.035 inch) is left in place until the first two sutures are closed. If adequate hemostasis was achieved, the guide wire was removed and the remaining sutures were closed. Manual compression was then performed if necessary. The duration of manual compression was recorded in all cases. If this duration exceeded 15 minutes, surgical repair of the access site was carried out.

All patients received a groin compression bandage for 24 hours. In-hospital follow-up included assessment of laboratory and clinical parameters and an ultrasound examination of the groin region. For further follow-up, control CT scans were carried out after 1, 6 and 12 months post-procedure and thereafter at yearly intervals.

Results

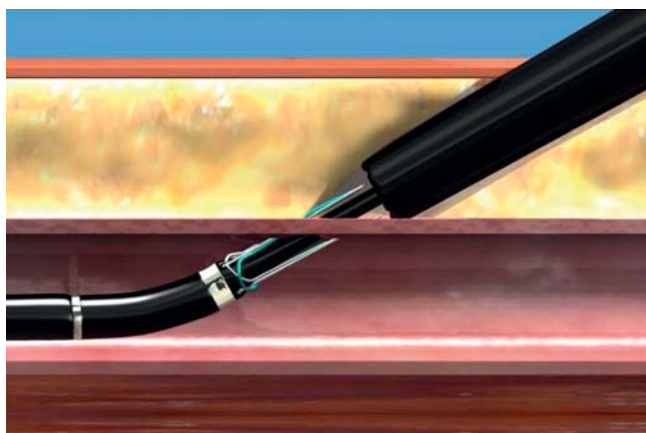
The patient demographics of the 92 patients (77 men, 15 women) are depicted in ► **Table 1**. The median age of the group was 71 years (range: 28 – 86 years). The indications for TEVAR, EVAR and FEVAR included a wide spectrum of aortoiliac diseases as illustrated in ► **Table 2**. In 92 patients a total of 94 endografts and 4 true lumen aortic stents were implanted. The introducer system size ranged from 12F to 25F. A list of the used endografts and stents with the range of introducer sizes is shown in ► **Table 3**.

A total of 142 femoral access sites were needed for the procedures in the 92 patients. Vascular surgery involving the femoral vessels or inguinal hernia repair had been previously carried out on 6 groins. The femoral access was from the left in 50 cases and the right in 92 cases. The descriptive statistics of the data in relation to the vessel characteristics are depicted in ► **Table 4**. The mean access artery diameter was 11.42 (SD: 2.22 mm, range: 7.2 – 18.3 mm). The access sheath diameter ranged from 12F to 25F (► **Fig. 4**). The vessel calcification scores were as follows: grade 1, n = 85, 59.8%; grade 2, n = 49, 34.5%; grade 3, n = 8, 5.6%. The mean skin-to-artery distance was 31.01 (SD: 10.38 mm, range 9 – 68.5 mm). The average sheath-to-artery ratio was 0.54 (SD: 0.15, range: 0.28 – 1.01).



► **Fig. 2** Prostar XL device introduced into the vessel. Correct device position before needle deployment denoted by the pulsatile marker outside. (Reprinted with permission from Abbott Vascular © 2015. All Rights reserved [rerif]).

► **Abb. 2** Ins Gefäß eingeführte Prostar XL System. Pulsatiler Außenmarker weist auf eine korrekte Position des Gefäßnahtsystems vor der Freisetzung der fadentragenden Nadeln. (Mit freundlicher Genehmigung von Abbott Vascular. © 2015. Alle Rechte vorbehalten [rerif]).



► **Fig. 3** The deployed needles bearing the sutures draw these through the vessel wall from inside. These sutures were externalized by pulling out the needles with the attached sutures through the device barrel. (Reprinted with permission from Abbott Vascular. © 2015. All rights reserved [rerif]).

► **Abb. 3** Die freigesetzten, fadentragenden Nadeln ziehen die Fäden von innen durch die Gefäßwand. Anschließend werden die Fäden mit Hilfe der Nadeln durch den Systemschaft nach außen gezogen. (Mit freundlicher Genehmigung von Abbott Vascular. © 2015. Alle Rechte vorbehalten [rerif]).

► **Table 1** Patient variables and their frequency in our patient cohort (n = 92).

► **Tab. 1** Patientenvariablen und deren Häufigkeiten in der Gruppe (n = 92).

Patient variables	Frequency	Percentage %
Male gender	77	83.6
Hypertension	59	64.1
Diabetes mellitus	11	11.9
Hyperlipidemia	32	34.7
Cardiovascular diseases	44	47.8
History of groin surgery (hernia repair, TEA)	6	6.5

Endograft implantation was successful in 91 of 92 patients. In one patient the endograft for thoracic aortic repair could not be introduced into the abdominal aorta across the iliac anastomosis of a preexisting infrarenal surgical Y prosthesis, despite successful introduction through the inguinal access site. Consequently, the graft introducer system was removed and the access site was closed by the pre-laid sutures. The endograft implantation was uneventful in the rest of the 91 patients. Primary hemostasis was achieved in 138 out of 142 access sites (97.1%). Time to hemosta-

sis was between 0 and 7 minutes in 121 access sites and between 7 and 15 minutes in 17 access sites. In 4 access sites with failed primary hemostasis despite 15 minutes of manual compression, surgical closure of the access site was performed in the angiography suite. This complication was not observed with introducer systems below 18F. In 3 sites the arterial access was sutured whereas 1 site required a Y surgical femoral prosthesis for the reconstruction of the femoral bifurcation. 2 of these 4 access sites had been operated upon previously.

As opposed to early complications, late complications at follow-up as noted either by clinical examination, ultrasound or CT (or a combination of these) were observed in altogether 17 access sites where introducer systems larger than 14F had been used. One of these access sites had been operated upon previously. The observed complications were as follows: inguinal hematoma in 7 patients, wound infection in 1 patient, scrotal hematoma in 1 case, pseudo-aneurysms in 4 patients (► Fig. 5) and late bleeding in 4 patients. Of these, 2 patients with pseudo-aneurysms and 2 patients with late bleeding complications required secondary surgical repair. All other complications were treated conservatively with compression bandage and additional antibiotics in the one patient with wound infection (► Table 5). The incidence of early and late complications in relation to the graft size is illustrated in ► Fig. 6. The incidence of complications in relation to the calcium score is shown in ► Table 6.

6 patients died in the hospital, 3 of whom had come in with rupture. The cause of death was not related to femoral access site complications in any of them. The causes of death included massive acidosis, low output syndrome, transmural cardiac ischemia and hemothorax. There were no further deaths at follow-up.

The estimated CIs, which were based on the low frequency of complications were very wide and overlapped each other, so that a significant relationship of the various calcification grades to the complications could not be shown (► Table 6). Similarly the estimation of a logistic regression of the complications in relation to

► **Table 2** Indications for TEVAR and EVAR procedures.

► **Tab. 2** Indikationen für die TEVAR und EVAR Prozeduren.

Pathology	Number of patients	
Type A Dissection following proximal aortic arch replacement	6	
Type B Dissection	Acute	8
	Chronic	5
Aneurysm rupture or impending rupture – thoracic aorta	13	
Thoracic intramural hematoma	3	
Juxtarenal aortic aneurysms –fenestrated endografts	3	
Infrarenal aortic aneurysm	With iliac branch	10
	Without iliac branch	33
Ruptured infrarenal aneurysm	2	
Iliac artery aneurysms	8	
Suspected aorto-ureteric fistula	1	
Total	92	

► **Table 3** Endografts and stents used for TEVAR & EVAR procedures.

► **Tab. 3** Im Rahmen der TEVAR & EVAR Prozeduren Verwendete Endografts und Stents.

Stentgraft/stent manufacturer	Graft/stent size	No. of patients		
Thoracic	Medtronic Valiant Captivia	22 – 25 F	32	
	Jotec GmbH Aortic Stent	16 F	4	
	Cook Medical – Zenith Alpha	16 – 20 F	5	
Abdominal	Medtronic	Endurant II /IIs	14 – 20 F	26
		Endurant II aorto-uniliac (AUI)	24 F	1
		Iliac extensions /Limbs	14 – 18 F	3
	Cook Medical	Zenith Flex AAA	14 – 20 F	4
		Zenith proximal Fenestrated AAA	16 – 22 F	3
		Zenith Flex AAA +Zenith branched iliac	16 – 20 F	7
		Zenith branched iliac	16 – 20 F	4
	Cordis	Incraft AAA Stentgraft system	12 – 16 F	9
Total		98		

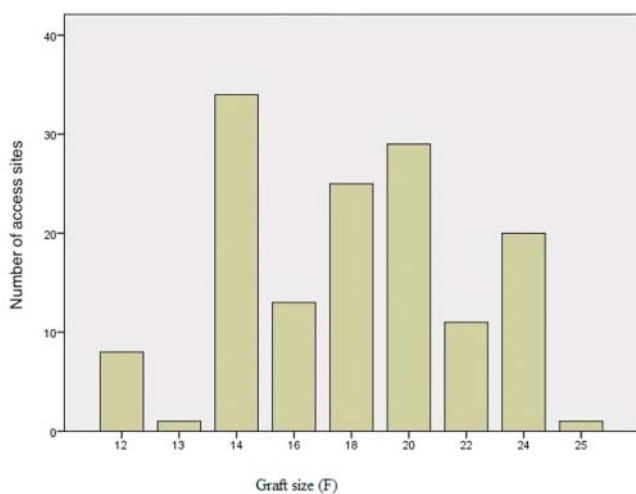
► **Table 4** Descriptive statistics of the vessel characteristics.

► **Tab. 4** Deskriptive Statistik der Zugangskriterien.

	Number	Minimum	Maximum	Mean	Standard deviation
Artery diameter (mm)	142	7.2	18.3	11.415	2.2226
STA	142	9	68.5	31.008	10.3773
SA	142	0.28	1.01	0.5423	0.15371
Graft size	142	12	25	18.10	3.737

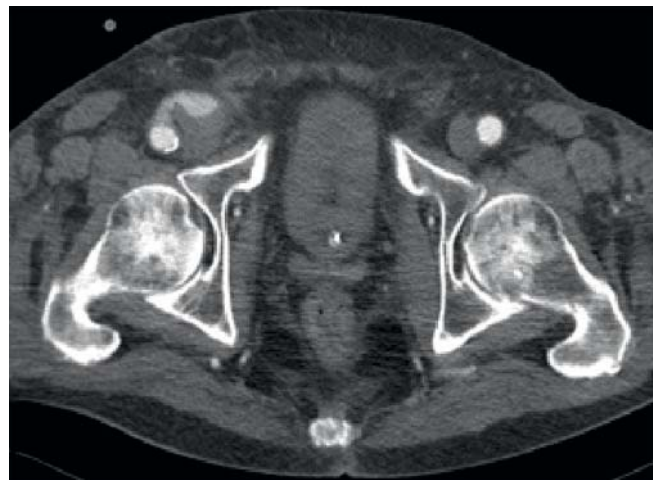STA = skin-to-artery distance, SA = sheath- to-artery ratio

STA = Distanz Hautoberfläche zur Arterie, SA = Verhältniss Einführbesteck zum Arterien Durchmesser.



► **Fig. 4** Distribution of introducer system sizes in our patient cohort (142 access sites).

► **Abb. 4** Verteilung der Größen der Einführbestecke (142 Zugänge).



► **Fig. 5** Pseudoaneurysm of the right common femoral artery on follow-up after primary hemostasis.

► **Abb. 5** Pseudoaneurysma der rechten A. femoralis communis nach primärer Hämostase in der Kontrolluntersuchung.

the other access site variables (vessel diameter, skin-to-artery distance and the sheath-to-artery ratio) did not lead to any interpretable results; hence a correlation could not be established. However, it is worthy of mention that 3 of the 6 patients with a previous history of groin surgery developed early ($n = 2$) or late complications ($n = 1$).

Discussion

The increasing availability of smaller and better endograft introducer systems and better vascular closure devices has led to the transition from the surgical femoral cut downs to the percutaneous approach in the treatment of many aortic pathologies. Against this backdrop, the efficacy, safety and complications of the percutaneous approach in relation to femoral cut down are of import.

The closure devices used for TEVAR, EVAR and FEVAR procedures described in the literature include the Prostar XL as well as the Proglide systems [10]. The choice of the closure device is vari-

able among interventionists. In one systematic literature review, Prostar XL was reported to have a procedural success rate equivalent to that of surgical cut down [1]. As opposed to this, the PEVAR trial demonstrated a non-inferiority to standard open femoral exposure for the Proglide systems but not for the Prostar systems [11]. In the Italian multi-center registry, the use of Proglide was associated with a lower failure rate as compared to Prostar XL, although the difference was not statistically significant [12].

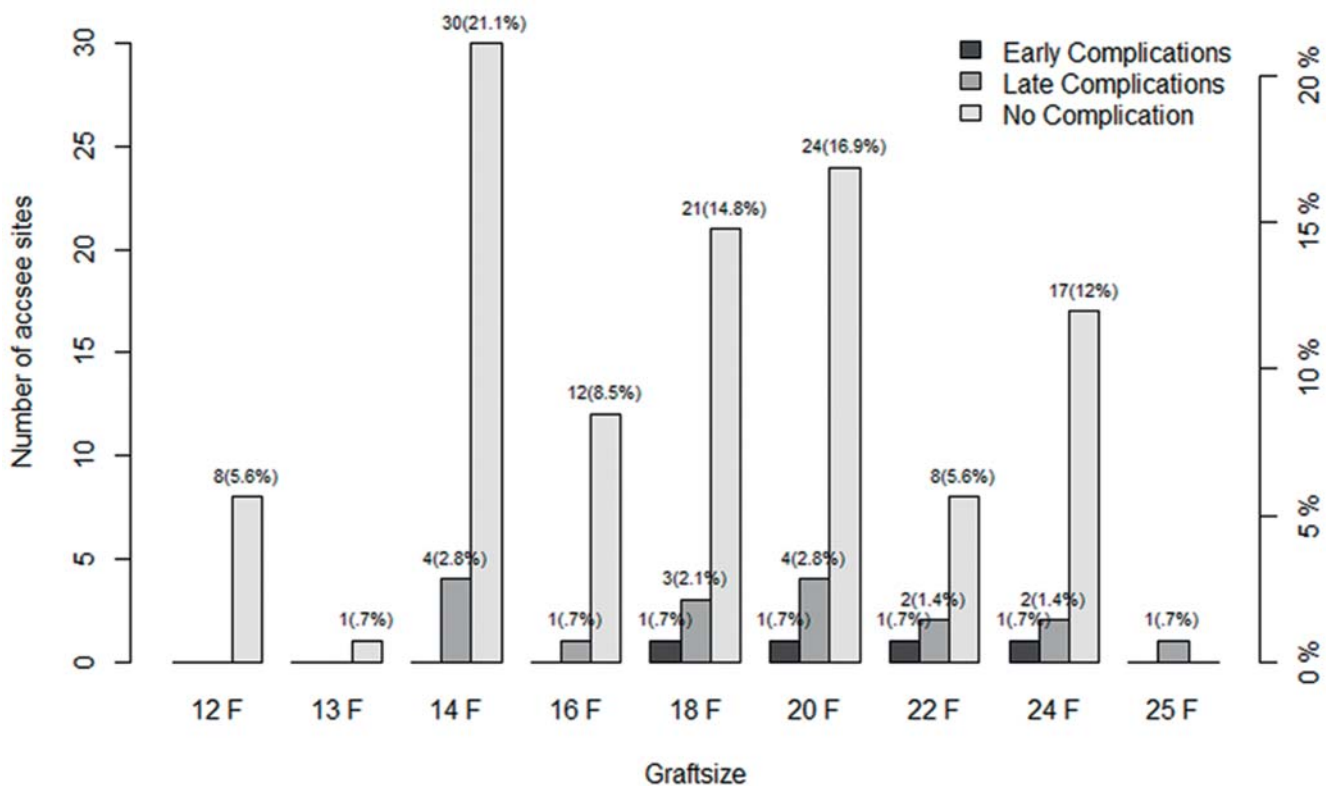
Percutaneous vascular closure devices lead to a significant reduction in the time to hemostasis as well as in the total operative time. This approach can shorten the time to ambulation and discharge [1, 2, 10, 13, 14]. The complication rate of the percutaneous approach is comparable to that of surgical cut down. Consequently, this approach is progressively being regarded to be at least as safe as the surgical approach.

In our set of patients, percutaneous access site closure was successful in over 95% of the access sites. Procedure failure in 4 access sites could be circumvented by surgical repair. In all 4 ac-

- ▶ **Table 5** Incidence of complications and their management.
- ▶ **Tab. 5** Häufigkeit der Komplikationen und deren Behandlung.

Complications		Number	Surgical repair	Conservative management
Early complications		4	4	–
Late complications	Inguinal hematoma	7	–	7
	Wound infection	1	–	1
	Scrotal hematoma	1	–	1
	Pseudoaneurysm	4	2	2
	Late bleeding	4	2	2
Total		21	8	13

Complications by Graftsize



- ▶ **Fig. 6** Incidence of early and late complications in relation to graft size.
- ▶ **Abb. 6** Anzahl der Früh und Spät komplikationen in Bezug auf die Größe der Einführsysteme.

cess sites the size of the introducer sheath was ≥ 18 F. The primary technical success rates of the percutaneous approach based on groin-based evaluation are reported to be between 83% and 100% [1, 15–19]. Our primary success rate of 97.1% compares well with the data published in the literature. It is worthy of mention that patients with heavily or inappropriately calcified vessel walls and those with a previous history of groin and local vascular surgery had been excluded from the study population in the PE-

VAR trial [11]. This was not the case in our cohort. Despite that, the percutaneous approach proved to be feasible and safe irrespective of the size of the introducer sheaths and nature of the aortic pathology. However, surgical backup was mandatory to deal with the few procedural failures and late complications.

Various factors related to the access sites that could influence the incidence of complications have been evaluated and reported on in the literature [1, 6, 20–22]. These include the degree and

► **Table 6** Incidence of complications in relation to calcification score.

► **Tab. 6** Komplikationshäufigkeit in Bezug zum Kalziumscore.

Calcification score	Number	Incidence of early complications			Incidence of late complications		
		Frequency	Percentage	95 % CI	Frequency	Percentage	95 % CI
1	85	2	2.4	0.3 – 8.2 %	9	10.6	5 – 19.2 %
2	49	2	4.1	0.5 – 14 %	8	16.3	7.3 – 29.7 %
3	8	–	–	–	–	–	–
Total	142	4	2.8	0.8 – 7.1 %	17	12	7.1 – 18.5 %

location of vessel wall calcification, obesity with body mass index, skin-to-artery distance and size of the punctured artery. Heavy calcification and obesity were shown to be the main risk factors for device failure and major complications leading to the requirement of surgical conversion according to the report by Eisenack et al. [5].

In our study, vessel characteristics such as degree of vessel wall calcification, artery size, skin-to-artery distance and the sheath-to-artery ratio were evaluated as possible factors that could influence complications. On account of the low rate of complications in our report, such a relationship could not be established between the evaluated parameters and the observed complications.

Recently Rijke et al. (2015) postulated that the ratio of the sheath size in mm to vessel diameter in mm could help predict device failure [20]. Based on their results, a ratio exceeding 0.75 led to higher rates of device failure. They therefore advocate a primary open groin approach in such cases. However, the authors used only Cook devices, the sheath diameters of which correspond to the inner sheath diameter and not to the actual outer diameter that effectively defines the size of the defect in the arterial wall [23]. In our set of patients, we used exclusively the outer sheath diameter for purposes of calculating the ratio. The ratio exceeded 0.75 in altogether 17 patients. Nevertheless, insertion of the endograft system was unproblematic in all patients.

Considering the fact that our cohort also included ruptured thoracic and abdominal aortic aneurysms, the mortality rate of 6.5 % is acceptable. None of the deaths were related to access site complications. Apart from the 4 technical failures (2.8 %), major late access site complications (grade C, SIR guidelines (24)) were noted at 4 access sites (2.8 %). Grade A or B minor late complications in altogether 13 further access sites were managed successfully with purely conservative measures.

We find it worthy of mention that 6 of our patients had a history of previous groin surgery. Failure of suture mediated closure ($n = 2$) or late complications ($n = 1$) were noted in half of them. Failure is imaginable because of postoperative fibrotic scar tissue that cannot be penetrated as easily by the device needles as normal healthy tissue. Furthermore, such tissue could also adversely affect the effective closure of the sutures. It may therefore be worthwhile to proceed with caution in such patients if a percutaneous procedure is contemplated.

Conclusion

Percutaneous endovascular aortic repair is feasible and safe irrespective of the size of the introducer sheath or the nature of the aortoiliac pathology. The technical success rate is high and the incidence of complications is low. Early complications in the form of insufficient hemostasis are most often associated with sheath sizes ≥ 18 F and may require surgical intervention. The majority of the late complications can be treated conservatively. In our opinion pre-operated groins may adversely influence procedural outcome. With the advent of low profile introducer sheaths and with increasing experience of the interventionist, the percutaneous approach could largely replace surgical cut down for endovascular aortic repair.

Acknowledgements

The authors thank Mr. Dominik de Sordi, Division of Epidemiology and Biometry, Department of Health Services Research, Faculty of Medicine and Health Sciences, Carl von Ossietzky University, Oldenburg for his assistance with the statistical analyses.

Conflict of Interest

No conflict of interest has been declared by the author(s).

References

- [1] Haulon S, Hassen Khodja R, Proudfoot CW et al. A systematic literature review of the efficacy and safety of the Prostar XL device for the closure of large femoral arterial access sites in patients undergoing percutaneous endovascular aortic procedures. *Eur J Vasc Endovasc Surg* 2011; 41: 201–213
- [2] Etezadi V, Katzen BT, Naiem A et al. Percutaneous suture mediated closure versus surgical arteriotomy in endovascular aortic aneurysm repair. *J Vasc Interv Radiol* 2011; 22: 142–147
- [3] Berchera CF, Barshes NR, Pisimisis G et al. Predicting the learning curve and failures of percutaneous endovascular aortic aneurysm repair. *J Vasc Surg* 2013; 57: 72–76
- [4] Metcalfe MJ, Brownrigg JRW, Black SA et al. Unselected percutaneous access with large vessel closure for endovascular aortic surgery: experience and predictors of technical success. *Eur J Vasc Endovasc Surg* 2012; 43: 378–381

- [5] Eisenack M, Umscheid T, Tessarek J et al. Percutaneous endovascular aortic aneurysm repair: a prospective evaluation of safety, efficiency and risk factors. *J Endovasc Ther* 2009; 16: 708–713
- [6] Mousa AY, Campbell JE, Broce M et al. Predictors of percutaneous access failure requiring open femoral surgical conversion during endovascular aortic aneurysm repair. *J Vasc Surg* 2013; 58: 1213–1219
- [7] Georgiadis GS, Antoniou GA, Papaioakim M et al. A meta-analysis of outcome after percutaneous endovascular aortic aneurysm repair using different sheaths or endograft delivery systems. *J Endovasc Ther* 2011; 18: 445–459
- [8] Lee WA, Brown MP, Nelson PR et al. Midterm outcomes of femoral arteries after percutaneous endovascular aortic repair using Perclose technique. *J Vasc Surg* 2008; 47: 919–923
- [9] Perdikiades TP, Georgiadis GS, Avgerinos ED et al. Percutaneous endovascular treatment of aortic aneurysms: clinical evaluation and literature results. *Minim Invasive Ther* 2012; 21: 342–350
- [10] Jahnke T, Schäfer JP, Charalambous N et al. Total percutaneous endovascular aneurysm repair with dual 6F Perclose AT preclosing technique: a case control study. *J Vasc Inter Radiol* 2009; 20: 1292–1298
- [11] Nelson PR, Krajcer Z, Kansal N et al. A multicentric, randomized, controlled trial of totally percutaneous access versus open femoral exposure for endovascular aortic aneurysm repair (the PEVAR trial). *J Vasc Surg* 2014; 59: 1181–1193
- [12] Pratesi G, Barbante M, Pulli R et al. Italian Percutaneous EVAR (IPER) Registry: outcomes of 2381 percutaneous femoral access sites' closure of aortic stent graft. *J Cardiovasc Surg (Torino)* 2015; 56: 889–898
- [13] Malkawi AH, Hinchliffe RJ, Holt PJ et al. Percutaneous access for endovascular aneurysm repair: a systematic review. *Eur J Vasc Endovasc Surg* 2010; 39: 676–682
- [14] Biancari F, Andrea DV, Di Marco C et al. Meta-analyses of randomized trials on the efficacy of vascular closure devices after diagnostic angiography and angioplasty. *Am Heart J* 2010; 159: 518–531
- [15] Starnes BW, Andersen CA, Ronsivalle JA et al. Totally percutaneous aortic aneurysm repair: experience and prudence. *J Vasc Surg* 2006; 43: 270–276
- [16] Howell M, Villareal R, Krajcer Z. Percutaneous access and closure of femoral access artery sites associated with endoluminal repair of abdominal aortic aneurysms. *J Endovasc Ther* 2001; 8: 68–74
- [17] Torsello GB, Kaspryck B, Klenk E et al. Endovascular suture versus cut-down for endovascular aneurysm repair: a prospective randomized pilot study. *J Vasc Surg* 2003; 38: 78–82
- [18] Morasch MD, Kibbe MR, Evans ME et al. Percutaneous repair of abdominal aortic aneurysms. *J Vasc Surg* 2004; 40: 12–16
- [19] Quinn SF, Kim J. Percutaneous femoral closure following stentgraft placement: use of perclose device. *Cardiovasc Intervent Radiol* 2004; 27: 231–236
- [20] Rijke MP, Stadius van Eps RG, Wever JJ et al. Knippenberg. Predictors of failure of closure in percutaneous EVAR using the Prostar XL percutaneous vascular surgery device. *Eur J Endovasc Surg* 2015; 49: 45–49
- [21] Skagius E, Bosnjak M, Bjorck M et al. Percutaneous closure of large femoral artery access with Prostar XL in thoracic endovascular aortic repair. *Eur J Vasc Endovasc Surg* 2013; 46: 558–563
- [22] Thomas C, Steger V, Heller S et al. Safety and Efficacy of the Prostar XL Vascular closure Device for Percutaneous closure of large arterial access sites. *Radiol Res Pract* 2013; 2013: 875484
- [23] Chakfe N, Georg Y. Commentary on 'Predictors of failure of closure in Percutaneous EVAR using the Prostar XL percutaneous vascular surgery device'. *Eur J Vasc Endovasc Surg* 2015; 49: 50–51
- [24] Walker TG, Kalva SP, Yeddula K et al. Clinical Practice Guidelines for Endovascular Abdominal Aortic Aneurysm Repair: Written by the Standards of Practice Committee for the Society of Interventional Radiology and Endorsed by the Cardiovascular and Interventional Radiological Society of Europe and the Canadian Interventional Radiology Association. *J Vasc Interv Radiol* 2010; 21: 1632–1655