

# Recurrent Interstitial Pregnancy: a Review of the Literature

## Wiederauftreten einer interstitiellen Schwangerschaft: eine Literaturübersicht

### Author

Eva Egger<sup>1,2</sup>

### Affiliations

- 1 University of Bonn, Department of Obstetrics and Gynecology/CIO, Bonn, Germany
- 2 Florence Nightingale Hospital, Department of Obstetrics and Gynecology, Düsseldorf, Germany

### Key words

ectopic pregnancy, interstitial pregnancy, angular pregnancy, cornual pregnancy, recurrent ectopic pregnancy

### Schlüsselwörter

ektope Schwangerschaft, interstitielle Schwangerschaft, anguläre Schwangerschaft, Uterushornschwangerschaft, erneute ektope Schwangerschaft

received 21.10.2016

revised 19.12.2016

accepted 22.12.2016

### Bibliography

DOI <http://dx.doi.org/10.1055/s-0043-100107>

Geburtsh Frauenheilk 2017; 77: 335–339 © Georg Thieme Verlag KG Stuttgart · New York | ISSN 0016-5751

### Correspondence

Dr. Eva Egger

University of Bonn, Department of Obstetrics and Gynecology/CIO  
Sigmund-Freud-Straße 25, 53127 Bonn, Germany  
[eva.egger@gmx.de](mailto:eva.egger@gmx.de)

### ABSTRACT

Interstitial pregnancies account for 2–4% of all ectopic pregnancies. Despite its rarity, various treatment options exist. However, no gold standard has yet been defined and data regarding recurrence of interstitial pregnancies in subsequent pregnancies after different treatments are sparse. This makes it very difficult to provide adequate patient counselling for treatment options with regards to the treatment-

related risk of recurrence. The present literature review demonstrates that recurrent interstitial pregnancy is a rare condition and more likely when additional anatomy-related risk factors for ectopic pregnancies are present, such as hydrosalpinges, blocked tubes, endometriosis, fibroids or prior tubal ectopic pregnancies. Therefore, at first appearance and in absence of additional anatomy-related risk factors, methotrexate intravenously, intramuscularly or into the amnion may be the first choice. In case of anatomical risk factors, cornual wedge resection seems to be first choice. In case of recurrence, cornual wedge resection is particularly justified in patients with anatomical alterations of the salpinges. The role of conservative surgical treatments in recurrence as cornuotomy, salpingectomy, endo-loop ligation and resection and curettage under laparoscopic guidance remains unclear due to sparse data.

### ZUSAMMENFASSUNG

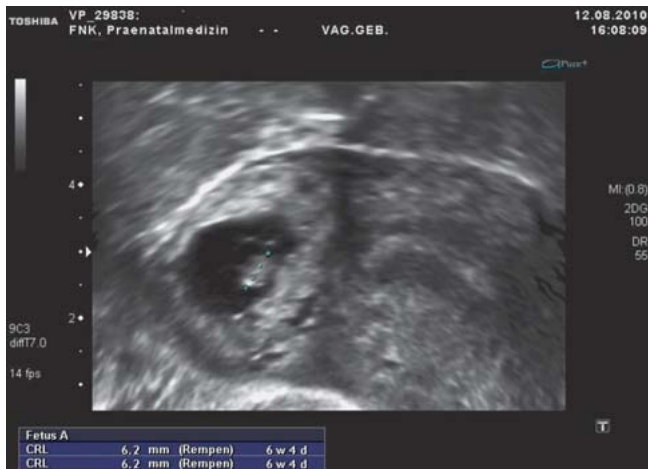Nur circa 2–4% aller ektopten Graviditäten liegen interstitiell. Trotz ihrer Seltenheit gibt es eine Reihe verschiedener Behandlungsoptionen. Aufgrund vieler Einzelfallberichte mit unterschiedlichen therapeutischen Herangehensweisen gibt es keinen Goldstandard und Daten zum Rezidivrisiko in Abhängigkeit zur gewählten Therapie fehlen. Das Rezidivrisiko ist für die adäquate Beratung der Patientin hinsichtlich ihrer Therapiemöglichkeiten aber eine wichtige Information. Diese Literaturübersicht zeigt, dass eine wiederholt auftretende interstitielle Schwangerschaft selten ist. Die Wahrscheinlichkeit eines erneuten Auftretens ist höher bei Vorliegen zusätzlicher anatomischer Risikofaktoren für ektope Schwangerschaften, wie Hydrosalpinx, Tubenobstruktion, Endometriose, Uterusmyome oder eine frühere ektope Tubargravidität. Bei Primärauftreten einer interstitiellen Schwangerschaft und ohne Nachweis anatomischer Risikofaktoren erscheint eine medikamentöse Behandlung mit Methotrexat systemisch oder lokal zielführend. Bei Vorliegen von anatomischen Risikofaktoren und weiterem Kinderwunsch sowie im Rezidivfall erscheint dagegen eine Keilresektion des entsprechenden Uterushorns sinnvoll. Aufgrund der eingeschränkten Datenlage und fehlender Studien bleibt der Stellenwert konservativer operativer Maßnahmen, wie die Uterushorneröffnung, die Salpingektomie, die Endo-loop-Resektion bzw. die Kürettage unter laparoskopischer Kontrolle noch unklar.

## Introduction

Interstitial pregnancy is a rare form of ectopic tubal pregnancy, accounting for 2–4% of all ectopic pregnancies. The terms cornual, interstitial and rarely angular ectopic pregnancy are often used synonymously. The true interstitial pregnancy is defined by its location lateral to the round ligament in the uterotubal junc-

tion, whilst cornual and angular pregnancies are considered as intrauterine pregnancies [1, 2]. Diagnosis is made by ultrasound and positive human chorionic gonadotropin (HCG) (► **Fig. 1**). Despite its rarity, there is a wide variety of treatment options but a lack of knowledge how recurrences might be prevented by the choice of treatment [1].

A literature search using PubMed and Google Scholar on recurrent interstitial pregnancy reveals that only very few cases of re-



► Fig. 1 Ultrasound picture of an interstitial pregnancy.

current interstitial pregnancies have been reported. As detailed below, prior history and visible risk factors for ectopic pregnancies appear to be significant for the best choice of treatment.

## Literature Search

A literature search in PubMed and Google Scholar was conducted by using the keywords “interstitial pregnancy” or “cornual pregnancy” or “angular pregnancy”. Additionally, the references of papers returned by this literature search were searched for further papers. The resulting abstracts were screened for information regarding the further reproductive outcome. In total we found 61 articles on interstitial pregnancies where further information about the reproductive outcome after treatment could be retrieved and 41 articles about interstitial pregnancies as heterotopic pregnancies where the further reproductive outcome was addressed. Only 13 of these 102 publications were related to recurrences of ipsilateral interstitial pregnancies. ► **Table 1** shows the 13 case reports, with details presented on treatment, risk factors, time frame to recurrence and subsequent pregnancies.

## General Overview

In the literature, recurrent interstitial pregnancy appears to be very rare. The only multiple case study of four cases [1] reported a prevalence of 0.3% of all women with ectopic pregnancies over a five-year period. In the largest reported series of ectopic pregnancies [3], there was no recurrence of interstitial pregnancies reported with an overall rate of interstitial pregnancies of 2.4%. All cases were treated by surgery. The majority of cases was treated by salpingectomy, which was considered a radical surgical approach.

## Risk Factors

In general, risk factors for an interstitial pregnancy and its recurrence include

1. tubal anomaly, which can be induced by endometriosis or uterine leiomyomata,
2. anatomical damage due to pelvic inflammatory disease,
3. prior ectopic pregnancies,
4. salpingectomy and
5. assisted reproductive techniques.

Eleven out of 17 cases of recurrent interstitial pregnancy showed at least one pathology or anatomical anomaly in the uterotubal junction [1, 2, 5, 11, 14, 16, 19, 20] (► **Table 1**). Furthermore, damaged tubes are found more frequently in proximal ectopic pregnancies than in distal ectopic pregnancies [3]. Additionally, salpingectomy appears to be a singular predisposition for interstitial pregnancies as Simpson et al. showed in a literature review of 46 interstitial pregnancies after ipsilateral salpingectomy [4].

In the context of risk factors it is interesting to note that tubal occlusion within the uterotubal junction after recurrent interstitial pregnancy, which was treated twice with systemic methotrexate, eventually led to a successful intrauterine pregnancy [5].

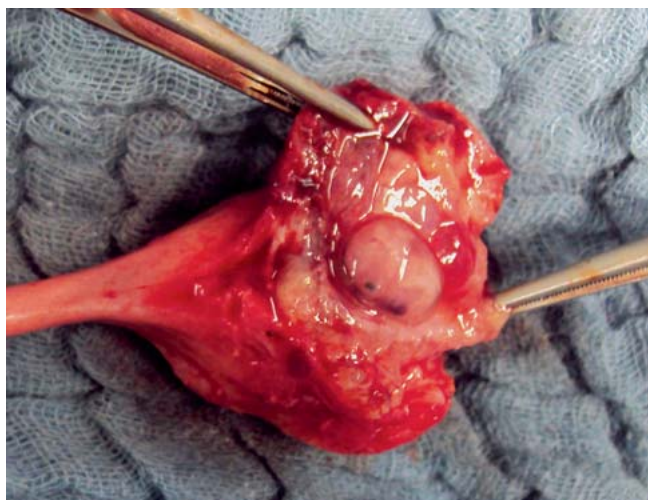
## Treatment Choice and Recurrence

There are various treatment options. Conservative approaches include methotrexate injections, which can be given systemically and/or locally. Tanaka reported in 1982 the first successful systemic methotrexate treatment of an interstitial pregnancy. He used 30 mg methotrexate intramuscularly on day 1, followed by two courses of 15 mg/d for a further five days. There were two days between the two courses [6]. The most common schedule is one or two courses with methotrexate 1 mg/kg/d systemically on day 1, 3, 5 and 7 with seven days in between. Different schedules also applied methotrexate locally in doses of 25 to 50 mg. The approximate overall success rate in various case reports is 83%, while the local treatment was considered to be slightly more successful [7]. Importantly, randomized trials comparing treatment options regarding interstitial pregnancy are missing. The randomized multicenter Demeter trial compared surgery with methotrexate 1 mg/kg/d on day 1, 4, 7, and 14 systemically in tubal ectopic pregnancies. The methotrexate schedule depended on the post-therapeutic HCG levels. While there was no significant difference regarding further fertility, the failure rate of systemic methotrexate was 21.8% [8]. Within heterotopic pregnancies, defined by the coexistence of an intrauterine and an ectopic pregnancy, the coexisting interstitial pregnancy is often treated by a local potassium chloride injection. Surgical interventions, on the other hand, primarily take place in case of failure of local treatment [7, 11]. We only found one case of recurrence after treatment of a heterotopic pregnancy by selective fetocide of a heterotopic cornual pregnancy by intracardial 0.5 ml 15% KCL injection at 8 weeks of gestation. The remaining intrauterine pregnancy was uneventful and was delivered at term by a Caesarean section [11].

► **Table 1** Reports about recurrent interstitial pregnancies.

Author	Prior obstetrical history	Treatment first interstitial pregnancy	Treatment recurrent interstitial pregnancy	Risk factors/uterine/tubal pathologies	Subsequent intrauterine pregnancy	Time to recurrence (month)
Sungurtekin and Uyar, 1998 [13]	2 SA	Methotrexate 50 mg/d i. m. + citrovorum factor 0.1 mg/kg for 5 days	1. 2 × Methotrexate 50 mg/d i. m. + citrovorum factor 0.1 mg/kg for 5 days, due to a viable pregnancy after the first course. 2. Laparotomy and resection of a uterine cornual mass, due to suspicion of an imminent rupture.	Pelvic endometriosis	NO	17
Vilos, 2001 [2]	1 SA, 1 VD	Laparoscopic ligation with endoloops and resection	Laparoscopic ligation with endoloops and resection	Bilateral interstitial-isthmic tubal anastomoses	NO	10
Wittich, 1998 [14]	2 VD 1 CS	Laparotomy + cornuostomy	Laparotomy + cornual wedge resection	PID, multiple leiomyomata	NO	19
Budnick et al., 1993 [15]	None	Curetage under laparoscopic guidance	Laparotomy + salpingectomy	None	MNS	8
Maruthini and Sharma, 2013 [16]	None	Laparotomy + cornuostomy + postoperatively methotrexate i. v.	Laparotomy and diathermic coagulation	Hydrosalpinges, bilateral salpingectomy, IVF	CS	12
Sagiv et al., 2001 [10]	None	Laparoscopic methotrexate injection (12.5 mg)	Laparoscopic cornuostomy	None	VD	6
Douysset et al., 2014 [17]	NO	Laparoscopic excision by Endo GIA stapling	Laparotomy + cornuostomy	NO	NO	NO
Siow and Ng, 2011 [1]	Pt 1: 2 EPT 1 TEP Pt 2: 2 EPT Pt 3: 1 EPT Pt 4: 1 EPT	Pt 1 + 2 Laparoscopic cornuostomy Pt 3 Uterine rupture, expellation by laparoscopic hydrodissection Pt 4 A left + right: laparoscopic wedge resection	Pt 1–4: Laparoscopic wedge resection	Pt 1: Previous tubal ectopic pregnancy Pt 3–4: PID Pt 4: IVF	Pt 3: 1 VD, 2 CS, 1 EPT Pt 4: VD	Pt 1: 18 Pt 2: 5 Pt 3: 26 Pt 4: 4/32
van der Weiden and Karsdorp, 2005 [11]	None	Selective fetocide of a heterotopic cornual pregnancy by intracardial 0.5 ml 15 % KCL injection at 8 weeks of gestation. CS of the intrauterine pregnancy at term.	0.5 ml 15 % KCL intracardial + 40 mg methotrexate in the gestational sac, 3 courses of methotrexate oral 1.0 mg/kg + 15 mg folinic acid	IVF, blocked tubes	NO	24
Faraj and Steel, 2008 [5]	None	Single dose systemic methotrexate	Suction evacuation, without pregnancy products, 2 single doses of systemic methotrexate	Abnormal shaped uterine cornu due to a fibroid	At publication Pt. was pregnant at 20 weeks of gestation after tubal occlusion	8
Hwang et al., 2011 [18]	NO	Cornual wedge resection	Cornual wedge resection	NO	NO	NO
Faleyimu et al., 2008 [19]		Laparotomy + cornual wedge resection	Laparotomy with salpingo-oophorectomy	Septic abortion in between both interstitial pregnancies	None	60
Sahoo et al., 2009 [20]	12 EG 3 SA 1 VD	Laparoscopic endoloop resection of the ectopic pregnancy and diathermy, due to rising β-HCG titers 600 mg mifepristone oral + 100 mg MTX i. m. was given.	Laparoscopic right cornual excision by endoloop and diathermy. Hysteroscopy demonstrated the complete removal.	2 tubal ectopic pregnancies, right salpingectomy	None	12

CS: Caesarean section, VD: vaginal delivery, MNS: mode of delivery not specified, NO: no information, EPT: early pregnancy termination, SA: spontaneous miscarriages, PID: pelvic inflammatory disease, IVF: in vitro fertilisation.



► **Fig. 2** Interstitial pregnancy after cornual wedge resection.

The main surgical options include salpingectomy, cornuotomy and cornual wedge resection (► **Fig. 2**). Regarding surgery one might expect cornual wedge resection as superior treatment and recurrent interstitial pregnancies to occur especially frequent after medical treatment, as only the cornual wedge resection, if done properly, will remove the uterotubal junction. In fact, we only found two publications on a total of two patients with recurrence after cornual wedge resection (► **Table 1**). Thirteen other patients recurred after being treated by various kinds of surgical techniques in their first interstitial pregnancy. In those 13 patients, different surgical techniques were used. All of these procedures included at least the removal of pregnancy products and if necessary wound closure but excluded the resection of the entire uterotubal junctions as it is part of the cornual wedge resection (► **Table 1**). However, given the diversity of treatments and the very sparse data on their further outcomes, it is difficult to judge whether those different techniques may create a predisposition for recurrent interstitial pregnancy as the possible anatomical reason for interstitial pregnancy is not removed. Randomized trials regarding the quality of different surgical techniques are missing.

## Tubal Milieu

In three cases, there was no known anatomical anomaly or tubal damage (► **Table 1**). In a further two cases, no information regarding risk factors was available. In addition, only three publications with recurrent interstitial pregnancy were found after prior medical treatment with systemic or local methotrexate injections. If anatomical alterations of the uterotubal junction as sequelae of conservative treatment of ectopic pregnancy would be the only reason for recurrence in interstitial pregnancies, one would have expected more case reports of recurrence [3, 5, 11].

Importantly, normal tubal function, which is needed for normal intrauterine implantation, depends on more than anatomic normality. Modifications in tubal milieu may also lead to blastocyst arrest. By now it is understood that tubal functions like

smooth muscle contractility and ciliary beat activity, which are of imminent importance for a later intrauterine implantation, are triggered through a wide range of different transmitters [3, 8].

Therefore, the conservative approach with systemic or local methotrexate injections may be justified, especially at first appearance and in the absence of additional anatomy-related risk factors.

## Uterine Rupture

The incidence of uterine ruptures in the scarred uterus appears to be low, but the fear of it remains and therefore medical treatment might be favored over cornual wedge resection [9]. Nevertheless, the actual risk of uterine rupture after medical treatment is unknown. Therefore, it is interesting to note that uterine rupture has been described in the unscarred uterus after interstitial pregnancy. As in the recurrent interstitial pregnancy after hysteroscopic resection of the first interstitial pregnancy [15] and in the subsequent intrauterine pregnancy at 24 weeks of gestation after spontaneous resolution of an interstitial pregnancy by excision of a corpus luteum [21].

## Surgical Approaches

Regarding the chosen surgical approach – laparoscopy or laparotomy – there seems to be no difference for later recurrences. As can be seen in ► **Table 1**, seven patients recurred after laparoscopy and four patients recurred after laparotomy. Optimal suturing and a very limited use of electrocautery might be of more importance when treating interstitial pregnancy surgically, regarding later uterine ruptures [1, 3, 12].

## Timeframe and Subsequent Pregnancies

The role of the variable timeframes to recurrence in all 16 cases, ranging from 5 to 60 months, and the significance of six subsequent intrauterine pregnancies cannot be judged properly with regards to subsequent fertility or risk of recurrence, given that information about contraception and try for pregnancy was not available. It is, however, interesting to note that two women had uneventful vaginal deliveries after cornual wedge resection and one after local methotrexate injection (► **Table 1**).

## Conclusions

The literature review demonstrates that recurrent interstitial pregnancy is a very rare condition and more likely when additional anatomy-related risk factors for ectopic pregnancies are present, such as hydrosalpinges, blocked tubes, endometriosis, fibroids or prior tubal ectopic pregnancies. Nevertheless, it has to be addressed when counseling patients for treatment options.

Therefore, at first appearance and in absence of additional anatomy-related risk factors, local or systemic methotrexate in-

jections may be the first choice. In case of anatomical risk factors, cornual wedge resection seems to be the first choice. In case of recurrence, cornual wedge resection is particularly justified in patients with anatomical alterations of the salpinges. Furthermore, surgery is needed to thoroughly inspect the anatomical conditions. The role of various other surgical treatments in recurrence, such as cornuotomy, salpingectomy, endoloop ligation and resection and curettage under laparoscopic guidance remains unclear due to sparse data.

## Acknowledgements

I would like to thank Prof. Herwig Egger and Prof. Walther C. Kuhn for helpful comments on an earlier version of this article.

## Conflict of Interest

The author declares that she has no conflict of interests.

## References

- [1] Siow A, Ng S. Laparoscopic management of 4 cases of recurrent cornual ectopic pregnancy and review of literature. *J Minim Invasive Gynecol* 2011; 18: 296–302
- [2] Vilos GA. Laparoscopic ligation and resection of two ipsilateral interstitial pregnancies in the same patient. *J Am Assoc Gynecol Laparosc* 2001; 8: 299–302
- [3] Bouyer J, Coste J, Fernandez H et al. Sites of ectopic pregnancy: a 10 year population-based study of 1800 cases. *Hum Reprod* 2002; 17: 3224–3230
- [4] Simpson J, Alford C, Miller A. Interstitial pregnancy following homolateral salpingectomy. A report of 6 new cases and review of the literature. *Am J Obstet Gynecol* 1961; 82: 1173–1179
- [5] Faraj R, Steel M. Can we reduce the recurrence of cornual pregnancy? A case report. *Gynecol Surg* 2008; 6: 57–59
- [6] Tanaka T, Hayashi H, Kutsuzawa T et al. Treatment of interstitial ectopic pregnancy with methotrexate: report of a successful case. *Fertil Steril* 1982; 37: 851–852
- [7] Lau S, Tulandi T. Conservative medical and surgical management of interstitial ectopic pregnancy. *Fertil Steril* 1999; 72: 207–215
- [8] Fernandez H, Capmas P, Lucot JP et al.; GROG. Fertility after ectopic pregnancy: the DEMETER randomized trial. *Hum Reprod* 2013; 28: 1247–1253
- [9] Vandenberghe G, De Blaere M, Van Leeuw V et al. Nationwide population-based cohort study of uterine rupture in Belgium: results from the Belgian Obstetric Surveillance System. *BMJ Open* 2016; 6: e010415
- [10] Sagiv R, Golan A, Arbel-Alon S et al. Three conservative approaches to treatment of interstitial pregnancy. *J Am Assoc Gynecol Laparosc* 2001; 8: 154–158
- [11] van der Weiden RM, Karsdorp VH. Recurrent cornual pregnancy after heterotopic cornual pregnancy successfully treated with systemic methotrexate. *Arch Gynecol Obstet* 2005; 273: 180–181
- [12] Shaw JL, Dey SK, Critchley HO et al. Current knowledge of the aetiology of human tubal ectopic pregnancy. *Hum Reprod Update* 2010; 16: 432–444
- [13] Sungurtekin U, Uyar Y. Recurrent interstitial pregnancy. *Aust N Z J Obstet Gynaecol* 1998; 38: 438–440
- [14] Wittich AC. Recurrent cornual ectopic pregnancy in a patient with leiomyomata uteri. *J Am Osteopath Assoc* 1998; 98: 332–333
- [15] Budnick SG, Jacobs SL, Nulsen JC et al. Conservative management of interstitial pregnancy. *Obstet Gynecol Surv* 1993; 48: 694–698
- [16] Maruthini D, Sharma V. A case of live birth after uterine reconstruction for recurrent cornual ectopic pregnancy following IVF treatment. *Case Rep Obstet Gynecol* 2013; 2013: 625261
- [17] Douysset X, Verspyck E, Diguët A et al. [Interstitial pregnancy: experience at Rouen's hospital]. *Gynecol Obstet Fertil* 2014; 42: 216–221
- [18] Hwang JH, Lee JK, Lee NW et al. Open cornual resection versus laparoscopic cornual resection in patients with interstitial ectopic pregnancies. *Eur J Obstet Gynecol Reprod Biol* 2011; 156: 78–82
- [19] Faleyimu BL, Igberase GO, Momoh MO. Ipsilateral ectopic pregnancy occurring in the stump of a previous ectopic site: a case report. *Cases J* 2008; 1: 343
- [20] Sahoo S, Jose J, Shah N et al. Recurrent cornual ectopic pregnancies. *Gynecol Surg* 2009; 6: 389–391
- [21] Downey GP, Tuck SM. Spontaneous uterine rupture during subsequent pregnancy following non-excision of an interstitial ectopic gestation. *Br J Obstet Gynaecol* 1994; 101: 162–163