



Management of Acute Complications during Endovascular Procedures in Peripheral Arterial Disease: A Review

Ajay Pawan Kumar¹ Jineesh Valakkada¹ Anoop Ayappan¹ Santhosh Kannath¹

¹Department of Imaging Sciences and Interventional Radiology, Sreechitra Institute of Medical Sciences and Technology, Trivandrum, Kerala, India

Address for correspondence Jineesh Valakkada, MD, Department of Imaging Sciences and Interventional Radiology, Sreechitra Institute of Medical Sciences and Technology, Trivandrum – 695011, Kerala, India (e-mail: jineesh174@gmail.com).

J Clin Interv Radiol ISVIR 2023;7:97–107.

Abstract

Endovascular therapy, as opposed to surgical bypass, has become the mainstay for peripheral arterial disease even in long segment occlusions. Complications can occur during the arterial access, catheter manipulation, balloon dilation, and/or stent placement. Given the high prevalence of comorbidities such as diabetes, hypertension, renal dysfunction, and coronary artery disease in these patients, early identification of procedural complications and initiation of treatment are of paramount importance. This review aims to provide comprehensive data on the identification and management of commonly encountered endovascular complications during endovascular interventions in peripheral arterial disease.

Keywords

- ▶ pseudoaneurysm
- ▶ complications
- ▶ femoral artery access

Introduction

Endovascular therapy has become the mainstay of treatment for peripheral arterial disease. These procedures are generally safe with a low incidence of complications. Significant intra- or post-procedural complications can occur and include those related to vascular access, or guidewire, catheter, balloon, or stent related. Early identification of these complications is important as many of the patients have associated comorbidities such as diabetes, hypertension, coronary artery disease, and renal dysfunction. This comprehensive review focuses on identification and management of acute complications commonly encountered during endovascular therapy of peripheral arterial disease.

Access Site Complications

The most common site of complication is at the access site. The access site complications include hematoma, retroperi-

toneal hemorrhage, arterial pseudoaneurysm (PSA), arteriovenous fistula (AVF), dissections, vessel occlusion, and branch vessel injury. The overall incidence is high during therapeutic procedures (4%) compared with diagnostic procedures (1.8%). Large access sheath, prolonged procedure time, and higher anticoagulant dose increase the incidence of complications.¹ The assistance of fluoroscopy and ultrasound (US) during arterial access reduces the incidence of access site complications.²

Retroperitoneal Hematoma

Although a minor hematoma at the access site is common (4%), significant bleeding with a decrease in hemoglobin of more than 3 g/dL and hypotension occurs in 0.5% of cases.¹ Risk factors for significant hematoma include older age, female gender, obesity, larger arterial sheath (> 8F), longer sheath dwell time, a higher dose of anticoagulants, high arterial puncture (above the inguinal ligament), and severe

article published online
December 27, 2022

DOI <https://doi.org/10.1055/s-0042-1760246>.
ISSN 2457-0214.

© 2022. Indian Society of Vascular and Interventional Radiology. All rights reserved.

This is an open access article published by Thieme under the terms of the Creative Commons Attribution-NonDerivative-NonCommercial-License, permitting copying and reproduction so long as the original work is given appropriate credit. Contents may not be used for commercial purposes, or adapted, remixed, transformed or built upon. (<https://creativecommons.org/licenses/by-nc-nd/4.0/>)

Thieme Medical and Scientific Publishers Pvt. Ltd., A-12, 2nd Floor, Sector 2, Noida-201301 UP, India

hypertension.³⁻⁷ The recommended site for the common femoral artery (CFA) access is over the lower third of the femoral head below the inguinal ligament. Access above the pubic ramus is associated with a high probability of retroperitoneal bleeding due to lack of bony support for compression.³ Since the retroperitoneum is a free space, it absorbs a large volume of blood in a short time. Patients present with hypotension, tachycardia, suprainguinal swelling, abdominal tenderness, a decrease in hemoglobin, and hypotensive shock. Patients may also experience abdominal compartment syndrome and neuropathy due to compression of femoral, obturator, and lateral femoral cutaneous nerves.^{5,8} Initial treatment consists of fluid replacement with intravenous fluids, blood transfusions, and anticoagulation reversal (if possible).⁸ However, aggressive fluid transfusion can dilute coagulation factors and result in loss of vasoconstriction (due to normotensive blood pressure) and dissolution of blood clots. It is better to practice permissive hypotension with a target mean blood pressure of 70 to 90 mm Hg.⁹ If the hemoglobin level is less than 7 g/dL, a blood transfusion should be started. In the case of massive transfusions (> 4 units of blood), the ratio fresh-frozen plasma: red blood cell: platelets = 1:1:1

must be observed to prevent dilution of the coagulation factors.¹⁰ If fluid correction does not result in clinical improvement, an attempt should be made to endovascularly inflate a balloon at low pressures at the site of extravasation. Balloon tamponade for approximately 10 minutes helps stop the bleeding, but the results can vary.¹¹

If symptoms occur post-procedure, a computed tomography angiography (CTA) helps confirm the extent of the hematoma and presence of arterial extravasation. If the bleeding is from the inferior epigastric artery and does not respond to compression, coil embolization of the bleeding vessel may be required. If bleeding does not respond to balloon tamponade, a stent graft (–Fig. 1) may be considered to exclude the bleeding site.⁵ Care should be taken not to place the stent graft across the hip joint as it may later fracture. Surgical repair should be considered if the stent graft jails the profunda femoris or if grafts are not available.¹² In such cases, a balloon catheter (BC) is kept partially inflated across the leak site to prevent active bleeding and the patient is shifted for surgical repair. Surgical repair with the evacuation of hematoma is also indicated if there are features of abdominal compartment syndrome or nerve compression.

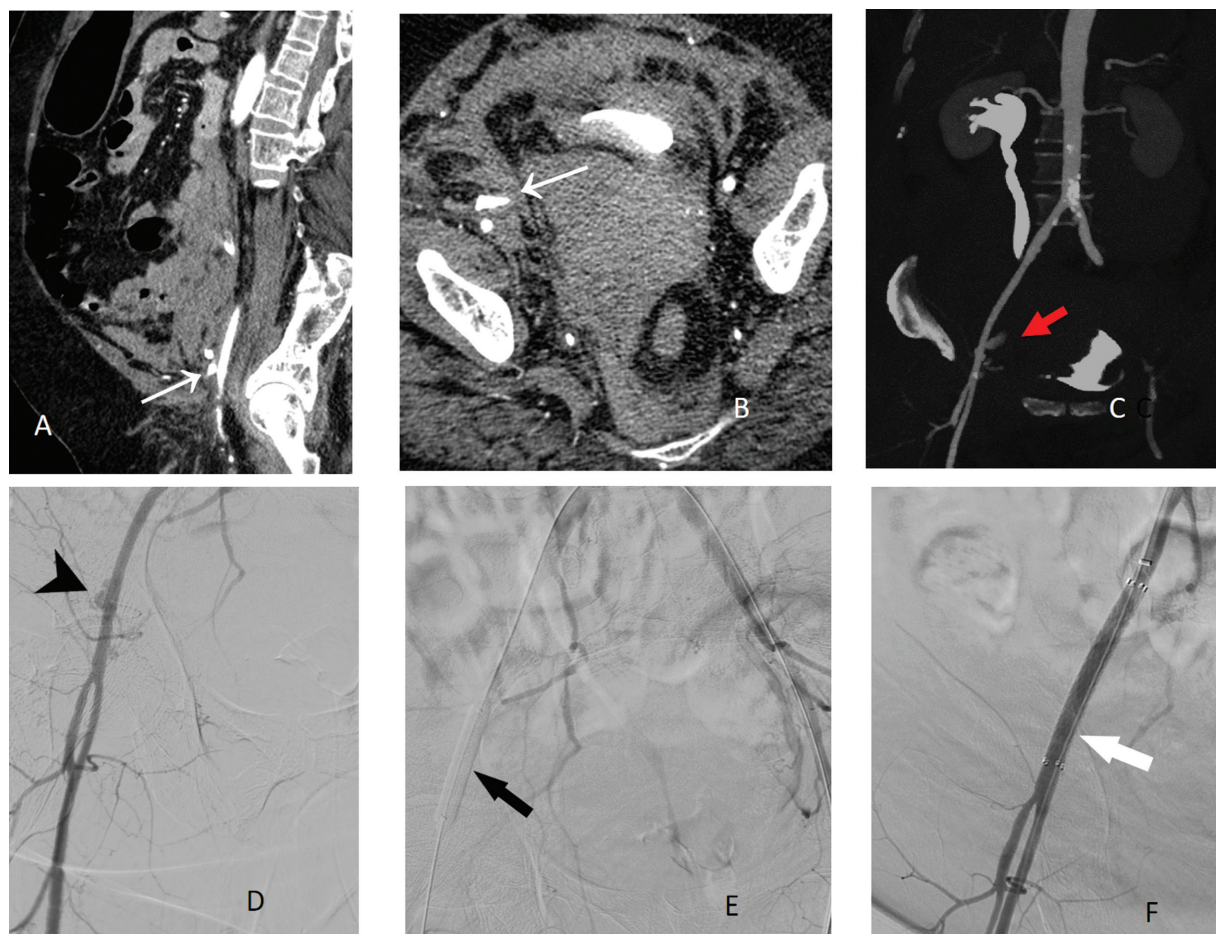


Fig. 1 Retroperitoneal bleeding. High puncture in the distal external iliac artery in a 47-year female resulted in a large retroperitoneal hematoma (RPH). Sagittal contrast-enhanced computed tomography (CECT) images show contrast extravasation from the external iliac artery (white arrow in A) with large RPH. Axial CECT (B) and coronal reformat images (C) show contrast extravasation (arrows in B and C) with adjacent hematoma. This patient did not respond to conservative treatment and was taken for an angiogram from the contralateral side. Angiogram (D) shows contrast extravasation (arrowhead) from external iliac artery. Low-pressure balloon angioplasty was attempted for 10 minutes (arrows in E) but failed. Self-expanding stent graft was placed resulting in a seal of the leak (arrows in F).

Access Artery Pseudoaneurysm

The incidence of PSA after percutaneous femoral arterial puncture is approximately 1.2%.¹³ Risk factors include female gender, elderly age, hypertension, arterial calcification, large arterial sheath, long sheath dwell time, and use of anticoagulation.¹⁴ Access below the level of femoral head leads to an increased incidence of PSA due to lack of adequate bone support.¹⁵ Access at the bifurcation of the CFA also increases the risk of PSA. The use of US can reduce the risk of pseudoaneurysms from 4.5 to 2.6%.¹⁶ The patient can be asymptomatic or present with pain and swelling in the groin. Expansion of the PSA can lead to distal embolization, arterial and venous occlusion, compression of adjacent neurovascular structures and rupture. US has a sensitivity of 85% for detection with yin-yang color flow inside the sac, but can be difficult in obese patients. CTA has a high sensitivity (90–96%) and specificity (98.7–100%) for detecting PSA and should be considered when in doubt.

Treatment depends on the size of the PSA, diameter of the neck of the PSA, and coagulation status of the patient. PSAs less than 2 mm in size can be followed with serial US as these usually spontaneously thrombose.^{17,18} US-guided compression (→Fig. 2) over the aneurysm neck for approximately 10 to 20 minutes shows a success rate of approximately 57 to 99% especially in PSAs with a narrow neck (2–4mm).¹⁹ The procedure is painful and takes longer in patients on anticoagulants. Direct percutaneous injection of thrombin (50–1500 IU) into the narrow-necked aneurysm sac is successful in 88 to 100%. Complications from thrombin injection into the PSA are rare, but can occur in 1.3 to 2.2%.²⁰ Distal thromboembolism is caused by direct thrombin injection into the neck of the aneurysm or accidental thrombin injection

into the artery. If the neck of the PSA is wide, inflating a balloon across the artery with an arterial access from the contralateral side avoids the risk of distal thromboembolism. Other embolic materials such as *n*-butyl cyanoacrylate have also been tried with success.²¹ Surgical repair is indicated for PSA when it is unresponsive to percutaneous treatment or results in compression of adjacent nerves and distal ischemic symptoms. Such patients have higher postoperative complications (7.4–71%), including infection and wound dehiscence.²² These complications are more often seen in women of more than 70 years of age and in patients on dual antiplatelet therapy (due to infection of seroma).²² A stent graft may be considered for PSA if there is a good landing zone and in patients who are unfit for surgery.¹²

Arteriovenous Fistula

AVF at the access site is an uncommon complication with an incidence of 0.017 to 0.86.^{23,24} It is more common in hypertensives, females, and patients on high doses of anticoagulants. It commonly involves the superficial femoral artery (SFA), profunda femoris artery (PFA), and less commonly the CFA.²⁵ A low femoral artery access below the bifurcation of CFA is associated with an increased risk of AVF since the common femoral vein runs between the SFA and PFA (anteroposterior relationship) below the femoral head.^{26–28} Though asymptomatic in majority of cases, an AVF can present with pain, pulsatile mass, distal ischemia, ipsilateral limb swelling due to chronic venous hypertension, dermatitis, skin ulceration or congestive heart failure depending on the size of the fistula and distal arterial steal.²⁷ US can show the abnormal communication between the artery and the vein with turbulent flow in the fistula with arterialized flow

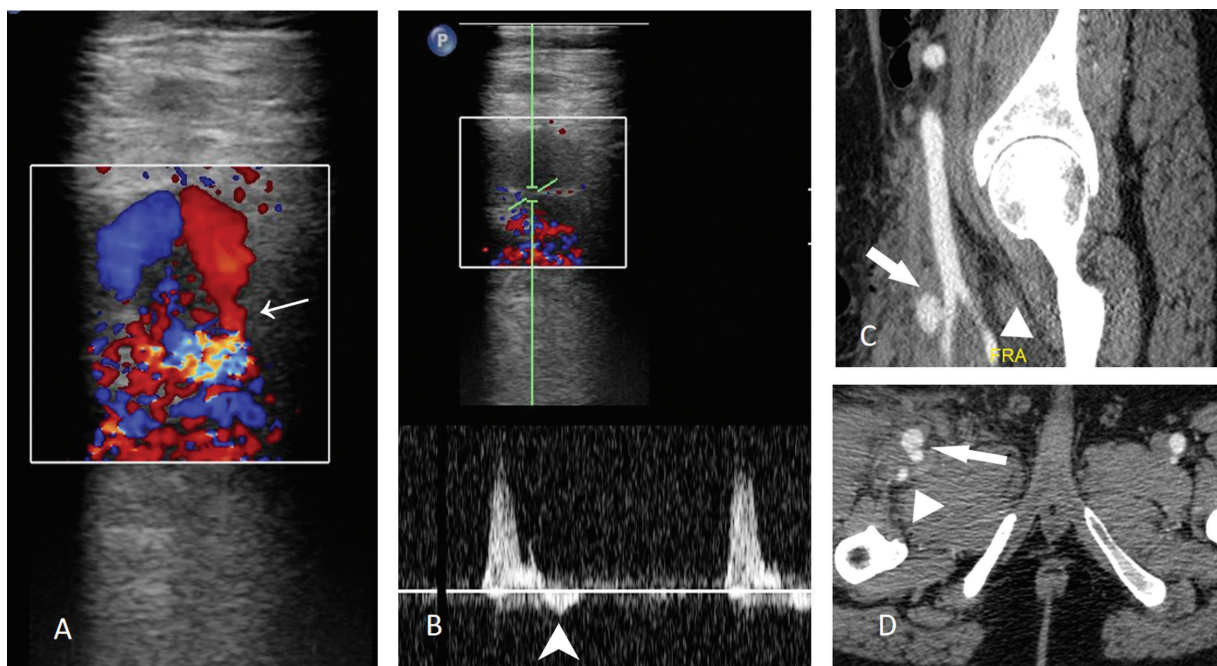


Fig. 2 Pseudoaneurysm (PSA) in a patient seen arising from superficial femoral artery (SFA) due to low puncture. Color Doppler (A) shows yin yang type of flow in pseudoaneurysm with a narrow neck (arrow) and on spectral trace Doppler (B) at the neck of aneurysm shows to and fro wave pattern (arrow in B). Contrast-enhanced computed tomographic images (C and D) show PSA with a narrow neck arising from SFA (bold white arrow) with normal profunda femoral artery. This patient underwent successful ultrasound-guided compression.

in the vein. It can also quantify the shunt volume which is usually 160 to 500 mL/min.²⁴ About a third of these AVFs have a flow of less than 200 mL/s and close spontaneously.²⁴ If the shunt volume is greater than 400 mL/min, there is a higher chance that the fistula would persist.²⁹ Cardiac overload can occur when the shunt volume is greater than 1200 mL/min. CT helps visualize the site of the fistula (►Fig. 3) and rule out associated PSA.

AVF persisting for more than 2 months, infection at the fistula site, and development of heart failure require closure of the fistula. US-guided compression with obliteration of the shunt is the first line of therapy. A poor success rate is seen in obese individuals, in the presence of large adjacent hematomas, fistulas lasting more than a month, short and wide fistula tracts, and in patients on anticoagulant therapy.²⁸ If the tract is long and lasts more than a month, tract maturation occurs, which can be embolized with coils. However, there is a high probability of coil prolapse into the arterial or venous system during embolization.^{28,30} Short-length self-expanding stent-graft can be tried in closing an AVF.³¹ However, stent graft at the bifurcation of the CFA is contraindicated since it jails PFA.²⁷ Stent grafts in CFA near the hip joint can kink and compress and are therefore better avoided, particularly in young patients who are good surgical candidates²⁵.

Guidewire and Catheter-Induced Injury

Guidewires and catheters can cause arterial dissection and perforation. They are commonly described in renal and infrapopliteal arteries. The injury is due to difficulty in passing the wires and catheters through the narrowed and spastic arteries.³² Straight tips and stiff wires also increase the risk of vessel injury.³³ When crossing an occlusion, the vessel perforation can be recognized by the deviation of the guidewire from the expected course of the artery. Early detection is necessary because further passage of the catheter or angioplasty balloon can increase the size of the

perforation. Most of these perforations are self-limiting and respond to balloon tamponade. Perforation of side branches can be problematic because they are detected late when the patient presents with a hematoma. Balloon tamponade of the main artery from which the tributary arises may not be effective because the tributaries have rich collateral supply secondary to chronic occlusions. Embolization of small side branches (►Fig. 4) with coils, gel foam, and cyanoacrylate glue is effective.³⁴ If the small side branch cannot be cannulated and bleeding is significant, open repair needs to be considered. Entrapment and fracture of the wire occur especially with subintimal angioplasty due to excessive rotation of the wire if the tip is not free. The guidewire components are thrombogenic and can lead to thrombosis and occlusion of the vessel. Treatment includes percutaneous removal of the wire fragment. In the event of a pinched wire, the use of excessive force can result in breakage of the wire. In such cases, a guiding catheter is passed over the guidewire with balloon inflated to hold the guidewire in place and the entire system is slowly removed.³⁵ In the event of a broken guidewire, percutaneous removal using a vascular snare can be attempted.³⁶ In select cases, fragments can also be left in situ and antiplatelet therapy given with close monitoring for migration of the fragment or ischemic events. Entrapment of catheter fragments can cause thrombosis and perforation of the artery and is treated similarly. Knot formation (►Fig. 5), especially with reverse curve catheters, can occur especially in bifurcations. Techniques to remove knot include fixation of the catheter in one of the side branches with the advancement of a wire, insertion of a straight guidewire (to open the knot), and contralateral arterial access with snaring through a larger sheath. If all procedures fail, arteriotomy needs performed for removal.³⁷ The mechanical interaction of catheters with the vessel wall can lead to arterial spasm, dissection, and perforation.³⁸ Spasm can be relieved by instilling intraarterial nitroglycerine (50–200 µg) provided the systolic blood pressure is more

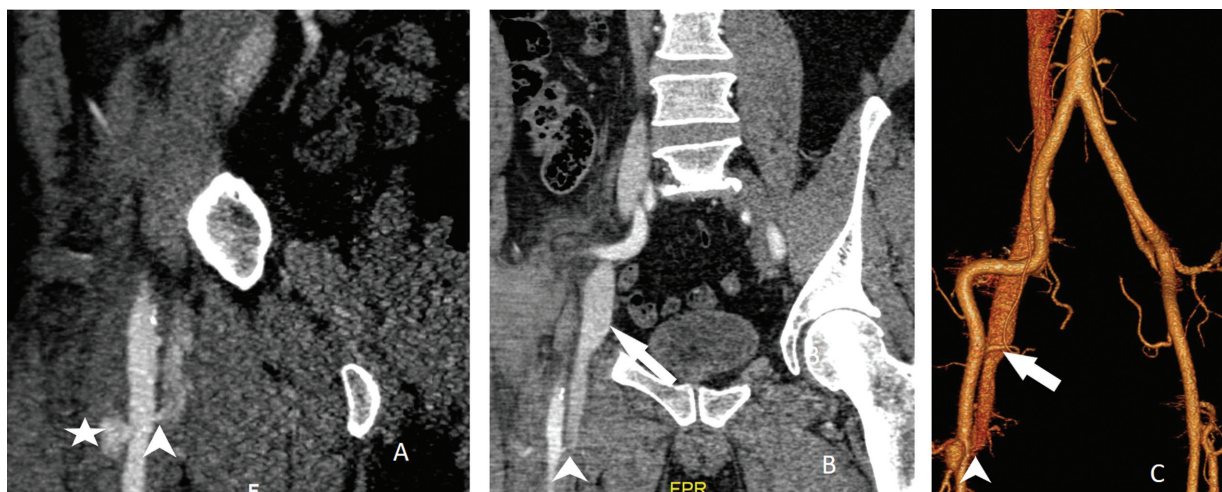


Fig. 3 Femoral arteriovenous fistula in a patient who had a lower access site in the superficial femoral artery (SFA) and complained of swelling and pain at the groin site. Computed tomographic angiogram in the sagittal sections (A) and coronal (B) and volumetric rendering technique images show a short and narrow tract between SFA and common femoral vein (CFV; arrowhead). Early opacification of CFV and iliac veins can be seen on the right side (white arrow). In addition, there is a small pseudoaneurysm from SFA (asterisk in A).

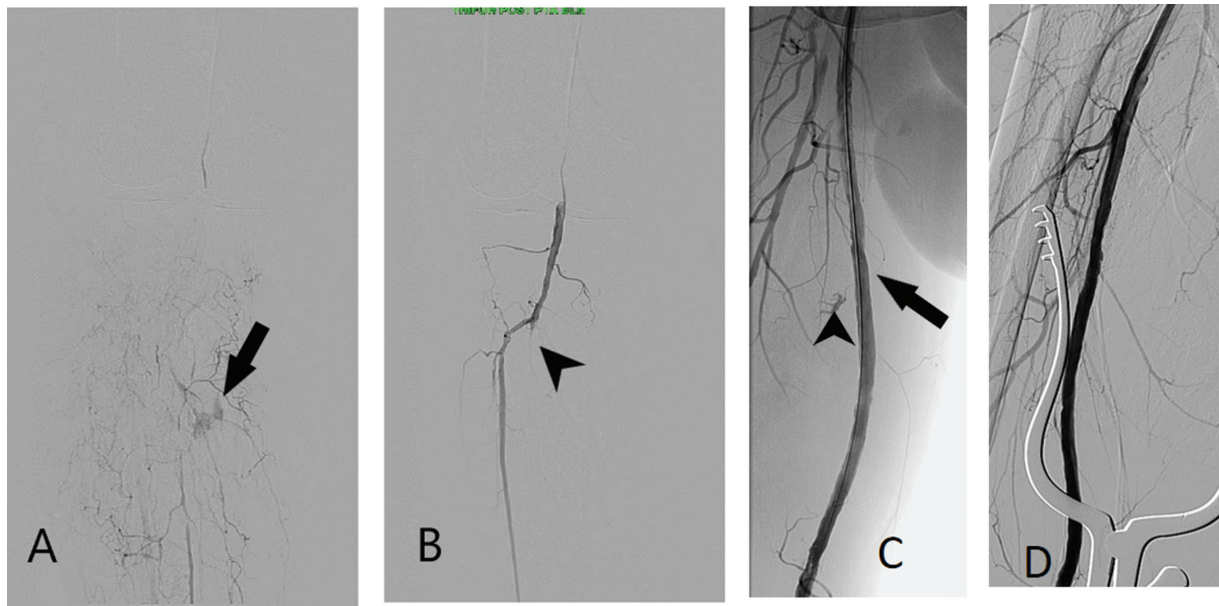


Fig. 4 Guidewire-induced perforations. Cannulation of Anterior tibial artery (ATA) using V14 guidewire resulted in perforation of one of the small branches of ATA (arrow in A), which was successfully embolized with Gelfoam (arrowhead in B). C and D show accidental rupture of one of the small branches of superficial femoral artery (SFA) due to guidewire with contrast extravasation from very small branch of SFA (arrowhead in C). This was recognized in the later stage of the procedure and was attempted to cannulate without any success. Temporary balloon occlusion of SFA was attempted for 15 minutes that also was unsuccessful. As there is significant thigh hematoma, he underwent surgical exploration on the table since it was done in hybrid theater. The final angiogram after ligating the branch vessel showed no contrast extravasation (D). ATA, anterior tibial artery.

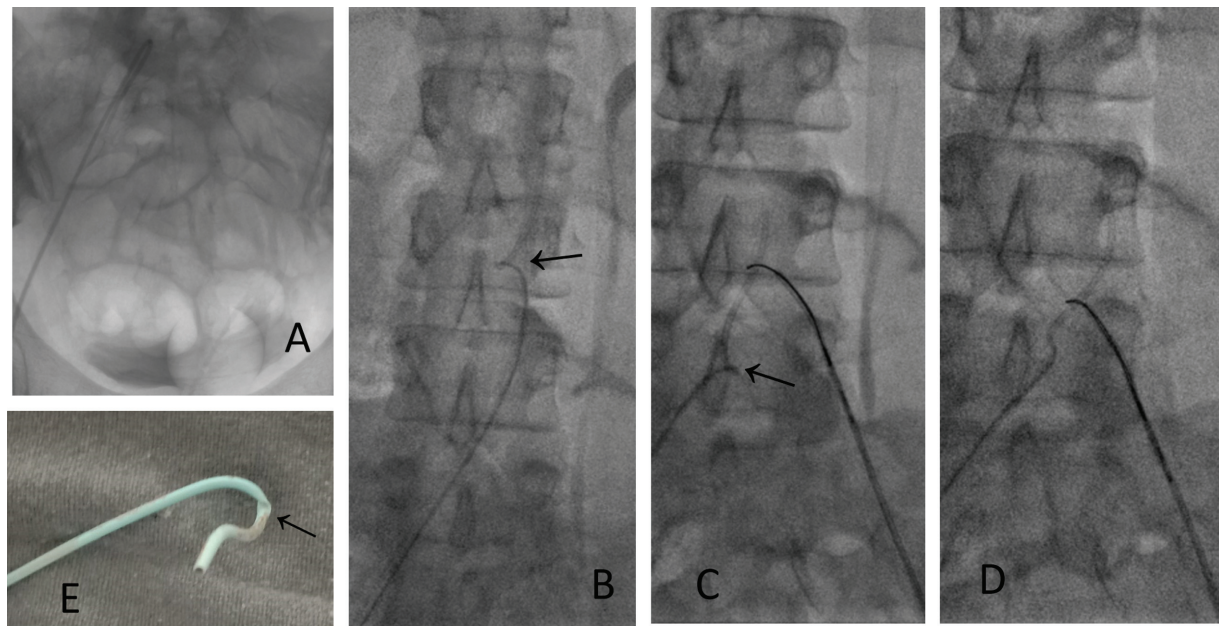


Fig. 5 Catheter kink. SIM catheter was used for crossover and resulted in kink (A). Initial attempts to unloop with tiff straight tip guidewire failed (B). Contralateral left femoral access was taken and a gooseneck snare was used to straighten the catheter (arrow in C), and removed from the ipsilateral side. (D) The kinked catheter (arrow). SIM, Simmons catheter; CIA, common iliac artery.

than 90 mm Hg.³⁹ Catheter biomaterial can also rarely cause anaphylaxis in certain patients.⁴⁰

Balloon Catheter-Induced Vessel Injury

BC rupture is an infrequent complication with an incidence around 3 to 4%.⁴¹ They can be diagnosed by loss of pressure in the inflation device and loss of contrast material at the end of the balloon.⁴² The risk factors include over inflation (above

the burst pressure), marked oversizing of the balloon, and severe vessel wall calcifications.⁴³ The rupture can be pin-hole, longitudinal, or circumferential fracture. Balloons are designed to tear longitudinally. Circumferential tears make removal of the catheter from sheath difficult since the ruptured fragments get everted. Any vigorous attempt made to remove results in embolization of balloon fragments, balloon entrapment, rupture, and vessel

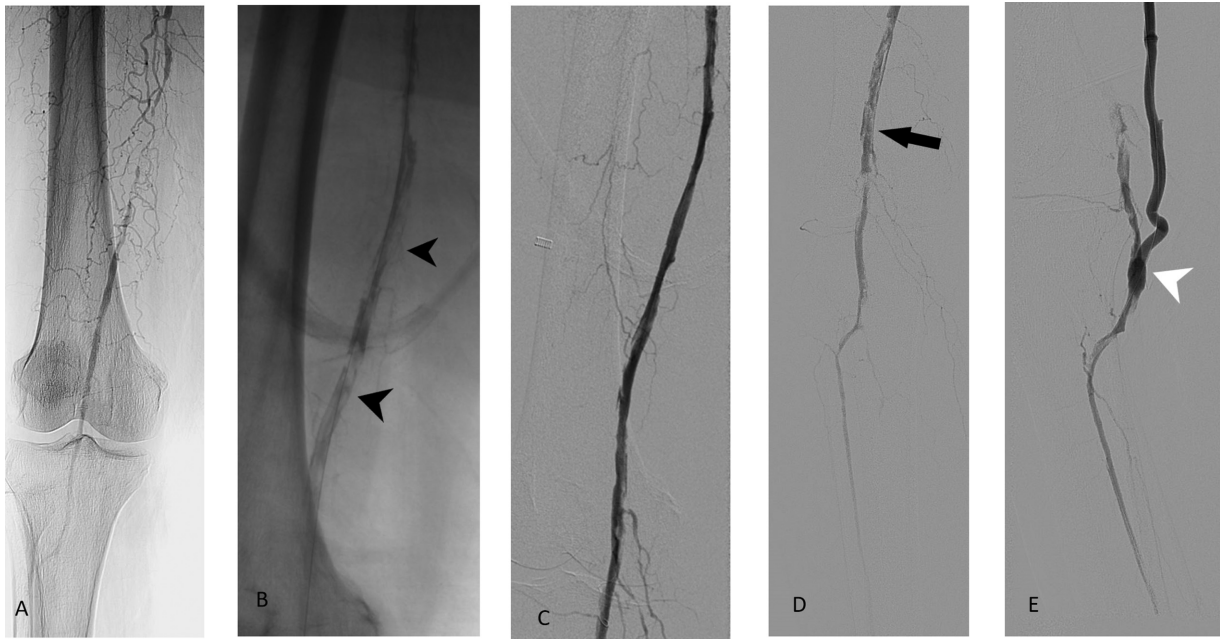


Fig. 6 (A) Acute in situ thrombosis of superficial femoral artery occlusion in a 65-year-old female patient with critical limb ischemia. After crossing the lesion subintimal angioplasty was done. Postangioplasty angiogram showed dissections and multiple filling defects all along the lumen (arrowhead in B). She underwent catheter-directed thrombolysis (CDT) with multiple side hole catheter for approximately 6 hours followed by balloon angioplasty resulted in a good opening of the lumen (C). Doppler after 12 hours showed re-occlusion of lumen with no color flow with repeat angiogram showing multiple filling defects in lumen (D). She underwent repeat CDT for next 24 hours and a repeat angiogram showed not much luminal gain. With the rest pain not improving, she underwent femoropopliteal bypass in the hybrid theater with post bypass angiogram (E) showing good distal flow.

dissection.^{44,45} An attempt may be made to cut the hub of the BC and exchanging with a larger sheath. Gentle traction may be applied to the BC until ruptured components at the tip of the sheath collapse into the larger sheath.⁴⁵ If endovascular procedures fail, arteriotomy and removal of balloon fragments are considered.

Acute Vessel Thrombosis

Acute in situ vascular thrombosis occurs in approximately 3.5%. Risk factors include female gender, long lesions, active smoking, smaller vessel caliber, and poor distal runoff.⁴⁶ Patients should be adequately anticoagulated with heparin (50–75 U/kg) to prevent thrombus formation. Acute thrombosis presents with acute limb pain during or immediately after the procedure. Angiogram can show complete cutoff of the distal vessels with contrast pooling in proximal artery. Acute arterial thrombosis should be treated immediately with catheter-directed thrombolysis (CDT) or thromboaspiration. CDT involves placing a multihole catheter in the thrombotic segment to infuse thrombolytics (→ Fig. 6). Reverse transcriptase plasminogen activators such as alteplase and tenecteplase are the preferred drug due to their high “bound-fibrin” specificity reducing bleeding risks. The Society of Interventional Radiology recommends a dose of 0.02 to 0.1 mg/kg/hour of alteplase (maximum recommended dose of 40 mg) for 24 to 36 hours.⁴⁷ If there is no improvement after 6 to 12 hours, an alternative treatment must be considered. CDT is associated with multiple hemorrhagic complications and the interventionalist should be aware of its contraindications. Monitoring of fibrinogen levels and blood

counts every 4 hours with a maintenance of fibrinogen levels more than 150mg/dL has been recommended by multiple authors.⁴⁸ Previously aspiration thrombectomy was considered in patients in whom CDT is contraindicated.⁴⁹ The use of aspiration thrombectomy can obviate thrombolytics thereby reducing bleeding complications but was associated with a high probability of failure and distal embolization.⁵⁰ However, with the advent of multiple new catheters and aspiration devices, they are becoming the first line of choice with a high success rate(90%).⁵¹ Stenting helps in opposing thrombus to the wall with rapid restoration of blood flow; however, it is not recommended routinely since it is associated with future thrombus risk and requires long-term antiplatelets therapy.⁵² The literature regarding glycoprotein IIb/IIIa inhibitors for acute thrombosis in lower extremity peripheral arterial disease had shown mixed results.⁵³ They may be considered as an adjunct to thrombolytic therapy in patients at higher risk of thrombolytic failure or recurrent thrombosis. This help reduce the formation of new thrombi, thereby reducing the dose of the thrombolytics.⁵⁴

Embolization

Distal embolization (→ Fig. 7) of plaque or thrombus occurs during the crossing of the lesion with wire, angioplasty, stent deployment, and with the use of atherectomy devices.⁵⁵ Embolization is more common in lesions with acute thrombosis, occluded stents, and with true lumen recanalization compared with subintimal angioplasty. If the wire readily crosses an occluded lesion, it may be acute or subacute thrombosis. Almost care should be taken in such cases to

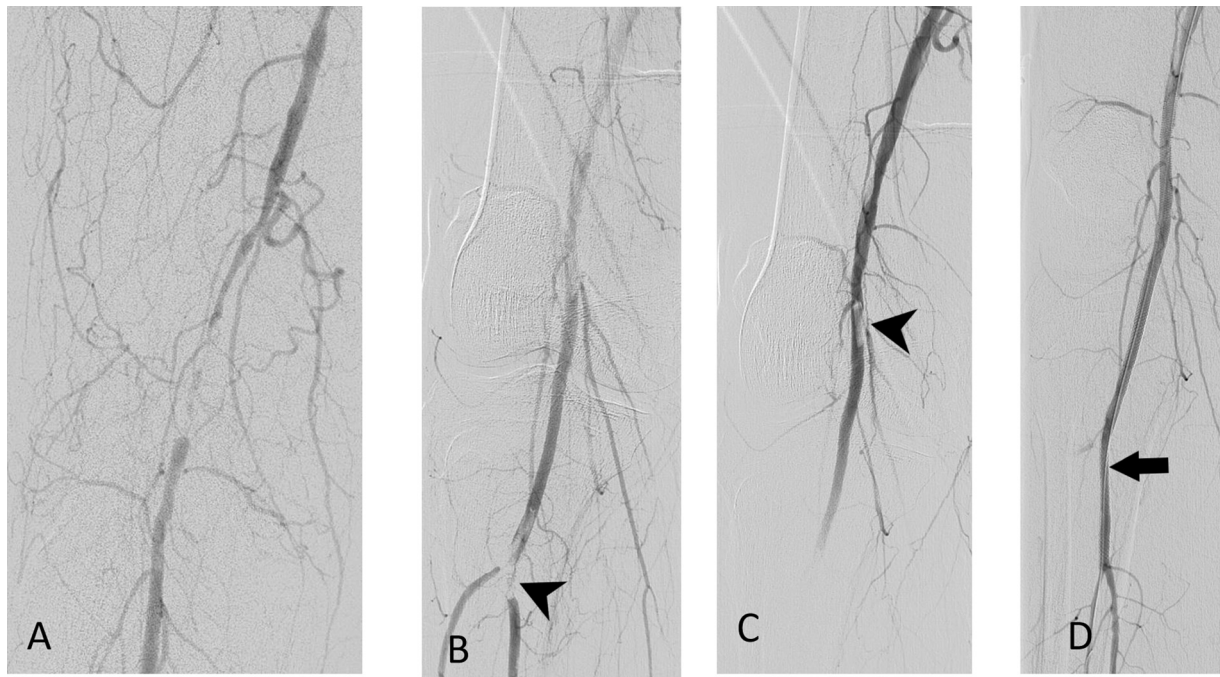


Fig. 7 Distal embolization. (A) Short segment occlusion of superficial femoral artery after angioplasty showing filling defect in the popliteal artery bifurcation suggestive of embolus (arrowhead in B). Thromboaspiration with a 6F guide catheter was attempted with aspiration of major part of embolus, however, with inadequate outflow (arrowhead in C). Given residual embolus in popliteal artery, stenting with vasculomimetic stent (Supera, Abbott, 4.5 × 100mm) was placed across the knee joint with a good opening of lumen.

prevent distal embolization particularly when there is a single distal runoff. The use of embolic protection devices can reduce distal embolization; however, it is not routinely recommended except in cases of atherectomy. The patient is usually asymptomatic if embolus is small. Larger embolism can result in symptoms of acute limb ischemia with severe leg pain. Aspiration of distal embolus using a large lumen guide catheter is a simple and rapid technique to restore the lumen. Compared with acute thrombosis, thrombolytics work poorly in distal embolization of chronic thrombotic occluded segments since embolic particles are either plaque or chronic in nature. In such situations, mechanical aspiration devices such as Indigo (Penumbra, Alameda, California, United States) can be attempted.⁴⁹ Microembolism and cholesterol embolism can present with leg pain, reticular changes in skin, or blue toe syndrome. Medical management with adequate heparinization can relieve the symptoms.

Arterial Rupture

Arterial rupture is observed in 0.8% of cases and requires immediate treatment because of the high mortality.⁵⁶ They can occur in patient with chronic steroid use, calcified plaques, vasculitis, and fibromuscular dysplasia or use of improper large-sized balloons for angioplasty.⁵⁷ Cutting balloon carries a high risk of arterial rupture, particularly with large or equal-sized arterial balloons.⁵⁸ Vessel size is an important determinant, as large vessels and the external iliac artery (due to relatively thin media and adventitia) are associated with a higher risk of rupture.⁵⁹ The patient usually complains of severe pain (due to stretching of the adventitia), which is a warning sign of rupture. Once a rupture is

identified, it is important not to remove the access wire across the lesion. The balloon should be inflated over the lesion with low pressure.⁶⁰ The timing of inflation is variable, with the average time varying from 5 to 30 minutes.^{61–64} Tamponade with a slightly larger balloon may be helpful when the initial tamponade is unsuccessful (→Fig. 8) but results are unpredictable.⁶⁵ Stent grafts can be placed in cases of nonresponsive cases and the vessel is expendable. The small branch vessel injury usually is self-limiting.

Arterial Dissection

Arterial dissection occurs with the use of large-sized balloons, heavily calcified plaques, small vessel lumen (< 5 mm), and long length occlusions (>15 cm).^{66–68} The use of atherectomy devices results in fewer dissections compared with balloon angioplasty.⁶⁹ Angiography reveals dissection flap with or without luminal narrowing. There are multiple classification systems for dissection,^{70,71} with treatment depending on the degree of luminal obstruction caused by the dissection flap. Nonflow-limiting dissections can be left untreated. Flow-limiting (NHLB D-F and Kobayashi C) dissection can be treated by prolonged (5–10 minutes) low pressure balloon angioplasty. Angioplasty results in the approximation of intima and media but has a high failure rate (→Fig. 9), especially in severe grades of dissection.⁶² Flow limiting dissections and long lengths of dissection (>10 cm) are associated with low patency following angioplasty and require stenting.⁶⁴ Spot stenting over the entry tear is associated with increased patency (71 to 55%) due to lesser chance of in-stent stenosis than stenting all along the length of dissection.⁷²

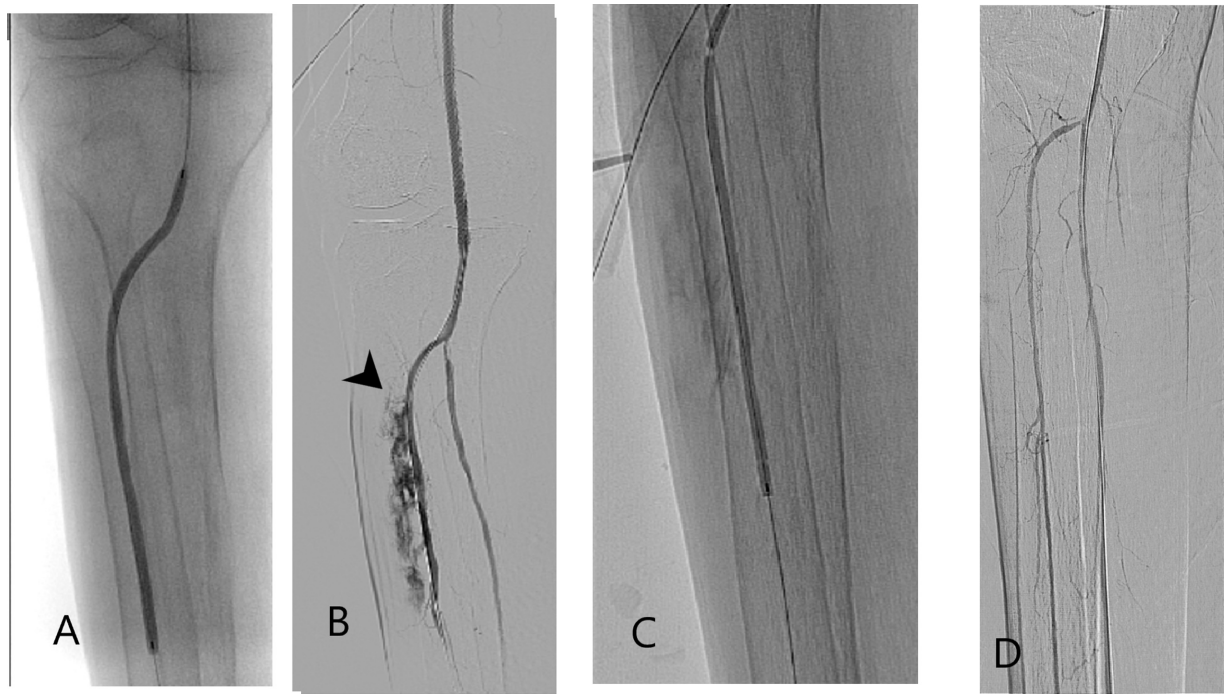


Fig. 8 Vessel rupture: Infrapopliteal angioplasty of ATA occlusion (A) resulting in rupture of ATA with contrast extravasation is seen (arrowhead in (B)). Prolonged inflation of the balloon (C) was done under low pressure for approximately 5 minutes resulting in the sealing of perforation (D).

Stent-Induced Complications

Complications can occur with both balloon-expandable (BE) and self-expandable (SE) stents. BE stents can migrate or displace off stent off the balloon during passage through the check flow valve of the sheath or while passing through tight curves resulting in the displacement of the stent from the balloon. SE stents can result in stent migration, elongation, and thrombosis. Stent thrombosis (–Fig. 10) defined as thrombosis within 5 mm of edges of stent or within the stent and occurs in 4.3%.⁷³ It is classified into acute (≤ 48 hours), subacute (>48 hours– ≤ 30 days), early (>30 days–1 year), and very late (> 1 year). Risk factors include noncompliance or resistance to antiplatelets, inadequate stent expansion, inadequate stent apposition, long stent length, multiple

stents, chronic total occlusion (CTO), and presence of heavy calcification.⁷⁴ Aspiration or mechanochemical thrombectomy is required for the management of stent thrombosis. In-stent stenosis is best addressed with laser atherectomy and balloon dilatation with or without distal embolic protection.⁷⁵ Stents also result in collapse, kinking, compression, and acute fracture due to elastic recoil of the artery. Plaque modification with atherectomy and balloon dilatation helps prevent stent kinking or elongation. Proper technique is also important for delivering the planned length of stent. The use of intravascular US may help preventing under-sizing or oversizing of the stent.⁷⁶

Access Site Infection

Infection is a rare complication after diagnostic angiogram or therapeutic procedure and occurs in less than 1% of the cases. They are caused by poor patient preparation, concomitant systemic infection or due to vascular closure devices (mainly plug based devices).⁷⁷ Infection can range from erythema, cellulitis, or abscess formation with staphylococcus epidermidis and aureus being the common organism isolated. Blood culture and appropriate antibiotics should be started if infection is suspected. Local abscess if any needs to be drained percutaneously.

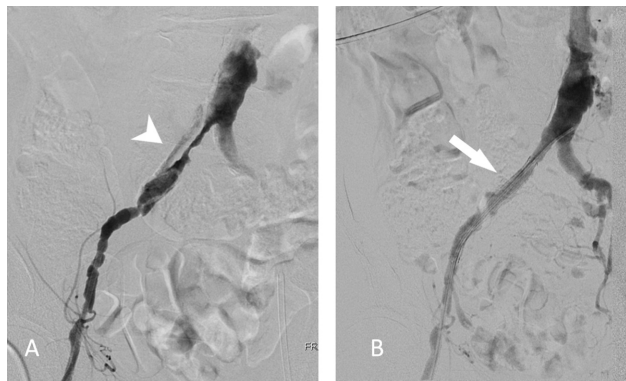


Fig. 9 Vessel dissection. Post-procedure check angiogram of treated left side distal superficial femoral artery occlusion showing significant dissection in the right CIA (white arrowhead in A). There was decreased right femoral pulse. Attempted with a low-pressure balloon was not successful and stenting was done. The final angiogram (B) showed good flow across the stent.

Reperfusion Injury and Compartment Syndrome

This occurs after ischemia of large muscle masses, which develop local and systemic metabolic abnormalities after reperfusion of ischemic tissues. The incidence is approximately 7.5% in patients with acute arterial occlusion and has a mortality rate of 4.7%.⁷⁵ Oxygen-free radicals are reintroduced into ischemic tissue during reperfusion, resulting in cellular damage, hyperkalemia, acidosis,

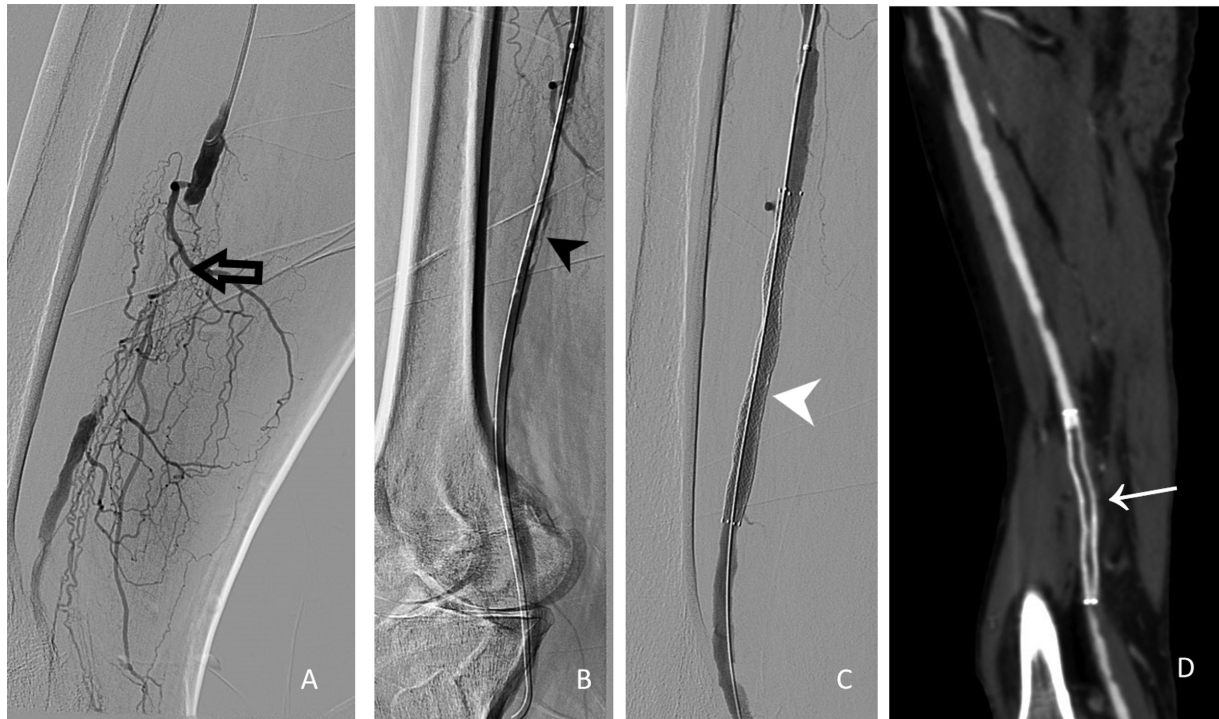

Fig. 10 (A) Acute stent thrombosis of right superficial femoral artery. After crossing the lesion subintima balloon angioplasty was done which showed dissections and thrombus in the lumen (arrowhead in B) and hence underwent stenting which showed good flow in the stent (arrowhead in C). He presented after 2 days with increased pain in the calf. Computed tomography angiogram showed acute in-stent thrombosis (white arrow in D) which was lysed by catheter-directed thrombolysis.

myoglobinuria, and renal failure. Preventive measures include alkalinization, osmotic diuresis, and correction of hyperkalemia. Antioxidant vitamins and calcium channel blockers are also helpful in reducing cell damage. Compartment syndrome also occurs after reperfusion due to edema and increased pressure in muscle compartments sandwiched between inelastic fascia and bone impairing tissue perfusion. Risk factors of compartment include prolonged ischemia time, young age, inadequate arterial collaterals, acute onset, and hypotension.⁷⁸ Diagnosis is based on clinical criteria including pain on flexion or passive extension of the foot, paraesthesia, anesthesia, paresis, or paralysis of the limb. Fasciotomy should be

performed promptly because it relieves muscle compression, restores capillary blood flow, and restores the caliber of arteries and veins.

Conclusion

In conclusion, every interventionalist must be aware of the possible expected complications during endovascular treatment of peripheral arterial disease. The clinical status of the patient and angiogram help in early diagnosing the complications. Early identification, use of accessories like US, and vigil during each step of the procedure (summarized in ►Table 1) can reduce the complications. Comprehensive

Table 1 Summary of common rules to avoid complications during peripheral vascular interventions

1. Use US-guided needle entry
2. Strict aseptic and sterile precautions
3. Single wall puncture in thrombocytopenia and coagulopathy
4. Puncture CFA at lower femoral head level
5. Confirming access site suitability for closure device before deployment
6. Anticoagulate early in the case prior to performing any intervention
7. Use embolic protection device in single vessel runoff
8. Use IVUS for appropriate balloon and stent sizing as well as confirming intra luminal location in CTOs
9. Ensure availability of bail out covered stents
10. Plan surgical backup in complex cases as alternative

Abbreviations: CFA, common femoral artery; CTOs, —; IVUS, intravenous ultrasound.

knowledge of the treatment of each complication helps in better patient outcomes.

Conflict of Interest

None declared.

Presentation at a Conference

Not presented in any conference.

References

- Chandrasekar B, Doucet S, Bilodeau L, et al. Complications of cardiac catheterization in the current era: a single-center experience. *Catheter Cardiovasc Interv* 2001;52(03):289–295
- Brenna CTA, Ku JC, Pasarikovski CR, et al. Access-site complications in ultrasound-guided endovascular thrombectomy: a single-institution retrospective cohort study. *Neurosurg Focus* 2021; 51(01):E3
- Sherev DA, Shaw RE, Brent BN. Angiographic predictors of femoral access site complications: implication for planned percutaneous coronary intervention. *Catheter Cardiovasc Interv* 2005;65(02): 196–202
- Bhatty S, Cooke R, Shetty R, Jovin IS. Femoral vascular access-site complications in the cardiac catheterization laboratory: diagnosis and management. *Interv Cardiol* 2011;3(04):503–514
- Sajnani N, Bogart DB. Retroperitoneal hemorrhage as a complication of percutaneous intervention: report of 2 cases and review of the literature. *Open Cardiovasc Med J* 2013;7:16–22
- Piper WD, Malenka DJ, Ryan TJ Jr, et al; Northern New England Cardiovascular Disease Study Group. Predicting vascular complications in percutaneous coronary interventions. *Am Heart J* 2003; 145(06):1022–1029
- Sui YG, Teng SY, Qian J, et al. Cross-sectional study of retroperitoneal hematoma after invasive intervention in a Chinese population: prevalence, characteristics, management and outcomes. *Exp Ther Med* 2020;20(04):2975–2984
- Kent KC, Moscucci M, Mansour KA, et al. Retroperitoneal hematoma after cardiac catheterization: prevalence, risk factors, and optimal management. *J Vasc Surg* 1994;20(06):905–910, discussion 910–913
- Spahn DR, Bouillon B, Cerny V, et al. The European guideline on management of major bleeding and coagulopathy following trauma: fifth edition. *Crit Care* 2019;23(01):98
- Chee YE, Liu SE, Irwin MG. Management of bleeding in vascular surgery. *Br J Anaesth* 2016;117(Suppl 2):ii85–ii94
- Samal AK, White CJ. Percutaneous management of access site complications. *Catheter Cardiovasc Interv* 2002;57(01):12–23
- Tsetis D. Endovascular treatment of complications of femoral arterial access. *Cardiovasc Intervent Radiol* 2010;33(03):457–468
- Ohlow MA, Secknus MA, von Korn H, et al. Incidence and outcome of femoral vascular complications among 18,165 patients undergoing cardiac catheterisation. *Int J Cardiol* 2009;135(01):66–71
- Lee MS, Applegate B, Rao SV, Kirtane AJ, Seto A, Stone GW. Minimizing femoral artery access complications during percutaneous coronary intervention: a comprehensive review. *Catheter Cardiovasc Interv* 2014;84(01):62–69
- Altin RS, Flicker S, Naidech HJ. Pseudoaneurysm and arteriovenous fistula after femoral artery catheterization: association with low femoral punctures. *AJR Am J Roentgenol* 1989;152(03):629–631
- Gabriel M, Pawlaczky K, Waliszewski K, Krasiński Z, Majewski W. Location of femoral artery puncture site and the risk of post-catheterization pseudoaneurysm formation. *Int J Cardiol* 2007; 120(02):167–171
- Miller-Thomas MM, West OC, Cohen AM. Diagnosing traumatic arterial injury in the extremities with CT angiography: pearls and pitfalls. *Radiographics* 2005;25(Suppl 1):S133–S142
- Madia C. Management trends for postcatheterization femoral artery pseudoaneurysms. *JAAPA* 2019;32(06):15–18
- Stolt M, Braun-Dullaeus R, Herold J. Do not underestimate the femoral pseudoaneurysm. *Vasa* 2018;47(03):177–185
- Kurzawski J, Sadowski M, Janion-Sadowska A. Complications of percutaneous thrombin injection in patients with postcatheterization femoral pseudoaneurysm. *J Clin Ultrasound* 2016;44(03): 188–195
- Aytekin C, Firat A, Yildirim E, Kirbas I, Boyvat F. Ultrasound-guided glue injection as alternative treatment of femoral pseudoaneurysms. *Cardiovasc Intervent Radiol* 2004;27(06):612–615
- San Norberto García EM, González-Fajardo JA, Gutiérrez V, Carrera S, Vaquero C. Femoral pseudoaneurysms post-cardiac catheterization surgically treated: evolution and prognosis. *Interact Cardiovasc Thorac Surg* 2009;8(03):353–357
- Glaser RL, McKellar D, Scher KS. Arteriovenous fistulas after cardiac catheterization. *Arch Surg* 1989;124(11):1313–1315
- Kelm M, Perings SM, Jax T, et al. Incidence and clinical outcome of iatrogenic femoral arteriovenous fistulas: implications for risk stratification and treatment. *J Am Coll Cardiol* 2002;40(02): 291–297
- Thalhammer C, Kirchherr AS, Uhlich F, Waigand J, Gross CM. Postcatheterization pseudoaneurysms and arteriovenous fistulas: repair with percutaneous implantation of endovascular covered stents. *Radiology* 2000;214(01):127–131
- Thavarajan D, Bakran A. Iatrogenic arteriovenous fistula in the groin presenting as cardiac failure. *NDT Plus* 2009;2(01):46–48
- Ruebben A, Tettoni S, Muratore P, Rossato D, Savio D, Rabbia C. Arteriovenous fistulas induced by femoral arterial catheterization: percutaneous treatment. *Radiology* 1998;209(03):729–734
- Lemaire JM, Dondelinger RF. Percutaneous coil embolization of iatrogenic femoral arteriovenous fistula or pseudo-aneurysm. *Eur J Radiol* 1994;18(02):96–100
- Perings SM, Kelm M, Lauer T, Strauer BE. [Duplex ultrasound determination of shunt volume in iatrogenic arteriovenous fistulas after heart catheterization]. *Z Kardiol* 2002;91(06):481–486
- Vaninbrouckx I, Vandekerckhof J. Endovascular stent graft treatment for iatrogenic arteriovenous fistulas after femoral catheterisation. *Acta Chir Belg* 2004;104(05):584–587
- Onal B, Kosar S, Gumus T, Ilgit ET, Akpek S. Postcatheterization femoral arteriovenous fistulas: endovascular treatment with stent-grafts. *Cardiovasc Intervent Radiol* 2004;27(05):453–458
- Gardiner GA Jr, Meyerovitz MF, Stokes KR, Clouse ME, Harrington DP, Bettmann MA. Complications of transluminal angioplasty. *Radiology* 1986;159(01):201–208
- Rizk T, Patel D, Dimitri NG, Mansour K, Ramakrishnan V. Iatrogenic arterial perforation during endovascular interventions. *Cureus* 2020;12(08):e10018
- Atta I, Zekilah S, El Abd A, Fouda H, Sawaby A. Arterial perforation during lower limb percutaneous transluminal angioplasty for treating critical lower limb ischemia. *Egypt J Surg* 2021;40(02): 522–527
- Danek BA, Karatasakis A, Brilakis ES. Consequences and treatment of guidewire entrapment and fracture during percutaneous coronary intervention. *Cardiovasc Revasc Med* 2016;17(02):129–133
- Al-Moghairi AM, Al-Amri HS. Management of retained intervention guide-wire: a literature review. *Curr Cardiol Rev* 2013;9(03): 260–266
- Silberstein M, Tress BM, Hennessy O. Selecting the right technique to reform a reverse curve catheter (Simmons style): critical review. *Cardiovasc Intervent Radiol* 1992;15(03):171–176
- Zeller T, Frank U, Müller C, et al. Technological advances in the design of catheters and devices used in renal artery interventions: impact on complications. *J Endovasc Ther* 2003;10(05):1006–1014
- Watts MM. Pharmacology of peripheral arterial disease in the angio suite: what every interventionalist should know. *Semin Intervent Radiol* 2018;35(05):393–398

- 40 Balloon Rupture During Coronary Angioplasty - Conrad C. Sempendorfer, Alexios P. Dimas, Adnan Zaidi, Jay Hollman, Irving Franco, Valerie Knezinek, Robert E. Hobbs, 1986 [Internet]. 2022 [cited 2022 Sep 6]. Accessed December 14, 2022, at: <https://journals.sagepub.com/doi/abs/10.1177/000331978603701106>
- 41 Rhodes A, Evans LE, Alhazzani W, et al. Surviving sepsis campaign: international guidelines for management of sepsis and septic shock: 2016. *Intensive Care Med* 2017;43(03):304–377
- 42 Basile A, Rebonato A, Failla G, et al. Early post-procedural patients compliance and VAS after UAE through transradial versus transfemoral approach: preliminary results. *Radiol Med (Torino)* 2018; 123(11):885–889
- 43 Andreou A. Balloon rupture during stent postdilatation: lesson from a movie. *Curr Res Cardiol*. 2016;3:25–26
- 44 Murata R, Kamiizumi Y, Haneda T, et al. Retrieval strategy for ruptured balloon with circumferential tear during angioplasty for arteriovenous fistula in hemodialysis patients. *J Vasc Access* 2020; 21(02):246–250
- 45 Tegtmeyer CJ, Bezirdjian DR. Removing the stuck, ruptured angioplasty balloon catheter. *Radiology* 1981;139(01):231–232
- 46 Davies MG, Bismuth J, Saad WE, et al. Implications of in situ thrombosis and distal embolization during superficial femoral artery endoluminal intervention. *Ann Vasc Surg* 2010;24(01): 14–22
- 47 Patel IJ, Rahim S, Davidson JC, et al. Society of Interventional Radiology Consensus Guidelines for the Periprocedural Management of Thrombotic and Bleeding Risk in Patients Undergoing Percutaneous Image-Guided Interventions-Part II: Recommendations: Endorsed by the Canadian Association for Interventional Radiology and the Cardiovascular and Interventional Radiological Society of Europe. *J Vasc Interv Radiol* 2019;30(08):1168–1184.e1
- 48 Kaufman C, Kinney T, Quencer K. Practice trends of fibrinogen monitoring in thrombolysis. *J Clin Med* 2018;7(05):111
- 49 Razavi MK. Detection and treatment of acute thromboembolic events in the lower extremities. *Tech Vasc Interv Radiol* 2011;14 (02):80–85
- 50 Kwok CHR, Fleming S, Chan KKC, et al. Aspiration thrombectomy versus conventional catheter-directed thrombolysis as first-line treatment for noniatrogenic acute lower limb ischemia. *J Vasc Interv Radiol* 2018;29(05):607–613
- 51 de Donato G, Pasqui E, Sponza M, et al; INDIAN trial collaborators. Safety and efficacy of vacuum assisted thrombo-aspiration in patients with acute lower limb ischaemia: the INDIAN trial. *Eur J Vasc Endovasc Surg* 2021;61(05):820–828
- 52 Kim C, Jeon W, Shin T, et al. Stent-assisted recanalisation of acute occlusive arteries in patients with acute limb ischaemia. *Eur J Vasc Endovasc Surg* 2010;39(01):89–96
- 53 Stangl PA, Lewis S. Review of currently available GP IIb/IIIa inhibitors and their role in peripheral vascular interventions. *Semin Intervent Radiol* 2010;27(04):412–421
- 54 Altenburg A, Haage P. Antiplatelet and anticoagulant drugs in interventional radiology. *Cardiovasc Intervent Radiol* 2012;35 (01):30–42
- 55 Lam RC, Shah S, Faries PL, McKinsey JF, Kent KC, Morrissey NJ. Incidence and clinical significance of distal embolization during percutaneous interventions involving the superficial femoral artery. *J Vasc Surg* 2007;46(06):1155–1159
- 56 Allaire E, Melliere D, Poussier B, Kobeiter H, Desgranges P, Becquemin JP. Iliac artery rupture during balloon dilatation: what treatment? *Ann Vasc Surg* 2003;17(03):306–314
- 57 Darcy M. Complications of iliac angioplasty and stenting. *Tech Vasc Interv Radiol* 2000;3(04):226–239
- 58 Tanemoto M, Abe T, Chaki T, Satoh F, Ishibashi T, Ito S. Cutting balloon angioplasty of resistant renal artery stenosis caused by fibromuscular dysplasia. *J Vasc Surg* 2005;41(05):898–901
- 59 Ge BH, Copelan A, Scola D, Watts MM. Iatrogenic percutaneous vascular injuries: clinical presentation, imaging, and management. *Semin Intervent Radiol* 2015;32(02):108–122
- 60 Arce-Gonzalez JM, Schwartz L, Ganassin L, Henderson M, Aldridge H. Complications associated with the guide wire in percutaneous transluminal coronary angioplasty. *J Am Coll Cardiol* 1987;10 (01):218–221
- 61 Joseph N, Levy E, Lipman S. Angioplasty-related iliac artery rupture: treatment by temporary balloon occlusion. *Cardiovasc Intervent Radiol* 1987;10(05):276–279
- 62 Brountzos EN, Ptohis N, Triantafyllidi H, et al. Renal artery rupture following cutting balloon angioplasty for fibromuscular dysplasia: a case report. *Cases J* 2009;2:8881
- 63 Ashenburg RJ, Blair RJ, Rivera FJ, Weigele JB. Renal arterial rupture complicating transluminal angioplasty: successful conservative management. *Radiology* 1990;174(3 Pt 2):983–985
- 64 Cooper SG, Sofocleous CT. Percutaneous management of angioplasty-related iliac artery rupture with preservation of luminal patency by prolonged balloon tamponade. *J Vasc Interv Radiol* 1998;9(1 Pt 1):81–83
- 65 Marin ML, Veith FJ, Panetta TF, et al. Transluminally placed endovascular stented graft repair for arterial trauma. *J Vasc Surg* 1994;20(03):466–472, discussion 472–473
- 66 Murphy TP, Dorfman GS, Segall M, Carney WJ Jr. Iatrogenic arterial dissection: treatment by percutaneous transluminal angioplasty. *Cardiovasc Intervent Radiol* 1991;14(05):302–306
- 67 Fitzgerald PJ, Ports TA, Yock PG. Contribution of localized calcium deposits to dissection after angioplasty. An observational study using intravascular ultrasound. *Circulation* 1992;86(01):64–70
- 68 Fujihara M, Takahara M, Sasaki S, et al. Angiographic dissection patterns and patency outcomes after balloon angioplasty for superficial femoral artery disease. *J Endovasc Ther* 2017;24(03):367–375
- 69 Shamma NW, Lam R, Mustapha J, et al. Comparison of orbital atherectomy plus balloon angioplasty vs. balloon angioplasty alone in patients with critical limb ischemia: results of the CALCIUM 360 randomized pilot trial. *J Endovasc Ther* 2012;19 (04):480–488
- 70 Huber MS, Mooney JF, Madison J, Mooney MR. Use of a morphologic classification to predict clinical outcome after dissection from coronary angioplasty. *Am J Cardiol* 1991;68(05):467–471
- 71 Kobayashi N, Hirano K, Yamawaki M, et al. Simple classification and clinical outcomes of angiographic dissection after balloon angioplasty for femoropopliteal disease. *J Vasc Surg* 2018;67(04): 1151–1158
- 72 Hong SK, Jang JY, Kang MJ, Han IW, Kim SW. Comparison of clinical outcome and cost-effectiveness after various preoperative biliary drainage methods in periampullary cancer with obstructive jaundice. *J Korean Med Sci* 2012;27(04):356–362
- 73 Banerjee S, Sarode K, Mohammad A, et al. Femoropopliteal artery stent thrombosis: report from the excellence in peripheral artery disease registry. *Circ Cardiovasc Interv* 2016;9(02):e002730
- 74 Lüscher TF, Steffel J, Eberli FR, et al. Drug-eluting stent and coronary thrombosis: biological mechanisms and clinical implications. *Circulation* 2007;115(08):1051–1058
- 75 Dippel EJ, Makam P, Kovach R, et al; EXCITE ISR Investigators. Randomized controlled study of excimer laser atherectomy for treatment of femoropopliteal in-stent restenosis: initial results from the EXCITE ISR trial (EXCimer Laser Randomized Controlled Study for Treatment of Femoropopliteal In-Stent Restenosis). *JACC Cardiovasc Interv* 2015;8(1 Pt A):92–101
- 76 Shamma NW, Radaideh Q, Shamma WJ, Daher GE, Rachwan RJ, Radaideh Y. The role of precise imaging with intravascular ultrasound in coronary and peripheral interventions. *Vasc Health Risk Manag* 2019;15:283–290
- 77 Johanning JM, Franklin DP, Elmore JR, Han DC. Femoral artery infections associated with percutaneous arterial closure devices. *J Vasc Surg* 2001;34(06):983–985
- 78 Olivia G, Petter L, Håkan P. Acute compartment syndrome following thrombolysis for acute lower limb ischemia. *Ann Vasc Surg* 2022;79:182–190