




Comparison of Nasal Analysis by Photographs (2D) against Low-cost Surface Laser Imaging (3D) and against Computed Axial Tomography Imaging

Marco Aurelio Rendón-Medina¹  Erik Hanson-Viana¹ Maria de los Angeles Mendoza-Velez¹
Rubén Hernández-Ordoñez¹ Hecly Lya Vazquez-Morales¹ Ricardo C. Pacheco-López¹

¹Department of Plastic and Reconstructive Surgery in The General Hospital Ruben Leñero, Mexico City, Mexico

Address for correspondence Marco Aurelio Rendon Medina, MD, Hospital General "Dr. Ruben Leñero," Calle Salvador Díaz Mirón 344, Miguel Hidalgo, 11340 Ciudad de México, México (e-mail: dr.rendon1989@gmail.com).

Indian J Plast Surg 2023;56:147–152.

Abstract

Introduction In aesthetic surgery, we have a few evaluation tools that numerically and objectively measure the changes we make in patients. This article aimed to evaluate the nasal systematic analysis and compare findings between the three systems of nasal evaluation: photographs 2D, 3D surface imaging with the Kinect system, and 3D CT scan imaging.

Methods We designed a longitudinal and descriptive prospective study with simple non-blind randomization. To compare the systematic nasal analysis between the three methods. If the findings are similar, all three methods would be useful in independent clinical scenarios.

Results A total of 42 observations were included finding a minimum age of 21 with a mean of 28 years old. Also, 64% were female, 93% had adequate facial proportions, and 50% were Fitzpatrick III. For outcome statistics, we found differential nasal deviation between 3D images with a mean of 6.53 mm. While when comparing the nasal dorsum length, we found a statistical significance of $p = 0.051$. When comparing the nasal dorsum length index, we found no significant difference $p = 0.32$. Also, we did not find statistical significance when comparing the nasofrontal angle and tip rotation angle $p = 1$ for both.

Conclusion We found that the population we serve has characteristics of Hispanic mestizo nose. The three methods seem to evaluate systematic nasal analysis in a very similar way, and any of them can be used depending on the scenario and the needs of plastic surgeons.

Keywords

- ▶ 3D surface imaging
- ▶ rhinoplasty
- ▶ nasal analysis
- ▶ CT scan imaging

Introduction

Facial aesthetic surgery is a challenging discipline in plastic surgery. Measuring and comparing outcomes such as swelling, asymmetries, and indexes are very difficult in plain two-

dimensional photographs. More papers are using photogrammetry as a tool in proving their hypothesis. However, the hardware and software are too expensive or difficult to use.^{1,2}

In aesthetic surgery, we have a few resources to measure our actions. Subjective parametric values can only be

article published online
December 16, 2022

DOI <https://doi.org/10.1055/s-0042-1759724>.
ISSN 0970-0358.

© 2022. Association of Plastic Surgeons of India. All rights reserved. This is an open access article published by Thieme under the terms of the Creative Commons Attribution-NonDerivative-NonCommercial-License, permitting copying and reproduction so long as the original work is given appropriate credit. Contents may not be used for commercial purposes, or adapted, remixed, transformed or built upon. (<https://creativecommons.org/licenses/by-nc-nd/4.0/>)
Thieme Medical and Scientific Publishers Pvt. Ltd., A-12, 2nd Floor, Sector 2, Noida-201301 UP, India

collected through opinions, satisfaction surveys, and highly subjective scales. We have a few evaluation tools that numerically and objectively measure the changes we make in patients.³⁻⁹ Human beings make a self-image based on imagination. For this reason, it is logical to think that all the elements: photographs and 3D images will improve patient–doctor communication, potentially simplifying the expectations of the patient and those of the surgeon.

To create more scientifically valid clinical studies, it is important to have means to measure results. The ideal measuring tool should be accurate, precise, low cost, non-invasive, easy to use, easy to replicate, and easy to read. Up to date, three measuring systems had been popular in plastic surgery: photogrammetry, 3D surface imaging, and 3D imaging with computer axial tomography.¹⁰⁻¹⁷

Photogrammetry is a three-dimensional coordinate measurement technique using photographs as its fundamental medium. It has the advantages that it is non-invasive and relatively low cost. To generate images in three dimensions requires sophisticated software. The main disadvantage is that information is lost by filling in the blanks with speculated information.¹⁵

The computed axial tomography image is defined as the three-dimensional image using its slices to generate a point map. It has the advantage that is very precise and is possible to join soft, bone, and cartilage tissues. The downside is that the cost can be high and it is invasive. As well as one use and in some clinical settings we need repeated scanning to follow and register progress.^{18,19} Previous articles have proven the most accurate method available of the ones described in this paper.

The surface laser image is an image that is generated by an infrared laser that bounces off an object and is captured by a sensor. Subsequently, a map of triangles is generated to generate a three-dimensional image. It has the advantage of being inexpensive and non-invasive. The downsides are that the accuracy is sensor dependent and is dependent on the quality of the scan.^{10,19-25}

This paper aims to evaluate the nasal systematic analysis proposed by Rohrich et al²⁶ and compare findings between the three systems of nasal evaluation: photographs 2D,²⁷ 3D surface imaging with the Kinect system, and 3D CT scan imaging. The secondary objective is to describe the ethnic nasal findings in our routine practice.

Methods

Following the Helsinki guidelines, the official Mexican standard for clinical studies, and the health law of Mexico City. We designed a longitudinal and descriptive prospective study with simple non-blind randomization. We used the hospital tomographer that the tomographies are subsidized by the free program of the city of Mexico. We use a second-hand Kinect 360 sensor and Skanect software that costs 1,000 pesos to license. We use a camera from a Smart set at a set distance of 1.9 m to avoid distortion by a 20 mm fisheye lens.

Sample Calculation

We calculated the sample using the population of Miguel Hidalgo and used the number of rhinoplasties performed in the United States as an incidence factor, obtaining that 36 observations were required to have statistical value. We considered a confidence level of 95% and a confidence interval of 5.²⁸

We recruited patients who wanted to undergo primary rhinoplasty. All participants signed consent for participation, photographs, scanning, and publication that protected their anonymity. Once they approved and signed the consent, we took the observations using the three methods described with standardized techniques to avoid inter-observer errors and also give reproducibility to the captures. The variables included were age, gender, and the variables included in the systematic nasal analysis from Dallas rhinoplasty.²⁶

Scanning methodology, systematization, and statistical analysis:

The photographs were taken at a distance of 2 m to avoid fish eye deformity from a smartphone that has a lens of 20 mm. The pictures were taken with a blue background and following guidelines from previous literature sitematization.^{29,30}

To perform our 3D surface imaging scan using the Kinect system.²²⁻²⁵ We placed patients 1.5 m from the sensor. They were on a surface capable of rotating 360 degrees. Skanect (3D Scanning Software by Occipital) software was used with standard mode and parameters in millimeters. The sensor was placed parallel to the patients' Frankfurt plane. The scan was performed by turning the patient while the sensor was at a fixed point. For the 3D CT scan imaging, we followed our previous protocol for 3D printing except we did not print the STL file.^{3,31} We collected our data in the Microsoft Excel and then exported it into the R-Studio. When we evaluated thr three groups, we used an ANOVA analysis of variance test and descriptive statistics (► **Fig. 1**).

Results

A total of 42 observations were included finding a minimum age of 21 with a mean of 28 years old. In total, 64% were female, 93% had adequate facial proportions, and 50% were Fitzpatrick III. The most prevalent was no deviation in the nasal dorsum, and narrow bonny and mid vault with 65%. The alar base was wide in 57% and the dorsum aesthetic lines were ill-defined in 65%, symmetric in 72%, and narrow in 78% of cases. The alar rim was seagull type in 78%, with boxy tip type III in 43% of cases. The supratip was not defined in 100% of cases, meanwhile, the infratip lobule was defined in 43%. The upper lip was long in only 7% of cases. The tip was not projected in 86% of cases, the alar columella relation was retracted in 57% of cases. The hanging columella presented in 86% of cases. The nostrils were asymmetric in 50% of cases. The nostrils were short in 57% of cases. Periapical hypoplasia was more prevalent on the right side with 43%. Thick skin was more prevalent with 72% (► **Table 1**).

We found the mean and standard deviation (SD) values to determine parametric values. The dorsum length had a mean of 3.9 cm with a standard deviation of 0.54, the nasal index




Fig. 1 In this image, we show some examples of how the images look. On the left, the photograph is in 2 dimensions, in the center the surface laser image, and on the right side the image generated by tomography.

Table 1 Summary of results with all variables included

	Age (y)	Gender		Facial proportions		
Minimum	21	Male	35% (N = 15)	Adequate	93%(N = 39)	
Median	29	Female	64% (N = 27)	Inadequate	7% (N = 3)	
Maximum	36					
Mean	28					
			Nasal dorsum deviation			
	Fitzpatrick				Bonny vault	Mid vault
III	50% (N = 21)	Right	14% (N = 6)	Narrow	65% (N = 27)	65% (N = 27)
IV	50% (N = 21)	No deviation	72%(N = 30)	Wide	35% (N = 15)	35% (N = 15)
		Left	14% (N = 6)			57% (N = 24)
	Dorsum aesthetic lines					
Well-defined	35%(N = 15)	Symmetric	72% (N = 30)	Wide	22% (N = 9)	
Ill-defined	65% (N = 27)	Asymmetric	28% (N = 12)	Narrow	78% (N = 33)	
	Alar rim		Nasal tip divergence		Supratip	Infratip lobule
Ideal	22% (N = 9)	Boxy tip I	14% (N = 6)	Defined	0% (N = 0)	43% (N = 18)
Seagull	78% (N = 33)	Boxy tip III	43% (N = 18)	Undefined	100% (N = 0)	57% (N = 24)
		Ideal divergence	43% (N = 18)			
	Upper lip		Tip projection		Alar columella relation	
Long	7% (N = 3)	Ideal	14% (N = 6)	Ideal	43% (N = 18)	
Normal	93% (N = 39)	No projection	86% (N = 36)	Retracted	57% (N = 24)	
	Columella		Nostril symmetry		Nostril length	
Retracted	14% (N = 6)	Symmetric	50% (N = 21)	Long	43% (N = 18)	
Hanging	86%(N = 36)	Assymmetric	50% (N = 21)	Short	57% (N = 24)	
Nasal Deviation Between 3D images (mm)			Periarycal hypoplasia		Skin thickness	
Minimum	6.1	Left	7% (N = 3)	Thick	72%(N = 30)	
Median	6.5	Right	43% (N = 18)	Thin	28%(N = 12)	
Maximum	7.28	No	50% (N = 21)			
Mean	6.53					

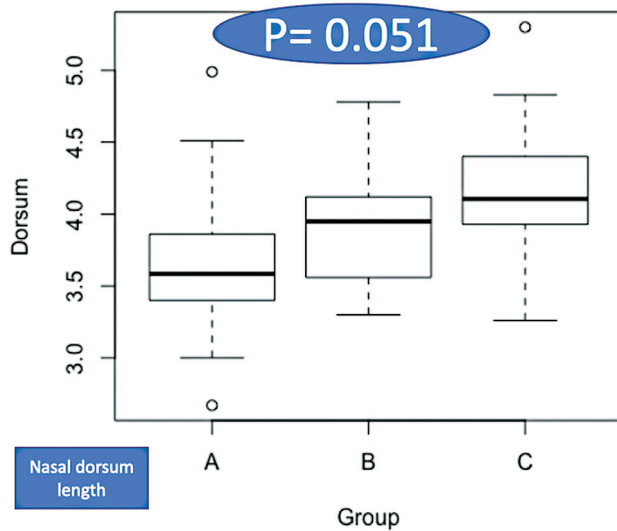


Fig. 2 In this image, we show the difference between the three groups in the nasal dorsum length. Group A is the two-dimensional photographic image, group B is the surface laser group, and group C is the tomography image group.

had a mean of 0.75 with SD 0.080, for nasofrontal angle had a mean of 137.9 degrees and SD of 10.15, and finally for tip rotation degree, a mean of 83 degrees and SD of 20.46. All these parametric values had a central distribution normal distribution.

For the outcome statistics, we found differential nasal deviation between 3D images with a mean of 6.53 mm (►Table 1). While when comparing the nasal dorsum length, we did not find a statistical significance of $p = 0.051$ (►Fig. 2). When comparing the nasal dorsum length index, we found

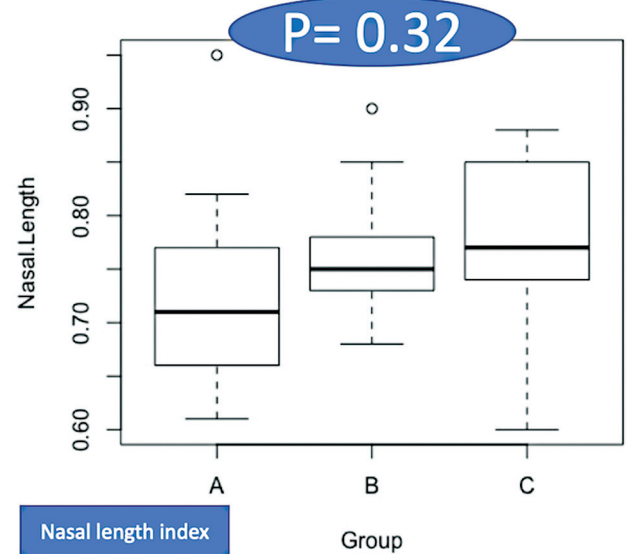


Fig. 3 In this image, we show the difference between the three groups in the nasal length index. Group A is the two-dimensional photographic image, group B is the surface laser group, and group C is the tomography image group.

no significant difference $p = 0.32$. (►Fig. 3). Also, we did not find statistical significance when comparing the nasofrontal angle and tip rotation angle $p = 1$ for both (►Figs. 4 and 5).

Discussion

We did not find any similar articles in the past, and we will discuss some of the most relevant papers that may apply.

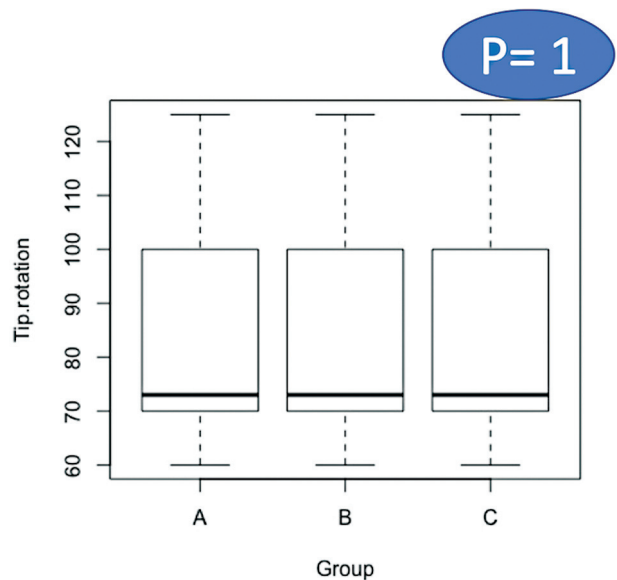


Fig. 4 In this image, we show the difference between the three groups in tip rotation angles. Group A is the two-dimensional photographic image, group B is the surface laser group, and group C is the tomography image group.

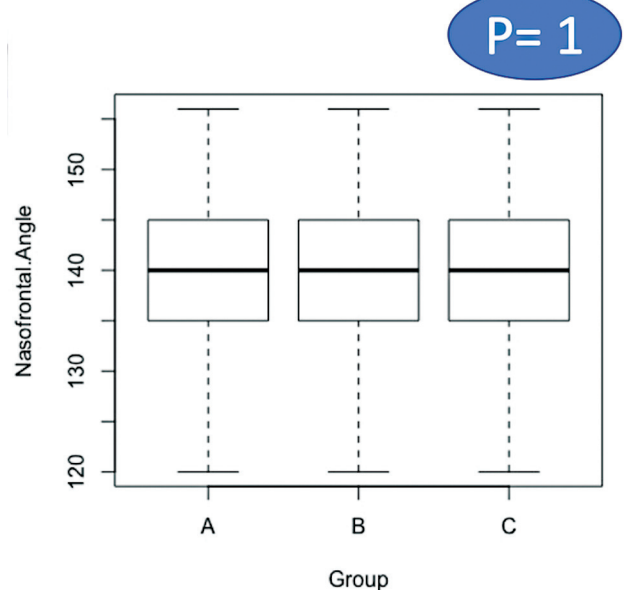


Fig. 5 In this image, we show the difference between the three groups in nasofrontal angles. Group A is the two-dimensional photographic image, group B is the surface laser group, and group C is the tomography image group.

Berssenbrugge et al¹⁴ explored the application of 3D imaging in studying facial asymmetry. They concluded that 5 points in a 3D image could be used to calculate an asymmetry index. They did not compare with the same purpose but they proved how 3D imaging is useful in a clinical setting.

Deacon et al¹² explored 3D imaging with low-cost, charge-coupled device cameras. They found very long times on scanning patients with very low-resolution images. We explored the Kinect system and compared it to a more sophisticated validated 3D imaging method. We did not measure the capture scanning time, but we can empirically say that it took ~60 seconds to scan successfully a person.

Multiple authors used the Kinect system in breast surgery Henseler et al²⁵ validated the application of the Kinect system for breast implant selection. We know that the clinical setting of the Kinect system is very different in breast surgery than in rhinoplasties. So, this is why it was fundamental to compare these three methods of imaging to have a clinical calibration of the accuracy and difference between the methods.^{22–25}

The most expensive of the three methods is CT scan imaging, and also it is the most invasive due to the use of radiation. In second place, the cost is the 3D surface imaging due to the price of the scanner and software. Finally, the less expensive methods would be photographs.^{32,33}

Conclusions

We found that the population we serve has characteristics of Hispanic mestizo nose. The three methods seem to evaluate systematic nasal analysis in a very similar way, and any of them can be used depending on the scenario and the needs of plastic surgeons. More third-party studies are required to give external validity to our results.

Ethical Approval

All procedures performed in studies involving human participants were in accordance with the ethical standards of the institutional and/or national research committee and with the 1964 Helsinki Declaration and its later amendments or comparable ethical standards. The Human Investigation Committee (IRB) of The Hospital Ruben Leñero approved this study (IRB: 2050100202021).

Informed Consent for Data Usage

Patients consented to the submission of the case report to this journal and masked the eye region in photographs of participants is inadequate protection of anonymity.

Informed Consent for Photographs and Scanning

All participants signed the consent for participation, photographs, scanning, and publication that protected their anonymity.

Conflict of Interest

None declared.

References

- Rohrich RJ, Durand PD, Dayan E. Changing role of septal extension versus columellar grafts in modern rhinoplasty. *Plast Reconstr Surg* 2020;145(05):927e–931e. Doi: 10.1097/PRS.00000000000006730
- Sawh-Martinez R, Perkins K, Madari S, Steinbacher DM. Control of nasal tip position: quantitative assessment of columellar strut versus caudal septal extension graft. *Plast Reconstr Surg* 2019;144(05):772e–780e
- Berlin NF, Berssenbrugge P, Runte C, et al. Quantification of facial asymmetry by 2D analysis - a comparison of recent approaches. *J Craniomaxillofac Surg* 2014;42(03):265–271
- FACE-Q © | AESTHETICS SCALES.
- Ishii LE, Tollefson TT, Basura GJ, et al. Clinical practice guideline: improving nasal form and function after rhinoplasty. *Otolaryngol Head Neck Surg* 2017;156(Suppl 2):S1–S30
- Carniol ET, Adamson PA. Surgical tips for the management of the wide nasal base. *Facial Plast Surg* 2018;34(01):29–35. Doi: 10.1055/s-0037-1621714
- Wähmann MS, Bulut OC, Bran GM, Veit JA, Riedel F. Systematic review of quality-of-life measurement after aesthetic rhinoplasty. *Aesthetic Plast Surg* 2018;42(06):1635–1647
- Pepper JP, Moyer JS. Upper blepharoplasty: the aesthetic ideal. *Clin Plast Surg* 2013;40(01):133–138
- Manafi A, Kaviani A, Hamed ZS, Rajabiani A, Manafi N. Evidence-based efficacy of autologous grated cartilage in primary and secondary rhinoplasty. *World J Plast Surg* 2017;6(02):137–143
- Riphagen JM, van Neck JW, van Adrichem LNA. 3D surface imaging in medicine: a review of working principles and implications for imaging the unsedated child. *J Craniofac Surg* 2008;19(02):517–524
- van Heerbeek N, Ingels KJAO, van Loon B, Plooi JM, Bergé SJ. Three dimensional measurement of rhinoplasty results. *Rhinology* 2009;47(02):121–125
- Deacon AT, Anthony AG, Bhatia SN, Muller JP. Evaluation of a CCD-based facial measurement system. *Med Inform (Lond)* 1991;16(02):213–228
- Gong X, He Y, An J, et al. Application of a computer-assisted navigation system (CANS) in the delayed treatment of zygomatic fractures: a randomized controlled trial. *J Oral Maxillofac Surg* 2017;75(07):1450–1463
- Berssenbrugge P, Berlin NF, Kebeck G, et al. 2D and 3D analysis methods of facial asymmetry in comparison. *J Craniomaxillofac Surg* 2014;42(06):e327–e334
- Tian J. Basics of Photogrammetry. Geod Serv Inc. 2011:62. Accessed May 23, 2020 at: <https://www.coursehero.com/file/58883437/Basics-of-Photogrammetry-2017pdf/>
- Struck R, Cordoni S, Aliotta S, Pérez-Pachón L, Gröning F. Application of photogrammetry in biomedical science. *Adv Exp Med Biol* 2019;1120:121–130
- Koban KC, Härtnagl F, Titze V, Schenck TL, Giunta RE. Chances and limitations of a low-cost mobile 3D scanner for breast imaging in comparison to an established 3D photogrammetric system. *J Plast Reconstr Aesthet Surg* 2018;71(10):1417–1423
- Ram MS, Joshi M, Debnath J, Khanna SK. 3 Dimensional Ct. *Med J Armed Forces India* 1998;54(03):239–242
- Koban KC, Leitsch S, Holzbach T, Volkmer E, Metz PM, Giunta RE. 3D-imaging and analysis for plastic surgery by smartphone and tablet: an alternative to professional systems? [article in German]. *Handchir Mikrochir Plast Chir* 2014;46(02):97–104
- Reynolds M, Reynolds M, Adeeb S, El-Bialy T. 3-d volumetric evaluation of human mandibular growth. *Open Biomed Eng J* 2011;5(01):83–89
- Kovacs L, Eder M, Zimmermann A, et al. Three-dimensional evaluation of breast augmentation and the influence of anatomic and round implants on operative breast shape changes. *Aesthetic Plast Surg* 2012;36(04):879–887

- 22 Wheat JS, Choppin S, Goyal A. Development and assessment of a Microsoft Kinect based system for imaging the breast in three dimensions. *Med Eng Phys* 2014;36(06):732–738
- 23 Pöhlmann STL, Harkness E, Taylor CJ, Gandhi A, Astley SM. Preoperative implant selection for unilateral breast reconstruction using 3D imaging with the Microsoft Kinect sensor. *J Plast Reconstr Aesthet Surg* 2017;70(08):1059–1067
- 24 Henseler H, Bonkat SK, Vogt PM, Rosenhahn B. The Kinect recording system for objective three- and four-dimensional breast assessment with image overlays. *J Plast Reconstr Aesthet Surg* 2016;69(02):e27–e34
- 25 Henseler H, Kuznetsova A, Vogt P, Rosenhahn B. Validation of the Kinect device as a new portable imaging system for three-dimensional breast assessment. *J Plast Reconstr Aesthet Surg* 2014;67(04):483–488
- 26 Fire K. *Dallas Rhinoplasty: Nasal Surgery by the Masters*. 3rd ed. Florida: CRC Press; 2014
- 27 Rohrich RJ. Chapter 15 Nasal analysis and anatomy. from book *Plast Surg (Oakv)* 2017;2:417–429. Doi: 10.1016/B978-0-323-35697-8.00015-9
- 28 Cantor AB, Lee H. Sample-size calculations for Cohen's kappa. *Psychol Methods* 1996;1(02):150–153
- 29 Persichetti P, Simone P, Langella M, Marangi GF, Carusi C. Digital photography in plastic surgery: how to achieve reasonable standardization outside a photographic studio. *Aesthetic Plast Surg* 2007;31(02):194–200
- 30 Yavuzer R, Smirnes S, Jackson IT. Guidelines for standard photography in plastic surgery. *Ann Plast Surg* 2001;46(03):293–300
- 31 Rendón-Medina MA, Andrade-Delgado L, Telich-Tarriba JE, Fuente-Del-Campo A, Altamirano-Arcos CA. Dimensional error in rapid prototyping with open source software and low-cost 3D-printer. *Plast Reconstr Surg Glob Open* 2018;6(01):e1646
- 32 Rendón-Medina MA, Hanson-Viana E, Palacios-Juarez J, Sandoval-Rodríguez JI. Application of low-cost fused deposition modeling additive manufacturing rapid anatomic models in patients with rhino-cerebral mucormycosis treated with maxillectomy. *Eur J Plast Surg* 2019:299–304
- 33 Rendón-Medina MA, Hanson-Viana E, Montoya-García SC, Vázquez-Morales HL, Pacheco-López RC. Time reduction by prebending osteosynthesis plates using 3D-printed anatomical models, in patients treated with open reduction and internal fixation. *J Craniofac Surg* 2021;32(04):1491–1493