



Imaging Recommendations for Diagnosis, Staging, and Management of Cervical Cancer

Palak Bhavesh Popat¹ Amita Maheshwari² Smita Manchanda³ Rupa Renganathan⁴ Saugata Sen⁵
Ekta Dhamija⁶ Meenakshi Thakur⁷ Kedar Deodhar⁸ Supriya Chopra⁹
Aditya Pavan Kumar Kanteti¹⁰ Jaya Ghosh¹⁰ Sneha Shah¹¹ Nilesh Sable⁷ Akshay Baheti⁷
Sonal Chauhan¹² Kunal Gala⁷ Suyash Kulkarni⁷

¹Department of Radiology, Homi Bhabha National Institute, Tata Memorial Hospital, Mumbai, Maharashtra, India

²Division of Gynaecologic Oncology, Department of Surgical Oncology, Tata Memorial Centre, Homi Bhabha National Institute, Mumbai, Maharashtra, India

³Department of Radiodiagnosis and Interventional Radiology, All India Institute of Medical Sciences, New Delhi, India

⁴Department of Diagnostic and Interventional Radiology, Kovai Medical Center and Hospitals, Coimbatore, Tamil Nadu, India

⁵Department of Radiology and Imaging Sciences, Tata Medical Centre, Kolkata, West Bengal, India

⁶Department of Radiodiagnosis, IRCH, AIIMS, New Delhi, India

⁷Department of Radiology, Homi Bhabha National Institute, Tata Memorial Hospital, Mumbai, Maharashtra, India

⁸Department of Pathology, Homi Bhabha National Institute, Tata Memorial Hospital, Mumbai, Maharashtra, India

Address for correspondence Palak Bhavesh Popat, DNB, Department of Radiology, Homi Bhabha National Institute, Tata Memorial Hospital, 117, Gr Floor, Main Building, E. Borges Road, Parel, Mumbai – 400012, Maharashtra, India (e-mail: dr.palakp@gmail.com).

⁹Department of Radiation Oncology, Homi Bhabha National Institute, Tata Memorial Hospital, Mumbai, Maharashtra, India

¹⁰Department of Medical Oncology, Homi Bhabha National Institute, Tata Memorial Hospital, Mumbai, Maharashtra, India

¹¹Department of Nuclear Medicine, Tata Memorial Hospital and Homi Bhabha National Institute, Mumbai, Maharashtra, India

¹²Department of Radiology, H. N. Reliance Hospital, Mumbai, Maharashtra, India

Ind J Med Paediatr Oncol 2023;44:119–129.

Abstract

Cervical cancer is the fourth most common cancer in women globally and the second most common cancer in Indian women, more common in lower socioeconomic strata. Improvement in survival and decrease in morbidity reflect the earlier detection with screening and imaging, as well as multifactorial multimodality therapy integrating surgery, and concurrent chemoradiation therapy providing superior therapeutic benefits. Imaging plays a vital role in assessing the extent of disease and staging of cervical cancer. The appropriateness criteria of a modality are different from its availability based on infrastructure, medical facilities, and resource status. Although in an ideal situation, magnetic resonance imaging (MRI) would be of greatest value in locoregional assessment of extent of disease and fluorodeoxyglucose positron emission tomography-computed tomography for distant staging; often, an ultrasonography, chest radiograph, and bone scans are utilized, with contrast-enhanced computed tomography representing a fair superior diagnostic accuracy, and can be reported as per the RECIST 1.1 criteria. MRI is also of good utility in the assessment of residual disease, predicting response and detecting small volume recurrence. MRI offers the highest diagnostic accuracy in determining parametrial invasion and hence surgical planning; so also, MRI-guided radiation planning helps in more accurate graded radiation dose planning in radiation therapy. Stage and therapy-based surveillance imaging should be encouraged and recommended.

Keywords

- ▶ cancer
- ▶ cervical
- ▶ guidelines
- ▶ imaging
- ▶ MRI

DOI <https://doi.org/10.1055/s-0042-1759717>.
ISSN 0971-5851.

© 2023. The Author(s).

This is an open access article published by Thieme under the terms of the Creative Commons Attribution License, permitting unrestricted use, distribution, and reproduction so long as the original work is properly cited. (<https://creativecommons.org/licenses/by/4.0/>)
Thieme Medical and Scientific Publishers Pvt. Ltd., A-12, 2nd Floor, Sector 2, Noida-201301 UP, India

Introduction

Cervical cancer is the fourth most common cancer in women globally and the second most common cancer in women in India. Annual global and Indian estimates of new cases for the year 2020 were 6,04,127 and 1,23, 907, respectively.¹ It is more common in women belonging to lower socioeconomic strata and more than 85% of all cases occur in developing countries. Even in these countries, the incidence is declining that could be attributed to better lifestyle, genital hygiene, and safe sexual practices. Down-staging among the diagnosed cases and earlier stages at presentation along with improved treatment protocol with chemoradiation therapy have led to improved survival. Pretreatment imaging plays a critical role in staging the disease as well as planning the appropriate treatment for the patient.

Etiology and Risk Factors

Infection with high-risk human papilloma virus (HPV) is a necessary but not sufficient cause for cervical cancer, with genotypes 16 and 18 being responsible for nearly 70% of cases.² HPV is a common sexually transmitted infection. In more than 90% of women, infection is transient and self-limiting; while in less than 10% virus may persist. Incorporation of viral genome into the host nucleus is the key step in HPV carcinogenesis. Factors that increase acquisition and persistence of HPV are also risk factors for cervical cancer and these include infections with other sexually transmitted diseases (human immunodeficiency virus and *Chlamydia trachomatis*), tobacco use, early onset of sexual activity, multiple sexual partners, multiparity, poor nutrition, personal hygiene, and long-term use of hormonal contraceptives. A minor fraction of cases of cervical cancer is HPV independent.

Classification

► **Table 1** shows the World Health Organization fifth edition 2020; classification of cervical tumors. Squamous cell carcinoma is the most common histologic type followed by adenocarcinoma.

Clinical Presentation and Workup

The median age at presentation of invasive cervical cancer is in the fifth decade. Early-stage disease is often asymptomatic and detected on screening. Abnormal vaginal bleeding in the form of postcoital, intermenstrual, or postmenopausal bleeding is the most common symptom. Foul smelling, blood-stained vaginal discharge is another common symptom. Constitutional symptoms, back pain, bladder or bowel habit alterations may occur in advanced stages. Rarely lower limb swelling due to deep vein thrombosis may be the presenting symptom. A detailed physical examination should include palpation of the supraclavicular and groin nodes, and liver to exclude metastatic disease. A pelvic examination including speculum, vaginal, and rectal examination is mandatory for the assessment of the cervical lesion as well as local spread to vagina,

Table 1 World Health Organization (WHO) fifth edition, 2020; classification of tumors of female reproductive organs classifies cervical tumors

Squamous epithelial tumors	Squamous metaplasia Atrophy Condyloma acuminatum Low-grade squamous epithelial lesion Cervical intraepithelial neoplasia 1 High-grade Squamous intraepithelial neoplasia Cervical intraepithelial neoplasia 2 Cervical intraepithelial neoplasia 3 Squamous cell carcinoma, HPV-associated Squamous cell carcinoma HPV-independent
Glandular tumors and precursors	Endocervical polyp Mullerian papilloma Nabothian cyst Tunnel clusters Microglandular hyperplasia Lobular endocervical glandular hyperplasia Diffuse laminar endocervical hyperplasia Mesonephric remnants and hyperplasia Arias-Stella reaction Endocervicosis Tuboendometrioid metaplasia Ectopic prostatic tissue Adenocarcinomas of in-situ NOS Adenocarcinoma in situ, HPV-associated Adenocarcinoma in situ HPV-independent Adenocarcinoma, NOS Adenocarcinoma, HPV-associated Adenocarcinoma, HPV-independent, gastric type Adenocarcinoma, HPV-independent, clear cell type Adenocarcinoma, HPV-independent, mesonephric type Adenocarcinoma, HPV-independent, NOS Endometrioid adenocarcinoma
Other epithelial tumors	Carcinosarcoma, adenosquamous and mucoepidermoid carcinomas, adenoid basal, and unclassified carcinomas.
Mixed epithelial and mesenchymal tumors	Adenomyoma and adenosarcoma
Germ cell tumors	Germ cell tumors

Abbreviations: HPV, human papilloma virus; NOS, not otherwise specified.

parametria, rectovaginal septum, and rectum. A punch biopsy should be performed from the visible cervical growth. Colposcopic examination and guided biopsy are required in a patient with grossly normal looking cervix but with an abnormal screening test. After confirmation of diagnosis, a comprehensive pretreatment workup should be done including hematocrit, liver and renal function tests, a chest radiograph, and an abdominopelvic imaging. An examination under anesthesia, cystoscopy, and proctoscopy are recommended only if clinically indicated.

Early detection of cervical cancer and precancer is possible by screening. Various methods available for screening include cytology, visual inspection with acetic acid and HPV DNA testing.

Imaging in Cervical Cancer

Imaging in cervical cancer is crucial for staging, to determine the extent of disease, in treatment planning and for response assessment.

Imaging findings are used as an adjunct to clinical staging.

Imaging Guidelines

The FIGO (*International Federation of Gynecology and Obstetrics*) staging system guides management protocol for cervical cancer patients and traditionally, this system was based on clinical evaluation with only limited imaging investigations. However, the most recent update on FIGO cervical cancer staging has allowed imaging findings in stage allocation. Equivalence of the TNM (*Tumor Node Metastases*) staging system maintained by the AJCC (*American Joint Committee on Cancer*) and the FIGO classification lay down common imaging and management recommendations. Version 9 update of the 8th edition AJCC TNM staging (► **Table 2**) highlights the changes of incorporation of imaging and surgical findings, elimination of lateral spread from T1a, addition of a subcategory to T1b (T1b3), and histopathology updated to reflect HPV-associated and independent carcinomas.³ With advancements in technology of computed tomographic (CT) scan and magnetic resonance imaging (MRI), there has been enough evidence to support good accuracy and diagnostic performance of these imaging modalities in determining the extent of disease and staging. In an ideal setting, MRI serves as the modality of choice for local extent of the disease, particularly for endocervical growths that cannot be evaluated on per-speculum or per-vaginal examination. The addition of diffusion weighted imaging has further enhanced the efficacy of MRI for locoregional extension, nodal involvement, and posttherapy tumor recurrence. However, since cervical cancer is more prevalent in women from low socioeconomic strata, MRI may not be accessible and/or affordable to them. Hence, role of ultrasound (US) and CT becomes more crucial in the management algorithm. US, the most readily available modality, offers comparable performance; however, it majorly depends on the expertise and skill of the operator and thus has not been able to find its place in routine practice. Availability of CT is better than MRI with added advantage of faster acquisition of images and better patient compliance. Positron emission tomography-computed tomography (PET-CT), on the other hand, provides functional information in addition to anatomical details. Considering all these factors, the recent FIGO 2018 has recommended baseline evaluation with cross-sectional imaging for patients with carcinoma cervix, but has not outlined a particular imaging protocol and advised to utilize the available modalities as per available infrastructure,⁴ attributed to limited resources in low- and middle-income countries in contrast to the incorporation of imaging evaluation at the

pretreatment level in the high-income countries. The NCCN (*National Comprehensive Cancer Network*) (► **Tables 2–4**) recommends baseline evaluation with MRI for local staging and CT or PET-CT for lymph node detection and distant metastases.⁵ Considering these different scenarios, the European Society of Gynecological Oncology, European Society for Therapeutic Radiotherapy and Oncology, and the European Society for Pathology put forth new guidelines in 2018 after FIGO apprised the role of imaging in its revised guidelines. The joint guidelines included imaging for staging, treatment and follow-up of cervical cancer based on combined staging by TNM and FIGO system,^{6,7} putting forth MR as a mandatory early investigation modality, with an optional transvaginal/transrectal US—if a skilled radiologist is available. The integration of various modalities of imaging, pathology, and clinical examination has been highlighted in the European guidelines that can be used for staging and treatment planning for the patients.⁵ Considering heterogeneity of resources in our country, the National Cancer Grid of India has categorized imaging guidelines as optimal and minimal based upon availability of imaging modality.⁸ MRI has been considered as the optimal imaging modality for disease assessment in early as well as advanced stages, whereas PET-CT is considered optional. On the other hand, in resource constraint setting, a radiograph of the chest and US abdomen should at least be performed for the patients and any indeterminate/suspicious node may be evaluated with fine-needle aspiration cytology sampling.

Imaging for Diagnosis

A. US: It is often the primary investigation performed for the presenting clinical symptoms, and it may be performed per-abdomen or per-vaginum, or both; the latter depicting a superior resolution. Cervical cancer appears as a hypoechoic lesion, with its epicenter in the cervical lips. Locoregional involvement of the uterine body and parametrium can also be seen. Large, lobulated, irregular pelvic nodes and attenuated hilum are suggestive of metastatic adenopathy. Involvement of extrapelvic organs may also be seen. A larger limitation of US is its subjectivity in assessment, often resting the diagnostic acumen to the hands of the skill of the operating radiologist. The following points should be noted:

- Epicenter and size of the lesion in three dimensions.
- Extent of vaginal involvement
- Involvement of parametrium, rectum or urinary bladder.
- Pelvic lymph nodes.
- Retroperitoneal lymph nodes.
- Renal morphology, and comment on hydronephrosis.
- Any other incidental finding

B. MRI: Carcinoma of the cervix is usually seen as a soft tissue appearing iso to hypointense on T2-weighted (T2W; compared with the normal darker signal intensity), isointense on T1W imaging, higher signal intensity on fat saturated sequences, and restricted diffusion. An important feature often is the differential enhancement between the uninvolved cervix and myometrium compared with cervical lesion, as seen on

Table 2 AJCC TNM staging system

TNM stage	FIGO stage	Description
Tumor stage(T)		
TX		Primary tumor cannot be assessed
T0		No evidence of primary tumor
T1	I	Carcinoma is strictly confined to the cervix (extension to the corpus should be disregarded)
T1a	IA	Invasive carcinoma that can be diagnosed only by microscopy with maximum depth of invasion ≤ 5 mm
T1a1	IA1	Measured stromal invasion ≤ 3 mm in depth
T1a2	IA2	Measured stromal invasion > 3 mm and ≤ 5 mm in depth
T1b	IB	Invasive carcinoma with measured deepest invasion > 5 mm ($>$ stage IA); lesion limited to the cervix uteri with size measured by maximum tumor diameter; note: the involvement of vascular/lymphatic spaces should not change the staging, and the lateral extent of the lesion is no longer considered
T1b1	IB1	Invasive carcinoma > 5 mm depth of stromal invasion and ≤ 2 cm in greatest dimension
T1b2	IB2	Invasive carcinoma > 2 cm and ≤ 4 cm in greatest dimension
T1b3	IB3	Invasive carcinoma > 4 cm in greatest dimension
T2	II	Carcinoma invades beyond the uterus but has not extended onto the lower one-third of the vagina or to the pelvic wall
T2a	IIA	Involvement limited to the upper two-thirds of the vagina without parametrial invasion
T2a1	IIA1	Invasive carcinoma ≤ 4 cm in greatest dimension
T2a2	IIA2	Invasive carcinoma > 4 cm in greatest dimension
T2b	IIB	With parametrial invasion but not up to the pelvic wall
T3	III	Carcinoma involves the lower one-third of the vagina and/or extends to the pelvic wall and/or causes hydronephrosis or nonfunctioning kidney; note: the pelvic wall is defined as the muscle, fascia, neurovascular structures, and skeletal portions of the bony pelvis; cases with no cancer-free space between the tumor and pelvic wall by rectal examination are FIGO stage III
T3a	IIIA	Carcinoma involves the lower one-third of the vagina, with no extension to the pelvic wall
T3b	IIIB	Extension to the pelvic wall and/or hydronephrosis or nonfunctioning kidney (unless known to be due to another cause)
T4	IVA	Carcinoma has involved (biopsy-proven) the mucosa of the bladder or rectum or has spread to adjacent organs (bullous edema, as such, does not permit a case to be assigned to stage IVA)
Nodal status(N)		
NX		Regional lymph nodes cannot be assessed
N0		No regional lymph node metastasis
N0(i+)		Isolated tumor cells in regional lymph node(s) ≤ 0.2 mm or single cells or clusters of cells ≤ 200 cells in a single lymph node cross-section
N1	IIIC1	Regional lymph node metastasis to pelvic lymph nodes only
N1mi	IIIC1	Regional lymph node metastasis (> 0.2 mm but ≤ 2.0 mm in greatest dimension) to pelvic lymph nodes
N1a	IIIC1	Regional lymph node metastasis (> 2.0 mm in greatest dimension) to pelvic lymph nodes
N2	IIIC2	Regional lymph node metastasis to para-aortic lymph nodes, with or without positive pelvic lymph nodes
N2mi	IIIC2	Regional lymph node metastasis (> 0.2 mm but ≤ 2.0 mm in greatest dimension) to para-aortic lymph nodes, with or without positive pelvic lymph nodes
N2a	IIIC2	Regional lymph node metastasis (> 2.0 mm in greatest dimension) to para-aortic lymph nodes, with or without positive pelvic lymph nodes
Metastatic status (M)		
M0		No distant metastasis
cM1	IVB	Distant metastasis (includes metastasis to inguinal lymph nodes, intraperitoneal disease, lung, liver, or bone; excludes metastasis to pelvic or para-aortic lymph nodes or vagina)
pM1	IVB	Microscopic confirmation of distant metastasis (includes metastasis to inguinal lymph nodes, intraperitoneal disease, lung, liver, or bone; excludes metastasis to pelvic or para-aortic lymph nodes or vagina)

Abbreviations: AJCC, American Joint Committee on Cancer; FIGO, International Federation of Gynecology and Obstetrics.

Table 3 Principles of imaging for initial workup, the NCCN guidelines

Stage I
Nonfertility sparing
◇ Consider pelvic MRI with contrast to assess local disease extent (preferred for FIGO stage IB1–IB3)
◇ Neck/chest/abdomen/pelvis/groin PET/CT (preferred) or chest/abdomen/pelvis CT or PET/MRI for FIGO stage IB1–IB3
◇ For patients who underwent TH with incidental finding of cervical cancer, consider neck/chest/abdomen/pelvis/groin PET/CT or chest/abdomen/pelvis CT to evaluate for metastatic disease and pelvic MRI to assess pelvic residual disease
◇ Other imaging should be based on symptomatology and clinical concern for metastatic disease
Fertility sparing
◇ Pelvic MRI (preferred) to assess local disease extent and proximity of tumor to internal cervical os; perform pelvic transvaginal ultrasound if MRI is contraindicated
◇ Neck/chest/abdomen/pelvis/groin PET/CT (preferred) or chest/abdomen/pelvis CT in FIGO stage IB1–IB3
◇ Consider chest CT with or without contrast
◇ Other imaging should be based on symptomatology and clinical concern for metastatic disease
Stage II–IVA
Pelvic MRI with contrast to assess local disease extent (preferred)
Neck/chest/abdomen/pelvis/groin PET/CT (preferred) or chest/abdomen/pelvis CT to evaluate for metastatic disease
Other initial imaging should be based on symptomatology and clinical concern for metastatic disease
For patients who underwent TH with incidental finding of cervical cancer, consider neck/chest/abdomen/pelvis/groin PET/CT or chest/abdomen/pelvis CT to evaluate for metastatic disease and pelvic MRI with contrast to assess pelvic residual disease
a. MRI and CT are performed with contrast throughout the guidelines unless contraindicated. Contrast is not required for screening chest CT
b. These factors may include abnormal physical exam findings or pelvic, abdominal, or pulmonary symptoms
c. These factors may include abnormal physical exam findings, bulky pelvic tumor (>4 cm), delay in presentation or treatment, and pelvic abdominal or pulmonary symptoms

Abbreviations: FIGO, International Federation of Gynecology and Obstetrics; MRI, magnetic resonance imaging; NCCN, National Comprehensive Cancer Network; PET/CT, positron emission tomography/computed tomography; TH, total hysterectomy.

dynamic subtracted fat-saturated T1 post contrast images. Cervical cancers are usually hypoperfused compared with their endometrial counterparts. Neuroendocrine tumors, however, may show avid enhancement. Parametrial invasion is seen as a loss of distinction of the hypointense T2W signal of the cervical and vaginal outer surface junction with the bright fat containing parametrium, with spiculations, lobulations, or frank invasion (→ Fig. 1).

Imaging for Staging

It can be divided into imaging for locoregional disease and systemic spread.

A. Evaluation of locoregional disease: Investigation of choice for local staging of cervical cancer is pelvic MRI. Contrast administration is optional, and when administered, a dynamic postcontrast MRI helps in better parametrial assessment, differentiating from the vascular plexus. The cervix is better evaluated when the vaginal cavity is distended by US or lignocaine jelly, opening up and outlining the patent fornices, and superior estimation of parametrial invasion. The following points should be considered while reporting MRI for cancer cervix, which help in determining stage of the lesion and management.

1. Dimensions of the lesion in orthogonal axes.
2. The site of the lesion and its extent within the confines of the cervix. Its epicenter, involvement of the fornices, the involvement of the lower uterine segment and vagina.
3. The extension of the lesion outside the confines of the uterus, for example, the parametrium on either side, involvement of the bladder, and rectum as well as the involvement of pelvic side walls.
4. Any secondary obstructive collection within the uterus due to stenosed endocervical canal.
5. Pelvic nodal disease on both sides along with sub sites. Internal, external iliac, obturator and common iliac nodes in their short axis dimension should be measured and mentioned separately. Screening abdomen is suggested, with careful analysis for the presence of supra- and infra renal-hilar retroperitoneal nodes.
6. Assessment of inguinal nodes.

B. Evaluation of systemic spread: Investigation of choice for systemic staging is CT with contrast (only portal venous phase may suffice). Both the abdomen (upper abdomen) and thorax should be covered. PET-CT has been used for both locoregional and systemic staging in clinically advanced stages. Depending on the available resources, technetium 99 m methylene diphosphonate bone scan

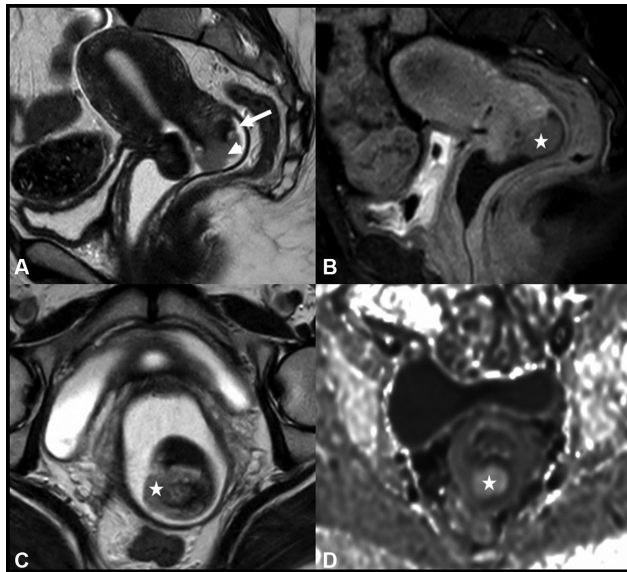


Fig. 1 A young 34-year-old lady with a history of postcoital pervaginal bleeding. Magnetic resonance imaging shows early-stage cervical lesion, pathologically proven as squamous cell carcinoma. (A) Small field of view sagittal T2-weighted image shows a polypoid exophytic lesion (marked by arrowhead) arising from the posterior lip of the cervix. Arrow shows superior delineation of the posterior vaginal fornical space, due to intravaginal instillation of lignocaine, distending the vaginal space. In this case, the posterior fornix and vaginal wall are clearly seen as uninvolved by the disease. (B) Postcontrast imaging shows differential poor enhancement of the lesion (marked by *). (C) Small field of view axial T2-weighted image shows lignocaine jelly surrounding the cervical lips and vaginal wall, also helping in ruling out lateral parametrial invasion. (D) Diffusion weighted imaging shows restricted diffusion seen as a high signal intensity (marked by *).

may be used for detecting predominantly sclerotic skeletal metastases. Chest radiographs have been used for detecting or following up on lung metastasis as well as pleural effusion, and US may be used to rule out organ metastases or adenopathy.

The following points should be considered for systemic staging.

- a. Retroperitoneal nodes, mention above or below the level of renal vein. Involvement of the major vessels by the nodes should be recorded.
- b. Liver or other organ metastasis.
- c. Peritoneal involvement.
- d. Mediastinal adenopathy.
- e. Supraclavicular nodes.
- f. Kidneys and ureters for any dilatation.
- g. Any pelvic arterial or venous and/or pulmonary embolus
- h. Apart from the above, an attempt for locoregional assessment in terms of size, parametrial invasion, and bowel/bladder wall involvement should be made.

Fluorodeoxyglucose (FDG) PET-CT: It has been a useful tool in pre-treatment evaluation to rule out distant nodal involvement or other metastatic disease. It is essential to rule out metastases, in early-stage cancer for definitive curative therapy, and hence PET-CT is recommended by the NCCN

guidelines for workup of cervical cancers clinically considered as stage IB. Metastatic workup of clinical stage IIB and III who are planned for multimodality treatment include a FDG PET-CT if available. The ability to reliably identify and characterize retroperitoneal nodal metastases may help in altering the radiotherapy (RT) field. Another nuclear medicine procedure proven to be helpful prior to surgical excision is the sentinel node scintigraphy. A radionuclide colloid, commonly Technetium (TcO₄) nano colloidal filtered sulfur colloid, is injected in the peritumoral region and scan obtained. Identification of the echelon node and frozen section examination of the sentinel node helps in intraoperative decision making. Radical surgery is abandoned in favor of definitive chemoradiation if sentinel lymph node shows metastatic disease. A check-list for PET-CT should include the following:

- a. Standardized uptake value of all the metabolically active lesions.
- b. Bone lesions.

Imaging for Planning Therapy

Based on the locoregional extent of disease and clinical status of patient, radical surgery or definitive radiation therapy (RT) with or without concurrent chemotherapy is planned. For RT planning contouring, contrast-enhanced CT (CECT) is the primary modality of imaging. MRI and CT fusion as well as PET-CT have been used as well. An advantage of MR over CT is its better soft tissue resolution that helps in planning graded radiation doses. Hypoxic imaging also serves as a surrogate for prediction of response to RT. Traditionally, brachytherapy prescription from last many decades has been performed using anatomical surrogates that represent boundaries of medial parametrium (referred as point A, representing the crossing of ureter and uterine artery). In the last two decades, MR has also been integrated for brachytherapy treatment planning in cervix cancer.

Imaging in Prediction of Pretreatment and Post-Treatment Response

MRI is a reliable modality for the assessment of post-therapy (especially post radiation) response, with remarkable reduction in size of the lesion, cicatrizing appearance of the cervical lips; accompanied with the tumor-related isointense T2W signal intensity changing to T2 dark signal intensity as the neoplasm undergoes fibrosis and the restricted diffusion moving towards near normal facilitation. Smaller areas of residual disease may be detected by remnant areas of signal intensity lacking these features and mimicking the index lesion. MRI has also been integrated in response and outcome prediction. Tumor necrosis identified on T2W MRI is known to clearly impact outcomes after chemoradiation.⁹ MR-based radiomics also allow discrimination of responders versus non responders prior to onset of chemoradiation therapy.¹⁰ Dynamic contrast-enhanced MRI identifies hypoxic fraction and allows identification of patients who are expected to have unfavorable outcome.¹¹ Blood oxygen

Table 4 The NCCN guidelines for imaging on surveillance

Stage I
Nonfertility sparing
a. Imaging should be based on symptomatology and clinical concern for recurrent/metastatic disease ^b
b. For patients with FIGO stage IB3 or patients who required postoperative adjuvant radiation or chemoradiation due to high-risk factors ^d
c. Neck/chest/abdomen/pelvis/groin PET/CT ^a may be performed at 3–6 months after completion of treatment
Fertility sparing
a. Consider pelvic MRI with contrast 6 months after surgery and then yearly for 2–3 years
b. Other imaging should be based on symptomatology and clinical concern for recurrent/metastatic disease ^b
Stage II to IV
Neck/chest/abdomen/pelvis/groin PET/CT (preferred) or chest/abdomen/pelvic CT with contrast within 3–6 months of completion of therapy
Consider pelvic MRI with contrast at 3–6 months post completion of therapy
Other imaging should be based on symptomatology and clinical concern for recurrent/metastatic disease ^e
Stage IVB or recurrence
Imaging as appropriate (CT, MRI, or PET/CT) to assess response or determine further therapy
a. MRI and CT are performed with contrast throughout the guidelines unless contraindicated. Contrast is not required for screening chest CT
b. These factors may include abnormal physical exam findings or pelvic, abdominal, or pulmonary symptoms
c. Risk factors may include positive nodes, positive parametria, positive margins, or local cervical factors
d. These factors may include abnormal physical exam findings such as palpable mass or adenopathy, or new pelvic, abdominal, or pulmonary symptoms

Abbreviations: FIGO, International Federation of Gynecology and Obstetrics; MRI, magnetic resonance imaging; NCCN, National Comprehensive Cancer Network; PET/CT, positron emission tomography/computed tomography.

level-dependent hypoxia imaging characterizes tumor biology at the cellular level.¹²

For response assessment in metastatic lymph nodes and other distant sites, either CECT or PET-CT or PET-CECT is useful. It is also imperative to note that in cervical cancer chemoradiotherapy studies, traditional radiological response evaluation has been sparingly utilized. Multiple ongoing studies especially that combine RT and drugs (targeted agents or immunotherapy) now utilize RECIST 1.1 for determining progression-free survival.^{13,14} As chemoradiotherapy studies have traditionally not utilized RECIST 1.1, studies are underway within multi-institutional collaboration to understand the impact of such a transition on assessment of various disease outcome endpoints.

The NCCN guidelines recommend the use of CECT/PET-CT/MRI modality for response assessment and surveillance, varying over 6 months to 2 to 3 yearly, depending on the stage of presentation and the therapy received (→ **Table 4** → **Table 5** and → **Table 6**).

Table 5 The NCCN guidelines on imaging for recurrence

Neck/chest/abdo/pelvis/groin PET-CT/CT
Consider pelvic MRI

Abbreviations: MRI, magnetic resonance imaging; NCCN, National Comprehensive Cancer Network; PET/CT, positron emission tomography/computed tomography.

Synoptic reporting formats have been attached for reference of the salient features essential for appropriate imaging (→ **Table 7** and → **Table 8**).

Table 6 The NCCN guidelines on imaging in small cell neuroendocrine carcinoma of the cervix

Additional workup
Neck/chest/abdomen/pelvis/groin PET/CT + brain MRI (preferred) or Chest/abdomen/pelvis CT + brain MRI
Treatment response assessment
If primary treatment is chemoradiation, then neck/chest/abdomen/pelvis/groin PET/CT ± brain MRI (preferred) or chest/abdomen/pelvis CT ± brain MRI If neoadjuvant chemotherapy is used, consider reassessment to rule out metastatic disease prior to chemoradiation and brachytherapy
Surveillance
Neck/chest/abdomen/pelvis/groin PET/CT ± brain MRI (preferred) or Chest/abdomen/pelvis CT ± brain MRI

Abbreviations: MRI, magnetic resonance imaging; NCCN, National Comprehensive Cancer Network; PET/CT, positron emission tomography/computed tomography.

Table 7 Synoptic reporting CT for cervical cancer

Protocol:	
Patient instructions:	Patient is asked to void 30 minutes prior to the scan Serum creatinine to be in check, ideally <1.2 mg/dL, above which the eGFR is calculated. If it is >30 mL/min, full dose contrast can be safely injected. If <30 mL/min, decide on IV contrast injection on case-by-case basis
Contrast agent:	Oral: 750–1,000 mL of oral positive contrast agent for delineating bowel loops, starting at ~2 hours prior to the procedure IV: At the time of scan, ~80–120 mL of nonionic contrast is injected at the rate of 2 mL/sec. Iso-osmolar contrast agent used if eGFR is on the lower side
Scan area:	Dome of diaphragm to perineum
	Usually for multidetector CT, the section collimation is 2.5 mm, the table speed is 12.5 mm per rotation, and the reconstructed section width is 3–5 mm. Section thickness: 5mm. Isotropic multi-planar postprocessing reconstruction at 1 mm interval
Reformatting and contrast adjustment:	Sagittal reformats and optimal change of windowing should also be used for assessment of findings
Interpretation	
Cervical lesion:	Size: Dimension (if lesion is well appreciated) Uterine body involved or not—If yes, its extent of involvement. Associated hydrometra / hematometra
Locoregional involvement:	Vaginal wall involvement: Uninvolved/involved (If involved, Upper two-thirds / whole) Parametrial involvement: Involved/equivocal (CT is not the ideal modality for the assessment of medial parametrial involvement) If involved, then the extent of involvement Hydroureter: Absent/present (with/without hydronephrosis) Renal function: Symmetric uptake/delayed nephrogram (Optional excretory phase may be obtained) Bowel involvement Bladder involvement
Adenopathy:	Size: Short axis dimension Morphology: round / oval; regular margins / irregular; hilum preserved / lost; homogenous / heterogenous enhancement. Site : Locoregional / Metastatic Locoregional nodal sites: Perivisceral, internal iliac, external iliac, and common iliac sites Metastatic nodal sites: Para-aortic and inguinal nodes and other distant sites
Ovaries:	Normal/suspicious
Ascites:	Present/absent
Pleural effusion:	Present/absent
Peritoneum and omentum:	Involved/not involved
Other viscera:	Liver, gall bladder, spleen, pancreas, adrenals and lung base
Metastases:	Bone/viscera
	Any other incidental benign appearing or indeterminate finding

Abbreviations: eGFR, estimated glomerular filtration rate; IV, intravenous; CT, computed tomography.

Principles of Management

Management guidelines are broadly dependent on the stage of disease, and its presence as an in-situ versus invasive component. The choice of treatment depends upon stage of the disease, patient's performance status, and preference. In patients up to FIGO stage IB2 disease (with disease confined to cervix) radical surgery is the preferred modality of treatment, although definitive RT gives equivalent survival in these patients. In stage IA disease (with microscopic invasive carcinoma with less than 5 mm depth of invasion), cervical conization or extrafascial hysterectomy with or without

pelvic lymphadenectomy is recommended. For stages IB1 and IB2, more radical surgery in the form of radical hysterectomy with bilateral pelvic lymphadenectomy is considered.¹⁵ Adjuvant RT is indicated in patients with any two intermediate risk factors including deep cervical stromal invasion, lymphovascular stromal invasion, and tumor size more than 4 cm.¹⁶ Adjuvant chemoradiotherapy with concurrent cisplatin is recommended in patients with any high-risk features including positive surgical margins, positive lymph nodes, or parametrial involvement.¹⁷

Neoadjuvant chemotherapy followed by surgery is not superior to concomitant chemoradiotherapy (CTRT) in stages

Table 8 Synoptic reporting MRI for cervical cancer

Protocol	
Patient instructions:	4 hours fasting, but water intake is encouraged prior to the scan Patient is asked to void 30 minutes prior to the scan Serum creatinine to be in check, ideally <1.2 mg/dL, above which the eGFR is calculated. Contrast enhanced scan can be safely performed for eGFR >30mL/min. Antiperistaltic medication (e.g., Buscopan) is recommended
Preparation:	For optimal reporting, instillation of per-vaginum sterile jelly is necessary
Sequences:	Dedicated oblique axial small FOV high-resolution T2W sequence. Dedicated oblique sagittal small FOV 24 cm high-resolution T2W sequence. Coronal T2W sequence, optional for small versus large FOV, but small FOV is preferred Large FOV T2W image in coronal plane to include kidneys for hydronephrosis Fat-saturated sequence for lower abdomen and pelvis Axial T1W sequence for screening upper abdomen. Diffusion-weighted imaging, with b value 600–800, optional FOV, but preferably small FOV Dynamic postcontrast screening is recommended in cases of uncertain diagnosis or equivocal parametrial extension. Precontrast followed by 4 to 5 runs of postcontrast imaging. (may be avoided in obviously large infiltrating diseases of advanced stage) Multiplanar postcontrast fat sat sequence
Interpretation	
Tumor description: Morphology descriptors	Exophytic vs. endophytic Location: Anterior cervical lip /posterior cervical lip /circumferential Dimension: Percentage involvement of stroma, i.e., >50% or <50% Signal intensity description: T2W, restricted diffusion, dynamic postcontrast enhancement characteristics Circumferential cervical hypointense stromal ring: Whether intact or involved, focally or circumferentially
Locoregional extent:	Uterine body involved or not—If yes, its extent of involvement Associated hematometra/hydrometra Vaginal forniceal space: Maintained/effaced/involved Vagina: Anterior/posterior; Upper two-thirds/upto inferior aspect Parametrium: Free/stranding/involved, seen as nodular enhancing soft tissue If parametrium involved, its lateral extent Hydroureter: Absent/present, without/with hydronephrosis Bowel wall: Uninvolved/involved Bladder wall: Uninvolved/bullous edema/involved
Adenopathy:	Size: Morphology: Site: Locoregional nodal sites: Perivisceral, internal iliac, external iliac, and common iliac sites Metastatic nodal sites: Para-aortic (nodes below the renal hilum/above the renal hilum) and inguinal nodes and other distant sites
Uterus:	Endometrial thickness Any other comment
Ovaries:	Normal/suspicious
Ascites:	Present/absent
Pleural effusion:	Present/absent
Peritoneum and omentum:	Involved/not involved
Other viscera:	Liver, gall bladder, spleen, pancreas, adrenals, and lung base
Metastases:	Bone/viscera
	Any other incidental benign appearing or indeterminate finding

Abbreviations: eGFR, estimated glomerular filtration rate; FOV, field of view; MRI, magnetic resonance imaging; T1W, T1-weighted.

IB2, IIA, and IIB.¹⁸ CTRT is the standard of care for bulky IB-IVA. Individual patient data meta-analysis from 13 trials confirmed benefit of CTRT in comparison to RT alone. Hazard ratio for overall survival (OS) and disease-free survival (DFS)

was 0.81 and 0.78, respectively, which translates into absolute survival benefit of 10% in FIGO stage I/II and 3% in stage III/IVA.¹⁹ A phase III randomized study comparing concurrent chemoradiation versus radiation alone, in patients with

stage III B disease showed improvement in both DFS (44% to 52%) and OS (46–54%) in favor of concurrent chemoradiation.¹⁸ Thus, CRT remains the standard of care even in stage III disease. The most commonly used chemotherapy regimen is weekly cisplatin¹⁹ 40 mg/m².

Integration of MRI in last two decades facilitated development of brachytherapy “adaptive target concept” that was based on response of tumor to external radiation.²⁰ Integration of target concept, simultaneous development of MRI compatible brachytherapy applicators for intracavitary–interstitial implants, and accurate tumor identification at brachytherapy has led to upward of 90% local control in patients with even very advanced cervical cancer. The results of multicentric international study of MR based brachytherapy (EMBRACE) have been recently reported and represent benchmark for cervical cancer brachytherapy.²¹ Further adaptations of brachytherapy dose were performed in EMBRACE II.²¹ Taken together these studies have recruited more than 2,800 patients worldwide. Though these were single arm large registration studies, a recent meta-analysis of more than 5,000 patients reported close to 11% improvement in 3-year DFS with integration of MR-based brachytherapy.²² This highlights the role of RT as curative therapy for early cervical cancer with marked improvement in DFS in advanced disease.

For patients with metastatic or recurrent disease who are not candidates for surgical resection or RT, platinum and paclitaxel with or without bevacizumab are the preferred treatment. Cisplatin-based doublets demonstrate superiority over cisplatin monotherapy in terms of response rates and PFS, whereas addition of bevacizumab to doublet shows prolongation of OS (GOG240).^{23,24} Japan Clinical Oncology Group (JCOG) demonstrated noninferiority with substitution of carboplatin AUC5 for cisplatin in JCOG0505(27).⁹ Addition of pembrolizumab with first-line chemotherapy with or without bevacizumab improves both PFS and OS with similar benefit between overall population and in those with programmed death ligand 1 (PD-L1) combined positive score more than 1 or more than 10.²⁵

There is little evidence to suggest that treatment in second line or later line setting improves OS compared with palliation alone. Single-agent carboplatin, paclitaxel, and topotecan are the most active agents in second-line setting. In PD-L1-positive cancers, single-agent pembrolizumab has shown favorable response rates in second-line setting.

An integrated multidisciplinary oncology team working towards increasing awareness and screening, improving accuracy of imaging and multimodal therapy for management of cervical cancers, bears a positive impact towards improvement in survival and quality of life.

Summary of Recommendations

- ◇ Imaging plays a vital role in assessing the extent of disease and staging of cervical cancer.
- ◇ In clinically early-stage disease, MRI, on the basis of estimation of tumor size, cervical stromal invasion,

parametrial invasion, and nodal involvement can help triage patients for surgery versus RT.

- ◇ While hypoxic imaging can predict response, MR is fairly reliable in post-RT locoregional response assessment and detect early recurrence
- ◇ CECT or PET CECT-based RECIST 1.1 may be followed for distant metastatic response assessment.
- ◇ Stage and therapy-based surveillance imaging should be recommended.

Conflict of Interest

None.

References

- 1 Sung H, Ferlay J, Siegel RL, et al. Global Cancer Statistics 2020: GLOBOCAN estimates of incidence and mortality worldwide for 36 cancers in 185 countries. *CA Cancer J Clin* 2021;71(03):209–249. <https://pubmed.ncbi.nlm.nih.gov/33538338/> cited 2022 Apr 4 [Internet]
- 2 Walboomers JMM, Jacobs MV, Manos MM, et al. Human papillomavirus is a necessary cause of invasive cervical cancer worldwide. *J Pathol* 1999;189(01):12–19 [Internet]
- 3 Olawaiye AB, Baker TP, Washington MK, Mutch DG. The new (Version 9) American Joint Committee on Cancer tumor, node, metastasis staging for cervical cancer. *CA Cancer J Clin* 2021;71(04):287–298. <https://onlinelibrary.wiley.com/doi/full/10.3322/caac.21663> cited 2022 Apr 4 [Internet]
- 4 Bhatla N, Berek JS, Cuello Fredes M, et al. Revised FIGO staging for carcinoma of the cervix uteri. *Int J Gynaecol Obstet* 2019;145(01):129–135. <https://pubmed.ncbi.nlm.nih.gov/30656645/> cited 2022 Apr 4 [Internet]
- 5 Haldorsen IS, Lura N, Blaakær J, Fischerova D, Werner HMJ. What is the role of imaging at primary diagnostic work-up in uterine cervical cancer? *Curr Oncol Rep* 2019;21(09):77. <https://pubmed.ncbi.nlm.nih.gov/31359169/> cited 2022 Apr 4 [Internet]
- 6 Recommendations | ESGO Gynae-Oncology Guidelines [Internet]. [cited 2022 Apr 4]. Accessed November 21, 2022 at: <https://guidelines.esgo.org/cervical-cancer/guidelines/recommendations/>
- 7 Cibula D, Pötter R, Planchamp F, et al. The European Society of Gynaecological Oncology/European Society for Radiotherapy and Oncology/European Society of Pathology Guidelines for the Management of Patients With Cervical Cancer. *Int J Gynecol Cancer* 2018;28(04):641–655. <https://pubmed.ncbi.nlm.nih.gov/29688967/> cited 2022 Apr 4 [Internet]
- 8 Chopra SJ, Mathew A, Maheshwari A, et al. National Cancer Grid of India Consensus Guidelines on the Management of Cervical Cancer. *J Glob Oncol* 2018;4:1–15. <https://pubmed.ncbi.nlm.nih.gov/30085891/> cited 2022 Apr 4 [Internet]
- 9 ESTRO - Session Item [Internet]. [cited 2022 Apr 5]. Accessed November 21, 2022 at. <https://www.estro.org/Congresses/ESTRO-2021/500/profferedpapers17-gynaecological/3421/newprognosticfactorsinlocallyadvancedcervicalcancer>
- 10 Fang M, Kan Y, Dong D, et al. Multi-habitat based radiomics for the prediction of treatment response to concurrent chemotherapy and radiation therapy in locally advanced cervical cancer. *Front Oncol* 2020;10:563
- 11 Hillestad T, Hompland T, Fjeldbo CS, et al. MRI distinguishes tumor hypoxia levels of different prognostic and biological significance in cervical cancer. *Cancer Res* 2020;80(18):3993–4003. <https://pubmed.ncbi.nlm.nih.gov/32606004/> cited 2022 Apr 5 [Internet]
- 12 Mahajan A, Sable NP, Popat PB, et al. Magnetic resonance imaging of gynecological malignancies: role in personalized management. *Semin Ultrasound CT MR* 2017;38(03):231–268
- 13 Schwartz LH, Litière S, de Vries E, et al. RECIST 1.1-update and clarification: from the RECIST committee. *Eur J Cancer* 2016;62:132–137

- 14 Seymour L, Bogaerts J, Perrone A, et al; RECIST working group. iRECIST: guidelines for response criteria for use in trials testing immunotherapeutics. *Lancet Oncol* 2017;18(03): e143–e152
- 15 Tewari KS, Monk BJ. Evidence-based treatment paradigms for management of invasive cervical carcinoma. *J Clin Oncol* 2019;37(27):2472–2489 <https://pubmed.ncbi.nlm.nih.gov/31403858/> cited 2022Apr5 [Internet]
- 16 Sedlis A, Bundy BN, Rotman MZ, Lentz SS, Muderspach LI, Zaino RJ. A randomized trial of pelvic radiation therapy versus no further therapy in selected patients with stage IB carcinoma of the cervix after radical hysterectomy and pelvic lymphadenectomy: a Gynecologic Oncology Group Study. *Gynecol Oncol* 1999;73(02):177–183 <https://pubmed.ncbi.nlm.nih.gov/10329031/> cited 2022Apr5 [Internet]
- 17 Peters WA III, Liu PY, Barrett RJ II, et al. Concurrent chemotherapy and pelvic radiation therapy compared with pelvic radiation therapy alone as adjuvant therapy after radical surgery in high-risk early-stage cancer of the cervix. *J Clin Oncol* 2000;18(08):1606–1613 <https://pubmed.ncbi.nlm.nih.gov/10764420/> cited 2022Apr5 [Internet]
- 18 Gupta S, Maheshwari A, Parab P, et al. Neoadjuvant chemotherapy followed by radical surgery versus concomitant chemotherapy and radiotherapy in patients with Stage IB2, IIA, or IIB squamous cervical cancer: a randomized controlled trial. *J Clin Oncol* 2018;36(16):1548–1555 <https://pubmed.ncbi.nlm.nih.gov/29432076/> cited 2022Apr5 [Internet]
- 19 Vale C, Tierney JF, Stewart LA, et al; Chemoradiotherapy for Cervical Cancer Meta-Analysis Collaboration. Reducing uncertainties about the effects of chemoradiotherapy for cervical cancer: a systematic review and meta-analysis of individual patient data from 18 randomized trials. *J Clin Oncol* 2008;26(35):5802–5812 <https://pubmed.ncbi.nlm.nih.gov/19001332/> cited 2022Apr12 [Internet]
- 20 Haie-Meder C, Pötter R, Van Limbergen E, et al; Gynaecological (GYN) GEC-ESTRO Working Group. Recommendations from Gynaecological (GYN) GEC-ESTRO Working Group (I): concepts and terms in 3D image based 3D treatment planning in cervix cancer brachytherapy with emphasis on MRI assessment of GTV and CTV. *Radiother Oncol* 2005;74(03):235–245 <https://pubmed.ncbi.nlm.nih.gov/15763303/> cited 2022Apr5 [Internet]
- 21 Pötter R, Tanderup K, Schmid MP, et al; EMBRACE Collaborative Group. MRI-guided adaptive brachytherapy in locally advanced cervical cancer (EMBRACE-I): a multicentre prospective cohort study. *Lancet Oncol* 2021;22(04):538–547 <https://pubmed.ncbi.nlm.nih.gov/33794207/> cited 2022Apr5 [Internet]
- 22 Hande V, Chopra S, Kalra B, et al. Point-A vs. volume-based brachytherapy for the treatment of cervix cancer: a meta-analysis. *Radiother Oncol* 2022;170(00):70–78 <http://www.thegreenjournal.com/article/S0167814022001232/fulltext> cited 2022Apr5 [Internet]
- 23 Moore DH, Blessing JA, McQuellon RP, et al. Phase III study of cisplatin with or without paclitaxel in stage IVB, recurrent, or persistent squamous cell carcinoma of the cervix: a gynecologic oncology group study. *J Clin Oncol* 2004;22(15):3113–3119 <https://pubmed.ncbi.nlm.nih.gov/15284262/> cited 2022Apr5 [Internet]
- 24 Tewari KS, Sill MW, Long HJ III, et al. Improved survival with bevacizumab in advanced cervical cancer. *N Engl J Med* 2014;370(08):734–743 <https://pubmed.ncbi.nlm.nih.gov/24552320/> cited 2022Apr5 [Internet]
- 25 Kitagawa R, Katsumata N, Shibata T, et al. Paclitaxel plus carboplatin versus paclitaxel plus cisplatin in metastatic or recurrent cervical cancer: the open-label randomized phase III Trial JCOG0505. *J Clin Oncol* 2015;33(19):2129–2135 <https://pubmed.ncbi.nlm.nih.gov/25732161/> cited 2022Apr5 [Internet]