


Lower Eyelid Management in Facial Paralysis

Nate Jowett, MD, PhD¹ 

¹ Department of Otolaryngology – Head and Neck Surgery, Massachusetts Eye and Ear, Harvard Medical School, Boston, Massachusetts

Address for correspondence Nate Jowett, MD, PhD, Massachusetts Eye and Ear, 243 Charles Street, Boston, MA 02114 (e-mail: Nate_Jowett@meei.harvard.edu).

Facial Plast Surg 2023;39:47–52.

Abstract

Keywords

- ▶ facial paralysis
- ▶ eyelids
- ▶ plastic surgery
- ▶ paralytic lagophthalmos
- ▶ lower eyelid retraction

Correction of lower eyelid retraction is necessary to restore adequate blink in paralytic lagophthalmos. A plethora of static and dynamic surgical techniques have been described for lower eyelid repositioning. This article provides an approach to management of the paralytic lower eyelid, including a summary of existing techniques, case examples, and surgical technique for in-office lower eyelid suspension using a palmaris longus tendon graft.

Paralytic lagophthalmos is characteristic of lower motor neuron facial palsy. Symptoms of paralytic lagophthalmos include reflex tearing and ocular sicca, which may progress to exposure keratopathy and corneal vision loss.^{1,2} Ocular findings in isolated hemifacial palsy may include upper eyelid lagophthalmos, lower eyelid retraction, ectropion, trichiasis, pooling of tears in the inferior fornix, and chemosis secondary to loss of orbicularis oculi function. Additional ocular symptoms in hemifacial palsy may comprise visual field obstruction and upper eyelid ptosis secondary to the mechanical effects of brow ptosis. Even in the absence of gross corneal surface abnormalities, slit lamp examination in paralytic lagophthalmos often reveals superficial punctate keratitis. Retraction of the lower eyelid in hemifacial palsy may worsen over time secondary to the downward pull of flaccid tissues of the lower two-thirds of the face yielding increasing laxity of the canthal tendons.

Assessment

Establishing the cause of a patient's paralytic lagophthalmos is the first step in management. Paralytic lagophthalmos most often arises in the setting of sudden-onset unilateral facial paralysis, whose etiologies include Bell palsy, Ramsay Hunt syndrome, and Lyme disease. Slowly progressive unilateral facial palsy is suggestive of a neoplastic process, and

warrants imaging workup of the entire course of the facial nerve. In the absence of facial trauma or surgery in the region of zygomatic branches of the facial nerve, new-onset isolated weakness of the oculi muscle should prompt concern for perineural spread of a malignancy. In rare cases, infectious, inflammatory, or autoimmune diseases such as multiple sclerosis may yield isolated paralytic lagophthalmos.

The time course of lagophthalmos onset, progression, and resultant symptoms should be documented, in addition to a thorough history, thorough head and neck exam, and any ancillary tests necessary to establish the diagnosis.³ Ophthalmologic assessment should be considered, and is particularly warranted where ocular surface injury is suspected. The physical exam of the lower eyelid should document the degree of retraction, ectropion, epiphora, chemosis, and presence or absence of Bell's phenomenon. Lower eyelid laxity is assessed with distraction and snap-back tests. The degree of eye prominence is particularly relevant in therapeutic decision making and may be assessed using the orbital vector (▶ **Fig. 1**). A positive orbital vector is present when the most anterior portion of the globe sits posterior to the lower eyelid margin and malar eminence. A negative orbital vector is present when the anterior surface of the globe lies anterior to the lower eyelid margin and malar eminence. The "two-finger test" is useful to identify negative orbital vectors in the setting of lower eyelid malposition. In this test, one finger is used to tension the lateral aspect of the

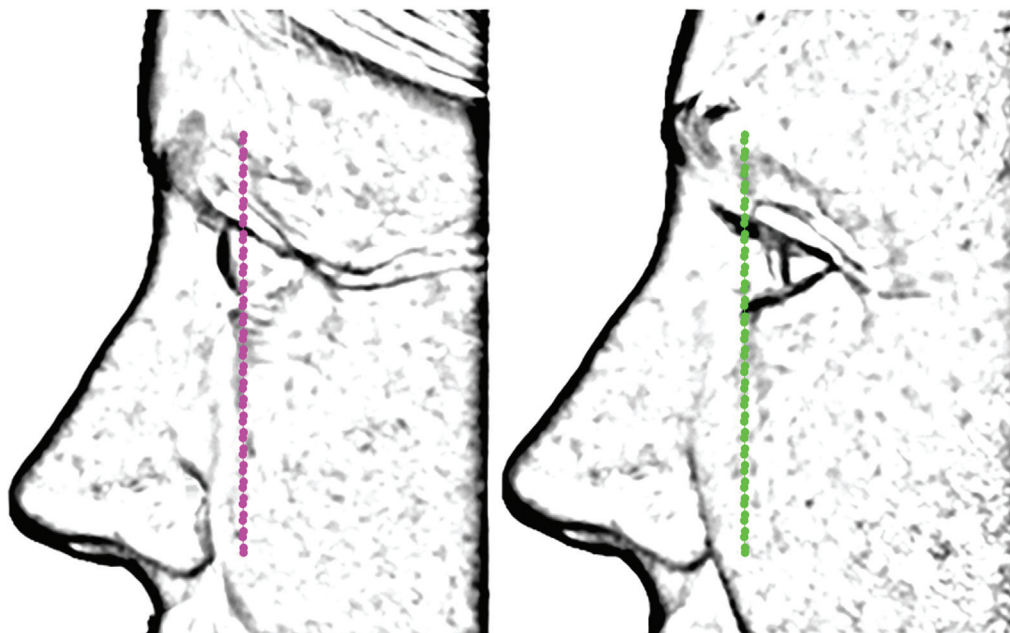


Fig. 1 The orbital vector. (Left) A negative orbital vector is present when the anterior surface of the globe lies anterior to the lower eyelid margin and malar eminence. (Right) A positive orbital vector is present when the anterior surface of the globe lies posterior to the lower eyelid margin and malar eminence. Correction of lower eyelid retraction in paralytic lagophthalmos is more challenging in patients with negative orbital vectors. A neutral orbital vector is present when the anterior surface of the globe lies at the level of the lower eyelid margin and malar eminence (not shown).

lower eyelid to simulate correcting horizontal eyelid laxity alone; if a second finger is necessary to further elevate the lower eyelid to correct its malposition, then a negative vector is present.

Therapeutic Management

Therapeutic management of paralytic lagophthalmos is guided by prognosis. There is utility in classifying patients with paralytic lagophthalmos into distinct management domains, based on timing of presentation, and status of the facial nerve and orbicularis oculi musculature: paralytic lagophthalmos with potential for spontaneous recovery, paralytic lagophthalmos without potential for spontaneous recovery and with viable orbicularis oculi muscle, and paralytic lagophthalmos without viable oculi muscle.

Conservative Measures

Spontaneous recovery of lower eyelid tone and position over a period of weeks to months is expected for non-neoplastic etiologies of acute flaccid facial palsy including Bell palsy, Ramsay Hunt syndrome, and Lyme disease-associated facial palsy. In cases where spontaneous recovery is expected, watchful waiting with conservative measures including frequent preservative-free artificial tears during the daytime, humidity chambers, and placement of ophthalmic lubricating gel and taping of the eyelid closed overnight often suffice. Some patients may benefit from hydroxypropyl cellulose ophthalmic inserts in lieu of frequent artificial tears. External or temporary placement of an upper eyelid weight may be considered where sicca symptoms are severe. Tarsorrhaphy should be considered where ocular surface injury has

already occurred and for high-risk patients, such as those who lack an adequate Bell's phenomenon or normal corneal sensation.⁴ Tarsorrhaphies may be taken down once oculi function has recovered. Lower eyelid procedures necessitating lateral canthotomy or cantholysis (such as lateral tarsal strip or tarsoconjunctival flaps) should be avoided in cases where spontaneous recovery is expected, as they may yield suboptimal visual field and aesthetic outcomes once oculi function returns, such as medial malposition, rounding, or dystopia of the lateral canthus.

Nerve Repair and Nerve Transfer

Where paralytic lagophthalmos has arisen secondary to an acquired discontinuity of the facial nerve, or where no recovery of facial function is noted 10 to 12 months following injury to an otherwise intact facial nerve, therapeutic management should focus on reestablishing motor neuron input to the oculi muscle. Evidence indicates that facial musculature remains receptive to reinnervation for periods up to 24 months following denervation in adults.⁵⁻⁸ Reanimation of the oculi muscle may be achieved via nerve repair or nerve transfer. Tension-free direct repair or interposition graft repair should be executed where the facial nerve discontinuity is surgically accessible. Where facial nerve repair is unfeasible (e.g., proximal injury to the facial nerve near the brainstem), transfer of a portion of ipsilateral hypoglossal nerve axons to the main trunk of the facial nerve is indicated to restore resting tone and some useful movements to the hemiface. Hypoglossal transfer to the main facial nerve trunk is increasingly being paired with targeted masseteric nerve transfer to lower zygomatic branches to restore volitional bite-driven smile movements.^{9,10} One downside of

masseteric nerve transfer is the near absence of resting tone the nerve provides to the midface and lower oculi muscle, often necessitating ancillary static repositioning procedures to restore adequate resting lower eyelid height.

Cross-facial nerve grafting is another option for restoring meaningful oculi function in unilateral paralytic lagophthalmos, whereby long nerve autografts are interposed between the proximal stump of redundant facial nerve branches driving blink on the unaffected side of the face to distal stumps of branches terminating in oculi muscle on the paralyzed side. Owing to the slow rate of human axonal regeneration over long distances and the limited window of time in which denervated muscle may be reanimated, cross-facial nerve grafting approaches are typically employed in staged “babysitter” fashion. The original babysitter approach was first characterized by Terzis, wherein motor neuronal input to the facial musculature is first reestablished by ipsilateral transfer of hypoglossal axons concomitant with placement of long cross-facial nerve grafts, with delayed distal coaptation of cross-facial nerve grafts to affected side nerve branches several months later to allow for axonal extension across the graft while minimizing oculi denervation time.^{11,12}

Static Repositioning of the Paralyzed Lower Eyelid

Definitive static repositioning of the paralyzed lower eyelid is typically employed where reanimation of native oculi muscle is deemed unattainable. Manifold static techniques have been characterized to address lower eyelid malposition in paralytic lagophthalmos. Decision making and patient counseling should be guided by the effectiveness of a given technique in reducing ocular exposure risk, in maintaining adequate visual fields, and of yielding an acceptable aesthetic result. Nearly all static repositioning techniques yield partial loss of the inferior visual field owing to restriction of lower eyelid lowering with downward gaze. Though effective in reducing sicca symptoms and protecting the ocular surface, lateral tarsorrhaphy and tarsoconjunctival flap techniques yield suboptimal aesthetics and impairments in temporal visual fields.^{13,14} Lateral tarsal strip and lateral wedge resections may suffice in many cases to address horizontal laxity and lower lid malposition in paralytic lagophthalmos, but may demonstrate loss of correction over time (►Fig. 2) and insufficient correction of medial lagophthalmos,¹⁵ and are generally unsuitable in isolation for correction of lower eyelid retraction in patients with negative orbital vectors.¹⁶

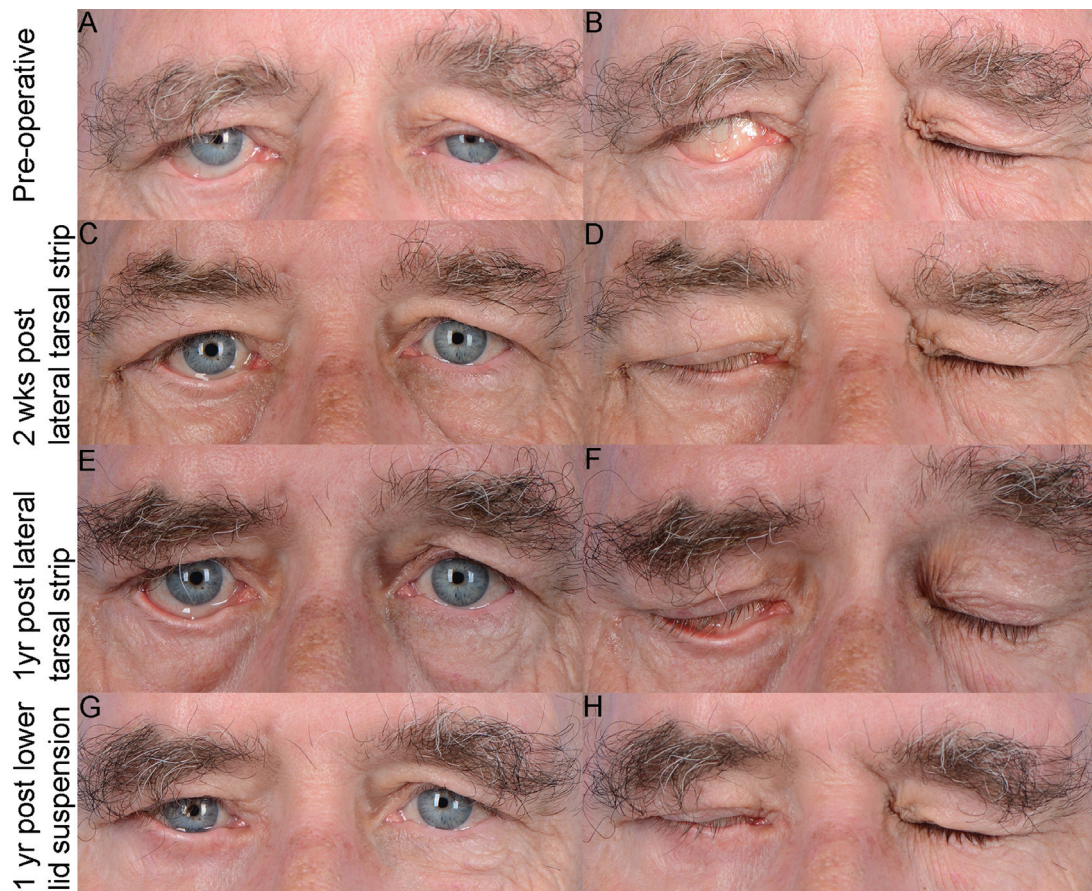


Fig. 2 Loss of correction following lateral tarsal strip procedure for lower eyelid malposition in paralytic lagophthalmos and subsequent revision by fascia suspension. Preoperative photographs at rest (A) and with light-effort blink (B) demonstrate right lower eyelid malposition with upper eyelid lagophthalmos in a patient with long-standing right facial paralysis and a negative orbital vector. Two weeks following right lateral tarsal strip procedure, upper eyelid weighting, and brow ptosis correction, lower eyelid retraction is improved but not fully corrected at rest (C), and lagophthalmos with light-effort blink (D) is still noted. One year following the procedure, complete loss of lower eyelid correction is noted at rest (E) with prominent lower lid lagophthalmos with light-effort blink (F). One year following revision lower eyelid suspension by fascia lata graft secured to medial and lateral orbital walls, adequate correction of lower lid retraction is demonstrated at rest (G) and eye closure is complete with light effort (H).

Placement of a spacer graft into the posterior lamella of the lower eyelid has been described in isolation or in combination with lateral tarsal procedures to augment lower eyelid height in paralytic lagophthalmos.^{17,18} Spacer grafts may comprise autologous hard palate or conchal cartilage, or allogenic acellular dermal matrix.¹⁹ Complications of spacer graft placement include insufficient correction and graft buckling or contracture, yielding suboptimal aesthetics and loss of correction over time.²⁰

Lower eyelid suspension by autologous fascia or tendon graft to correct lower eyelid retraction has been described using various techniques.^{21–29} Lower eyelid suspension is presently this author's favored static technique for correction of lower eyelid malposition in long-standing paralytic lagophthalmos given its tunability and reliability.¹⁵ The technique may be performed in office using local anesthesia in isolation or paired with lateral tarsal strip for simultaneous correction of horizontal laxity of the lower eyelid.

In-Office Technique: Lower Eyelid Suspension via Palmaris Longus Tendon Graft

A local anesthetic (lidocaine 1% in 1:100,000 epinephrine) solution is injected about the anterior lamella of the lower eyelid, medial and lateral canthi, and graft donor site. Palmaris longus tendon graft is favored when present, harvested from the nondominant hand (→Fig. 3A) using a tendon or vein stripper through one or two 1/4" incisions to a length of at least 6 to 7 cm. Knowledge of the relevant anatomy of the volar wrist is critical to avoid inadvertent injury to the median nerve or flexor carpi radialis tendon during palmaris longus tendon harvest.³⁰ Alternatively, a 6- to 7-cm strip of temporalis fascia may be harvested under local anesthesia with care to avoid injury to auriculotemporal sensory branches of the trigeminal nerve and temporal branches of the facial nerve.

Three miniature periocular incisions are then made as illustrated in →Fig. 3B in the medial upper and lower eyelids, and lateral canthus. Starting in the upper eyelid, blunt dissection is employed superficial to the orbital septum toward the lateral nasal wall. A 2-mm region of the superior aspect of the anterior lacrimal crest is identified and osteotomy made using a hand drill with 1.4 mm drill bit (→Fig. 3C) into which a titanium bone anchor (DePuy Mitek Micro Quickanchor Plus, J&J Inc.) with attached 3-0 Ethibond sutures is placed (→Fig. 3D, E). A Wright fascia needle is then passed between upper and lower medial eyelid incisions to interpose the tendon graft in a plane deep to the superficial limb of the medial canthal tendon and superficial to the course of the lacrimal canaliculi (→Fig. 3F). The graft is then secured medially to the bone anchor. The Wright fascia needle is then passed from the lateral canthotomy incision to the medial lower eyelid incision in the pretarsal plane just inferior to the lash line (→Fig. 3G). The fascia is interposed across the anterior lamella, then passed deep to remnant pretarsal orbicularis oculi muscle in the lateral canthal region with preservation of the lateral canthal tendon (→Fig. 3H) and secured to periosteum of the frontal process of the zygoma using 3-0 Ethibond sutures. Alternatively, if horizontal laxity of the eyelid is noted preoperatively, the graft may be directly sutured to the lateral aspect

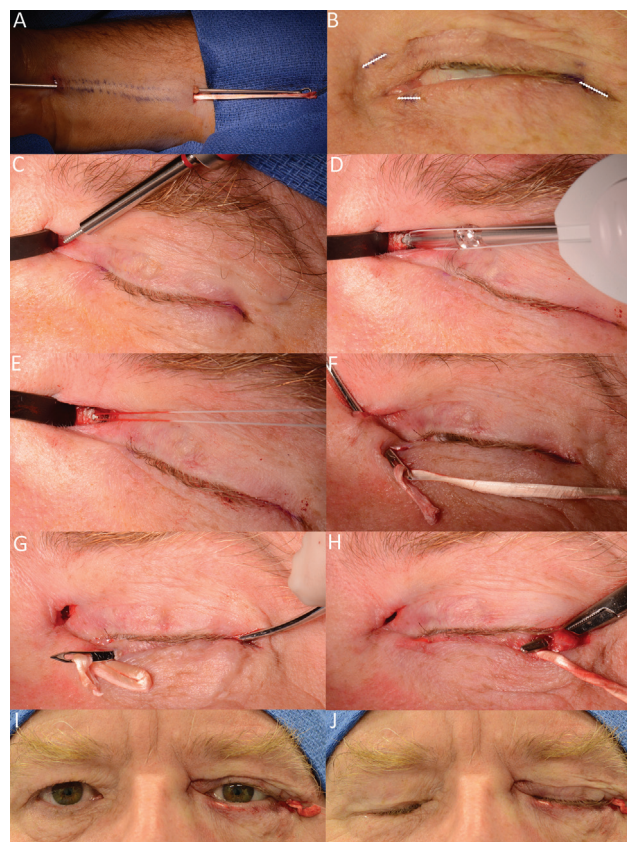


Fig. 3 In-office lower eyelid suspension with palmaris longus tendon graft. (A) A 6- to 7-cm long palmaris longus tendon graft is harvested through one or two small incisions in the volar forearm on the nondominant hand side using a tendon or vein stripper. (B) Three small periocular incisions are made as shown using the white dotted lines. (C) An osteotomy is made in anterior lacrimal crest using a hand drill with affixed 1.4 mm drill bit. (D) A 1.3-mm titanium suture anchor is positioned into the osteotomy (E) (F) A Wright fascia needle is employed to interpose the graft between the upper and lower medial eyelid incisions in a plane deep to the superficial limb of the medial canthal tendon and superficial to the lacrimal canaliculus. (G) The graft is then interposed between medial and lateral incisions in the pretarsal plane of the lower eyelid just below the lash line using a Wright fascia needle. (H) The graft is then passed deep to remnant oculi fibers about the lateral canthal tendon; the lateral canthal tendon may be left intact where minimal horizontal laxity of the lower eyelid is noted. (I, J) With the patient sitting up, the optimal height and tension of fixation of the graft to the periosteum overlying the frontal process of the zygoma to obtain adequate correction of resting lower eyelid retraction and lower eyelid lagophthalmos is determined.

of the inferior tarsus following cantholysis and lateral tarsal strip. The height and tension of the lateral fixation point of the graft is adjusted with the patient sitting up to observe the effects on lower eyelid resting position and blink. In patients with negative orbital vectors, securing the graft higher up on the frontal process of the zygoma under minimal tension is typically sufficient to achieve adequate correction of lower eyelid retraction. →Fig. 4 illustrates preoperative and early postoperative results of the patient who underwent in-office lower eyelid suspension using the technique illustrated in →Fig. 3. →Fig. 5 illustrates preoperative and early postoperative results of a second patient who underwent the procedure concurrent with reversal of a lateral tarsorrhaphy, illustrating the advantages of the technique in correcting medial and

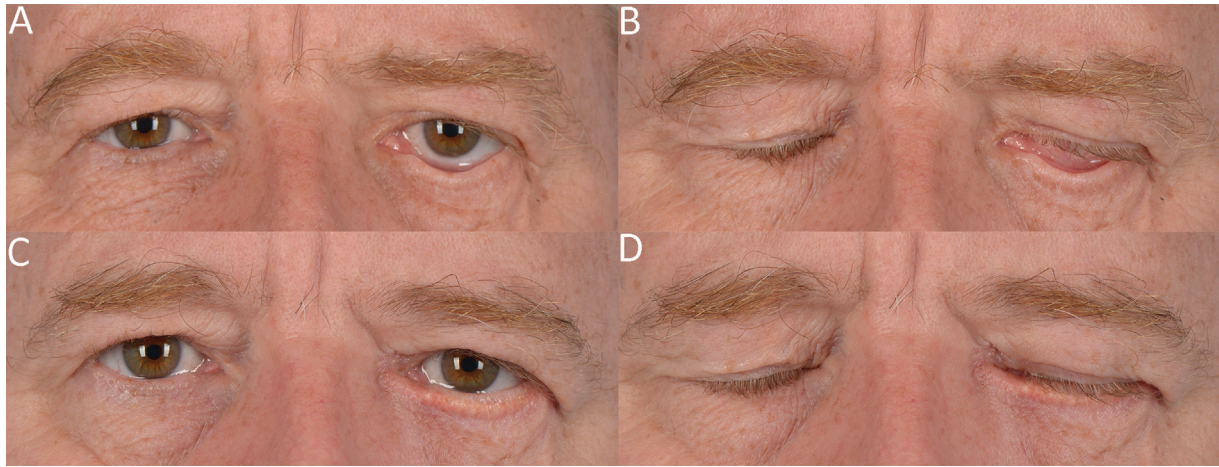


Fig. 4 Pre- and early post-operative results of in-office palmaris longus tendon suspension of lower eyelid (of procedure shown in ►Fig. 3). Preoperative photos at rest (A) and with light-effort blink (B) in a patient with left facial palsy of 1 year duration and a positive orbital vector. Three weeks after in-office correction, near optimal position of the left lower eyelid height is noted at rest (C), together with complete eye closure with light-effort (D). The patient required no upper eyelid weight.

lateral lower eyelid retraction while yielding satisfactory ocular aesthetics and improved temporal visual field.

Functional Muscle Transfers

Restoration of dynamic blink in long-standing paralytic lagophthalmos via neurotized free muscle transfer was first reported in 1984.³¹ The technique employed free platysma muscle transfer, but never gained widespread adoption owing to its technical complexity. In 2014, it was observed that small nonvascularized free muscle grafts positioned about the proximal stump of a severed motor nerve could undergo a process of degeneration, regeneration, and reinnervation and serve as an interface for transmission of

electromyography signals for prosthetic control.³² That such regenerative peripheral nerve interfaces are possible suggests that nonvascularized thin muscle grafts neurotized by cross-facial nerve autografts may be a suitable strategy for reconstruction of oculi function in long-standing facial palsy. Nassif and Yung Chia recently characterized initial results of blink reanimation via cross-facial nerve grafting paired with second-stage direct neurotization of free nonvascularized platysma grafts secured across the lower and upper eyelids.³³ Multivector free vascularized functional muscle flaps also carry potential for simultaneous reanimation of dynamic smile and blink function in patients with facial palsy.^{34,35}

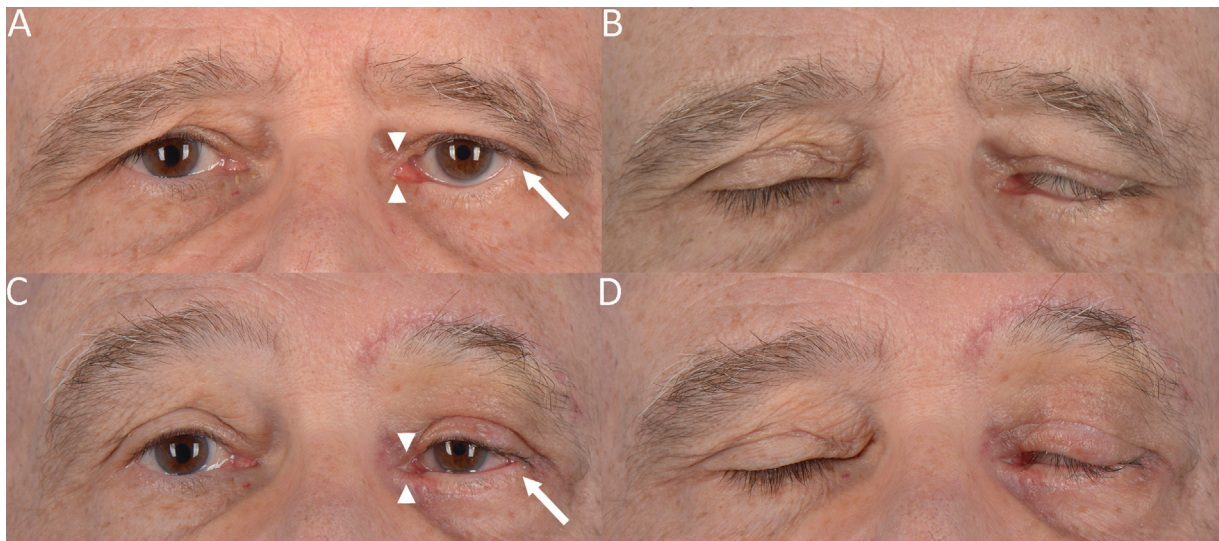


Fig. 5 Pre- and early postoperative results of in-office palmaris longus tendon suspension of lower eyelid with concomitant takedown of a lateral tarsorrhaphy. (A, B) Preoperative photos in a patient with left facial palsy of 20 years' duration and a neutral orbital vector. The patient noted chronic impairment in temporal visual fields. Note widening of the medial aspect of the palpebral fissure (arrowheads), rounding of the lateral canthus and disruption of ocular aesthetics owing to the tarsorrhaphy (arrow) at rest (A) and incomplete closure with light effort despite presence of an upper eyelid weight (B). Three weeks after in-office lower eyelid suspension with palmaris longus tendon graft, reversal of lateral tarsorrhaphy, and direct brow lift, an improvement in medial canthal ptosis and ocular aesthetics are noted at rest (C), in addition to improvement in eye closure with light-effort blink (D).

Conclusion

Lower eyelid malposition in facial paralysis warrants intervention to reduce corneal exposure symptoms and risks to vision. Conservative measures targeted at maintaining ocular surface lubrication suffice for most instances of paralytic lagophthalmos secondary to self-limiting etiologies. Surgical intervention is merited where spontaneous recovery is unlikely. Reanimation of native oculi muscle should be prioritized where feasible. In-office static suspension of the lower eyelid may yield immediate and lasting correction of lower eyelid retraction with enhanced aesthetics compared to lateral strip and tarsorrhaphy techniques. Increasing adoption of vascularized and nonvascularized functional muscle transfer techniques for eyelid reanimation is likely over the next decade.

Conflict of Interest

None declared.

References

- Pereira MV, Glória AL. Lagophthalmos. *Semin Ophthalmol* 2010; 25(03):72–78
- Homer N, Fay A. Management of long-standing flaccid facial palsy: periocular considerations. *Otolaryngol Clin North Am* 2018;51(06):1107–1118
- Jowett N. A general approach to facial palsy. *Otolaryngol Clin North Am* 2018;51(06):1019–1031
- Jowett N, Pineda R II. Corneal and facial sensory neurotization in trigeminal anesthesia. *Facial Plast Surg Clin North Am* 2021;29(03):459–470
- Wu P, Chawla A, Spinner RJ, et al. Key changes in denervated muscles and their impact on regeneration and reinnervation. *Neural Regen Res* 2014;9(20):1796–1809
- Conley J. Hypoglossal crossover—122 cases. *Trans Sect Otolaryngol Am Acad Ophthalmol Otolaryngol* 1977;84(4 Pt 1):ORL-763–ORL-768
- Gavron JP, Clemis JD. Hypoglossal-facial nerve anastomosis: a review of forty cases caused by facial nerve injuries in the posterior fossa. *Laryngoscope* 1984;94(11 Pt 1):1447–1450
- Kunihiro T, Kanzaki J, Yoshihara S, Satoh Y, Satoh A. Hypoglossal-facial nerve anastomosis after acoustic neuroma resection: influence of the time anastomosis on recovery of facial movement. *ORL J Otorhinolaryngol Relat Spec* 1996;58(01):32–35
- Klebec M. Masseter-to-facial nerve transfer: a new technique for facial reanimation. *J Reconstr Microsurg* 2006;22(03):A101
- Klebec MJA. Facial reanimation using the masseter-to-facial nerve transfer. *Plast Reconstr Surg* 2011;127(05):1909–1915
- Terzis JK. “Babysitter”: An Exciting New Concept in Facial Reanimation. Paper presented at: Proceedings of the Sixth Int’l Symposium on the Facial Nerve. October 2–5, 1988, Rio de Janeiro, Brazil
- Terzis JK, Tzafetta K. The “babysitter” procedure: minihypoglossal to facial nerve transfer and cross-facial nerve grafting. *Plast Reconstr Surg* 2009;123(03):865–876
- Joseph SS, Joseph AW, Douglas RS, Massry GG. Periocular reconstruction in patients with facial paralysis. *Otolaryngol Clin North Am* 2016;49(02):475–487
- Sohrab M, Abugo U, Grant M, Merbs S. Management of the eye in facial paralysis. *Facial Plast Surg* 2015;31(02):140–144
- Bartholomew RA, Ein L, Jowett N. Lower eyelid sling for primary and revision correction of paralytic lagophthalmos. *Facial Plast Surg Aesthet Med* 2022. Doi: 10.1089/fpsam.2022.0096
- Vahdani K, Ford R, Garrett H, Thaller VT. Lateral tarsal strip versus Bick’s procedure in correction of eyelid malposition. *Eye (Lond)* 2018;32(06):1117–1122
- Kim MJ, Choi YM, Kim N, Choung H-K, Khwarg SI. The effects of using spacer grafts on lower-eyelid retraction surgery in patients with facial nerve palsy. *Eur J Ophthalmol* 2022;32(04):2072–2077
- Krastinova D, Franchi G, Kelly MB, Chabolle F. Rehabilitation of the paralysed or lax lower eyelid using a graft of conchal cartilage. *Br J Plast Surg* 2002;55(01):12–19
- Taban M, Douglas R, Li T, Goldberg RA, Shorr N. Efficacy of “thick” acellular human dermis (AlloDerm) for lower eyelid reconstruction: comparison with hard palate and thin AlloDerm grafts. *Arch Facial Plast Surg* 2005;7(01):38–44
- Park E, Lewis K, Alghoul MS. Comparison of efficacy and complications among various spacer grafts in the treatment of lower eyelid retraction: a systematic review. *Aesthet Surg J* 2017;37(07):743–754
- Gillies H. Experiences with fascia lata grafts in the operative treatment of facial paralysis: section of otology and section of laryngology. *Proc R Soc Med* 1934;27(10):1372–1382
- de la Torre J, Simpson RL, Tenenhaus M, Bourhill I. Using lower eyelid fascial slings for recalcitrant burn ectropion. *Ann Plast Surg* 2001;46(06):621–624
- Yoo J, Matic D. Transnasal tendon suspension for the paralyzed lower eyelid. *J Plast Reconstr Aesthet Surg* 2015;68(08):1072–1078
- Terzis JK, Kyere SA. Minitendon graft transfer for suspension of the paralyzed lower eyelid: our experience. *Plast Reconstr Surg* 2008;121(04):1206–1216
- Hontanilla B, Gómez-Ruiz R. Surgical correction of lower eyelid paralysis with suture screw anchors. *J Plast Reconstr Aesthet Surg* 2009;62(12):1598–1601
- Senders CW, Tollefson TT, Curtiss S, Wong-Foy A, Prahlad H. Force requirements for artificial muscle to create an eyelid blink with eyelid sling. *Arch Facial Plast Surg* 2010;12(01):30–36
- Sendul SY, Cagatay HH, Dirim B, et al. Effectiveness of the lower eyelid suspension using fascia lata graft for the treatment of lagophthalmos due to facial paralysis. *BioMed Res Int* 2015; 2015:759793
- Rose EH. Autogenous fascia lata grafts: clinical applications in reanimation of the totally or partially paralyzed face. *Plast Reconstr Surg* 2005;116(01):20–32, discussion 33–35
- Hayashi A, Maruyama Y, Okada E, Ogino A. Use of a suture anchor for correction of ectropion in facial paralysis. *Plast Reconstr Surg* 2005;115(01):234–239
- Leslie BM, Osterman AL, Wolfe SW. Inadvertent harvest of the median nerve instead of the palmaris longus tendon. *J Bone Joint Surg Am* 2017;99(14):1173–1182
- Lee K, Terzis J. Reanimation of the eye sphincter. Paper presented at: Fifth International Symposium on the Facial Nerve. ; September 3–6, 1984, Bordeaux, France
- Kung TA, Langhals NB, Martin DC, Johnson PJ, Cederna PS, Urbanek MG. Regenerative peripheral nerve interface viability and signal transduction with an implanted electrode. *Plast Reconstr Surg* 2014;133(06):1380–1394
- Nassif T, Yung Chia C. Neurotized platysma graft: a new technique for functional reanimation of the eye sphincter in longstanding facial paralysis. *Plast Reconstr Surg* 2019;144(06):1061e–1070e
- Ein L, Hadlock TA, Jowett N. Dual-vector gracilis muscle transfer for smile reanimation with lower lip depression. *Laryngoscope* 2021;131(08):1758–1760
- Boahene KO, Owusu J, Ishii L, et al. The multivector gracilis free functional muscle flap for facial reanimation. *JAMA Facial Plast Surg* 2018;20(04):300–306