



Internal Hernia After Laparoscopic Left Colectomy: Case Series and Review of the Literature

Danilo Tueme-de la Peña¹ José Adolfo Acosta-Flores² Alan Alejandro Garza-Cantú³
Hugo Antonio Rangel-Ríos³ Alberto Félix Chapa-Lobo³ Luis Enrique Salgado-Cruz^{2,3}

¹ Department of Surgery, Division of Colorectal Surgery, Instituto Nacional de Ciencias Médicas y Nutrición "Salvador Zubirán", Mexico City, México

² Department of General Surgery, Escuela de Medicina y Ciencias de la Salud del Tecnológico de Monterrey, Monterrey, Nuevo León, México

³ Department of Surgery, Division of Coloproctology, Colomcare, Hospital Ángeles Valle Oriente, San Pedro Garza García, Nuevo León, México

Address for correspondence Luis E. Salgado-Cruz, MD, Colomcare, Hospital Ángeles Valle Oriente, Av. Cto. Frida Kahlo 180, Valle Oriente, San Pedro Garza García, Nuevo León, CP 66260, México (e-mail: salgado.luis@gmail.com).

J Coloproctol 2022;42(4):348–351.

Abstract

Objective Laparoscopic colectomy has gained acceptance as a standard treatment for benign and malignant colorectal disease, such as diverticular disease and cancer, among others. Same as in open surgery, the laparoscopic approach carries a low risk of small bowel obstruction in the postoperative period, but in laparoscopic surgery, internal hernia after laparoscopic left colectomy may be a cause of small bowel obstruction with a significant risk of morbidity and mortality. This rare complication may be prevented with routine closure of the mesenteric defects created during the colectomy.

Methods We present four cases of internal herniation after laparoscopic colectomy. Two cases were after laparoscopic left colectomy and two after laparoscopic low anterior resection. All four cases had full splenic flexure mobilization. Routine closure of the mesenteric defect was not performed in the initial surgery.

Results The four patients were treated by laparoscopic reintervention with closure of the mesenteric defect. In two of them, conversion to open surgery was necessary. One of the patients developed recurrent internal herniation after surgical reintervention with mesenteric closure of the defect. All patients were managed without need for bowel resection, and mortality rate was 0%.

Conclusion Internal herniation after laparoscopic colorectal surgery is a highly morbid complication that requires prompt diagnosis and management and should be suspected in the early postoperative period. Additional studies with extended follow-up are required to establish recommendations regarding its prevention and management.

Keywords

- ▶ laparoscopic left hemicolectomy
- ▶ internal hernia
- ▶ lesser omental sac
- ▶ mesenteric defect
- ▶ laparoscopic low anterior resection

received

August 18, 2022

accepted after revision

October 25, 2022

DOI <https://doi.org/10.1055/s-0042-1759608>.

ISSN 2237-9363.

© 2022. Sociedade Brasileira de Coloproctologia. All rights reserved.

This is an open access article published by Thieme under the terms of the Creative Commons Attribution-NonDerivative-NonCommercial-License, permitting copying and reproduction so long as the original work is given appropriate credit. Contents may not be used for commercial purposes, or adapted, remixed, transformed or built upon. (<https://creativecommons.org/licenses/by-nc-nd/4.0/>)

Thieme Revinter Publicações Ltda., Rua do Matoso 170, Rio de Janeiro, RJ, CEP 20270-135, Brazil

Introduction

Since 1991, when Jacobs et al. described the first reports of colonic resections with laparoscopic assistance in Miami, Florida, laparoscopic colectomy has gained acceptance as a standard treatment for benign and malignant colorectal disease, such as diverticular disease and cancer, among others.¹ The laparoscopic approach has equivalent results in long-term survival in terms of colon cancer and offers the benefits of a minimally invasive approach. The risk of small bowel obstruction also has a similar rate; nevertheless, the need for operative intervention is lower in laparoscopic surgery. In contrast to open surgery, a peculiarity of laparoscopic colectomy is that there is no routine closure of mesenteric defects. However, since 1999, there have been scarce reports of symptomatic internal hernias forming through mesenteric defects. It is necessary to be aware of the possibility of internal herniation in laparoscopic colectomy as it poses as a morbid complication. We herein report four cases of symptomatic internal hernias after laparoscopic left-sided colorectal surgery, their evolution and management.

Case 1 Presentation

A 64-year-old female with history of recurrent diverticulitis was admitted to our hospital for surgical resection of descending and sigmoid colon. Laparoscopic-assisted left colectomy was elicited with a functional end-to-end anastomosis with a circular stapler. The patient was discharged uneventfully and 6 weeks later she returned to the ER with abdominal pain, bloating, nausea, and vomiting. X-ray abdominal plain films showed multiple dilated small bowel loops and air fluid levels in the left upper quadrant. The patient was admitted under the diagnosis of intestinal obstruction and treated conservatively, after a period of observation and without complete resolution of symptoms, with persistent abdominal pain and a high output from the nasogastric (NG) tube. The patient underwent computed tomography (CT), which showed dilated small bowel clustered in the left upper abdomen, engorged mesenteric vessels, and loops displaced behind the stomach. After these findings, the patient was taken to the operating room for diagnostic laparoscopy.

Laparoscopic findings showed free fluid and dilated small bowel protruding behind the lesser curvature of the stomach. The small bowel was herniated into the lesser omental sac between the mesenteric defect and the retroperitoneum, with a portion visible through the pars flaccida. After several failed attempts of reduction via laparoscopy, a decision to convert to laparotomy was made due to the high probability of intestinal perforation.

After reduction, the small bowel recovered completely and no intestinal resection was required. After repositioning of the small bowel, the mesenteric defect was closed with 2 interrupted non-absorbable sutures. The patient was discharged 5 days after the reintervention.

Case 2 Presentation

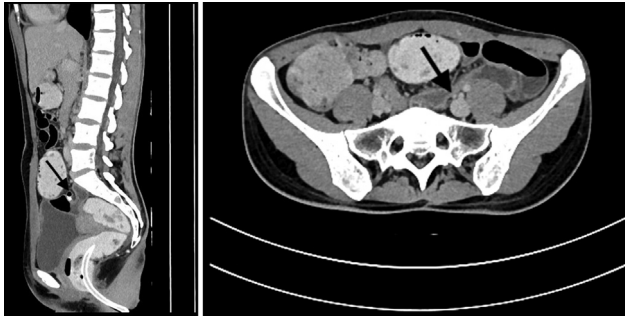
A 46-year-old male with a stage IVa middle rectal cancer who received neoadjuvant chemo and radiotherapy was admitted for surgical treatment. He underwent a laparoscopic low anterior resection with a double-stapled colorectal anastomosis and a loop ileostomy. During the early postoperative period, the patient developed a reduced output from the ileostomy and abdominal distention at postoperative day 5. The CT scan showed dilatation of the small bowel and a cluster of bowels behind and displaced the descending colon. The patient was consented and explored laparoscopically, and an internal hernia was found behind the descending colon through a mesenteric defect. While reducing the hernia content, the bowel was injured and conversion to open surgery was decided on to complete reduction, enterorrhaphy, and repositioning of the small bowel. Postoperatively, the patient developed a pelvic collection treated with percutaneous drainage and pneumonia and was discharged after 30 days of hospital stay.

Case 3 Presentation

A 56-year-old male with history of a stage-II left colon cancer that was treated with a laparoscopic assisted left colectomy 8 days prior to the initial obstructive symptoms. The patient was evaluated clinically and with a CT scan, which showed dilated small bowel loops displaced to the left abdomen, and air fluid levels. The patient was explored laparoscopically, and a herniation of the small bowel was found behind the colon. Reduction was not achieved laparoscopically, and conversion to open surgery was performed. After reduction and repositioning of the small bowel, no intestinal resection was required. The patient evolved favorably and was discharged 4 days after the reintervention.

Case 4 Presentation

A 29-year-old female with diagnosis of low rectal cancer underwent laparoscopic low anterior resection, hand sewn coloanal anastomosis, and loop ileostomy. She was admitted 30 days later complaining of distension, abdominal pain, and nausea; the ileostomy had low output as well as mucous discharge. A CT scan with contrast showed fluid-filled, dilated small bowel with transitional zone in the pelvis (→Figs. 1 & 2); therefore, the patient was brought to the operating room where a diagnostic laparoscopy was performed. During the procedure, dilated small bowel loops were identified behind the mesocolon, and a reduction of the internal hernia was done with repositioning of the bowel. The patient had a complete resolution of symptoms and was discharged 24 hours after the procedure. Afterwards, the patient returned for an ileostomy reversal which 60 days later, which was done uneventfully. Four months after the last surgical procedure, the patient came back to the emergency department, once again complaining of abdominal distension, nausea, and abdominal pain. She reported 48 hours of constipation at the moment of hospital



Figs. 1 & 2 Computed tomography abdominal scan with rectal contrast showing dilated small bowel with transitional zone in the pelvis (arrow).

admission. Imaging studies showed internal intestinal hernia associated with pseudo-obstruction and intrabdominal free fluid in the recto-uterine pouch. She was taken to laparoscopic exploration, where reduction of the intestinal hernia was performed for a second time, and, to prevent further recurrences, the running suture of the mesocolon was done with a barbed suture. The patient had a prompt recovery after the procedure and was discharged from the hospital. Unfortunately, she returned to the ER 3 months later, complaining of abdominal pain and distension. Computer tomography scan showed no signs of dilated intestinal loops but scarce free fluid and a suspected lesion of endometrioma. Diagnostic laparoscopy revealed, besides the preoperative suspicion of endometrioma, an asymptomatic recurrent internal hernia involving almost the total of the small bowel through a 4 cm opening in the previous closure of the mesenteric defect (→**Fig. 3**). Once again, continuous suture of the mesenteric defect was performed, with non-absorbable barbed suture, although this time it was done in a two-plane fashion (→**Fig. 4**). The postoperative course was uneventful, and the patient was discharged at postoperative day 3. At the 6-month follow-up, the patient remained asymptomatic. All

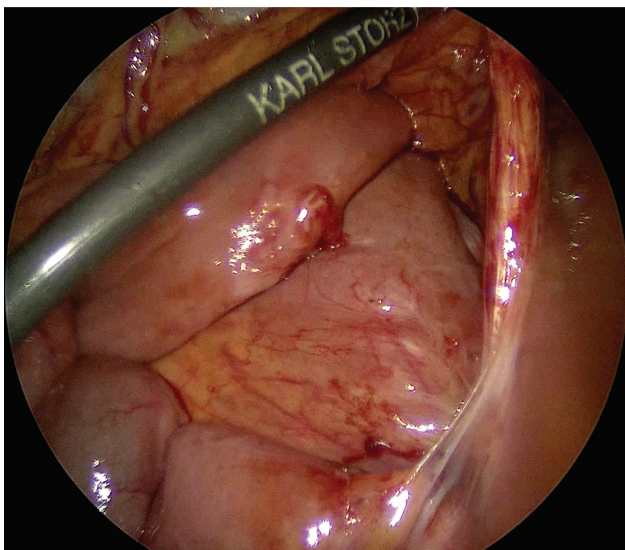


Fig. 3 Recurrent internal hernia after laparoscopic low anterior resection.

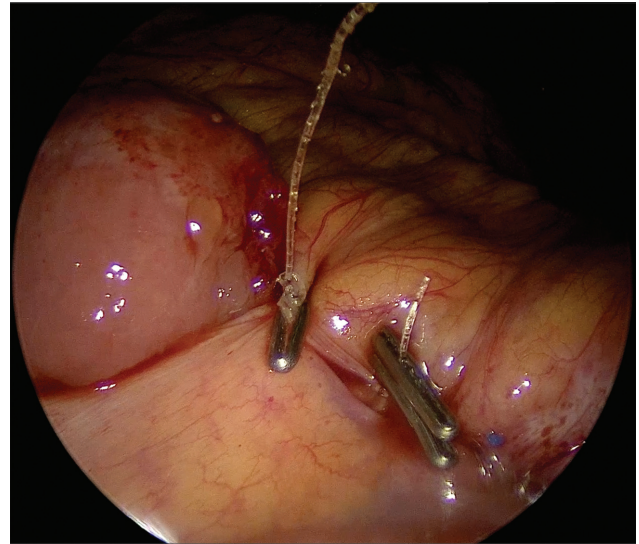


Fig. 4 Laparoscopic internal hernia repaired in a two-plane fashion with running non-absorbable barbed suture reinforced with running absorbable barbed suture.

four cases had full splenic flexure mobilization. In this case series, all patients managed without need for bowel resection, and mortality rate was 0%. A summary of patients characteristics, diagnosis, type of surgery and time to internal hernia formation is presented (→**Table 1**).

Discussion

Since the introduction of laparoscopic abdominal surgery and the first laparoscopic colonic resections in the early 1990s, some early concerns regarding its safety and oncological efficacy were raised.¹ Since then, several landmark trials emerged to mark the turning point in laparoscopic colorectal cancer surgery, making this the preferred approach when feasible.

Internal hernia has been described as a cause of small bowel obstruction after gastric bypass surgery, nephrectomy, liver, and kidney transplant surgery, laparoscopic Nissen procedure, and cholecystectomy, encouraging the closure of all the mesenteric-created defects.² However, regarding colorectal surgery, the reports of internal hernia are scarce; as one of the most morbid and dreadful complications, higher incidence has been reported in laparoscopic surgery when compared with open surgery, between 0.65 and 1.14%.³⁻⁵ However, recent studies have suggested the prevalence of asymptomatic internal hernia to be much higher, around 21%.⁶ Regardless of its low-incidence, internal hernia after colorectal surgery has a mortality rate of approximately 20%.^{2,4,7}

Several mechanisms have been proposed to explain internal herniation after laparoscopic colorectal surgery, such as reduced adhesions which allow free movement of the bowel inside the abdominal cavity, early mobility, the orientation of the small bowel mesentery from left to right with the fixation of the first jejunal loop posteriorly by the Treitz ligament direct the jejunal loops to the left,^{4,6} among

Table 1 Patient characteristics by gender, age, diagnosis, surgery, and internal hernia formation

	Gender	Age	Diagnosis	Surgery	Internal hernia formation
1	F	64	Diverticular disease	Laparoscopic left colectomy	42 days
2	M	46	Rectal cancer	Low anterior resection with loop ileostomy	5 days
3	M	56	Colon cancer	Laparoscopic left colectomy	8 days
4	F	29	Rectal cancer	Low anterior resection with loop ileostomy	30 days, recurrence 4 months later

others. As stated by Portale et al., most of the reported cases of symptomatic internal hernia following laparoscopic colorectal surgery in the literature have occurred after left-sided resections.⁸

An internal hernia may be asymptomatic or can cause symptoms such as abdominal distension and discomfort, nausea, vomiting, intermittent colicky pain, and recurrent intestinal obstruction.⁷ Abdominal pain has been the most common clinical sign reported. Regarding their presentation, most internal hernias develop during the early postoperative period, with 69% presenting within 10 days of the initial surgery, but few cases have been reported later than 3 years after the surgery.⁴ In suspected cases, the internal hernia is confirmed with a contrast-enhanced CT scan, as rectal contrast enema aids in interpretation; however, the diagnosis is not excluded in the absence of radiological signs.²

The standard approach with symptomatic internal hernia is reintervention, with or without closure of the mesenteric defect. There are several methods described for closure of the mesenteric defect, such as continuous suture, endo-hernia staples, Ligasure, clips, and fibrin glue.^{4,9} The surgical management may be done by either laparoscopic or open approach.¹⁰ The study by Däster et al. reports an incidence of asymptomatic internal hernia of 21%, which raises consideration for routine closure of the intermesenteric space. Such closure may be performed with two continuous sutures, or with fibrin sealant.⁶ In the study of Cabot et al., who investigated the long-term consequences of not closing the mesenteric defect after laparoscopic right colectomy, 530 patients were followed for a median of 20 months; two patients presented small bowel obstruction due to internal herniation and two had torsion of the anastomosis through the defect. They concluded that there are not enough data to support routinely closing of the mesenteric defect.¹¹ Similar findings were also reported by Tsai et al., who suggested that routine closure of the mesenteric defect after laparoscopic right colectomy might not be beneficial.¹² In the case of laparoscopic left colectomy, Sereno-Trabado et al. suggest that all mesenteric defects created during laparoscopic colorectal surgery should be closed given the high mortality rate associated with internal herniation (20%).^{2,4}

Conclusion

Internal hernia after laparoscopic colonic resection is a highly morbid complication that should be suspected mostly in the early postoperative period, although it can present several years after the surgery. Computed tomography scans

with rectal contrast enema can be helpful in diagnosing patients in the context of intestinal obstruction after laparoscopic colonic resection. Formation of internal hernias may be prevented by several methods of mesenteric defect closure during the initial surgery, but additional studies with extended follow-up are needed for this to be routinely done during the procedure.

Conflict of Interests

The authors have no conflict of interests to declare.

References

- Blackmore AE, Wong MTC, Tang CL. Evolution of laparoscopy in colorectal surgery: an evidence-based review. *World J Gastroenterol* 2014;20(17):4926–4933
- Sereno Trabaldo S, Anvari M, Leroy J, Marescaux J. Prevalence of internal hernias after laparoscopic colonic surgery. *J Gastrointest Surg* 2009;13(06):1107–1110
- Saklani A, Naguib N, Tanner N, Moorhouse S, Davies CE, Masoud AG. Internal herniation following laparoscopic left hemicolectomy: an underreported event. *J Laparoendosc Adv Surg Tech A* 2012;22(05):496–500
- Toh JWT, Lim R, Keshava A, Rickard MJFX. The risk of internal hernia or volvulus after laparoscopic colorectal surgery: a systematic review. *Colorectal Dis* 2016;18(12):1133–1141
- Sim WH, Wong KY. Mesenteric defect after laparoscopic left hemicolectomy: to close or not to close? *Int J Colorectal Dis* 2016;31(07):1389–1391
- Däster S, Xiang H, Yang J, Rowe D, Keshava A, Rickard MJFX. High prevalence of asymptomatic internal hernias after laparoscopic anterior resection in a retrospective analysis of postoperative computed tomography. *Int J Colorectal Dis* 2020;35(05):929–932
- Svraka M, Wilhelmsen M, Bulut O. Internal hernia following laparoscopic colorectal surgery: single center experience. *Pol Przegl Chir* 2017;89(05):19–22
- Portale G, Cipollari C, Zuin M, Spolverato Y, Fiscon V. Prevalence of internal hernia following laparoscopic colorectal surgery: single-center report on 1300 patients. *Surg Endosc* 2021;35(08):4315–4320. Disponible en: <https://doi.org/10.1007/s00464-020-07921-w>
- Angelini P, Sciuto A, Cuccurullo D, Pirozzi F, Reggio S, Corcione F. Prevention of internal hernias and pelvic adhesions following laparoscopic left-sided colorectal resection: the role of fibrin sealant. *Surg Endosc* 2017;31(07):3048–3055
- Portale G, Cipollari C, Zuin M, Spolverato Y, Fiscon V. Laparoscopic treatment of internal hernia following minimally invasive left hemicolectomy. *Tech Coloproctol* 2020;24(10):1089. Disponible en: <https://doi.org/10.1007/s10151-020-02233-6>
- Cabot JC, Lee SA, Yoo J, Nasar A, Whelan RL, Feingold DL. Long-term consequences of not closing the mesenteric defect after laparoscopic right colectomy. *Dis Colon Rectum* 2010;53(03):289–292
- Tsai KL, Lai WH, Lee KC, et al. Long-Term Consequences of Non-closure of Mesenteric Defects after Traditional Right Colectomy. *BioMed Res Int* 2018;2018:9123912