



# VAAFT PROCEDURE (Video-assisted Anal Fistula Treatment) versus Open Method in the Treatment of High Fistula in Ano

Asaad Mohammed Kadhim<sup>1</sup> Madhi Hashim Otaiwi Altaraikhim<sup>2</sup>

<sup>1</sup>Department of Surgery, College of Dentistry, University of Basrah, Basrah, Iraq

<sup>2</sup>Department of Dentist Medicines, Al- Kunooz University College, Basrah, Iraq

Address for correspondence Asaad Mohammed Kadhim, Professor, Department of Surgery, College of Dentistry, University of Basrah, Basrah, Iraq (e-mail: medicalresearch11@yahoo.com).

J Coloproctol 2022;42(4):322–326.

## Abstract

**Background** A common acquired anorectal condition is anal fistula. The treatment approaches that have been employed have been linked to erratic outcomes and sometimes life-threatening consequences. Video-assisted anal fistula treatment (VAAFT), a minimally invasive method, was introduced for adult patients in 2011.

**Objective** To know the efficacy of the VAAFT procedure in treating high anal fistulas and to compare it to open methods in the Basrah province.

**Methods** The present study was performed on 200 patients with high fistulas in ano in Basrah province. We divided the patients into 2 groups: Group A: treated by the VAAFT technique and Group B: treated by open fistulotomy

**Results** The patients treated with VAAFT revealed no occurrence of the following postoperative complication: Infection, incontinence, recurrence, anal stenosis, and bleeding. There was lower incidence of pain, short time for wound healing, rapid return to work, and more patient satisfaction compared with open fistulotomy

**Conclusion** An innovative method for managing ano fistula is VAAFT. Compared with traditional methods, it has a lot of benefits. It is day case surgery no open wound. no damage to anal sphincter and no risk of incontinence, it is more affordable. it allow for clear identification of internal office, whole tract and its associated branches and cavity. The instrument can be used for multiple patients after good sterilization and disinfection.

## Keywords

- ▶ anal fistula
- ▶ VAAFT
- ▶ minimally invasive approach

## Introduction

An epithelized connection between the rectum or anal canal and the perineum region, called an anal fistula, is of infectious origin. When a track crosses between 30 and 50% of the external sphincter (high trans-sphincteric, suprasphincteric,

and extrasphincteric fistulas), is recurs, has multiple tracks, or the patient has pre-existing incontinence, local irradiation, or Crohn disease, it is referred to as complex.<sup>1,2</sup> A complicated anal fistula is generally a source of concern for both patients and anorectal surgeons because of its high risk of recurrence and postoperative fecal incontinence.<sup>3</sup>

received  
September 10, 2022  
accepted after revision  
October 25, 2022

DOI <https://doi.org/10.1055/s-0042-1759607>.  
ISSN 2237-9363.

© 2022. Sociedade Brasileira de Coloproctologia. All rights reserved.

This is an open access article published by Thieme under the terms of the Creative Commons Attribution-NonDerivative-NonCommercial-License, permitting copying and reproduction so long as the original work is given appropriate credit. Contents may not be used for commercial purposes, or adapted, remixed, transformed or built upon. (<https://creativecommons.org/licenses/by-nc-nd/4.0/>)

Thieme Revinter Publicações Ltda., Rua do Matoso 170, Rio de Janeiro, RJ, CEP 20270-135, Brazil

Numerous sphincter-saving strategies have gained popularity as study topics in the management of complex anal fistulas in recent years due to the growing emphasis on the preservation of anal sphincter function. Fistula plugs, fibrin glue, transanal advancement flap repairs (TAFRs), and ligation of the intersphincteric fistula tract (LIFT) are currently the most common procedures.<sup>4</sup> However, their healing rates vary widely, from 14 to 81.4%.<sup>5-8</sup> Complex anal fistula is one of the most difficult clinical issues in anorectal surgery, despite several attempts to repair it over the years.<sup>4</sup>

Simple and most distal fistulas can be successfully treated with traditional surgical procedures such the lay-open operation and fistulotomy, with a success rate of almost 100%.<sup>9</sup> However, when they are used to manage complex anal fistulas, the high risks of recurrence and damage to anal sphincter function remain serious problems.<sup>3</sup> Complex anal fistulas were traditionally primarily treated by cutting setons. This procedure might help preserve some anal sphincter function. However, several studies showed that faecalis incontinence rates continued to be significant, ranging from 20.5 to 67%.<sup>10</sup> Draining Setons can reduce harm to the ability of the anal sphincter to function; however, the rates of fistula recurrence range from 19.5 to 47.0%.<sup>11,12</sup> Fibrin glue injection is a straightforward method with little side effects for healing complex anal fistulas, although the long-term success rate is only ~ 14%.<sup>8</sup>

Therefore, currently, fibrin glue injection is generally used in combination with other therapeutic approaches.<sup>11</sup> The primary causes of surgery failure are local tissue ischemia after mobilization of local structures and the tendency of flaps to retract or dehiscence. Anal fistula repair employing a unique radial emitting laser probe was first described by Wilhelm in 2011. After a median follow-up of 7.4 months, the healing rate was 81.8%.<sup>12,13</sup> The disadvantage of this method is the challenge of locating the internal aperture, secondary tracts, and abscess cavities.

Three fundamental principles underlie the majority of current treatments for complex anal fistulas: accurate identification of the fistula tracts and internal opening, total eradication of the tracts, and maintenance of anal sphincter function.<sup>13</sup> However, some studies have shown that the real key to fistula healing lies in the sealed closure of the internal opening coupled with adequate drainage of the fistula tract.<sup>14</sup>

Video-assisted anal fistula treatment (VAAFT), invented by Meinero in 2006, is a cutting-edge, minimally invasive method for treating difficult anal fistula.<sup>13</sup> The direct view of the fistula tract and internal opening is this key characteristic of the technique. However, VAAFT clinical use is still relatively new globally, and reported success rates range from 66.7 to 87.5%.<sup>15-18</sup> Therefore, additional research is required to determine both its effectiveness and indication.

The goal of the present study was to explain this method for treating patients with high anal fistulas utilizing VAAFT and to compare it to open methods for treating high fistulas in ano in the Basrah province

## Methods

### Study Design and Setting

The present study was performed on 200 patients with high fistulas in ano in the Basrah province; all patients were assessed preoperatively by taking history particularly of previous surgery, examination of anal canal, proctoscopy, and radiological assessment by magnetic resonance imaging (MRI) to know the type of fistula. We divided the patients into 2 groups:

Group A: treated by the VAAFT technique

Group B: treated by open Fistulotomy

Then we compared the following items in both groups:

1. Surgical site infection
2. Incontinence
3. Recurrence
4. Bleeding
5. Pain
6. Time of operation
7. Anal stenosis
8. Days of hospitalization
9. Wound healing
10. Return to work
11. Cost
12. Patient satisfaction

### Surgical Technique

The VAAFT procedure<sup>8</sup> consists of:

1. Three doses of ceftriaxone 1 gm IV given every 12 hours beginning 30 minutes before surgery as an antibiotic prophylactic.
2. Anesthesia-induced examination to identify the exterior entrance of the fistula.
3. Electrostimulation to validate the alleged trans-sphincteric or suprasphincteric course of the fistula.
4. High-pressure saline irrigation of the fistula (to achieve enlargement of the internal lumen of the fistula).
5. Fistuloscopy using a pediatric standard 3.3-mm coaxial operative cystoscope to view the course of the fistula and spot any side tracts that extend up to the internal anal or rectal entrance. As there were no pediatric-sized instruments available, a suitable fistuloscope was not employed.
6. Determining whether the endorectal or anal opening exists.
7. After visualization of the whole tract and electrocautery of the branches, monopolar type use for all sites carefully and step by step to avoid missing any lesion.
8. Mucosal sleeve closure of the rectal or anal opening of the fistula

### Statistical Analysis

For qualitative data, descriptive statistics were presented as absolute frequencies and percentages. To describe quantitative variables, mean and standard deviations (SDs) or median and range (depending on variability) were employed.

**Table 1** VAAFT versus fistulotomy complications, advantages, and disadvantages

Postoperative complication		
	VAAFT	Fistulotomy
Number of patients	100	100
Surgical site infection	0%	3%
Incontinence	0%	5%
Recurrence	0%	12%
Bleeding	0%	4%
Pain	Pain score 2	Pain score 5
Time of operation	30–45 minute	20–30 minute
Anal stenosis	0%	1%
Days of hospitalization	1 day	1–2 days
Wound healing	1 week	4–8 weeks
Return to work	1 week	4 weeks
Cost	High	Low
Patient satisfaction	More	Less

**Table 2** Correlation between VAAFT and fistulotomy

VAAFT versus Fistulotomy	Mean difference	p-value	t-test
	-2.181	0.02	- 2.096

## Results

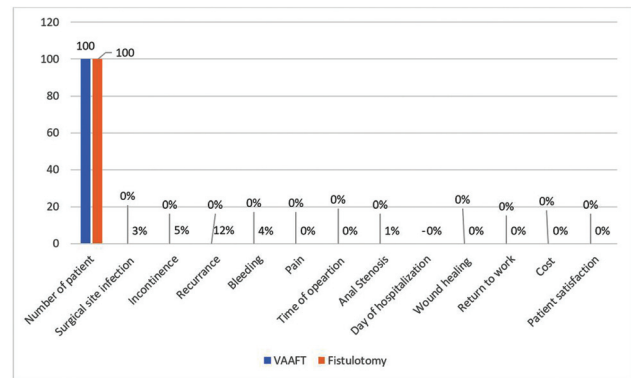
Video-assisted anal fistula treatment versus fistulotomy complications, advantages, and disadvantages are shown in ►Table 1 and ►Fig. 1. The correlation between VAAFT and fistulotomy was shown in ►Table 2.

## Discussion

For each type of fistula, there is a specific type of surgical procedure according to park classification fistula can be divided into low or high type in relation to site of internal opening above or below dentate line.<sup>19</sup> Also in relation of fistula tract to anal sphincter muscles, it can be divided into four types, intersphincteric, transsphinctric, superasphinctric and extra sphinctric.

Numerous surgical techniques, from simple tract opening to colostomy, are recommended for fistula in ano. The most extensively used techniques for treating fistula in ano with minor or no involvement of the anal muscles are fistulectomy and fistulotomy. The majority of recurrences, which have a recurrence rate of ~ 6.5%, are brought on by misidentifying the internal orifice after surgery. Missing the treatment of the secondary branches or the rapid closure of the surgical site could be to blame for the remainder.<sup>20</sup>

Due to the significant risk of surgical complications, including incontinence, treating complex fistulas is particularly time consuming. Recently, fistulotomy has been promoted as a golden option for treatment of high fistulas, with

**Fig. 1** Comparison between VAAFT and fistulotomy.

a variable success rate and satisfactory objective anal parameters.<sup>21</sup> The aim of surgical treatment is first to identify the internal opening, which is a very important step, and second to treat the fistula tract and try to avoid damage to the anal sphincter and maintain the continence mechanism intact.

Although many attempts have been made over the decades to treat complex anal fistulas, it continues to be one of the most challenging clinical problems in anorectal surgery.<sup>4,9</sup> Traditional surgical treatments, such as the lay-open procedure and fistulotomy, are effective in the treatment of simple and most distal fistulas, with an almost 100% success rate.<sup>9</sup> However, when they are used to manage complex anal fistulas, the high risks of recurrence and damage to anal sphincter function remain serious problems.<sup>3</sup> In our study, we used this procedure for high anal fistulas but there were postoperative complications such as recurrence and incontinence and it found similar to other study. Cutting setons were once the primary treatment for complex anal fistula. This technique could preserve anal sphincter function to some extent. However, many studies indicated that the fecal incontinence rates remained high, ranging from 20.5 to 67%.<sup>10</sup> Draining setons can minimize damage to anal sphincter function, but the fistula recurrence rates vary from 19.5 to 47.0%.<sup>22,23</sup>

The literature describes the role of fibrin injection in treating fistula. The noninvasiveness, simplicity, and reproducibility of this technique are encouraging qualities. Since there is no damage to anal muscles and no risk of incontinence, the percentages of long-term success range from 14 to 69%.<sup>8,19,24</sup>

A straightforward operation that does not affect the external sphincter is an anal fistula plug. As a result, it has emerged as a viable and economical method for treating complex fistulas that have a high risk of recurrence and incontinence. It entails using a biological fistula plug to plug the internal opening. The literature reports success rates that range from 34 to 77%.<sup>25,26</sup>

By preventing sphincteric damage, this technique aims to retain the continence mechanism. It is a difficult surgery with florid recurrence rates that, according to various research, vary from 6 to 41%.<sup>27,28</sup>

In some investigations, the patients with Crohn disease consider risk factor for poor outcome,<sup>28</sup> whereas in other

studies, the only meaningful outcome predictor was a history of fistula repair attempts.<sup>27</sup> When local structures are mobilized using these procedures, local tissue ischemia occurs, and flaps have a propensity to retract or dehisce. According to these procedures, the percentage of postoperative anal incontinence ranges from 9 to 38%.<sup>27</sup>

Ligation of the intersphincteric fistula tract is a new surgical technique. It includes suture closure of the external orifice, curettage of the tract, make opening wound in intersphincteric space .the fistula tract identify located divided a ligated. The treatment efficiently preserves continence, making it particularly helpful for high and complex fistulas. The success rate ranges from 57 to 94.5% according to several research. No fecal incontinence-related morbidity was reported.<sup>29,30</sup>

Athanasiadis et al. used a different procedure by performing closure of the internal opening by three layers involving mucosa, sub mucosa and muscles with fulguration of the whole tract.<sup>31</sup>

The risk of suture line dehiscence, which might result in the fistula persisting or recurring, is the main disadvantage of the surgery. Nearly 22.5% of the cases had it reported. The success rate for this surgery was 59% according to another study.<sup>32</sup>

Fistula tract laser closure is a different method that has lately gained support. It starts with emptying the abscess and inserting the seton. The internal aperture is then sealed with a flap, or by simple double layer closure, and the fistulous tract are fulgurated using 360 or radial emitting laser probe (FiLaC, Biolitec, and Jena, Germany). The authors reported an 81.8% success rate.<sup>33</sup>

The treatment of complex fistulas by using stem cell taken from fatty tissue of the patient together with fibrin glue procedure had a reported success rate of 71%.<sup>34</sup> The benefits of the procedure are that it does not necessitate resecting the fistulous tract and that the sphincteric mechanism is not harmed. The high cost and technically challenging nature of the procedure, which requires sealing off the internal entrance and obliterating the tract with the cell solution, are its drawbacks. Visualizing the fistulous tract and its interior opening is the core of VAAFT. It enables accurate fistuloscopy-based identification of the anatomy, real-time viewing of the tract, and fulguration of the tract under direct vision. Additionally, the branching tracts and abscess cavities that prevent the effective treatment of fistula in ano can be recognized and addressed. Additionally, the interior incision can be effectively closed by stapling or suturing. Fistuloscopy is used in conjunction with an internal opening closure technique, such as suturing or stapling, to treat complex anal fistulas while protecting the anal sphincters. Meinerer et al. reported a recurrence rate of ~ 26.5%. The recurrent instances were either treated with further VAAFT or cyanoacrylate glue injection.<sup>13</sup>

Despite the 26.5% recurrence rate in the trial by Meinerer et al., we performed our research using VAAFT due to the low morbidity of the procedure. A high degree of patient satisfaction resulted from the low discharge and pain at the surgery site, the absence of a raw region, and the early return

to work of the patient. The fundamental benefit of VAAFT is that there is little morbidity involved. Although it is linked to recurrence, its low morbidity should make it more acceptable to patients as a therapy option.

In our study, the patients who were treated with VAAFT revealed no occurrence of the following postoperative complications: infection, incontinence, recurrence, anal stenosis, and bleeding. There was a lower incidence of pain, short time for wound healing, rapid return to work and more patient satisfaction compared with open fistulotomy, which is compatible with results of previous research.<sup>13,35,36</sup>

## Conclusion

An innovative method for managing ano fistula is VAAFT. Compared with traditional methods, it has a lot of benefits. It is performed as one day surgery, with no open wound. No postoperative anal muscles damage and no risk of incontinence, it is less invasive, it is more affordable, and it allows for visualization of the internal opening and of the whole tract and its associated branches and cavity and can manage it accordingly. Its healing rate is better than those of traditional methods and patients can return to work within a short period. The instrument can be used repeatedly after good disinfection and sterilization. This method is low-cost because the patient can discharge from hospital the same day of surgery and resume his work and life early.

### Funding

None.

### Conflict of Interests

The authors have no conflict of interests to declare.

## References

- Whiteford MH, Kilkenny J, Hyman N, et al. Practice parameters for the treatment of perianal abscess and fistula-in-ano (revised). Springer 2005;48(07):1337–1342
- Garg P, Song J, Bhatia A, Kalia H, Menon GR. The efficacy of anal fistula plug in fistula-in-ano: a systematic review. *Colorectal Dis* 2010;12(10):965–970
- Limura E. WJG PGWJ of G, 2015 undefined. Modern management of anal fistula. ncbi.nlm.nih.gov [Internet]. [cited 2022 Jul 7]; Available from: <https://www.ncbi.nlm.nih.gov/pmc/articles/PMC4284327/>
- Bubbers EJ, Cologne KG. Management of Complex Anal Fistulas. *Clin Colon Rectal Surg* 2016;29(01):43–49
- Alasari S, Kim NK. Overview of anal fistula and systematic review of ligation of the intersphincteric fistula tract (LIFT). *Tech Proctol* 2014;18(01):13–22
- Schouten WR, Zimmerman DD, Briel JW. Transanal advancement flap repair of transsphincteric fistulas. *Dis Colon Rectum* 1999;42(11):1419–1422, discussion 1422–1423
- Ommer A, Herold A, Joos A, et al. CSGM, 2012 undefined. Gore BioA Fistula Plug in the treatment of high anal fistulas—initial results from a German multicenter-study. ncbi.nlm.nih.gov [Internet]. [cited 2022 Jul 7]; Available from: <https://www.ncbi.nlm.nih.gov/pmc/articles/PMC3440842/>
- Buchanan GN, Bartram CI, Phillips RKS, et al. Efficacy of fibrin sealant in the management of complex anal fistula: a prospective trial. *Dis Colon Rectum* 2003;46(09):1167–1174

- 9 Westerterp M, Volkers NA, Poolman RW, van Tets WF. Anal fistulotomy between Skylla and Charybdis. *Colorectal Dis* 2003; 5(06):549–551
- 10 Ritchie RD, Sackier JM, Hodde JP. Incontinence rates after cutting seton treatment for anal fistula. *Colorectal Dis* 2009;11(06): 564–571
- 11 Kochhar G, Saha S, Andley M, et al. AKJ of the, 2014 undefined. Video-assisted anal fistula treatment. ncbi.nlm.nih.gov [Internet]. [cited 2022 Jul 7]; Available from: <https://www.ncbi.nlm.nih.gov/pmc/articles/PMC4236078/>
- 12 A new technique for sphincter-preserving anal fistula repair using a novel radial emitting laser probe. Springer 2011;15(04): 445–449
- 13 Meinero P, Mori L. Video-assisted anal fistula treatment (VAAFT): a novel sphincter-saving procedure for treating complex anal fistulas. *Tech Coloproctol* 2011;15(04):417–422
- 14 Seow-En I, Seow-Choen F, Koh PK. An experience with video-assisted anal fistula treatment (VAAFT) with new insights into the treatment of anal fistulae. *Tech Coloproctol* 2016;20(06): 389–393
- 15 Chowbey PK, Khullar R, Sharma A, Soni V, Najma K, Baijal M. Minimally Invasive Anal Fistula Treatment (MAFT)-An Appraisal of Early Results in 416 Patients. *Indian J Surg* 2015;77 (Suppl 2):716–721
- 16 Mendes C et al. LF... B de C, 2014 undefined. Video-assisted anal fistula treatment: technical considerations and preliminary results of the first Brazilian experience. *SciELO Brasil* [Internet]. [cited 2022 Jul 7]; Available from: <https://www.scielo.br/jj/abcd/a/F433tcxNYNNVfYpbt8GwcYG/abstract/?lang=en>
- 17 Meinero P, Mori L rectum GGD of the colon &, 2014 undefined. Video-assisted anal fistula treatment: a new concept of treating anal fistulas. *journals.lww.com* [Internet]. [cited 2022 Jul 7]; Available from: [https://journals.lww.com/dcrjournal/Fulltext/2014/03000/Video\\_Assisted\\_Anal\\_Fistula\\_Treatment\\_\\_A\\_New.12.aspx](https://journals.lww.com/dcrjournal/Fulltext/2014/03000/Video_Assisted_Anal_Fistula_Treatment__A_New.12.aspx)
- 18 Wałęga P, Romaniszyn M chirurgiczny WNP przegląd, 2014 undefined. VAAFT: a new minimally invasive method in the diagnostics and treatment of anal fistulas-initial results. *europemc.org* [Internet]. [cited 2022 Jul 7]; Available from: <https://europemc.org/article/med/24578448>
- 19 Mishra A, Shah S, Nar A and ABj of C, 2013 undefined. The role of fibrin glue in the treatment of high and low fistulas in ano. ncbi.nlm.nih.gov [Internet]. [cited 2022 Aug 5]; Available from: <https://www.ncbi.nlm.nih.gov/pmc/articles/PMC3681059/>
- 20 Sangwan YP, Rosen L, Riether RD, Stasik JJ, Sheets JA, Khubchandani IT. Is simple fistula-in-ano simple? *Dis Colon Rectum* 1994; 37(09):885–889
- 21 Atkin GK, Martins J, Tozer P, Ranchod P, Phillips RKS. For many high anal fistulas, lay open is still a good option. *Tech Coloproctol* 2011;15(02):143–150
- 22 Eitan A, Koliada M, Bickel A. The use of the loose seton technique as a definitive treatment for recurrent and persistent high trans-sphincteric anal fistulas: a long-term outcome. *J Gastrointest Surg* 2009;13(06):1116–1119
- 23 Galis-Rozen. Longterm outcome of loose-seton for... - Google Scholar [Internet]. [cited 2022 Jul 7]. Available from: [https://scholar.google.com/scholar\\_lookup?journal=Colorectal+Dis&title=Long-term+outcome+of+loose+seton+for+complex+anal+fistula:+A+two-centre+study+of+patients+with+and+without+Crohn%E2%80%99s+disease&author=E+Galis-Rozen&author=H+Tulchinsky&author=A+Rosen&volume=12&publication\\_year=2010&pages=358-62&pmid=19220385&](https://scholar.google.com/scholar_lookup?journal=Colorectal+Dis&title=Long-term+outcome+of+loose+seton+for+complex+anal+fistula:+A+two-centre+study+of+patients+with+and+without+Crohn%E2%80%99s+disease&author=E+Galis-Rozen&author=H+Tulchinsky&author=A+Rosen&volume=12&publication_year=2010&pages=358-62&pmid=19220385&)
- 24 Sentovich SM. Fibrin glue for anal fistulas: long-term results. *Dis Colon Rectum* 2003;46(04):498–502
- 25 Johnson EK, Gaw JU, Armstrong DN. Efficacy of anal fistula plug vs. fibrin glue in closure of anorectal fistulas. *Dis Colon Rectum* 2006; 49(03):371–376
- 26 Adamina M, Hoch J, Surgery MB 2010 undefined. To plug or not to plug: a cost-effectiveness analysis for complex anal fistula. Elsevier [Internet]. [cited 2022 Aug 5]; Available from: [https://www.sciencedirect.com/science/article/pii/S0039606009003638?casa\\_token=zASaTsvKW1QAAAAA:ZQHthKlkokIT53pkhkXpHNt1dSrPQGTbNzMBZyDBIROcfmqTw042AlgEv8iXDTJRdERbTFZJEX](https://www.sciencedirect.com/science/article/pii/S0039606009003638?casa_token=zASaTsvKW1QAAAAA:ZQHthKlkokIT53pkhkXpHNt1dSrPQGTbNzMBZyDBIROcfmqTw042AlgEv8iXDTJRdERbTFZJEX)
- 27 Mizrahi N, Wexner SD, Zmora O, et al. Endorectal advancement flap: are there predictors of failure? *Dis Colon Rectum* 2002;45 (12):1616–1621
- 28 Sonoda T, Hull T, Piedmonte MR, Fazio VW. Outcomes of primary repair of anorectal and rectovaginal fistulas using the endorectal advancement flap. *Dis Colon Rectum* 2002;45(12):1622–1628
- 29 Shanwani A, Nor A rectum NAD of the colon &, 2010 undefined. Ligation of the intersphincteric fistula tract (LIFT): a sphincter-saving technique for fistula-in-ano. *journals.lww.com* [Internet]. [cited 2022 Aug 5]; Available from: [https://journals.lww.com/dcrjournal/fulltext/2010/01000/Ligation\\_of\\_the\\_Intersphincteric\\_Fistula\\_Tract.8.aspx?casa\\_token=eeF40i6QrScAAAAA:zCmeUQGweewH-\\_3UAd5hniu-PpoAj1Xr7x64WHDIR8lj\\_m1kk1E9z-vefGw0ytPRFqGUhryQfcdQO7eSkjxwCl4FSUcgz4Vs](https://journals.lww.com/dcrjournal/fulltext/2010/01000/Ligation_of_the_Intersphincteric_Fistula_Tract.8.aspx?casa_token=eeF40i6QrScAAAAA:zCmeUQGweewH-_3UAd5hniu-PpoAj1Xr7x64WHDIR8lj_m1kk1E9z-vefGw0ytPRFqGUhryQfcdQO7eSkjxwCl4FSUcgz4Vs)
- 30 Rojanasakul A et al. JPJM, 2007 undefined. Total anal sphincter saving technique for fistula-in-ano; the ligation of intersphincteric fistula tract. *researchgate.net* [Internet]. 2007 [cited 2022 Aug 5]; Available from: [https://www.researchgate.net/profile/Chucheeep-Sahakitrungruang/publication/6399991\\_Total\\_anal\\_sphincter\\_saving\\_technique\\_for\\_fistulain-ano\\_the\\_ligation\\_of\\_intersphincteric\\_fistula\\_tract/links/5e1587624585159aa4bcf963/Total-anal-sphincter-saving-technique-for-fistulain-ano-the-ligation-of-intersphincteric-fistula-tract.pdf](https://www.researchgate.net/profile/Chucheeep-Sahakitrungruang/publication/6399991_Total_anal_sphincter_saving_technique_for_fistulain-ano_the_ligation_of_intersphincteric_fistula_tract/links/5e1587624585159aa4bcf963/Total-anal-sphincter-saving-technique-for-fistulain-ano-the-ligation-of-intersphincteric-fistula-tract.pdf)
- 31 Athanasiadis S, Helmes C, Yazigi R, Köhler A. The direct closure of the internal fistula opening without advancement flap for transsphincteric fistulas-in-ano. *Dis Colon Rectum* 2004;47(07):1174–1180
- 32 Thomson WHF, Fowler AL. Direct appositional (no flap) closure of deep anal fistula. *Colorectal Dis* 2004;6(01):32–36
- 33 Wilhelm A. A new technique for sphincter-preserving anal fistula repair using a novel radial emitting laser probe. *Tech Coloproctol* 2011;15(04):445–449. <https://pubmed.ncbi.nlm.nih.gov/21845480/>
- 34 Garcia-Olmo D, Herreros D, et al. IPD of the colon, 2009 undefined. Expanded adipose-derived stem cells for the treatment of complex perianal fistula: a phase II clinical trial. *journals.lww.com* [Internet]. [cited 2022 Aug 5]; Available from: [https://journals.lww.com/dcrjournal/fulltext/2009/01000/expanded\\_adipose\\_derived\\_stem\\_cells\\_for\\_the.13.aspx?casa\\_token=jvld\\_b8IY-wAAAAA:xTIONQf2VWLzzDby0gt-H61WJbftgOxxz1fZ5kMZqd-S6UrkPWNWckabY-wwT-z\\_BVvfGKeGeZFmej0rgM08dFS\\_0zEaSehw](https://journals.lww.com/dcrjournal/fulltext/2009/01000/expanded_adipose_derived_stem_cells_for_the.13.aspx?casa_token=jvld_b8IY-wAAAAA:xTIONQf2VWLzzDby0gt-H61WJbftgOxxz1fZ5kMZqd-S6UrkPWNWckabY-wwT-z_BVvfGKeGeZFmej0rgM08dFS_0zEaSehw)
- 35 Meinero P, Mori L, Gasloli G. Video-assisted anal fistula treatment: a new concept of treating anal fistulas. *Dis Colon Rectum* 2014;57(03):354–359. <https://pubmed.ncbi.nlm.nih.gov/24509459/>
- 36 Jiang HH, Liu HL, Li Z, et al. Video-Assisted Anal Fistula Treatment (VAAFT) for Complex Anal Fistula: A Preliminary Evaluation in China. *Med Sci Monit* 2017;23:2065–2071