



Evaluation of The Three-Dimensional Endoscopy in Basic and Extended Nasal Procedures: A Clinical and Cadaveric Study

Amr Kholief^{1,2} Ahmed Ali¹ Samy Elwany¹ Shahzada Ahmed² Ahmed Youssef^{1,2}
Mohamed Zahran¹

¹Department of Otolaryngology-Head and Neck Surgery, Alexandria University Hospital, Alexandria, Egypt

²Ear, Nose, and Throat Department, University Hospitals Birmingham NHS Foundation, Birmingham, United Kingdom

Address for correspondence Mohamed Zahran, MD, PhD, FACS, Department of Otolaryngology, Alexandria Faculty of Medicine, Champillion Street, El-Azareeta, Alexandria, Egypt (e-mail: abdelnaby00@hotmail.com).

Int Arch Otorhinolaryngol 2023;27(4):e620–e624.

Abstract

Introduction The three-dimensional (3D) endoscope is considered a new surgical tool used in different approaches in intranasal and anterior skull base surgical procedures. There are many advantages of 3D over two-dimensional (2D) endoscopy that have been demonstrated in clinical applications, surgical training, and different experimental studies.

Objective To show the difference between using the 3D and 2D endoscopes during endonasal and anterior skull base surgery and its importance.

Methods Our study is divided into two phases (clinical and cadaveric phases). In the clinical study we, have performed 52 endonasal and anterior skull base surgical procedures (26 study cases and 26 control cases). We recorded accuracy, duration, and intraoperative complication for each case. The cadaveric study was performed on three cadavers. Differences in accuracy and dissection time were recorded using 3D and 2D endoscopy for each side chosen by randomization.

Results In the clinical study, the cases done by 3D endoscope were significantly faster and more accurate with less intraoperative complications compared with cases done using 2D endoscope. In cadaveric dissection, while using 3D endoscope, there was better depth of perception regarding the anatomical landmarks compared with 2D endoscope.

Conclusion Three-dimensional endoscopy is an advanced instrument that allows better training for the coming generation of ear, nose, and throat surgeons. Both clinical and cadaveric studies offer a promising outcome in both endonasal and anterior skull base surgery.

Keywords

- ▶ three-dimensional endoscopy
- ▶ skull base surgery
- ▶ endoscopic sinus surgery

Introduction

Despite advancements in new equipment and surgical instruments, it is only recently that three-dimensional (3D) endoscopes have been used in endonasal and anterior skull base

surgery. Previous publications have shown the importance, advantages and limitations of 3D endoscopy either in endonasal or skull base surgical approaches.^{1,2} The endoscopes used in the present study incorporate dual ‘chip-on-the-tip’ technology in which two video chips create two different

received
September 10, 2022

accepted
October 11, 2022
article published online
September 14, 2023

DOI <https://doi.org/10.1055/s-0042-1759604>.
ISSN 1809-9777.

© 2023. Fundação Otorrinolaringologia. All rights reserved.
This is an open access article published by Thieme under the terms of the Creative Commons Attribution-NonDerivative-NonCommercial-License, permitting copying and reproduction so long as the original work is given appropriate credit. Contents may not be used for commercial purposes, or adapted, remixed, transformed or built upon. (<https://creativecommons.org/licenses/by-nc-nd/4.0/>)
Thieme Revinter Publicações Ltda., Rua do Matoso 170, Rio de Janeiro, RJ, CEP 20270-135, Brazil

digital images which are displayed onto a 3D screen. Polarizing glasses are worn to project a different image to each eye.³

Extended endoscopic endonasal approaches are increasingly applied in the management of various intracranial and cranial base pathologies. On one end of the complexity spectrum, lie lesions such as pituitary adenomas and encephaloceles of the cribriform plate, which can be more easily approached through the endonasal corridor.⁴⁻⁶

There are many advantages of the endoscope; however, it does not achieve binocular vision. Monocular endoscopes create a 2D image during the operative view which lack the depth of perception, size orientation, and hand-to-eye coordination.^{7,8} Human kinematic studies proved that longer movement times are required by monocular cues to estimate the distance between variable surgical landmarks.⁹

Many binocular cues are essential to gain the depth of perception like convergence, stereopsis, and vertical disparities which are the main features of the 3D technology. To achieve stereopsis, two meticulously different retinal images obtained from different angles and directions are required, and then the human cortex superimposes these two images to give stereopsis. Like the majority of stereoscopic systems that provide a 3D display of the surgical field by production of minimally different images, then displayed separately to each eye, so the two generated images are the concept of stereopsis which named the dual channel and the shutter mechanism technologies.⁷

Patients and Methods

The present study has been performed in two phases: clinical and cadaveric parts.

Clinical Study

The clinical study was performed on patients admitted to the University Hospital during 1 calendar year. All patients gave informed consent after the nature of the research had been fully explained to them and the research was approved by the Institutional Review Board of the faculty according to the Helsinki declaration (ethical research number 0201021). We used the Karl Storz second generation 3D HD endoscope (Karl Storz GmbH & Co., Tuttlingen, Germany) that utilizes the 'dual chip-on-the-tip' technology with two lenses on the tip of the endoscope, Medtronic navigation system (Medtronic PLC, Minnesota, USA, Model: Stealth Station™) and Panasonic 3D polarizing glasses (Panasonic, Osaka, Japan. Model: TY-EP3D20) that filter less light than conventional polarizing glasses, so the operating room was not required to be dark. The 3D polarizing glasses fit over normal glasses worn by surgeons. This phase was performed on 52 endonasal and anterior skull base cases (26 control cases using 2D endoscope and 26 study cases using 3D endoscope (► Fig. 1). Duration of surgery, accuracy (frequency of navigation system use), intraoperative complications, and surgeon discomfort were recorded.

Cadaveric Dissection Study

This study was performed on three fresh frozen cadavers (six sides in total) using Karl Storz 2nd generation 3D HD endoscope

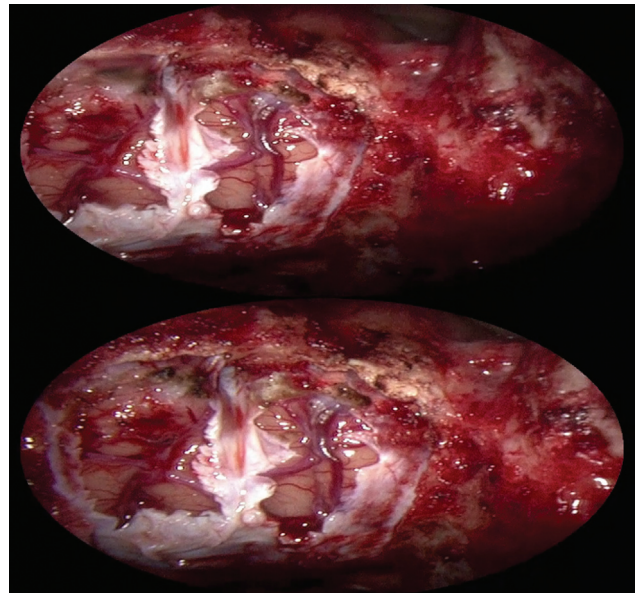


Fig. 1 3D intra-operative view after resection of anterior skull base tumor (double images created by the 3D endoscope).

(Karl Storz GmbH 81 Co., Tuttlingen, Germany) to dissect the different anatomical landmarks and regions in advanced endonasal and anterior skull base surgery. We used this endoscope for both 2D and 3D visualization using different settings on the endoscope, and this ensured minimal influence from optical variables that could arise from using two different endoscopes, making the intervention purely 3D and thus resulting in a more controlled design. Time was recorded in each side from first touching the vestibule of the nose until completing the sphenoidotomy and entering the sphenoid sinus cavity in the cadavers (uncinectomy, middle meatal antrostomy, ethmoidectomy, and sphenoidotomy were done on each side). Also, identification of various intranasal dissection sites and anatomical landmarks

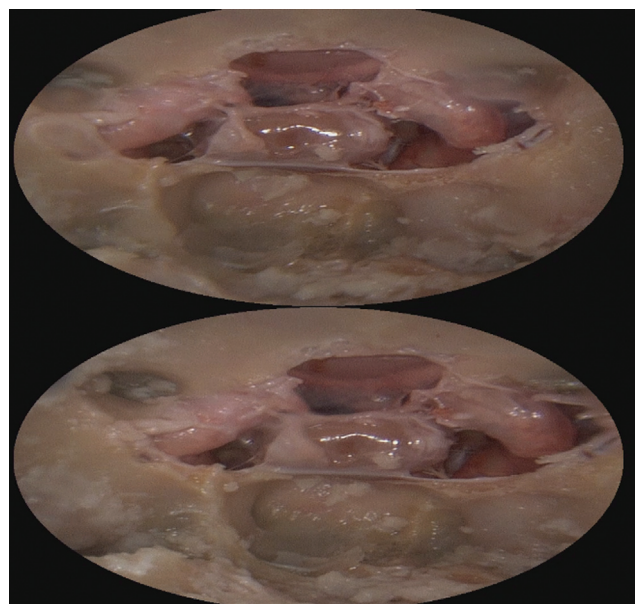


Fig. 2 3D cadaveric view inside the sphenoid sinus after removal of bone over the pituitary gland, the planum sphenoidale, and both carotid arteries.

Table 1 Comparison between the studied groups according to the pathology of operative cases

	2D endoscope (n = 26)		3D endoscope (n = 26)	
	n	%	n	%
Operative procedures				
Pituitary adenoma	12	46.2	12	46.2
Recurrent pituitary adenoma	6	23.1	6	23.1
Anterior skull base tumor	2	7.7	2	7.7
Unilateral vidian neurectomy	2	7.7	2	7.7
Draf II b	2	7.7	2	7.7
Draf III	2	7.7	2	7.7

were done for illustrative, educational, and training purposes (►Fig. 2).

Results

A range of operative procedures undertaken using 2D and 3D endoscope was performed. The majority of cases in 2 two groups were pituitary adenomas, (12 cases in each group 46.2%), followed by recurrent pituitary adenomas (6 cases in each group), as shown in ►Table 1.

In the clinical study, the operative time was recorded for each case starting from touching the skin of the patient until the end of each operative procedure. The mean operative time in the 2D group was 2.92 ± 1.51 hours, while in 3D it was 1.88 ± 0.65 hours. Comparing the two groups regarding the operative time, there was a highly significant increase in operative time in the 2D group compared with the 3D group ($p < 0.05$) as shown in ►Table 2.

Regarding the frequency of navigation system use intra-operatively, the mean frequency of using the navigation system in the 2D group was 5.0 ± 3.31 , while in the 3D group it was 2.50 ± 2.04 . Consequently, there was a highly significant increase in the number of navigation system utilizations in the 2D group compared with the 3D group ($p < 0.05$) as demonstrated in ►Table 3.

The incidence of intraoperative complications during use of the 2D endoscope was higher than intraoperative complications while using the 3D endoscope which was not statistically significant. The most common complications reported in the 2D group were cavernous bleeding in 11 cases (42.3%) followed by cerebrospinal fluid (CSF) leak in 6 patients (23.1%), while in

the 3D group there were 7 cases of CSF leak (26.9%) followed by cavernous bleeding in 5 patients (19.2%).

There was no reported discomfort to the surgeon while using the 2D endoscope; however, 3 surgeons reported headache/migraine while using the 3D endoscope. This was not statistically significant ($p > 0.05$).

In the cadaveric study, the mean time while using 2D endoscopy was 19.67 ± 1.53 minutes, while 3D endoscopy it was 21.33 ± 4.93 minutes. This did not reach statistical significance.

Discussion

Endoscopic sinus surgery (ESS) is considered the gold standard for the management of most sinus pathologies. Improvements and updates in image quality and angled scopes have resulted in advances in ESS with the expansion of use of the endoscopic approach in skull base surgical interventions.¹⁰

The three dimensional (3D) endoscopes have been utilized for endonasal surgery, and recent publications have shown the advantages and several limitations in using 3D endoscopes in endonasal sinus surgery or skull base surgical approaches.² In these reports, 3D images were reconstructed from multiple 2D images obtained using special lenses that imitate the compound eye of bees, from various angles.¹¹ This is a different technology to the 3D HD Storz endoscopes that were used in the present study.

In our clinical study, the mean operative time in the 2D group was significantly higher than in the 3D group. This is also shown by Castelnovo et al., who, while studying the utilization of the 3D endoscope in resection of anterior skull base malignancy, found a statistically significant reduction of

Table 2 Comparison between the studied groups according to operative time

	2D endoscope (n = 26)	3D endoscope (n = 26)	U	p-value
Operative time (hours)				
Minimum–maximum	0.75–7.43	0.50–2.95	145.50*	< 0.001*
Mean \pm SD	2.92 ± 1.51	1.88 ± 0.65		
Median (IQR)	2.49(2.35–2.92)	2.02(1.48–2.18)		

Abbreviations: IQR, interquartile range; SD, standard deviation.

U: Mann Whitney test.

*: Statistically significant at $p \leq 0.05$.

Table 3 Comparison between the studied groups according to the frequency of navigation system use

	2D endoscope (n = 26)	3D endoscope (n = 26)	U	p-value
Number of navigation system use				
Minimum–maximum	0.0–14.0	0.0–7.0	166.0*	0.001*
Mean ± SD	5.0 ± 3.31	2.50 ± 2.04		
Median (IQR)	5.0 (3.0–6.0)	3.0 (0.0–4.0)		

Abbreviations: IQR, interquartile range; SD, standard deviation.

U: Mann Whitney test.

*: Statistically significant at $p \leq 0.05$.

both operative time and error rates by using the new stereoscopic endoscope,¹² which requires the passive polarizing 3D display¹³ compared with the 2D endoscope. Also, they recorded low¹⁴ or absent surgeon discomforts with the novel stereoscopic systems.¹⁵ Moreover Barkhoudarian et al. reported that there is strong evidence for 3D allowing a 30-minute reduction in pituitary adenoma resection operating time.¹⁶ A shorter operative time decreases the risk of post-operative complications in endoscopic pituitary surgery.¹⁷

In our study, the frequency of using the surgical navigation system showed that there was a highly significant increase in the frequency of navigation system use in the 2D group more than in the 3D group. There are no similar studies in the literature to compare with our study, but these results are in line with the hypothesis that 3D endoscopy gives improved depth of perception, hence a reduction in the need of using the navigation to confirm anatomy.

In our 2D group, there was no surgeon discomfort during all operative cases, while 3 operative cases in the 3D group resulted in the surgeon reporting discomfort (-headache/migraine); there was no significant difference between the two studied groups. Other authors in clinical and experimental studies reported similar results. Moreover, a small number of surgeons in multiple studies recorded user side effects and discomforts like dizziness, eye strain, fatigue, migraine, and headaches in 3D endoscope users.¹⁸

Minimally invasive surgery is the standard of patient care in many institutions.¹⁹ However, incidents of increased complication rates among inexperienced surgeons have been reported and a detailed study of these claims demonstrates that the surgical learning curve plays a vital role in the rate of complications.²⁰

Regarding intraoperative complications, the incidence of complications in our 2D group was higher than in the 3D group; however, it was statistically not significant. The most common complications in our 2D group was cavernous bleeding in 11 cases (42.3%) followed by CSF leak in 6 patients (23.1%), while in the 3D group there were 7 cases of CSF leak (26.9%) followed by cavernous bleeding in 5 patients (19.2%).

For endoscopic pituitary surgery, the Southern Surgeons club noted that 90% of complications happened in the first 30 patients of the learning curve, with the initial risk being 10-fold of that after 50 operations.²¹ They were using 2D endoscopy and several explanations were given including: loss of depth perception (stereopsis), ergonomic difficulties of using an endoscope, and issues with training.²⁰

Regarding our cadaveric study, the mean dissection time for both sides of the cadavers using the 2D endoscope was 19.67 ± 1.53 minutes, while using the 3D endoscope it was 21.33 ± 4.93 minutes, which was not statistically significant ($p > 0.05$). It is possible that if we had chosen a more complicated index longer operation to compare then we might increase the likelihood of repeating the same results as seen in the clinical study with 2D taking longer than 3D.

The cadaveric study describes only a qualitative comparison of various approaches and anatomical landmarks using 3D endoscopy as a new learning tool and technique. Future studies should focus on more detailed quantitative comparisons of field exposure and surgical limitations.

Conclusions

Three-dimensional endoscopy is an advanced instrument that allows better training for the coming generation of ear, nose, and throat surgeons. Both clinical and cadaveric studies offer a promising outcome in both endonasal and anterior skull base surgery.

Summary

- Using the 3D endoscope in different surgical procedures in our study revealed a significantly faster than the 2D endoscope of the same operative cases.
- In the comparison between the 2D and 3D endoscope regarding intraoperative complications, there were less intraoperative complications while using the 3D endoscope than the 2D one, but it was statistically not significant.
- In our study, we used a new parameter to estimate the accuracy of both 3D and 2D endoscopes, which is the number of surgical navigation system use for each case to confirm the anatomy in different operative procedures, and there was a statistically significant reduction in the number of surgical navigation system use in the 3D group compared with the 2D group.
- In the present study, we noted a statistically nonsignificant increase in surgeon discomfort while using the 3D endoscope while no surgeon discomfort was reported while using the 2D endoscope in endonasal and anterior skull base operative procedures.

- Using the 3D endoscope in cadaveric dissection, there was improvement in depth of perception while demonstrating different anatomical landmarks compared with the 2D endoscope; this recent development holds much promise for different surgical subspecialties and training options, particularly endonasal and anterior skull base surgery.
- Regarding the dissection time of the cadavers, we recorded a nonsignificant increase in dissection time while using the 3D endoscope compared with the 2D endoscope. Due to the limited number of cadavers, further studies should focus on the quantitative comparison.

Funding

None.

Conflict of Interests

The authors have no conflict of interests to declare.

Contribution of the Authors

Kholief A.: Study design and conduction; collection, analysis, and interpretation of the data; writing and approval of the manuscript. Ali A.: Study design and conduction; analysis, and interpretation of the data; and approval of the manuscript. Elwany S.: Study design and conduction; analysis, and interpretation of the data; writing and approval of the manuscript. Ahmed S.: Study design and conduction; collection, analysis, and interpretation of the data; writing and approval of the manuscript. Youssef A.: Study design and conduction; analysis, and interpretation of the data; writing and approval of the manuscript. Zahran M.: analysis, and interpretation of the data; writing and approval of the manuscript.

References

- 1 Brown SM, Tabaee A, Singh A, Schwartz TH, Anand VK. Three-dimensional endoscopic sinus surgery: feasibility and technical aspects. *Otolaryngol Head Neck Surg* 2008;138(03):400–402
- 2 Shah RN, Leight WD, Patel MR, et al. A controlled laboratory and clinical evaluation of a three-dimensional endoscope for endonasal sinus and skull base surgery. *Am J Rhinol Allergy* 2011;25(03):141–144
- 3 Szold A. Seeing is believing: visualization systems in endoscopic surgery (video, HDTV, stereoscopy, and beyond). *Surg Endosc* 2005;19(05):730–733
- 4 Cappabianca P, Cavallo LM, Colao A, et al. Endoscopic endonasal transsphenoidal approach: outcome analysis of 100 consecutive procedures. *Minim Invasive Neurosurg* 2002;45(04):193–200
- 5 de Divitiis E, Cappabianca P, Gangemi M, Cavallo LM. The role of the endoscopic transsphenoidal approach in pediatric neurosurgery. *Childs Nerv Syst* 2000;16(10-11):692–696
- 6 Dehdashti AR, Ganna A, Karabatsou K, Gentili F. Pure endoscopic endonasal approach for pituitary adenomas: early surgical results in 200 patients and comparison with previous microsurgical series. *Neurosurgery* 2008;62(05):1006–1015, discussion 1015–1017
- 7 Hofmeister J, Frank TG, Cuschieri A, Wade NJ. Perceptual aspects of two-dimensional and stereoscopic display techniques in endoscopic surgery: review and current problems. *Semin Laparosc Surg* 2001;8(01):12–24
- 8 Taffinder N, Smith SG, Huber J, Russell RC, Darzi A. The effect of a second-generation 3D endoscope on the laparoscopic precision of novices and experienced surgeons. *Surg Endosc* 1999;13(11):1087–1092
- 9 Tabaee A, Anand VK, Fraser JF, Brown SM, Singh A, Schwartz TH. Three-dimensional endoscopic pituitary surgery. *Neurosurgery* 2009; 64(5, Suppl 2):288–293, discussion 294–295
- 10 Govindaraj S, Adappa ND, Kennedy DW. Endoscopic sinus surgery: evolution and technical innovations. *J Laryngol Otol* 2010; 124(03):242–250
- 11 Wasserzug O, Margalit N, Weizman N, Fliss DM, Gil Z. Utility of a three-dimensional endoscopic system in skull base surgery. *Skull Base* 2010;20(04):223–228
- 12 Castelnovo P, Battaglia P, Bignami M, et al. Endoscopic transnasal resection of anterior skull base malignancy with a novel 3D endoscope and neuronavigation. *Acta Otorhinolaryngol Ital* 2012;32(03):189–191
- 13 Committee ATASGE Technology Committee. High-definition and high-magnification endoscopes. *Gastrointest Endosc* 2014;80(06):919–927
- 14 Albrecht T, Baumann I, Plinkert PK, Simon C, Sertel S. Three-dimensional endoscopic visualization in functional endoscopic sinus surgery. *Eur Arch Otorhinolaryngol* 2016;273(11):3753–3758
- 15 Cappabianca P, Cavallo LM, Esposito F, De Divitiis O, Messina A, De Divitiis E. Extended endoscopic endonasal approach to the midline skull base: the evolving role of transsphenoidal surgery. *Adv Tech Stand Neurosurg* 2008;33:151–199
- 16 Barkhoudarian G, Del Carmen Becerra Romero A, Laws ER. Evaluation of the 3-dimensional endoscope in transsphenoidal surgery. *Neurosurgery* 2013 73(1, Suppl Operative):ons74–ons78, discussion ons78–ons79
- 17 Daley BJ, Cecil W, Clarke PC, Cofer JB, Guillaumondegui OD. How slow is too slow? Correlation of operative time to complications: an analysis from the Tennessee Surgical Quality Collaborative. *J Am Coll Surg* 2015;220(04):550–558
- 18 Botanov Y, Ilardi SS. The acute side effects of bright light therapy: a placebo-controlled investigation. *PLoS One* 2013;8(09):e75893
- 19 Gallagher AG, Smith CD. From the operating room of the present to the operating room of the future. Human-factors lessons learned from the minimally invasive surgery revolution. *Semin Laparosc Surg* 2003;10(03):127–139
- 20 Dunn D, Nair R, Fowler S, McCloy R. Laparoscopic cholecystectomy in England and Wales: results of an audit by the Royal College of Surgeons of England. *Ann R Coll Surg Engl* 1994;76(04):269–275
- 21 Lofrese G, Vigo V, Rigante M, et al. Learning curve of endoscopic pituitary surgery: Experience of a neurosurgery/ENT collaboration. *J Clin Neurosci* 2018;47:299–303