



Treatment and Outcome of Anterior Inferior Cerebellar Artery (AICA) Aneurysms: Helsinki Series of 15 Consecutive Patients

Sajjad Muhammad^{1,2} Ahmad Hafez² Hanna Kaukovalta² Behnam Rezai Jahromi² Riku Kivisaari²
Daniel Hänggi¹ Mika Niemelä²

¹Department of Neurosurgery, Medical Faculty, Heinrich Heine University, Düsseldorf, Germany

²Department of Neurosurgery, Helsinki University Hospital, University of Helsinki, Helsinki, Finland

Address for correspondence Sajjad Muhammad, MD, PhD, Department of Neurosurgery, Medical Faculty, Heinrich Heine University, Moorenstrasse 5, 40225, Düsseldorf, Germany (e-mail: sajjad.muhammad@med.uni-duesseldorf.de).

AJNS 2023;18:30–35.

Abstract

Objective Anterior inferior cerebellar artery (AICA) aneurysms are rare posterior circulation lesions that are challenging to treat. This article presents the treatment and clinical outcome of AICA aneurysms in an unselected cohort of patients.

Methods A retrospective analysis of patient record files, digital subtraction angiography, and computed tomography angiography images of 15 consecutive patients harboring AICA aneurysms treated between 1968 and 2017.

Results Of the 15 AICA aneurysm patients reviewed, 12 (80%) were females. Twenty percent had intracerebral hemorrhage and 40% presented with intraventricular hemorrhage. Eleven out of 15 (73%) patients presented with subarachnoid hemorrhage (SAH); 82% of SAH patients had a good-grade SAH (Hunt and Hess grade 1–3). Eleven patients (73%) were treated surgically, three (20%) were treated conservatively, and one (7%) had coil embolization. In 27% of patients, a subtemporal approach with anterior petrosectomy was performed. A retrosigmoid approach was used in the remaining 73%. In 18% of the patients, a parent vessel occlusion was necessary to occlude the aneurysm. Five out of 11 (47%) of the patients developed postoperative cranial nerve deficits. Twenty-seven percent developed shunt-dependent hydrocephalus. All patients who presented with an unruptured AICA aneurysm had good clinical outcome (modified Rankin scale [mRS] 1–2). In patients with SAH, 82% achieved good clinical outcome and 18% had poor clinical outcome (mRS 3–6) after 1 year.

Conclusion Surgical treatment of AICA aneurysms has a high rate of cranial nerve deficits but most of patients have a good long-term clinical outcome.

Keywords

- ▶ anterior inferior cerebellar artery (AICA) aneurysms
- ▶ DSA and CT angiography
- ▶ intracerebral hemorrhage
- ▶ intraventricular hemorrhage

article published online
March 10, 2023

DOI <https://doi.org/10.1055/s-0042-1758844>.
ISSN 2248-9614.

© 2023. Asian Congress of Neurological Surgeons. All rights reserved.

This is an open access article published by Thieme under the terms of the Creative Commons Attribution-NonDerivative-NonCommercial-License, permitting copying and reproduction so long as the original work is given appropriate credit. Contents may not be used for commercial purposes, or adapted, remixed, transformed or built upon. (<https://creativecommons.org/licenses/by-nc-nd/4.0/>)

Thieme Medical and Scientific Publishers Pvt. Ltd., A-12, 2nd Floor, Sector 2, Noida-201301 UP, India

Key Message

After surgical treatment of AICA aneurysms, most of the patients show good long-term clinical outcome. Surgical treatment may be an option only in selected cases of AICA aneurysms.

Introduction

Anterior inferior cerebellar artery (AICA) aneurysms are rare lesions and account for less than 1% of all intracranial aneurysms.^{1,2} Except a few larger case series,³ only case reports with a single or a few patients have been reported.^{1,4–63} Drake et al⁶⁴ reported a larger series of AICA aneurysms. However, they also included aneurysms originating from the basilar trunk near the origin of AICA. Both surgical and endovascular treatments of AICA aneurysms are challenging as these aneurysms are more often fusiform in morphology. Recent multicenter studies have shown that endovascular coiling has a better outcome than surgical clipping of posterior circulation aneurysms.⁶⁵ Although most of these trials included patients with posterior circulation aneurysms that harbored posterior inferior cerebellar artery or basilar bifurcation aneurysms, endovascular coiling has now been accepted as a favored treatment option for all posterior circulation aneurysms.⁶⁶ However, if parent vessel occlusion and a revascularization procedure is needed, surgery may still be a better choice in such selected cases due

to the often larger size and fusiform shape of AICA aneurysms.^{27,58} We report our series of patients harboring AICA aneurysms admitted during 1968 to 2017 to the Department of Neurosurgery at Helsinki University Hospital. We discuss treatment options (including the role of surgery) for AICA aneurysms. Moreover, we discuss different surgical approaches for clipping AICA aneurysms, postoperative complications, and clinical outcomes in Helsinki series of AICA aneurysms.

Subjects and Methods

Patients and Radiological Data

We retrospectively identified 21 patients with AICA aneurysms comprising 0.22% of the aneurysms admitted during the period. After exclusion of aneurysms with missing computed tomography (CT) angiography scans or digital subtraction angiography, 15 patients with AICA aneurysms were identified. Analysis of CT angiography images until 2007 was performed with a 4-slice scanner (GE LightSpeed QX/I; GE Medical Systems, Milwaukee, Wisconsin, United States) and later with a 32-slice scanner (GE LightSpeed Pro 32) or a 64-row scanner (GE LightSpeed VCT Advantage). Images were stored in the digital archiving system of the hospital (IMPAX, version 5.3, Agfa, Mortsel, Belgium). Analysis of CT angiography scans was performed by two board-certified neurosurgeons (►Fig. 1). The study was approved by the local ethical committee. An additional approval for the

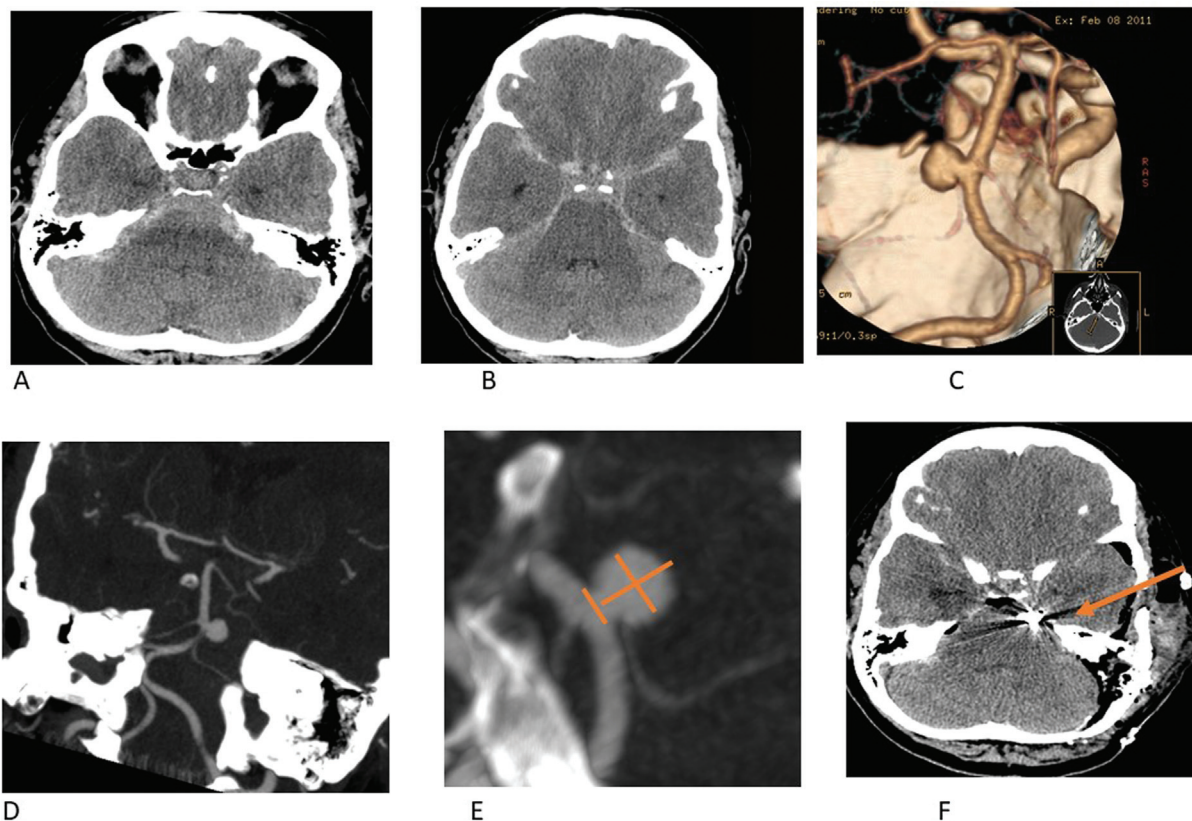


Fig. 1 Computer tomography showing subarachnoid hemorrhage (A, B) from an anterior inferior cerebellar artery (AICA) (proximal) aneurysm (C–E). Aneurysm clipping was performed through a subtemporal approach (F).

collection of retrospective data or additional patient consent was not required.

Clinical Outcome

For each patient we retrieved data on initial clinical grade on admission. Patients with Hunt and Hess grade 1 to 3 were classified as good clinical grade. Patients with subarachnoid hemorrhage (SAH) and patients with Hunt and Hess grade 4 to 5 were classified as poor grade SAH. Data on surgical approach and on postoperative cranial nerve deficits were retrieved from patient electronic record files. Clinical outcome was quantified using modified Rankin scale (mRS). Patients with mRS 1 to 2 were classified as good clinical outcome whereas patients with mRS 3 to 6 were classified as poor clinical outcome.

Statistical Analysis

Data were analyzed using the commercial statistical software IBM SPSS version 20.0.0. Data are presented in frequencies (percentage) or mean \pm standard deviation.

Results

Patients and Presentation

Of the 15 AICA aneurysm patients analyzed, 12 (80%) were females and the remaining 3 (20%) were males. Twenty percent had intracerebral hemorrhage and 40% presented with intraventricular hemorrhage (**► Table 1**). Eleven out of 15 (73%) patients presented with SAH and 82% of SAH patients had good-grade SAH (Hunt and Hess grade 1–3).

Treatment

Four patients presented with cranial nerve deficits without SAH. Eleven patients (73%) were treated surgically, three (20%) were treated conservatively, and one (7%) had coil embolization. In 27% of patients, a subtemporal approach with anterior petrosectomy was performed. In the remaining 73%, the aneurysms were approached through a retrosigmoid approach with or without modifications. In 18% of the patients, a parent vessel occlusion was necessary to occlude the aneurysm.

Clinical Outcome

Five out of 11 (47%) of patients who underwent surgery developed postoperative cranial nerve deficits including oculomotor and abducens ($n = 1$), abducens ($n = 2$), glossopharyngeus ($n = 1$), and facial nerve palsy with hearing loss ($n = 1$). Twenty-seven percent developed shunt-dependent hydrocephalus. All patients who presented with an unruptured AICA aneurysm had good clinical outcome (mRS 1–2). In patients with SAH, 82% achieved good clinical outcome (mRS 1–2) and 18% had poor clinical outcome (mRS 3–6) after 1 year (**► Table 2**).

Discussion

Due to their often-larger size and fusiform shape (in \sim 33% of cases), AICA aneurysms are a special group of posterior

Table 1 Clinical presentation of anterior inferior cerebellar artery aneurysms ($n = 15$)

	Mean	Percentage
Presentation		
Males	3	20
Females	12	80
Intracerebral hemorrhage (ICH)		
Intracerebral hemorrhage (ICH)	3	20
No ICH	12	80
Intraventricular hemorrhage (ICV)		
Intraventricular hemorrhage (ICV)	6	40
No ICV	9	60
Presentation ($n = 15$)		
Unruptured	4	26.7
Ruptured	11	63.3
Hunt and Hess grade ($n = 11$)		
Hunt and Hess grade (1–3)	9	81.8
Hunt and Hess grade (4–5)	2	18.2

circulation aneurysms that may more often require surgery compared with other posterior circulation aneurysms. Selection of surgical approach is an important factor because of critical location of the aneurysm near important cranial nerves. There are two key factors that determine the approach during microsurgical clipping of AICA aneurysms. These are the height of the aneurysm in relation to the clivus and the segmental location of the aneurysm along the artery. High-lying AICA aneurysms can be accessed through a subtemporal approach with an additional petrosectomy. The far-lateral approach is suitable for low-lying AICA aneurysms near the origin of the basilar artery. A retrosigmoid approach including its modifications is a simple and straightforward approach that can expose most parts of the AICA below the fifth cranial nerve and around the internal auditory meatus.⁶⁷ A lumbar drain is helpful to release cerebrospinal fluid and increase the surgical exposure while operating through a retrosigmoid approach. In our series, 3 out of 11 patients were operated through a subtemporal approach with anterior petrosectomy and the other 8 were operated through a retrosigmoid approach with some extension according to location of the aneurysm. It is important to take special care to avoid injuring the sixth cranial nerve during anterior petrosectomy. In the series of Drake, most of the patients were treated through a subtemporal approach with a very high rate of postoperative sixth nerve injury. In our series, 46% (33% already preoperatively) of the patients presented cranial nerve deficits, which is lower than that reported in the literature.³ The high rates of cranial nerve deficits are due not only to direct injury to the nerve but also vascular injury of the vasa nervorum, which can cause significant cranial nerve deficits.⁴⁰ Twenty-seven percent of patients developed shunt-dependent hydrocephalus, which is consistent with

Table 2 Postoperative complications and clinical outcome of anterior inferior cerebellar artery aneurysms ($n = 15$)

	Mean	Percentage
Presentation		
Treatment		
Conservative	3	20
Coiling	1	6.7
Clipping	11	73.3
Approach ($n = 11$)		
Subtemporal + anterior petrosectomy	3	27.3
Retrosigmoid (with its modifications)	8	72.7
Parent vessel occlusion ($n = 11$)	2	18.2
Postop cranial nerve deficits ($n = 11$)		
Yes	5	46.5
No	6	54.5
Hydrocephalus		
Shunt-dependent hydrocephalus	4	26.7
No hydrocephalus	11	73.3
Postop CSF leak	1	9.1
Clinical outcome unruptured ($n = 4$)		
mRS (1–2)	4	100
mRS (3–6)	0	0
Clinical outcome ruptured ($n = 11$)		
mRS (1–2)	9	81.8
mRS (3–6)	2	18.2

Abbreviations: CSF, cerebrospinal fluid; mRS, modified Rankin scale.

the literature. The overall clinical outcome in surgically treated patients is heavily dependent on the presentation status of the patient and the surgical skills of the neurosurgeon. In our series, all patients ($n = 4$) who presented with unruptured aneurysms achieved good clinical outcome (mRS 1–2). Patients who presented with good-grade SAH (Hunt and Hess grade 1–3; $n = 9$) achieved good clinical outcome (mRS 1–2). Two patients with poor-grade SAH achieved poor clinical outcome (mRS 3–6). One patient in our series was coil embolized and had an initial Hunt and Hess grade 2; this patient also achieved mRS 2 at 1 year after treatment. For the conservatively treated patients, one patient who had SAH in 2003 lived until 2012 and reached mRS 3 at 1 year after SAH. One patient who was admitted with poor-grade SAH died after 1 day of hospitalization. The third patient in the conservative group who was admitted with SAH in 1968 achieved mRS 1 at 1 year after SAH. This patient later died due to prostate carcinoma. The reason for the low rate of rebleeding may be the high rate of thrombosis of these aneurysms. Although our surgical results are comparable to endovascular coiling, multicenter controlled and randomized trials in recent years have demonstrated that endovascular coiling is a better treatment for posterior circulation

aneurysms. Thus, endovascular coiling has now become the standard first-choice treatment for all posterior circulation aneurysms (including AICA) in most neurosurgical centers worldwide.

Limitations

Our analysis is retrospective and may not completely reflect the natural disease course. Due to the low number of patients, we could not analyze the influence of surgical approach and segmental location of the aneurysm on clinical outcome.

Conclusion

Although surgical treatment of AICA aneurysms has a high rate of cranial nerve deficits, most patients achieve a good long-term clinical outcome. Surgical treatment may still be an option in selected cases of AICA aneurysms. Based on this series and previous policy of our hospital to ignore endovascular therapy, it maybe not possible to give a clear recommendation. This is biased toward surgery.

Conflict of Interest

None declared.

References

- Li X, Zhang D, Zhao J. Anterior inferior cerebellar artery aneurysms: six cases and a review of the literature. *Neurosurg Rev* 2012;35(01):111–119, discussion 119
- Sanai N, Tarapore P, Lee AC, Lawton MT. The current role of microsurgery for posterior circulation aneurysms: a selective approach in the endovascular era. *Neurosurgery* 2008;62(06):1236–1249, discussion 1249–1253
- Gonzalez LF, Alexander MJ, McDougall CG, Spetzler RF. Anterior-inferior cerebellar artery aneurysms: surgical approaches and outcomes—a review of 34 cases. *Neurosurgery* 2004;55(05):1025–1035
- Adorno JO, de Andrade GC. Aneurysm of the anterior inferior cerebellar artery: case report [in Portuguese]. *Arq Neuropsiquiatr* 2002;60(04):1019–1024
- Aguiar GB, Veiga JC, Jory M, Souza RB, Mattar Neto B, Conti ML. Fusiform aneurysm of the anterior inferior cerebellar artery and arteriovenous malformation fed by the same vessel [in Spanish]. *Medicina (B Aires)* 2012;72(03):245
- Akyüz M, Tuncer R. Multiple anterior inferior cerebellar artery aneurysms associated with an arteriovenous malformation: case report. *Surg Neurol* 2005;64(Suppl 2):S106–S108
- Andrade G, Faquini I, Azevedo-Filho H, et al. Dissecting anterior inferior cerebellar artery aneurysm treated by endovascular route: report of three cases and review. *Arq Neuropsiquiatr* 2010;68(04):645–647
- Baskaya MK, Coscarella E, Jea A, Morcos JJ. Aneurysm of the anterior inferior cerebellar artery-posterior inferior cerebellar artery variant: case report with anatomical description in the cadaver. *Neurosurgery* 2006;58(02):E388, discussion E388
- Cantore GP, Ciappetta P, Vagnozzi R, Bozzao L. Giant aneurysm of the anterior inferior cerebellar artery simulating a cerebellopontine angle tumor. *Surg Neurol* 1982;18(01):76–78
- DiMaio S, Mohr G, Dufour JJ, Albrecht S. Distal mycotic aneurysm of the AICA mimicking intracanalicular acoustic neuroma. *Le J Canad Sci Neurol* 2003;30:388–392

- 11 Ebara M, Tanaka T, Sawauchi S, Morooka S, Yuhki K, Abe T. A ruptured aneurysm of the anterior and posterior inferior cerebellar artery: a case report [in Japanese]. *No Shinkei Geka* 1999;27(11):1013–1017
- 12 Fukuya T, Kishikawa T, Ikeda J, et al. Aneurysms of the peripheral portion of the anterior inferior cerebellar artery; report of two cases. *Neuroradiology* 1987;29(05):493–496
- 13 Gleeson MJ, Cox TC, Strong AJ. Aneurysm of the anterior inferior cerebellar artery mimicking an intracanalicular acoustic neuroma. *J Laryngol Otol* 1989;103(01):107–110
- 14 Gopalakrishnan CV, Menon G, Nair S. Aneurysm of the anterior inferior cerebellar artery-posterior inferior cerebellar artery variant: two case reports and review of literature. *Br J Neurosurg* 2009;23(05):554–556
- 15 Goto S, Ohshima T, Yamamoto T, et al. A case of ruptured intrameatal aneurysm successfully treated with coil embolization. *Nagoya J Med Sci* 2015;77(1-2):307–313
- 16 Honda Y, Tanaka R, Kameyama S. Ruptured distal anterior inferior cerebellar artery aneurysm—case report. *Neurol Med Chir (Tokyo)* 1994;34(11):763–767
- 17 Ishii D, Takechi A, Shinagawa K, Sogabe T. Endovascular treatment for ruptured distal anterior inferior cerebellar artery aneurysm—case report—. *Neurol Med Chir (Tokyo)* 2010;50(05):396–399
- 18 Ito J, Takeda N, Suzuki Y, Takeuchi S, Osugi S, Yoshida Y. The anterior inferior cerebellar arteries originating from the internal carotid artery (author's transl) [in Japanese]. *No To Shinkei* 1979;31(10):999–104
- 19 Jinbo Y, Zheng Z, Jiaquan H, Hui Y, Jun L. Embolization of a ruptured aneurysm of the distal anterior inferior cerebellar artery with parent artery preservation. *Neurol India* 2010;58(05):786–788
- 20 Johnson JH Jr, Kline DG. Anterior inferior cerebellar artery aneurysms. Case report. *J Neurosurg* 1978;48(03):455–460
- 21 Kanamori F, Kawabata T, Muraoka S, et al. Ruptured partially thrombosed anterior inferior cerebellar artery aneurysms: two case reports and review of literature. *Nagoya J Med Sci* 2016;78(04):517–522
- 22 Kang HS, Roh HG, Han MH, Koh YC. Successful endovascular occlusion of a ruptured distal anterior inferior cerebellar artery aneurysm of the caudal trunk: case report. *Interv Neuroradiol* 2007;13(03):271–276
- 23 Kiya K, Uozumi T, Emoto K, Matsuoka T. Anterior inferior cerebellar artery aneurysm at the internal auditory meatus—case report. *Neurol Med Chir (Tokyo)* 1989;29(07):592–595
- 24 Kiya K, Uozumi T, Emoto K, Matsuoka T. Aneurysm of the anterior inferior cerebellar artery at the internal auditory meatus: case report and review of the literature. *Hiroshima J Med Sci* 1989;38(01):39–44
- 25 Koizumi H, Kurata A, Suzuki S, Miyasaka Y, Tanaka C, Fujii K. Endosaccular embolization for a ruptured distal anterior inferior cerebellar artery aneurysm. *Radiol Case Rep* 2015;7(02):651
- 26 Kyoshima K, Matsuda M, Handa J. Cerebral aneurysm of the distal anterior inferior cerebellar artery: case report. *Nihon Geka Hokan* 1995;64(06):139–145
- 27 Lee BS, Witek AM, Moore NZ, Bain MD. Treatment of an anterior inferior cerebellar artery aneurysm with microsurgical trapping and in situ posterior inferior cerebellar artery to anterior inferior cerebellar artery bypass: case report. *Oper Neurosurg (Hagerstown)* 2018;15(04):418–424
- 28 Lee SJ, Koh JS, Ryu CW, Lee SH. Ruptured intrameatal aneurysm of the anterior inferior cerebellar artery accompanying an arteriovenous malformation: a case report. *Cerebellum* 2012;11(03):808–812
- 29 Lv X, Li Y, Liu A, Zhang J, Wu Z. Parent artery occlusion for peripheral anterior inferior cerebellar artery aneurysm. A case report and review of the literature. *Neuroradiol J* 2008;21(02):261–265
- 30 Mahmoud M, El Serwi A, Alaa Habib M, Abou Gamrah S. Endovascular treatment of AICA flow dependent aneurysms. A report of three cases and review of the literature. *Interv Neuroradiol* 2012;18(04):449–457
- 31 Marchini AK, Mosimann PJ, Guichard JP, Boukobza M, Houdart E. Anterior inferior cerebellar artery aneurysms mimicking vestibular schwannomas. *J Neuroimaging* 2014;24(04):404–406
- 32 Martin RG, Grant JL, Peace D, Theiss C, Rhoton AL Jr. Microsurgical relationships of the anterior inferior cerebellar artery and the facial-vestibulocochlear nerve complex. *Neurosurgery* 1980;6(05):483–507
- 33 Mascitelli JR, McNeill IT, Mocco J, Berenstein A, DeMattia J, Fifi JT. Ruptured distal AICA pseudoaneurysm presenting years after vestibular schwannoma resection and radiation. *J Neurointerv Surg* 2016;8(05):e19
- 34 Matsushige T, Ikawa F, Ohbyashi N, Imada Y, Kajiwara Y, Inagawa T. Ruptured aneurysm arising from the anterior medullary segment of the posterior inferior cerebellar artery: report of two cases [in Japanese]. *No Shinkei Geka* 2004;32(08):867–874
- 35 Matsuyama T, Okuchi K, Norimoto K, Ueyama T. Ruptured dissecting anterior inferior cerebellar artery aneurysm—case report. *Neurol Med Chir (Tokyo)* 2002;42(05):214–216
- 36 Menovsky T, André Grotenhuis J, Bartels RH. Aneurysm of the anterior inferior cerebellar artery (AICA) associated with high-flow lesion: report of two cases and review of literature. *J Clin Neurosci* 2002;9(02):207–211
- 37 Mizushima H, Kobayashi N, Yoshiharu S, et al. Aneurysm of the distal anterior inferior cerebellar artery at the medial branch: a case report and review of the literature. *Surg Neurol* 1999;52(02):137–142
- 38 Mori K, Miyazaki H, Ono H. Aneurysm of the anterior inferior cerebellar artery at the internal auditory meatus. *Surg Neurol* 1978;10(05):297–300
- 39 Nakagawa K, Sakaki S, Kimura H, Matsuoka K. Aneurysm of the anterior inferior cerebellar artery at the internal auditory meatus. *Surg Neurol* 1984;21(03):231–235
- 40 Nishimoto A, Fujimoto S, Tsuchimoto S, Matsumoto Y, Tabuchi K, Higashi T. Anterior inferior cerebellar artery aneurysm. Report of three cases. *J Neurosurg* 1983;59(04):697–702
- 41 Oh JS, Yoon SM, Shim JJ, Bae HG, Yoon IG. Endovascular treatment for ruptured distal anterior inferior cerebellar artery aneurysm. *J Cerebrovasc Endovasc Neurosurg* 2014;16(01):20–25
- 42 Okumura Y, Sakaki T, Hirabayashi H, Shimomura T. Intrameatal aneurysm successfully treated by meatal loop trapping—case report. *Neurol Med Chir (Tokyo)* 1999;39(02):161–164
- 43 Päsler D, Baldauf J, Runge U, Schroeder HW. Intrameatal thrombosed anterior inferior cerebellar artery aneurysm mimicking a vestibular schwannoma. *J Neurosurg* 2011;114(04):1057–1060
- 44 Pritz MB. Aneurysms of the anterior inferior cerebellar artery. *Acta Neurochir (Wien)* 1993;120(1-2):12–19
- 45 Russegger L, Furtschegger A. Aneurysms of the anterior inferior cerebellar artery. A case report and review of the literature [in German]. *Nervenarzt* 1990;61(08):499–503
- 46 Saito R, Tominaga T, Ezura M, Shimizu H, Yoshimoto T. Distal anterior inferior cerebellar artery aneurysms: report of three cases and literature review [in Japanese]. *No Shinkei Geka* 2001;29(08):709–714
- 47 Santillan A, Gobin YP, Patsalides A, Riina HA, Rosengart A, Stieg PE. Endovascular management of distal anterior inferior cerebellar artery aneurysms: report of two cases and review of the literature. *Surg Neurol Int* 2011;2:95
- 48 Santucci N, Gazzeri G, Magliocco C. Aneurysm of the anterior inferior cerebellar artery (AICA). 18th case in the literature [in Italian]. *Riv Neurol* 1985;55(01):30–37
- 49 Sarkar A, Link MJ. Distal anterior inferior cerebellar artery aneurysm masquerading as a cerebellopontine angle tumor: case report and review of literature. *Skull Base* 2004;14(02):101–106, discussion 106–107
- 50 Sasame J, Nomura M. Dissecting aneurysm of anterior inferior cerebellar artery initially presenting with nonhemorrhagic symptom. *J Stroke Cerebrovasc Dis* 2015;24(08):e197–e199

- 51 Singh S, Mittal RS, Purohit D, Shekhawat J. Spontaneous resolution of ruptured dissecting anterior inferior cerebellar artery aneurysm: a rare case report. *Asian J Neurosurg* 2017;12(03):570–572
- 52 Spallone A, De Santis S, Giuffrè R. Peripheral aneurysms of the anterior inferior cerebellar artery. Case report and review of literature. *Br J Neurosurg* 1995;9(04):537–541
- 53 Suh SH, Kim DJ, Kim DI, et al. Management of anterior inferior cerebellar artery aneurysms: endovascular treatment and clinical outcome. *AJNR Am J Neuroradiol* 2011;32(01):159–164
- 54 Sun Y, Wrede KH, Chen Z, Bao Y, Ling F. Ruptured intrameatal AICA aneurysms—a report of two cases and review of the literature. *Acta Neurochir (Wien)* 2009;151(11):1525–1530
- 55 Suzuki K, Meguro K, Wada M, Fujita K, Nose T. Embolization of a ruptured aneurysm of the distal anterior inferior cerebellar artery: case report and review of the literature. *Surg Neurol* 1999;51(05):509–512
- 56 Takeuchi S, Takasato Y, Masaoka H, et al. Trapping of ruptured dissecting aneurysm of distal anterior inferior cerebellar artery—case report [in Japanese]. *Brain Nerve* 2009;61(02):203–207
- 57 Tamura Y, Shirai W, Tokumitsu N. Intrameatal aneurysm of distal anterior inferior cerebellar artery manifesting a subarachnoid hemorrhage: a report of 2 cases [in Japanese]. *No Shinkei Geka* 2018;46(08):673–681
- 58 Taussky P, Garber S, Schmidt RH. Surgical management of a ruptured and unruptured distal anterior inferior cerebellar artery aneurysm. Report of 2 cases and review of the literature. *Cent Eur Neurosurg* 2011;72(02):108–111
- 59 Yamakawa H, Hattori T, Tanigawara T, Sahashi Y, Ohkuma A. Intracanalicular aneurysm at the meatal loop of the distal anterior inferior cerebellar artery: a case report and review of the literature. *Surg Neurol* 2004;61(01):82–88, discussion 88
- 60 Yokoyama S, Kadota K, Asakura T, Kawazoe K. Aneurysm of the distal anterior inferior cerebellar artery—case report. *Neurol Med Chir (Tokyo)* 1995;35(08):587–590
- 61 Zager EL. Isolated trigeminal sensory loss secondary to a distal anterior inferior cerebellar artery aneurysm: case report. *Neurosurgery* 1991;28(02):288–291
- 62 Zlotnik EI, Sklyut JA, Smejanovich AF, Stasenko EN. Saccular aneurysm of the anterior inferior cerebellar-internal auditory artery. Case report. *J Neurosurg* 1982;57(06):829–832
- 63 Zotta DC, Stati G, De Paulis D, Galzio RJ. Intrameatal aneurysm of the anterior inferior cerebellar artery. *J Clin Neurosci* 2011;18(04):561–563
- 64 Bojanowski MW, Berania I, Robert T. Anterior Inferior Cerebellar Artery Aneurysms. In: Rangel-Castilla L, Nakaji P, Siddiqui AH, Spetzler RF, Levy EI, eds. *Decision Making in Neurovascular Disease*. Thieme; 2018;283. Doi: 10.1055/b-0038-162171
- 65 Molyneux A, Kerr R, Stratton I, et al; International Subarachnoid Aneurysm Trial (ISAT) Collaborative Group. International Subarachnoid Aneurysm Trial (ISAT) of neurosurgical clipping versus endovascular coiling in 2143 patients with ruptured intracranial aneurysms: a randomised trial. *Lancet* 2002;360(9342):1267–1274
- 66 Spetzler RF, McDougall CG, Zabramski JM, et al. The Barrow Ruptured Aneurysm Trial: 6-year results. *J Neurosurg* 2015;123(03):609–617
- 67 Bambakidis NC, Manjila S, Dashti S, Tarr R, Megerian CA. Management of anterior inferior cerebellar artery aneurysms: an illustrative case and review of literature. *Neurosurg Focus* 2009;26(05):E6