




# Disseminated Gonococcal Infection Caused by a Multidrug-Resistant Pathogen Presenting with Hemorrhagic Manifestation: A Case Report

Yahaya Mohammed<sup>1</sup>  Amina Gambo Umar<sup>2</sup> Muhammad Zainu Sabitu<sup>3</sup> Saratu Bello<sup>2</sup>  
Muktar Umar<sup>4</sup> Ahmed Kolawole Jimoh<sup>3</sup> Fatima Birnin Yauri Aliyu<sup>2</sup> Jibril Abubakar<sup>3</sup>

<sup>1</sup>Department of Medical Microbiology and Parasitology, Faculty of Basic Clinical Sciences, College of Health Sciences, Usmanu Danfodiyo University, Sokoto, Nigeria

<sup>2</sup>Department of Obstetrics and Gynaecology, Usmanu Danfodiyo University Teaching Hospital, Sokoto, Nigeria

<sup>3</sup>Department of Medical Microbiology, Usmanu Danfodiyo University Teaching Hospital, Sokoto, Nigeria

<sup>4</sup>Department of Surgery, Usmanu Danfodiyo University Teaching Hospital, Sokoto, Nigeria

Address for correspondence Yahaya Mohammed, MBBS, MPH, FWACP, Department of Medical Microbiology and Parasitology, Faculty of Basic Clinical Sciences, College of Health Sciences, Usmanu Danfodiyo University, Sokoto, 800722, Nigeria (e-mail: yahyakt@yahoo.com).

J Lab Physicians 2023;15:462–465.

## Abstract

The incidence of disseminated gonococcal infection (DGI) is rising in some parts of the world, but there is paucity of data on its true incidence from sub-Saharan Africa. DGI has varied manifestations in different population group. We report a case of a 30-year-old sexually active woman presenting with hemorrhagic symptoms 2 weeks after a surgery on account of diagnosis of uterine fibroid made at a peripheral hospital. A multidrug-resistant *Neisseria gonorrhoeae* was isolated from the wound on her surgical site and blood sample. She was managed with intravenous meropenem, pressure dressing, and blood products, with the patient making a full recovery after a week. This case is presented because it is a rare one. Moreover, there is the need to revive the awareness of clinicians on the existence of multidrug-resistant gonococcus in our environment. We herein report a case of DGI from Nigeria.

## Keywords

- ▶ gonococcus
- ▶ resistance
- ▶ dissemination
- ▶ hemorrhage
- ▶ case report

## Key Message

Disseminated gonococcal infection due to multidrug-resistant *Neisseria gonorrhoeae* can present with hemorrhagic manifestations and may mimic Lassa fever or other viral hemorrhagic fevers. High index of suspicion and robust laboratory diagnostics are needed for clinicians/laboratorians managing sexually active females.

## Introduction

Disseminated gonococcal infection (DGI) results from the systemic spread of the pathogen, *Neisseria gonorrhoeae* (gonococcus) that may manifest with varied clinical features such as skin lesions, arthritis, and tenosynovitis.<sup>1</sup> Risk factors for DGI are menstruation, pregnancy, hepatitis, and pharyngeal gonococcal infection.<sup>1</sup> The clinical presentation of DGI

article published online  
December 19, 2022

DOI <https://doi.org/10.1055/s-0042-1758806>.  
ISSN 0974-2727.

© 2022. The Indian Association of Laboratory Physicians. All rights reserved.

This is an open access article published by Thieme under the terms of the Creative Commons Attribution-NonDerivative-NonCommercial-License, permitting copying and reproduction so long as the original work is given appropriate credit. Contents may not be used for commercial purposes, or adapted, remixed, transformed or built upon. (<https://creativecommons.org/licenses/by-nc-nd/4.0/>)

Thieme Medical and Scientific Publishers Pvt. Ltd., A-12, 2nd Floor, Sector 2, Noida-201301 UP, India

varies from patient to patient. However, typically patients present with a triad of tenosynovitis, arthritis, and dermatitis. By the time the symptoms of DGI appear, many patients no longer have any localized symptoms of mucosal infection. Maculopapular rashes and fever can manifest. Complication can include any of the following: gonococcal meningitis, pericarditis, and endocarditis.<sup>2</sup>

The World Health Organization estimated the yearly incidence of gonococcal infection to be 78 million cases.<sup>3</sup> A study by Wariso and Oboro from Port Harcourt in Nigeria documented only a 5% prevalence rate of *N. gonorrhoeae* following the screening of 200 sexually active women.<sup>4</sup> *Neisseria gonorrhoeae* has a specific growth requirement, resulting in it being missed in the laboratory. More so, most cases of the infection are asymptomatic.<sup>1</sup> There has been rising incidence in drug resistance by gonococcus arising mainly from the penicillinase-producing *N. gonorrhoeae*. Fluoroquinolone resistance has also emerged and is widespread. Resistance to third-generation cephalosporins, macrolides, and tetracycline has also emerged. Consequently, this narrows the choice of antibiotics for management and complicates treatment.<sup>5</sup> Effective management of DGI revolves around counseling, the early detection of cases, prompt management with relevant antibiotics, compliance, and contact tracing.<sup>5</sup> We present a case of DGI from a 30-year-old married nullipara, 2 weeks after an open myomectomy on account of diagnosis of uterine fibroid made at a peripheral hospital.

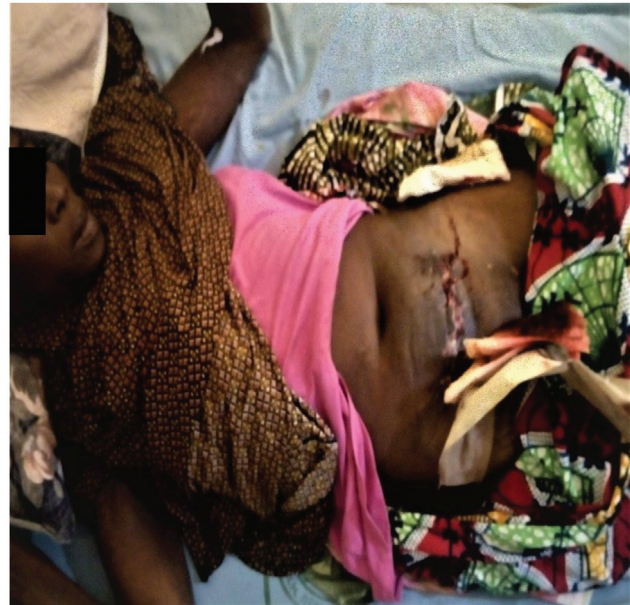## Case History

A 30-year-old woman presented to our center on March 7, 2020, with complaint of 5 days history of epistaxis, bleeding from the gums, per vaginal bleeding, and bleeding from an operation site. She also had complaint of fever that was more in the evenings and early mornings.

The patient had rashes on her body and right wrist pains 2 weeks prior to presentation which had resolved on presentation. She had an exploratory laparotomy on account of diagnosis of uterine fibroid made at a peripheral hospital about 2 weeks prior to presentation (February 21, 2020).

She was a nullipara whose last menstrual period was sometime in early November 2019. She was married in a polygamous family setting consisting of two other cowives and was not engaged in an extramarital relationship. Her husband was a middle grade civil servant with the state government.

On examination, she was an ill-looking young woman, febrile (temperature of 39.2°C), moderately pale, anicteric, with purpura on the tongue and buccal mucosa. There was petechial hemorrhage on the palms. The chest and cardiovascular system examination were normal. The abdomen was asymmetrical with swelling around the operation site, and it moved with respiration. There was obvious blood oozing from the operation site, with hyperpigmentation surrounding the operation site. There was no area of tenderness, ascites was not demonstrable, and bowel sounds were present and normoactive. The liver, spleen, and kidneys were



**Fig. 1** Patient showing the surgical scar.

not palpably enlarged. Pelvic examination revealed a vulva without abnormal secretions, blood, rashes, and a posterior cervix that was firm in consistency. The cervical os was closed with negative cervical motion tenderness. Rectal examination was normal.

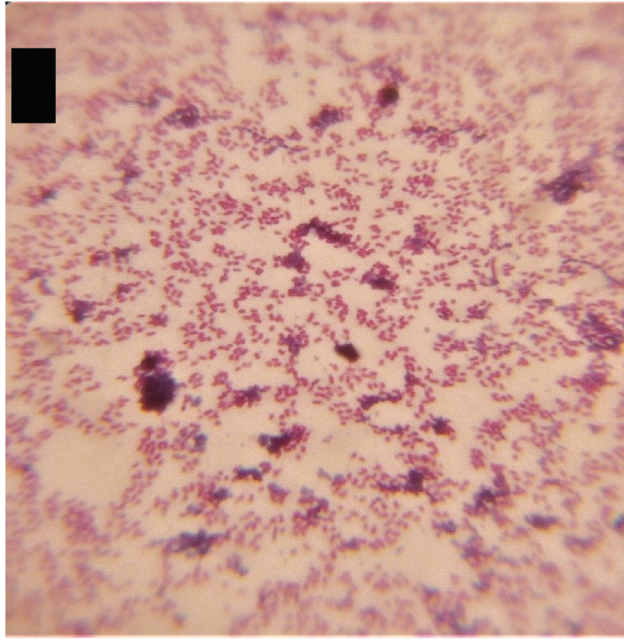
A diagnosis of anterior abdominal wall hematoma around the operation site following myomectomy was made. The differentials of viral hemorrhagic fever, severe sepsis, and aplastic anemia were considered. ►**Fig. 1** shows the patient with the surgical scar at presentation.

Investigation requested revealed a packed cell volume of 21%. The clotting profile, liver function test, urea, electrolytes, and creatinine were all within normal limits.

Blood film for malaria parasite was positive and retroviral (HIV) screening was negative. An abdominal ultrasound scan showed a mildly enlarged liver with uniform parenchymal echogenicity and echotexture. The uterus was normal with an intact endometrial plate. A simple right adnexal cyst with moderate fluid collection in the pouch of Douglas was seen.

Bone marrow aspiration for cytology (March 9, 2020) showed reactive features of white blood cells, microcytic hypochromic red cells, and thrombocytopenia. Blood for viral hemorrhagic fever screening returned negative for Lassa fever, yellow fever, and dengue fever. Wound swab microscopy revealed numerous gram-negative intracellular diplococci as shown in ►**Fig. 2**.

The blood culture (BACTEC) result was positive (March 10, 2020) and the isolate was then subcultured on Thayer–Martin agar and incubated at 5% CO<sub>2</sub> for 24 hours. *Neisseria gonorrhoeae* was isolated following Gram staining that shows a gram-negative diplococcus, positive reaction to oxidase test, positive fermentation of glucose, and a negative fermentation to maltose and lactose. Antimicrobial susceptibility testing was done on Thayer–Martin agar using the modified Kirby–Bauer method. The result is shown in ►**Fig. 3**. There was multidrug resistance to all the tested



**Fig. 2** Microscopy of *Neisseria gonorrhoeae* following overnight culture on Thayer–Martin agar ( $\times 1,000$ ).

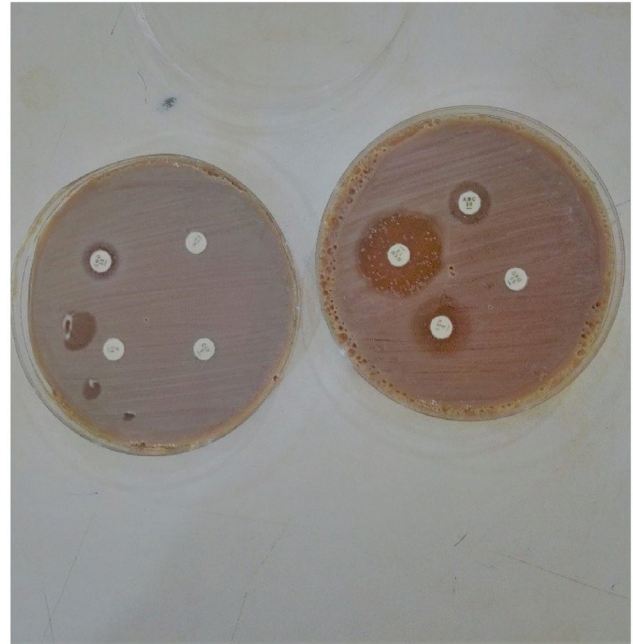
agents (penicillin, erythromycin, ceftriaxone, coamoxiclav, ciprofloxacin, levofloxacin, cefpodoxime) with the exception of meropenem.

She was administered on intravenous artesunate 120 mg at 0, 12, and 24 hours and thereafter administered on oral artemisinin-based combination therapy as soon as the patient can tolerate orally. Three units of packed cells were transfused at the rate of one unit per day for 3 days (March 9–11, 2020). Pressure dressing was applied on the operation site. Intravenous meropenem 1 g was commenced on March 10, 2020, given at 8-hourly interval for 72 hours. Counseling contact tracing and treatment was instituted for her known sexual contact. She was discharged on March 13, 2020, following full recovery and at 2 weeks (March 27, 2020) follow-up, examination revealed a healed abdominal scar with normal abdominal findings.

## Discussion

The patient in this report is a woman who recently had myomectomy on account of diagnosis of uterine fibroid made at a peripheral hospital. Histology and surgical findings were not available upon presentation at our center. A review of 42 patients with DGI by Holmes et al found out that 79% were women.<sup>6</sup> It is common in them due to dissemination as a result of menstruation or pregnancy.<sup>6</sup> The index patient was amenorrheic for 2 months prior to the first surgery; however, we do not receive sufficient information from the peripheral center as to whether pregnancy complicated with gonococcus infection was ruled out. This is a further call on referring physicians to provide detailed information to referral centers.

Even though fever and petechial hemorrhages have been documented as common manifestations of DGI,<sup>2</sup> our patient



**Fig. 3** Antimicrobial susceptibility testing for the *Neisseria gonorrhoeae* isolate.

presented with typical hemorrhagic symptoms (epistaxis, bleeding from operation site, per vaginal bleeding) with high-grade fever in the setting of relatively normal blood parameters. This important and rare presentation may be confused with Lassa fever or other viral hemorrhagic fevers. Even though by further evaluation, we could not detect the prevalent viral hemorrhagic agents. Clinicians managing such category of patients may miss this manifestation with negative consequences to management and prognosis.

The anemia detected from the index patient is probably from a long-standing malnutrition based on evidence from the bone marrow of it being microcytic–hypochromic. An abdominal ultrasound scan was able to pick moderate liver enlargement; however, the liver function test was essentially normal. Even though liver is not usually involved in the pathology, Lee et al<sup>7</sup> from Seoul, Korea have reported a case of liver abscess in a young man with DGI.

The isolate from our patient was multidrug resistant. This is not surprising, as the global rise in antimicrobial resistance pathogen includes gonococcus. Since the 1940s, antibiotic resistance in gonococcus have been rising steadily. Resistance has been documented to almost all antibiotics of choice with worrying reports of resistance to ceftriaxone and azithromycin.<sup>8,9</sup> However, we did not carry out further molecular characterization to detect resistant genes of the isolate due to logistics constraint.

The index patient did not have the classical triad presentation of tenosynovitis, rash, and polyarthralgia at presentation to our center, probably because she presented late. Lohani et al<sup>10</sup> from the United State reported a similar finding.

Our literature search on PubMed, African Journal Online, and Google Scholar could not find a reported case of DGI from Nigeria making this probably the first reported case.

## Conclusion

Multidrug-resistant *N. gonorrhoeae* can present with hemorrhagic manifestations in patients with DGI. Therefore, sexually active females at risk of contracting sexually transmitted diseases presenting with hemorrhagic tendencies need to be evaluated for DGI.

### Informed Consent

Patient consent was obtained for her images and other clinical details to be used in the case report. The names and initials were not published, and her identity was concealed as much as possible.

### Conflict of Interest

None declared.

## References

- 1 Thiéry G, Tankovic J, Brun-Buisson C, Blot F. Gonococemia associated with fatal septic shock. *Clin Infect Dis* 2001;32(05):E92–E93
- 2 Centres for Disease Control and Prevention. 2009 Sexually Transmitted Diseases Surveillance: Gonorrhoea. Accessed May 5, 2020, at: <http://www.cdc.gov/STD/stats09/gonorrhea.htm>
- 3 World Health Organization. Sexually Transmitted Infections (STIs). Accessed June 10, 2020, at: [https://www.who.int/news-room/factsheets/detail/sexually-transmitted-infections-\(stis\)](https://www.who.int/news-room/factsheets/detail/sexually-transmitted-infections-(stis))
- 4 Wariso KT, Oboro IL. Prevalence of *Neisseria gonorrhoeae* among undergraduate female students of University of Port Harcourt using strand displacement and amplification (SDA) technique. *IOSR J Dent Med Sci* 2013;7(04):76–79. Accessed November 16, 2022, at: [https://www.researchgate.net/publication/314529656\\_Prevalence\\_of\\_Neisseria\\_Gonorrhoea\\_among\\_Under\\_Graduate\\_Female\\_Students\\_of\\_University\\_Of\\_Port\\_Harcourt\\_Using\\_Strand\\_Displacement\\_and\\_Amplification\\_Sda\\_Technique](https://www.researchgate.net/publication/314529656_Prevalence_of_Neisseria_Gonorrhoea_among_Under_Graduate_Female_Students_of_University_Of_Port_Harcourt_Using_Strand_Displacement_and_Amplification_Sda_Technique)
- 5 World Health Organization. Emergence of multi-drug resistant *Neisseria gonorrhoeae* - threat of global rise in untreatable sexually transmitted infections. Accessed June 21, 2020, at: [http://whqlibdoc.who.int/hq/2011/WHO\\_RHR\\_11.14\\_eng.pdf](http://whqlibdoc.who.int/hq/2011/WHO_RHR_11.14_eng.pdf)
- 6 Holmes KK, Counts GW, Beaty HN. Disseminated gonococcal infection. *Ann Intern Med* 1971;74(06):979–993
- 7 Lee MH, Byun J, Jung M, et al. Disseminated gonococcal infection presenting as bacteremia and liver abscesses in a healthy adult. *Infect Chemother* 2015;47(01):60–63
- 8 Gonococcal Isolate Surveillance Project (GISP). Centers for Disease Control and Prevention. Accessed June 21, 2020, at: <https://www.cdc.gov/std/GISP/>
- 9 Brooks M. Center for Disease Control (CDC) Finds First Cluster of Highly Resistant Gonorrhea in US. *Medscape Medical News*. Accessed June 21, 2020, at: <http://www.medscape.com/viewarticle/869170>
- 10 Lohani S, Nazir S, Tachamo N, Patel N. Disseminated gonococcal infection: an unusual presentation. *J Community Hosp Intern Med Perspect* 2016;6(03):31841