



# Anti-F-Actin Antibody Positivity on Indirect Immunofluorescence Assay Following Chinese and Alternative Medicine Therapy: A Case Report

Mala Mahto<sup>1</sup>  Neha Rai<sup>1</sup>  Soma Dey<sup>1</sup> Ramesh Kumar<sup>2</sup>

<sup>1</sup>Department of Biochemistry, All India Institute of Medical Sciences (AIIMS) Patna, Patna, Bihar, India

<sup>2</sup>Department of Gastroenterology, All India Institute of Medical Sciences (AIIMS) Patna, Patna, Bihar, India

Address for correspondence Mala Mahto, MD, Department of Biochemistry, All India Institute of Medical Sciences (AIIMS) Patna, Patna, 801507, Bihar, India (e-mail: dr.malamahto@gmail.com).

J Lab Physicians 2023;15:311–315.

## Abstract

### Keywords

- ▶ anti-F-actin antibody
- ▶ indirect immunofluorescence
- ▶ drug-induced autoimmune liver disease
- ▶ giloy

Immunofluorescence on human epithelial type 2 cells is the standard screening assay for the detection of antinuclear antibodies (ANA). Cytoplasmic speckled patterns are a common finding. However, the less commonly reported ones include the cytoplasmic fibrillar patterns on indirect immunofluorescence technique (IIFT). The cytoplasmic fibrillar patterns include the cytoplasmic linear (AC-15), cytoplasmic filamentous (AC-16), and cytoplasmic segmental (AC-17). We report a case of cytoplasmic linear (F-actin) detected through IIFT during ANA screening in a 77-year-old man and later reconfirmed on liver mosaic biochip through IIFT on vascular smooth muscle substrate (VSM-47) without features suggestive of anti-smooth muscle antibody involvement post-complementary and alternative medicine therapy initiation.

## Introduction

In hospital settings, antinuclear antibodies (ANA) test is typically performed through indirect immunofluorescence technique (IIFT) on human epithelial type 2 (HEp-2) cells, using sera from the patients. To overcome interphysician heterogeneity in the naming and classification of ANA staining patterns and to reach an international consensus, the 2015 International Consensus on ANA Patterns workshop classified ANA patterns into three major groups: nuclear, cytoplasmic, and mitotic patterns. Nuclear patterns include the distinct fluorescence of the nucleoplasm, that is, speckled or homogeneous and patterns attributed to specific nuclear subcomponents, that is, centromere, nuclear dots, nucleolar, or nuclear envelope. Cytoplasmic patterns represent staining of the cytoplasm and are subdivided into five different patterns, that is, fibrillar, speckled, reticular/mitochondrial, polar/Golgi-like, and rods

and rings. These ANA patterns may provide clinically relevant insights into autoimmune diseases and further recommend diagnostic measures. Further confirmation of these patterns may be done by more specific tests based on IIFT, enzyme-linked immunosorbent assay, or line immunoassay (LIA). We try to analyze through this case study the role of IIFT using HEp-2 cell line and liver mosaic (six substrate combination) in detection of an extremely rare pattern with anti-F actin positivity without features suggestive of anti-smooth muscle antibody (ASMA) positivity by IIFT in a suspected case of drug (herbal)-induced liver injury (DILI).

## Case Study

A 77-year-old man was admitted to the gastroenterology inpatient department of a tertiary care center with complaints of altered sensorium along with yellowish discoloration of

article published online  
December 5, 2022

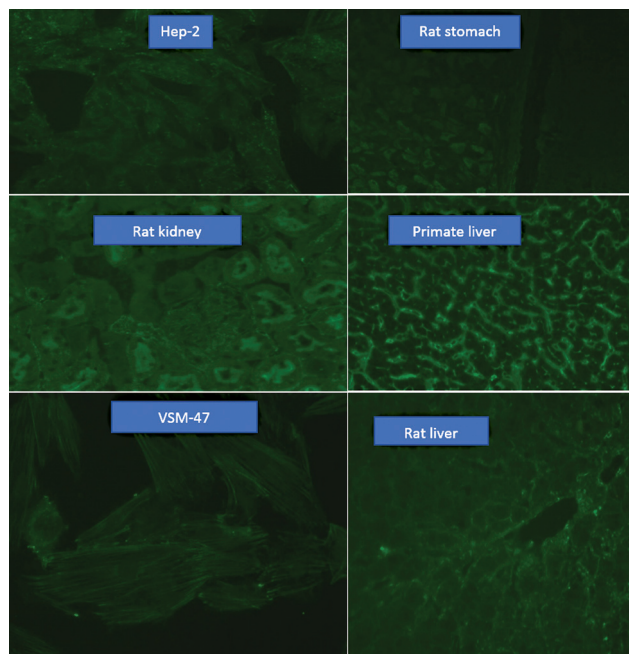
DOI <https://doi.org/10.1055/s-0042-1758663>.  
ISSN 0974-2727.

© 2022. The Indian Association of Laboratory Physicians. All rights reserved.

This is an open access article published by Thieme under the terms of the Creative Commons Attribution-NonDerivative-NonCommercial-License, permitting copying and reproduction so long as the original work is given appropriate credit. Contents may not be used for commercial purposes, or adapted, remixed, transformed or built upon. (<https://creativecommons.org/licenses/by-nc-nd/4.0/>)

Thieme Medical and Scientific Publishers Pvt. Ltd., A-12, 2nd Floor, Sector 2, Noida-201301 UP, India

eyes since 5 days. There was no history of fever, abdominal distention, pedal edema, or gastrointestinal bleeding. Upon examination, the patient had icterus, eczematous dermatitis, and grade IV hepatic encephalopathy. There were no focal neurological deficits or stigmata of chronic liver disease (CLD). There was no history of alcohol use or risk factors for metabolic liver disease. However, there was a significant history of taking giloy (*Tinospora cordifolia* [TCP]), a herbal supplement, for at least 2 months, presumably as an immune booster. In laboratory analysis (– Table 1), his liver function tests (LFTs) were as follows: serum bilirubin 333.11 μmol/L, alanine transaminase (ALT) 560 IU/L, aspartate transaminase 645 IU/L, serum alkaline phosphatase (ALP) 126 IU/L, and serum albumin 2.76 g/dL. His hemogram showed white blood cell count at  $13.820 \times 10^3/\mu\text{L}$ , hemoglobin at 13.4 g/dL, and platelet count at  $108 \times 10^3/\mu\text{L}$ . Patient was also found to be oliguric with deranged kidney function tests (serum creatinine: 159.16 μmol/L). His serological markers for viral hepatitis virus (A to E) were negative. Abdominal ultrasonography showed no evidence of cirrhosis or portal hypertension. Based on above findings, a diagnosis of acute liver failure (ALF) with multiorgan dysfunctions was made. His indirect immunofluorescence for autoantibodies to liver antigens on Liver Mosaic-8 (Euroimmun, Germany) revealed strong positivity for anti-F actin antibodies at a dilution of 1:100 (– Fig. 1). The Roussel Uclaf Causality Assessment Model score indicated that this patient had a high likelihood of having herb (giloy)-induced liver damage (score 6–8). Patient was given standard supportive care in accordance with the ALF treatment guidelines, but his condition rapidly



**Fig. 1** Indirect immunofluorescence technique (IIFT) on Liver Mosaic-8 by Euroimmun, Germany, showing F-actin antibody positivity on vascular smooth muscle-47 (VSM 47), human epithelial type 2 (HEp-2), and primate liver. Anti-smooth muscle antibody (ASMA) is negative on rat stomach, rat kidney, and rat liver.

deteriorated, and eventually he passed away from progressive multiorgan dysfunction and shock.

## Discussion

Autoantibodies related to liver disease are mainly classified into two entities: (1) nonorgan-specific autoantibodies including ANA, ASMA, antimitochondrial antibodies (AMA), and antibodies to liver kidney microsome type-1 (LKM-1), and (2) liver-specific autoantibodies such as antibodies to soluble liver antigen and antibodies to asialoglycoprotein receptor. The presence of these autoantibodies is essential in the process of diagnosing autoimmune liver diseases, including autoimmune hepatitis (AIH), primary biliary cirrhosis, or primary sclerosing cholangitis. However, some of these autoantibodies are occasionally detected even in the sera of patients with liver disease other than autoimmune liver diseases.<sup>1</sup>

The reference method to test liver-associated autoantibodies is IIF on triple rodent tissue, that is, liver, kidney, and stomach along with vascular smooth muscle-47 (VSM-47) cells on which the current knowledge of the clinical significance of autoimmune liver serology is based.<sup>2</sup> The biochip Liver Mosaic manufactured by Euroimmun (Germany) consists of six substrates: HEp-2 cells, primate liver, rat kidney, rat liver, rat stomach, and VSM-47. This technique allows the simultaneous detection of the main liver-related autoantibodies, including ANA, SMA, anti-LKM-1, and the AMA. A second major advantage of IIFT is its ability to detect autoantibodies whose target antigens are still unknown. However, the demerits of IIFT are that it requires trained laboratory personnel, is observer-dependent, and poorly standardized. Historically, ANA is the first autoantibody that has been associated to AIH, therefore suggesting an autoimmune origin of the disease, earlier named “chronic hypergammaglobulinemic hepatitis.”<sup>3</sup> ANA should be tested by IIF, since nuclear target antigens in AIH are unknown in at least one-third of the patients, leading to false negative results with probably severe clinical consequences if only molecular-based tests are used. ANA, coupled with ASMA, defines AIH type-1 (AIH-1), being positive in about two-thirds of the patients and associated with ASMA in half of the cases.<sup>4</sup>

ANA were the first autoantibodies to be associated with AIH. However, they lack disease specificity as they are present in healthy persons or associated with diseases such as other systemic autoimmune diseases or liver-specific diseases like fatty liver, DILI, or viral hepatitis. The pattern of ANA associated with AIH noted on HEp-2 cells is usually homogenous or speckled. However, no definite pattern on ANA screening has found to be specifically associated with AIH. Similar to ANA, ASMA has been associated with AIH since long time. ASMA targets the smooth muscles of the arterial vessels (V), the glomerular mesangium (G), and the fibers surrounding the kidney tubules (T), which results in the characteristic VGT pattern on rat kidney that is observed with AIH-1. The VGT pattern of ASMA also targets F-actin (microfilaments or filamentous actin) and the intermediate

**Table 1** Details of relevant laboratory investigations

Parameters	Result	Unit	Reference range
BUN	9.014	mmol/L	2.1–8.5
Serum creatinine	159.16	µmol/L	40–66
Serum uric acid	409.82	µmol/L	89.22–475.84
Serum calcium	2.05	mmol/L	2.15–2.27
Serum phosphorus	1.26	mmol/L	0.81–1.45
Sodium	136.41	meq/L	135–145
Potassium	3.81	meq/L	3.5–5
Chloride	102	meq/L	98–107
Total bilirubin	333.11	µmol/L	0–34
Indirect bilirubin	197.85	µmol/L	0.0–30.6
Direct bilirubin	135.26	µmol/L	0.0–3.4
ALT	560	U/L	13–40 (males)
AST	645	U/L	< 37 (males)
ALP	126	U/L	30–90
Total protein	5.83	g/dL	6.4–8.3
Albumin	2.76	g/dL	3.4–4.8
Globulin	3.07	g/dL	2.0–3.5
A:G ratio	0.9		1.5–2.5
Hemoglobin	13.4	g/dL	12–15
WBC	13.82	10 <sup>3</sup> /µL	4–10
Platelet	108	10 <sup>3</sup> /µL	150–450
RBC	4.44	million/µL	3.8–4.8
PT	44.3	seconds	< 14
INR	3.58		
Differential leucocyte count	N 84 L9 M4 E1		
HBs antigen	Negative		
Anti-HCV antibody	Negative		
ANA profile (LIA for 17 antigens)	Negative		
Liver profile (LIA for 5 antigens)	Negative		
Urine culture and sensitivity	Sterile		
Urine sugar	Trace		
Urine bile pigments	3+		
Urine bile salts	Negative		
Urine nitrite	Present		
Urine urobilinogen	+		
Urine microscopy WBC	2–3	hpf	
Urine microscopy RBC	40–50	hpf	
Urine microscopy epithelial cells	0–1	hpf	
Urine protein/albumin	2+		
Urine ketone bodies	15	mg/dL	
Serum IgG	18.90	g/L	7–16
HIV	Negative		

Abbreviations: ALP, alkaline phosphatase; ALT, alanine transaminase; ANA, antinuclear antibodies; AST, aspartate aminotransferase; BUN, blood urea nitrogen; HBs, hepatitis B surface; HCV, hepatitis C virus; HIV, human immunodeficiency virus; IgG, immunoglobulin G; INR, international normalized ratio; LIA, line immunoassay; PT, prothrombin time; RBC, red blood cell; WBC, white blood cell.

filaments (vimentin and desmin). However, 20% of ASMA positive patients with AIH-1 do not show the VGT/F-actin pattern indicating that the absence of this pattern alone is not sufficient to exclude the diagnosis of AIH-1. IIFT using HEp-2 cell line gives the cell a characteristic “cable” pattern in presence of anti-F-actin antibodies. Antibodies to tubulin and intermediate filaments are commonly encountered in viral infections, including viral hepatitis and other autoimmune and nonautoimmune diseases.<sup>5</sup> Due to the lack of specificity, this has led some to suggest abandoning nonspecific ASMA testing in favor of more specific anti-F actin assays.<sup>6</sup> In case of ASMA positivity, the stomach shows distinct cytoplasmic fluorescence of the lamina muscularis and tunica muscularis and interglandular contractile fibers of the tunica mucosa. ASMA directed against the target antigen F-actin react furthermore with the cytoskeletal of HEp-2 cells and bile canaliculi of primate liver. Rat liver may show enhanced homogenous fluorescence of muscle fibers in walls of the blood vessel. The substrate, VSM-47, derived from rat embryonic thoracic aorta reacts very specifically to anti-actin antibodies showing filamentous, needle-like fluorescence. Isolated fibroblasts may also take up fluorescence staining and give cable-like appearance depicting presence of anti-F actin antibodies in the serum sample.

In this case, the predominant laboratory findings included a deranged LFT, positive ANA screening on HEp-2 cells, and positive anti-actin antibodies on liver mosaic by IIFT. However, the most peculiar finding noted was positive antibody against actin (actin-F) on HEp-2 cells, primate liver, and VSM-47 but no significant fluorescence was elicited for ASMA on rat stomach, kidney, and liver. The presence of anti-actin antibodies on HEp-2 cell line and primate liver and VSM-47 suggested a diagnosis compatible with AIH-1 (→ Fig. 1). Fifty percent of individuals with AIH-1 who are ASMA-positive have specific anti-F-actin antibodies. The use of anti-F-actin antibody is more predictive of AIH, with a specificity and sensitivity of approximately 80 and 90%, respectively; in 26% of individuals, it may be the sole marker of disease with literature also reporting anti-actin positivity rarely noted in SMA-negative AIH sera.<sup>6</sup> Czaja and Homberger elucidated that AIH-1 patients seropositive for anti-F-actin developed liver failure and required liver transplantation more frequently than those seronegative for anti-F-actin.<sup>7</sup> Anti-actin antibody positivity has shown to be associated with relapse after withdrawal of steroid therapy.<sup>1</sup>

More notable in this case was the recent history of giloy intake during the coronavirus disease 2019 pandemic in 2021 followed by the onset of symptoms suggestive of liver pathology within 2 months. Complementary and Chinese medicine (CAM) therapy originated in India and has gained popularity globally presently. CAM accounts for a significant portion of DILI in India and China. TCP (giloy) has been used for augmenting immunity and ameliorating diseases as per the ancient Indian Ayurveda system. It is believed to have hypoglycemic, diuretic, anti-inflammatory, antioxidant, analgesic, antimalarial, hepatoprotective, immunomodulatory, and anti-cancer attributes.<sup>8</sup> A similar study has been reported earlier by Karousatos et al.<sup>9</sup> The evidence from several studies in past

suggest that TCP has the potential to induce hepatotoxicity and even fatal consequence in patients with or without CLDs. Recently, Nagral et al have published a case series of six patients representing DILI after consumption of TCP in the form of boiled extracts, tablets, and syrup.<sup>10</sup> Animal models of TCP consumption have shown significantly higher levels of cholesterol, lower levels of blood glucose, and reduced body weight. However, a high dosage or long-term use of TCP may result in elevated liver enzymes like ALP, ALT, and  $\gamma$ -glutamyl transferase along with bilirubin, both in human and rat model studies.<sup>11</sup> In a study by Kulkarni et al, the authors reported that most patients took self-medicated pure giloy-based formulations in the form of decoctions purchased locally, and the median duration of giloy consumption was 42 days. The median time from first giloy ingestion to development of symptoms was 46 days with a mean intake of 40.8 mL per day. The most common clinical presentation was acute worsening of CLD followed by acute hepatitis, and the most common autoantibody was ANA. Approximately 10% of the patients in this study died within 2 months of presentation, and nearly 5% required liver transplantation within 3 months. Liver histology was suggestive of HILI with autoimmune features but not classical AIH with atypical features on biopsy such as hepatocyte and canalicular cholestasis and neutrophilic and eosinophilic infiltration. Autoantibodies were found in 29.6% of patients, with ANA in 25.9%, LKM-1 antibodies in 7.4%, and AMA in 3.7%. The authors suggested that giloy use in predisposed patients could induce hepatitis with autoimmune features or unmask an underlying autoimmune CLD due to its immune-stimulant mechanisms, which may also result in significant liver toxicity and lead to severe acute hepatitis and to acute on chronic liver failure or ALF.<sup>12</sup>

## Conclusion

IIFT may be capable of detecting autoantibodies in serum in suspected autoimmune liver diseases which may be missed out by solid phase immunoassays like LIA which are coated with selective antigens. VSM substrate (VSM-47) serves as a potential substrate to identify anti-F-actin antibodies which may go undetected by HEp-2 cells and primate liver substrate on ANA screening. Pattern of drug-induced liver disease may show variation from the common autoimmune liver diseases on IIFT. It is suggested that CAM therapy may unmask an autoimmune disease in predisposed candidates due to its immunomodulatory properties and hence may be judiciously used.

## Conflict of Interest

None declared.

## References

- 1 Himoto T, Nishioka M. Autoantibodies in liver disease: important clues for the diagnosis, disease activity and prognosis. *Auto Immun Highlights* 2013;4(02):39–53
- 2 Berreta-Piccoli BT, Miegi-Vergani G, Vergani D. Autoimmune hepatitis: serum autoantibodies in clinical practice. *Clin Rev Allergy Immunol* 2022;63(02):124–137

- 3 Cowling DC, Mackay IR, Taft LI. Lupoid hepatitis. *Lancet* 1956;271(6957):1323–1326
- 4 Sebode M, Weiler-Normann C, Liwinski T, Schramm C. Autoantibodies in autoimmune liver disease—clinical and diagnostic relevance. *Front Immunol* 2018;9:609
- 5 Cancado ELR, Abrantes-Lemos CP, Terrabuio DRB. The importance of autoantibody detection in autoimmune hepatitis. *Front Immunol* 2015;6:222
- 6 Zeman MV, Hirschfield GM. Autoantibodies and liver disease: uses and abuses. *Can J Gastroenterol* 2010;24(04):225–231
- 7 Czaja AJ, Homburger HA. Autoantibodies in liver disease. *Gastroenterology* 2001;120(01):239–249
- 8 Saha S, Ghosh S. *Tinospora cordifolia*: one plant, many roles. *Anc Sci Life* 2012;31(04):151–159
- 9 Karousatos CM, Lee JK, Braxton DR, Fong TL. Case series and review of Ayurvedic medication induced liver injury. *BMC Complement Med Ther* 2021;21(01):91
- 10 Nagral A, Adhyaru K, Rudra OS, Gharat A, Bhandare S. Herbal immune booster induced liver injury in the COVID-19 pandemic—a case series. *J Clin Exp Hepatol* 2021;11(06):732–738
- 11 Kadir FA, Othman F, Abdulla MA, Hussan F, Hassandarvish P. Effect of *Tinospora crispa* on thioacetamide-induced liver cirrhosis in rats. *Indian J Pharmacol* 2011;43(01):64–68
- 12 Kulkarni AV, Hanchanale P, Prakash V, et al; Liver Research Club India. *Tinospora Cordifolia* (giloy)-induced liver injury during the COVID-19 pandemic-multicenter nationwide study from India. *Hepatol Commun* 2022;6(06):1289–1300