








Evolution of Anatomical Studies on the Arterial, Venous, and Lymphatic System in Plastic Surgery

Soo Jin Woo, MD¹  Hee Tae Koo, MD¹  Seong Oh Park, MD, PhD²  Hiroo Suami, MD, PhD³ 
Hak Chang, MD, PhD¹ 

¹ Department of Plastic and Reconstructive Surgery, Seoul National University College of Medicine, Seoul, Republic of Korea

² Department of Plastic and Reconstructive Surgery, Hanyang University Medical Center, Hanyang University College of Medicine, Seoul, Republic of Korea

³ Faculty of Medicine, Health and Human Sciences, Macquarie University, Sydney, Australia

Arch Plast Surg 2022;49:773–781.

Address for correspondence Hak Chang, MD, PhD, Department of Plastic and Reconstructive Surgery, Research Institute of Plastic and Reconstructive Surgery, Ischemic/Hypoxic Disease Institute, Seoul National University College of Medicine, 101 Daehak-ro, Jongno-gu, Seoul 03080, Republic of Korea (e-mail: hchang@snu.ac.kr).

Hiroo Suami, MD, PhD, Faculty of Medicine, Health and Human Sciences, Level 1, 75 Talavera Road, Macquarie University, SW 2109, Australia (e-mail: hiroo.suami@mq.edu.au).

Abstract

Anatomies of the vascular and lymphatic systems have been vital research topics in reconstructive surgery. Harvey was a pioneer who provided the earliest descriptions of the cutaneous vasculature in the 17th century. The concept of vascular territories of the skin was first described by Manchot. The radiographic injection method in cadavers was developed by Salman, who defined more than 80 vascular territories. The arterial system has been thoroughly investigated with the development of regional and free flaps. The concept of axial and random pattern flaps was introduced by McGregor and Morgan. Manchot's vascular territories were refined by Taylor and Palmer as the angiosome concept. Detailed information about the venous circulation is essential for reconstructive surgeries. The concept of intrinsic and extrinsic venocutaneous vascular systems was introduced by Nakajima and led to the development of the venoadipofascial flap. The importance of venous augmentation in flap survival was emphasized by Chang. The lymphatic system was discovered much later than the arterial and venous systems. Aselli was credited for discovering the lacteal vessels in the 17th century; mercury was popularly used as a contrast agent to distinguish lymphatic vessels for the next three centuries. A radiographic method in cadavers was developed by Suami. Lymphatic imaging devices are constantly upgrading, and photoacoustic imaging was recently introduced for three-dimensional visualization of architecture of superficial layers of the lymphatic and venous systems.

Keywords

- ▶ vascular system
- ▶ lymphatic system
- ▶ flap
- ▶ reconstructive surgery

Introduction

Reconstructive surgery for tissue defects continues to be a challenging task for surgeons, and local or distant flap transfer is performed in cases wherein the wound cannot

be closed by primary wound closure. The first description of flap dates back to 600 B.C., when Sushruta, an Indian physician, documented that cheek flaps were used to reconstruct amputated noses.¹ The word “flap” originates from the 16th century Dutch word “*flappen*” and refers to an object hanging

received
December 7, 2021
accepted after revision
June 8, 2022

DOI <https://doi.org/10.1055/s-0042-1758636>.
eISSN 2234-6171.

© 2022. The Korean Society of Plastic and Reconstructive Surgeons. All rights reserved.

This is an open access article published by Thieme under the terms of the Creative Commons Attribution-NonDerivative-NonCommercial-License, permitting copying and reproduction so long as the original work is given appropriate credit. Contents may not be used for commercial purposes, or adapted, remixed, transformed or built upon. (<https://creativecommons.org/licenses/by-nc-nd/4.0/>)

Thieme Medical Publishers, Inc., 333 Seventh Avenue, 18th Floor, New York, NY 10001, USA

broad and loose and being fastened only by one side. The flap surgery was initially performed by surgeons who had no precise knowledge of the vascular anatomy. Therefore, they did not have sufficient understanding about maintaining the viability of flaps, and surgical outcomes were usually not considered favorable. Gillies and Millard adverted that it was a “constant battle between blood supply and beauty”². Although anatomical studies of the vascular system and development of the various surgical procedures did not occur concurrently, they are closely interconnected. Anatomical studies of the vascular system are essential for surgeons to perform reliable reconstructive surgery.

The human vasculature has been investigated over centuries; however, knowledge gaps exist in performing safe reconstructive procedures. This article aims to provide a chronological overview of the literature and research on the anatomy of the human vasculature and to discuss how these studies contributed to the development and refinement of various flaps and assist surgeons in performing lymphatic surgery during reconstructive plastic surgery.

Arterial System

Vascular Territories of the Skin

Galen, a Greek physician, was the first researcher to distinguish between arteries and veins. He also recognized that

arteries carry blood instead of oxygen. However, he believed that the arteries and veins were independent one-way tracts with no connections. In 1628, Harvey corrected this long-standing misunderstanding and proposed that blood circulates through the body via arteries and veins and that the heart pumps blood.³

The concept of vascular territories of the skin was depicted by Manchot through his dissections of cutaneous vessels in cadavers (→Fig. 1).⁴ Each vascular territory of the skin was defined by the target area to which each source artery and its branches supplied blood. He could not benefit from radiography in his study because it was conducted before Röntgen discovered radiation. However, Manchot's findings were later proven to be remarkably accurate by radiographic injection studies. Unfortunately, his work was known by only a few surgeons until it was translated into English.⁵

The revolutionary anatomical study was conducted by Michel Salmon in 1936. His work refined Manchot's results through the extensive use of radiography. He developed the intravascular injection technique with the mixture of lead oxide, gelatin, phenol, and water, which enabled the demonstration of smaller vessels on radiographs.^{6,7} He defined more than 80 vascular territories in the entire body in his book (→Fig. 2). Salmon focused on the interconnections between the source arteries, investigated the density and

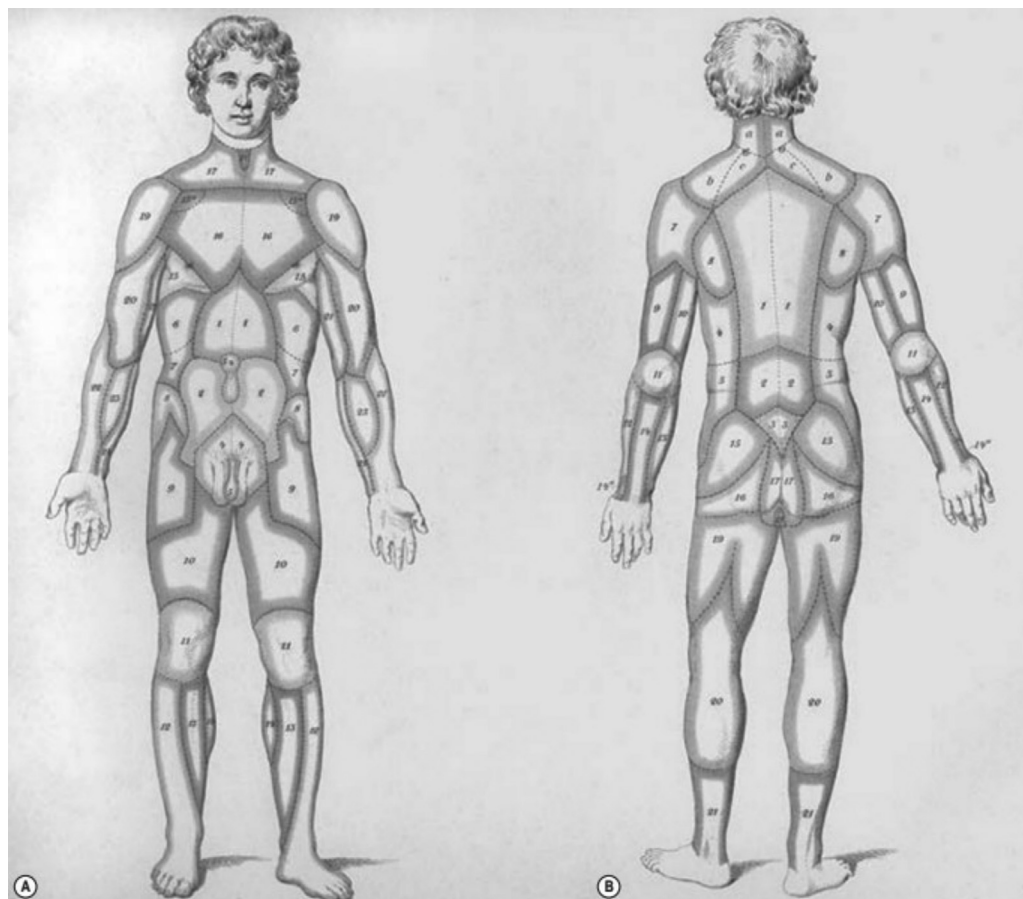


Fig. 1 Carl Manchot's vascular territories of the human integument. (From Manchot C. *Die Haut Arterien des menschlichen Körpers*. Leipzig: FCW Vogel; 1889.)

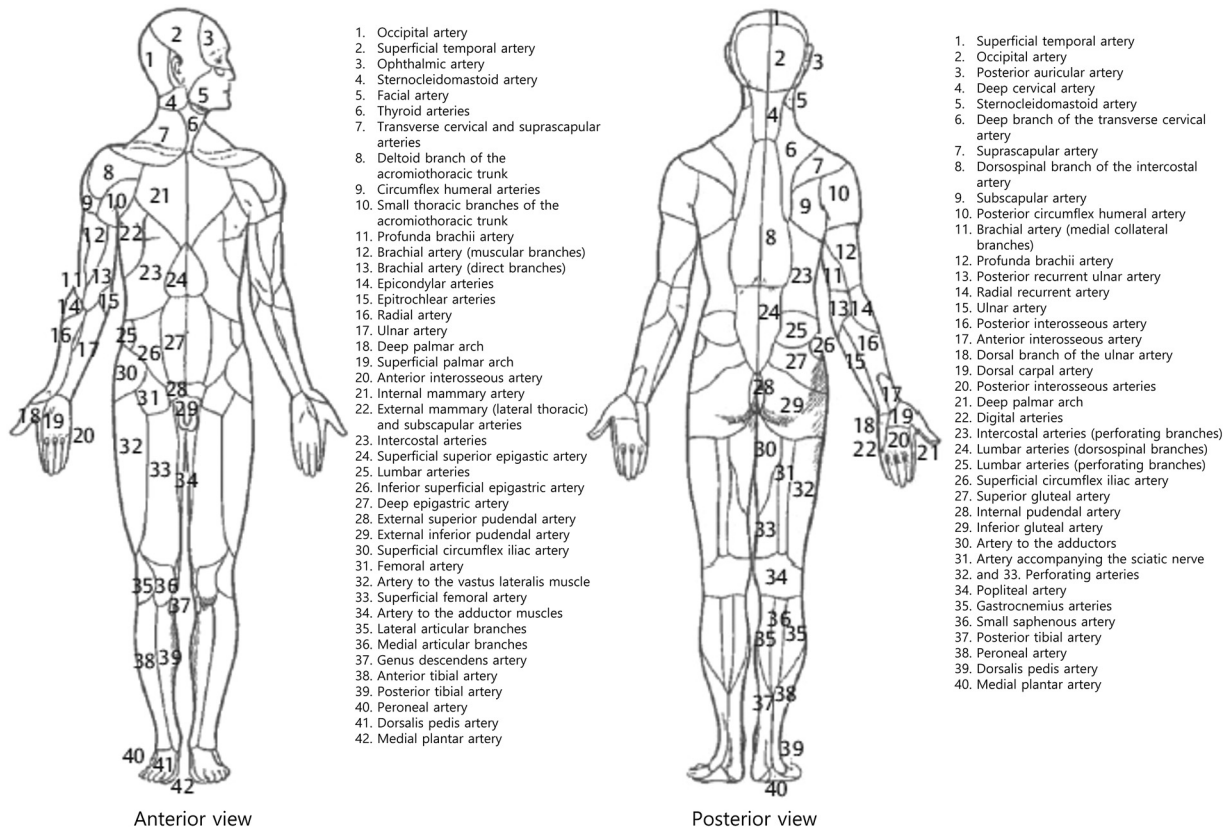


Fig. 2 Michel Salmon’s vascular territories of the human body. (Reproduced from Zenn, Jones, Reconstructive Surgery Anatomy, Technique, and Clinical Applications, ©2012, Thieme Publishers, New York, with permission.)

size of blood vessels in the different parts of the body, and distinguished between hyper- and hypovascular zones.

The arterial territories of the skin were studied *in vivo* by Nakajima et al, in 1981.⁸ When they performed selective angiography on peripheral arteries in patients, prostaglandin E1 was injected for vasodilation before injection of radio-contrast media. The prostaglandin injection caused flushing of the skin in the respective area, and they were able to distinguish between the source arteries and their corresponding skin territories. In 1996, Cormack and Lamberty classified the vascular territories of cutaneous flap into three types: anatomical, dynamic, and potential vascular territories.⁹ The anatomical territory refers to the area supplied by a vessel before it anastomoses with any other vessels. The dynamic territory develops after flap elevation when a cutaneous vessel is divided, but the original area of blood supply remains viable due to the rearrangement of the local blood flow such that an adjacent vessel invades that territory. The potential territory of a cutaneous vessel includes areas beyond its dynamic territories and can only be captured following a delay procedure.

Subsequently, Taylor and Palmer proposed the “angiosome” concept of the body in 1987¹⁰ (→ Fig. 3). Angiosome is derived from the Greek words “*angeion* and *somat*”, which refers to a composite block of tissue supplied by a source artery. Their concept assisted in the development of various free flaps including cutaneous, musculocutaneous, and osteal flaps and vascularized nerve grafts. They applied the radiocontrast

injection method developed by Salmon to their cadaver studies. The original study was followed by studies of specific body parts.^{11–14} These studies strengthened the angiosome concept of blood supply and revealed the interconnections between adjacent vascular regions via choke vessels.

Geddes et al attempted to standardize the nomenclature of perforator flaps by describing all perforator flaps in 2003.¹⁵ Tang and Morris introduced a new three-dimensional (3D) visualization technique for vessels using angiography and 3D reconstruction software in 2008.¹⁶ This new technique provided fine microvascular perfusion with higher radio-opacity and elimination of problems of superimposition, and it was suitable for the assessment of anatomical variation within a large sample population.

Saint-Cyr et al investigated individual perforator territories and the flow characteristics between them using the 3D computed tomography (CT) angiographic perfusion method in 2009.¹⁷ The results provided impetus for vascular knowledge from the source artery to the perforator level. The vascular territory of an individual perforator was termed “*perforasome*.” CT angiography revealed that each perforasome is connected to adjacent perforasomes through direct or indirect linking of vessels.

Patterns of Blood Supply to the Skin

In 1893, Werner Spalteholz provided some of the earliest descriptions of cutaneous vasculature by arterial injections

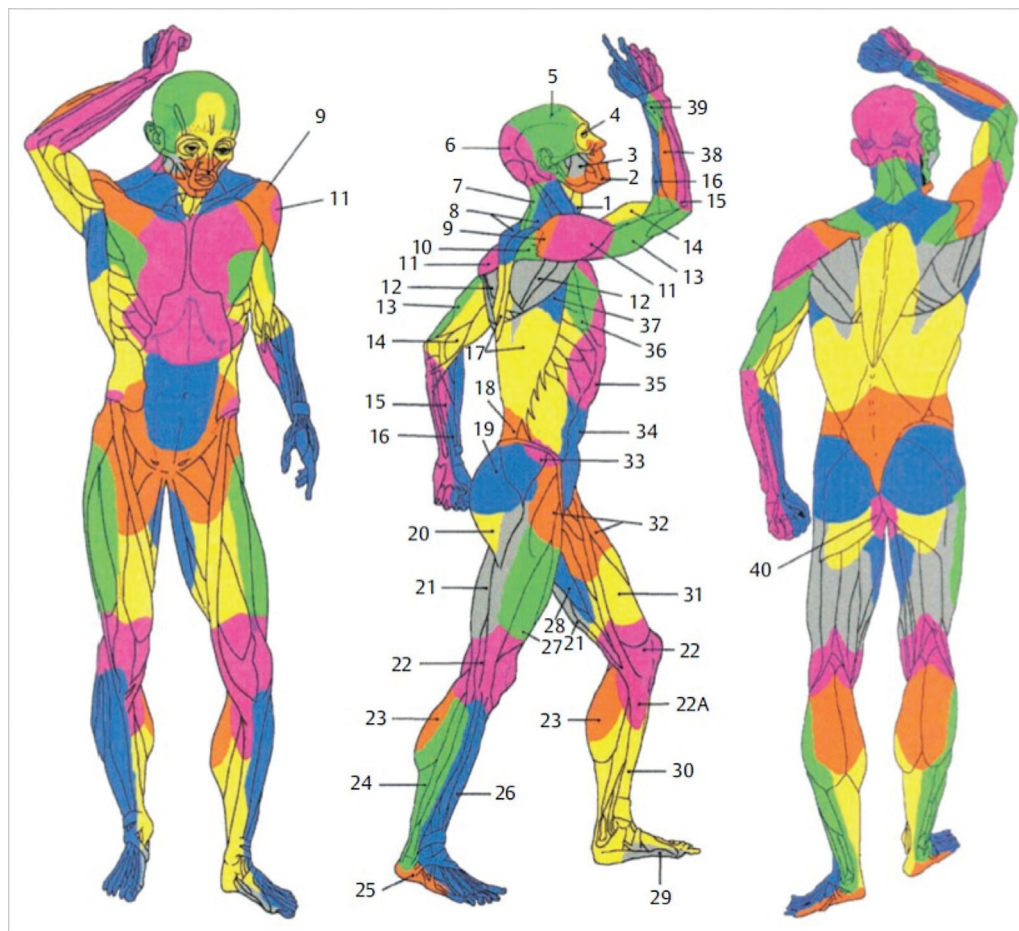


Fig. 3 Ian Taylor's vascular territories (angiosomes) of the integument of the skin according to the source vessel of the perforator (1, thyroid; 2, facial; 3, buccal internal maxillary; 4, ophthalmic; 5, superficial temporal; 6, occipital; 7, deep cervical; 8, transverse cervical; 9, acromiothoracic; 10, suprascapular; 11, posterior circumflex humeral; 12, circumflex scapular; 13, profunda brachii; 14, brachial; 15, ulnar; 16, radial; 17, posterior intercostals; 18, lumbar; 19, superior gluteal; 20, inferior gluteal; 21, profunda femoris; 22, popliteal; 22A, descending geniculate saphenous; 23, sural; 24, peroneal; 25, lateral plantar; 26, anterior tibial; 27, lateral femoral circumflex; 28, adductor profunda; 29, medial plantar; 30, posterior tibial; 31, superficial femoral; 32, common femoral; 33, deep circumflex iliac; 34, deep inferior epigastric; 35, internal thoracic; 36, lateral thoracic; 37, thoracodorsal; 38, posterior interosseous; 39, anterior interosseous; 40, internal pudendal). (Reproduced from Zenn, Jones, *Reconstructive Surgery Anatomy, Technique, and Clinical Applications*, ©2012, Thieme Publishers, New York, with permission.)

of gelatin and various pigments.¹⁸ He classified the cutaneous arteries into two: direct and indirect. The direct cutaneous arteries extend directly into the skin by traveling through the intermuscular septa without passing through the muscle belly. In contrast, the indirect cutaneous artery supplies both the deeper tissues, such as muscles, and the skin.

In 1973, McGregor and Morgan found large subcutaneous vessels in several parts of the body and large cutaneous flaps could be raised from these vessels.¹⁹ They named one such flap as the “axial pattern flap” that had an inbuilt arteriovenous system. The other flap was called a “random pattern flap” without such a vascular system. Recognition of the axial pattern flap required detailed knowledge about the vascular anatomy including the variants. McGregor and Morgan investigated the demarcation of the skin territories corresponding to individual arteries and found that the vascular boundaries were not fixed and could be altered, and a “watershed” zone existed between territories. They postulated that the boundary may be determined by a dynamic

pressure equilibrium existing in the blood vessels of each territory.

Indocyanine green (ICG) angiography is a recent imaging tool used to visualize the vasculature *in vivo*; it enabled mapping of the terminal portion of the skin perforator that branches up to approximately 0.1 mm. Narushima used ICG angiography during flap surgeries and proposed the pure skin perforator concept in 2018.²⁰ They described that the pure skin perforator flap can be elevated based on branches of the perforating artery directly supplying blood to the deep dermal layer. They reported that branches of pure skin perforators formed intradermal anastomoses with the adjacent pure skin perforator territory and allowed safe expansion of the flap to the adjacent territory.

Venous System

In the 16th century, arteries and veins were thought to be two separate systems. Vesalius described the vein as the vital

vascular system. He believed that the vein carried blood and nutrients from the core of the body to its periphery.²¹ For the first time in 1628, Harvey published a treatise on veins that proved that arteries and veins belonged to a single circulatory system.²² He also proved the presence of valvular structures in the vein by a simple experiment; when a tourniquet was applied to the upper arm and the cutaneous veins in the forearm were distended, the proximal portion of the obstructed vein remained empty on palpation with a finger because venous valves stopped blood reflux from the proximal site.

Anatomy of the venous system had been ignored in plastic surgical research. Plastic surgeons conventionally believed that arterial supply was most essential for flap survival and that venous drainage was less important. However, introduction of the free flap necessitated further investigation into the effects of venous drainage on flap physiology.

Anatomists investigated the venous system in cadavers. Unlike dissection studies of the arterial system, injection into the venous system was challenging because venous valves prevented retrograde filling. Taylor mapped the direction and locations of venous valves and proposed the “venosome” concept in 1987.²³ The venous drainage of the skin and subcutaneous tissue consists of two separated systems: the primary and secondary venous systems interconnected by valveless (oscillating or bidirectional) veins (→Fig. 4). Veins in the secondary venous system run along the arteries; thus, the direct and indirect cutaneous arteries are associated with concomitant veins. They drain into the venae comitantes of the source arteries in the deep tissue. The primary system is composed of longitudinal subcutaneous veins including the cephalic, basilic, saphenous, and superficial inferior epigastric veins. They contribute to thermoregulation and are often accompanied by cutaneous nerves.

Blood supply to the flaps has been focused on branches of the source arteries. However, Nakajima et al considered that the arteries accompanying the cutaneous vein could be utilized as blood supply to the flaps and introduced a new flap design concept in 1998.²⁴ They identified two types of arteries accompanying the cutaneous vein: intrinsic and extrinsic venocutaneous vascular systems. The intrinsic vascular system is the same vasculature known as the vasa vasorum surrounding the venous wall, and the extrinsic vascular system formed a network around the vein.^{25,26}

The discovery of venocutaneous vascular systems led to the development of new pedicled flap named veno-accompanying artery fasciocutaneous (VAF) flap. While most experimental studies focused on supercharging arterial supply to increase flap survival, Chang reported that venous augmentation contributed to flap survival in an animal study.²⁷ Imanishi et al depicted the 3D venous polygons underneath the dermis and hypothesized that the congestive necrosis of a flap resulted from the obstruction of venous flow specifically in a horizontal plane.²⁸ Imanishi also emphasized the importance of preserving the polygonal venous network beneath the dermis during thinning procedure to raise a super thin flap.²⁹

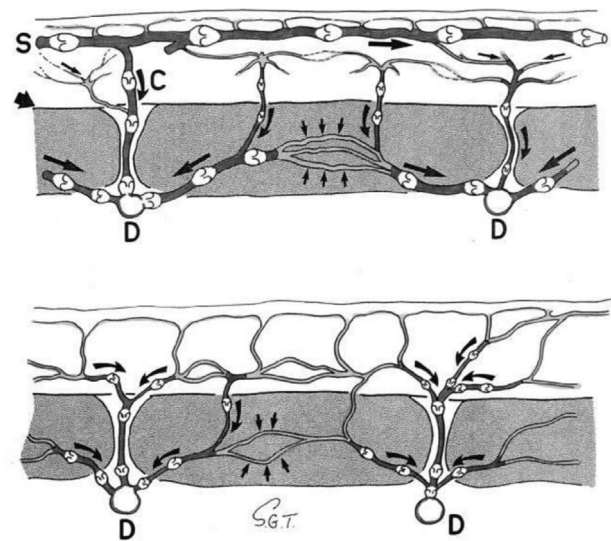


Fig. 4 Ian Taylor's diagram of venosome concept (S, superficial venous system; D, deep venous system; C, vena communicans). (From Taylor GI, Caddy CM, Watterson PA, et al. *The Venous Territories (venosomes) of the human body. Plastic and Reconstructive Surgery.* 1990;86(2):185–213, with permission.)

Lymphatic System

Anatomy of Lymphatic Vessels

Compared with the arterial and venous systems, the lymphatic system was discovered much later in the 17th century and was not given much attention in anatomy. Hippocrates provided the first description of the lymphatic system as white blood around 400 BC.³⁰ Vesalius, the “Father of Anatomy,” did not mention about lymphatic vessels or could hypothesize why the body would require a third set of vessels. Aselli, an Italian anatomist and surgeon, incidentally discovered the lacteal vessels in canine mesentery when he was asked to demonstrate the autonomic nerves in 1627.³¹ He recognized the significance of his discovery, and barely restraining his delight, shouted “Eureka” upon the discovery of the exceedingly thin and attractively white, scattered cords near the intestines.

Nuck used mercury to delineate the lymphatic vessels and published his findings on the lymphatics in the uterus, in 1692.³² This mercury injection technique served as the stepping stone for the fundamental anatomical works of lymphatic topography depicted by Cruickshank³³ and Mascagni and Sanctius.³⁴ Mascagni and Sanctius published a masterpiece anatomical atlas of the lymphatics in 1748 (→Fig. 5). Hunter, Hewson, and Cruickshank described the anatomy and function of the lymphatics in 1786.³³ Their work is still recognized as the basis of the understanding of the lymphatic system. In 1874, Sappey also used Nuck's mercury technique and published his findings of the lymphatic system with excellent etching Figs.³⁵

Gerota developed a new technique using Prussian blue in turpentine and ether in place of mercury due to its toxicity.³⁶ Since the injected dye in Gerota's method could not travel long distances, anatomists had to use smaller specimens such as fetal or child cadavers. This material issue became a

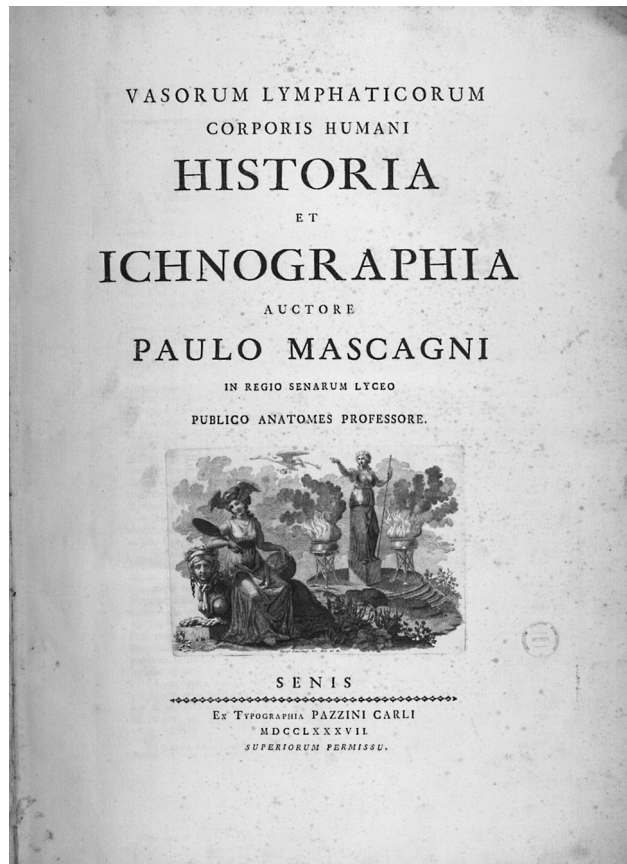


Fig. 5 Mascagni's anatomic atlas of the lymphatics. (From Mascagni P. Vasorum lymphaticorum Corporis Humani Historia et ichnographia. Senis: Pazzini; 1787.)

potential barrier to conducting these anatomical studies of the lymphatics. In 2005, Suami et al developed a new method for demonstrating and recording the lymphatic anatomy in fresh adult cadavers on radiographs.³⁷ When hydrogen peroxide (3%) or a mixture of hydrogen peroxide and acrylic blue dye was injected into the skin or soft tissue of cadavers, fine oxygen bubbles were produced, which inflated the lymphatic vessels and made them identifiable under a surgical microscope. Suami refined his method using an extruded glass tube for cannulation into smaller lymphatic vessels with calibers below 0.3 mm³⁸ (► Fig. 6).

Since Sappey depicted the anatomy of the lymphatic system in an atlas in the late 19th century, there have been few updates regarding lymphatic mapping of the whole body. However, there has been an increasing demand for an accurate map of the lymphatic system because this anatomical information helps to predict cancer metastasis including sentinel node biopsy and aids the understanding of pathological changes occurring in lymphedema. Thus, Suami introduced the "lymphosome" concept in 2017 that provided color-coded lymphatic territories demarcated by corresponding groups of lymph nodes.³⁹

Clinical Imaging of Lymphatic Vessels

Lymphatic vessels have a thin wall and small diameter and transport clear lymph fluid. These characteristics make them

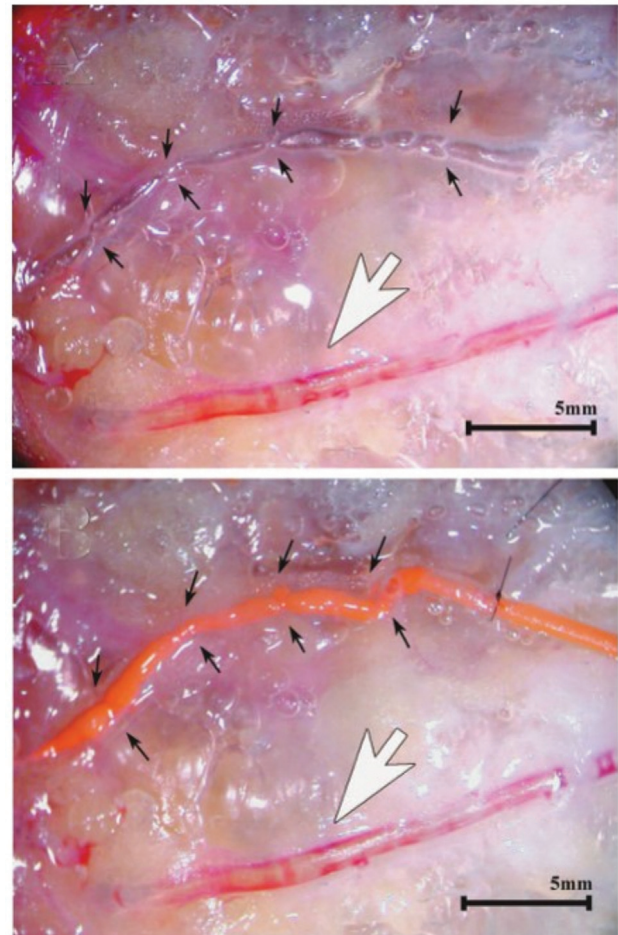


Fig. 6 Suami's injection technique using hydrogen peroxide. Lymphatic vessels (small black arrows) and veins (large white arrows) have been inflated with (above) hydrogen peroxide and were injected with (below) radiopaque lead oxide. (From Suami H, Taylor GI, Pan W-R. Refinements of the radiographic cadaver injection technique for investigating minute lymphatic vessels. Plastic and Reconstructive Surgery. 2007;120(1):61-7, with permission.)

difficult to locate and cannulate for angiographic techniques. Therefore, imaging techniques rely on the spontaneous ability of lymphatic vessels to absorb the injected tracers into the interstitial tissue space.

Hudack and McMaster intradermally injected patent blue violet into their arms to visualize lymphatic capillaries.⁴⁰ Kinmonth developed the lymphangiography technique in 1952⁴¹ (► Fig. 7). He used patent blue violet to identify a lymphatic vessel in the dorsum of the hand and foot, cannulated a fine needle into the vessel, and injected radiocontrast media.

Walker first used nuclear radiotracers to map lymphatic drainage in 1950.⁴² Sherman and Ter-Pogossian showed that colloidal gold could be traced from the point of intradermal injection to the regional lymph nodes in 1953.⁴³ Sage and Gozun reported using colloidal protein labeled with gold¹⁹⁸ in a dog to obtain images of lymphatic scintigraphy.⁴⁴ Lymphoscintigraphy was initially performed for the evaluation of lymphedema⁴⁵ and visualization of internal mammary lymph nodes in patients with breast cancer.⁴⁶

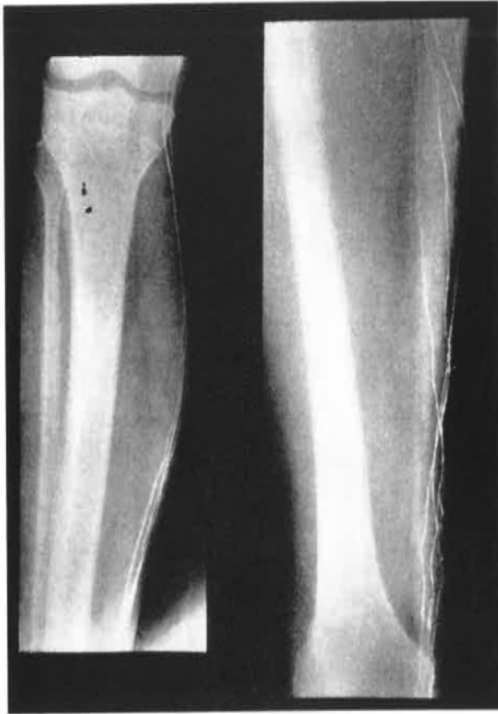

Fig. 7 Kinmonth's lymphangiography technique. Diodone was injected to exposed lymphatic on the dorsum of the foot. (From Kinmonth JB. Lymphangiography in man; a method of outlining lymphatic trunks at operation. *Clinical Science*, 11(1), 13–20, with permission.)

Single-photon emission computed tomography (SPECT) uses triangulation of data from multiple detectors to reconstruct a 3D image of a radiotracer.⁴⁷ SPECT/CT has been developed to improve the poor spatial resolution of SPECT; it is useful in analyzing lymph drainage and identifying sentinel lymph nodes.^{48,49}

Ogata et al., first reported the clinical application of ICG lymphography with near-infrared imaging for mapping the lymphatic vessels in lymphedema in 2007.^{50,51} ICG lymphography was able to demonstrate the lymphatics in real time without exposure to radiation. Unno et al described the use of ICG lymphography for diagnosing lymphedema of the lower extremity and described the four abnormal patterns of lymph drainage identified in the patients.⁵²

Liu and Wang introduced contrast-enhanced magnetic resonance lymphography (MRL) for the diagnosis of lymphatic disorders as well as dilated lymphatic collectors in 1996.⁵³ They improved the quality of the lymphatic vasculature images obtained with the 3D construction technique.⁵⁴ 3D MRL provided information on the altered lymphatic anatomy and the soft tissue changes in lymphedema. During acquisition of MR lymphangiography, venous enhancement can load interpretative challenges in differentiating enhancing lymphatic channels from superficial veins. Mitsumori et al introduced incorporation of a delayed MR venogram to the examination protocol, or using iron-based blood-pool contrast agent (Ferumoxytol) to selectively remove venous signal to create a lymphatic-only image.⁵⁵

Kajita and Kishi used a 3D photoacoustic imaging (PAI) system to visualize lymphatic and venous systems with diameters of up to 0.2 mm.⁵⁶ The imaging system (PAL, photoacoustic lymphangiography) enabled the differentiation of lymphatic vessels from blood vessels by assigning different color codes.^{57,58} (– Fig. 8). The multispectral optoacoustic imaging tomography system uses the same technology but has a hand-held probe similar to that used in ultrasound.⁵⁹ Both PAI devices use ICG as a contrast medium for demonstrating lymphatic vessels and simultaneously obtaining 3D images of the vein.^{57,58,60} The outstanding features of PAL allow direct observation of lymphaticovenous anastomosis and postoperative patency. However, PAI can degrade image quality in areas with thick subcutaneous tissue commonly seen in patients with lymphedema due to light penetration. Also, differences in the sound velocity in tissues can interfere with the reconstruction of clear images in the intensity of the PA signal.⁶¹ PAI is an emerging technology currently in development.

Conclusion

The evolution of our understanding of microvascular and lymphatic anatomy in plastic surgery has been made possible by the chronological accumulation of knowledge, progress of research methods, and technological advancement of imaging devices. This achievement was also supported by extensive efforts from numerous anatomists and scientists. Plastic surgeons and trainees should be aware and be respectful of the landmark studies described in this article. Further advancement in the field of vascular anatomy would be built upon these pioneering works.

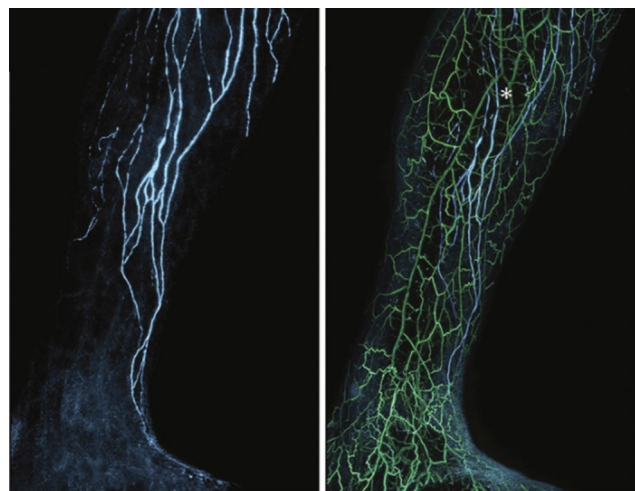


Fig. 8 Kajita's visualization of lymphatic and venous system with three-dimensional (3D) photoacoustic imaging system. Multiple lymphatic vessels (blue) and veins (green) are shown with 3D relationship. (From Suzuki Y, Kajita H, Konishi N, et al. Subcutaneous lymphatic vessels in the lower extremities: Comparison between photoacoustic lymphangiography and near-infrared fluorescence lymphangiography. *Radiology*. 2020;295(2):469–74, with permission.)

Authors' Contribution

Conceptualization: Suami H, Chang H. Funding acquisition: Chang H. Methodology: Koo HT, Park SO. Writing – original draft: Woo SJ. Writing review & editing: Woo SJ, Suami H, Chang H.

Conflict of Interest

Hak Chang is an editorial board member of the journal but was not involved in the peer reviewer selection, evaluation, or decision process of this article. No other potential conflicts of interest relevant to this article were reported.

References

- Bhishagratna KL An English translation of The Sushruta Samhita: based on original Sanskrit text: author; 1911
- Gillies H, Millard DR The Principles and Art of Plastic Surgery: Butterworth; 1957
- Aird WC. Discovery of the cardiovascular system: from Galen to William Harvey. *J Thromb Haemost* 2011;9(Suppl 1):118–129
- Manchot C, ed. Die Hautarterien de Menschlichen Korpers Leipzig: FCW Vogel; 1889
- Manchot C. The cutaneous arteries of the human body. translated by Ristic J and Morain WD. 1983:105–114
- Salmon M, Dor J Les artères des muscles des membres et du tronc: Masson; 1933
- Salmon M Artères des muscles de la tête et du cou: Masson; 1936
- Nakajima H, Maruyama Y, Koda E. The definition of vascular skin territories with prostaglandin E1—the anterior chest, abdomen and thigh-inguinal region. *Br J Plast Surg* 1981;34(03):258–263
- Cormack GC, Lamberty BG. The arterial anatomy of skin flaps. The Arterial Anatomy of Skin Flaps: Publisher: Churchill Livingstone, 1994:538
- Taylor GI, Palmer JH. The vascular territories (angiosomes) of the body: experimental study and clinical applications. *Br J Plast Surg* 1987;40(02):113–141
- Taylor GI, Daniel RK. The free flap: composite tissue transfer by vascular anastomosis. *Aust N Z J Surg* 1973;43(01):1–3
- Boyd JB, Taylor GI, Corlett R. The vascular territories of the superior epigastric and the deep inferior epigastric systems. *Plast Reconstr Surg* 1984;73(01):1–16
- Reid CD, Taylor GI. The vascular territory of the acromiothoracic axis. *Br J Plast Surg* 1984;37(02):194–212
- Palmer JH, Taylor GI. The vascular territories of the anterior chest wall. *Br J Plast Surg* 1986;39(03):287–299
- Geddes CR, Morris SF, Neligan PC. Perforator flaps: evolution, classification, and applications. *Ann Plast Surg* 2003;50(01):90–99
- Tang M, Yin Z, Morris SF. A pilot study on three-dimensional visualization of perforator flaps by using angiography in cadavers. *Plast Reconstr Surg* 2008;122(02):429–437
- Saint-Cyr M, Wong C, Schaverien M, Mojallal A, Rohrich RJ. The perforasome theory: vascular anatomy and clinical implications. *Plast Reconstr Surg* 2009;124(05):1529–1544
- Spalteholz W. Die Verteilung der Blutgefäße in der Haut. *Arch. f. Anat. u. Phys. Anat. Abt* 1893;1.
- McGregor IA, Morgan G. Axial and random pattern flaps. *Br J Plast Surg* 1973;26(03):202–213
- Narushima M, Yamasoba T, Iida T, et al. Pure skin perforator flaps: the anatomical vascularity of the superthin flap. *Plast Reconstr Surg* 2018;142(03):351e–360e
- Barr J. The anatomist Andreas Vesalius at 500 years old. *J Vasc Surg* 2015;61(05):1370–1374
- Harvey W The Circulation of the Blood (1628). Ed. Kenneth J. Franklin. Springfield, Illinois: Charles C. Thomas 1958
- Taylor GI, Caddy CM, Watterson PA, Crock JG. The venous territories (venosomes) of the human body: experimental study and clinical implications. *Plast Reconstr Surg* 1990;86(02):185–213
- Nakajima H, Imanishi N, Fukuzumi S, Minabe T, Aiso S, Fujino T. Accompanying arteries of the cutaneous veins and cutaneous nerves in the extremities: anatomical study and a concept of the venoadipofascial and/or neuroadipofascial pedicled fasciocutaneous flap. *Plast Reconstr Surg* 1998;102(03):779–791
- Nakajima H, Imanishi N, Fukuzumi S, et al. Accompanying arteries of the lesser saphenous vein and sural nerve: anatomic study and its clinical applications. *Plast Reconstr Surg* 1999;103(01):104–120
- Imanishi N, Nakajima H, Fukuzumi S, Aiso S. Venous drainage of the distally based lesser saphenous-sural veno-neuroadipofascial pedicled fasciocutaneous flap: a radiographic perfusion study. *Plast Reconstr Surg* 1999;103(02):494–498
- Chang H, Minn KW, Imanishi N, Minabe T, Nakajima H. Effect of venous superdrainage on a four-territory skin flap survival in rats. *Plast Reconstr Surg* 2007;119(07):2046–2051
- Imanishi N, Kishi K, Chang H, Nakajima H, Aiso S. Three-dimensional venous anatomy of the dermis observed using stereography. *J Anat* 2008;212(05):669–673
- 今西宣晶, 三鍋俊春, 福積聡, 血管解剖からみた超薄皮弁, 日本マイクロサージャリー学会会誌2018;31:109–113
- Grotte G. The discovery of the lymphatic circulation. *Acta Physiol Scand Suppl* 1979;463:9–10
- Foster M Lectures on the History of Physiology: CUP Archive; 2012
- Nuck A Adenographia curiosa et uteri foeminei anatome nova cum epistola ad amicum de inventis novis: Luchtmans
- Cruikshank W The anatomy of the absorbing vessels of the human body: G. Nicol; 1790
- Mascagni P, Sanctius C Vasorum lymphaticorum corporis humani historia et ichnographia: Ex typographia Pazzini Carli; 1787
- Sappey MPC Anatomie, physiologie, pathologie des vaisseaux lymphatiques considérés chez l'homme et les vertébratés: Adrien Delahaye; 1874
- Gerota D. Zur technigue der lymphgefessininjection. Eine neue injectionsmasser. *Polyehrome injection. Anal. Anz* 1896;12:216
- Suami H, Taylor GI, Pan W-R. A new radiographic cadaver injection technique for investigating the lymphatic system. *Plast Reconstr Surg* 2005;115(07):2007–2013
- Suami H, Taylor GI, O'Neill J, Pan WR. Refinements of the radiographic cadaver injection technique for investigating minute lymphatic vessels. *Plast Reconstr Surg* 2007;120(01):61–67
- Suami H. Lymphosome concept: Anatomical study of the lymphatic system. *J Surg Oncol* 2017;115(01):13–17
- Hudack SS, McMaster PD. The lymphatic participation in human cutaneous phenomena: a study of the minute lymphatics of the living skin. *J Exp Med* 1933;57(05):751–774
- Kinmonth JB. Lymphangiography in man; a method of outlining lymphatic trunks at operation. *Clin Sci* 1952;11(01):13–20
- Walker LA. Localization of radioactive colloids in lymph nodes. *J Lab Clin Med* 1950;36(03):440–449
- Sherman AI, Ter-Pogossian M. Lymph-node concentration of radioactive colloidal gold following interstitial injection. *Cancer* 1953;6(06):1238–1240
- Sage HH, Gozun BV. Lymphatic scintigrams: a method for studying the functional pattern of lymphatics and lymph nodes. *Cancer* 1958;11(01):200–203
- Weissleder H, Weissleder R. Lymphedema: evaluation of qualitative and quantitative lymphoscintigraphy in 238 patients. *Radiology* 1988;167(03):729–735
- Ege GN. Internal mammary lymphoscintigraphy. The rationale, technique, interpretation and clinical application: a review based on 848 cases. *Radiology* 1976;118(01):101–107
- Barrett T, Choyke PL, Kobayashi H. Imaging of the lymphatic system: new horizons. *Contrast Media Mol Imaging* 2006;1(06):230–245

- 48 Mar MV, Miller SA, Kim EE, Macapinlac HA. Evaluation and localization of lymphatic drainage and sentinel lymph nodes in patients with head and neck melanomas by hybrid SPECT/CT lymphoscintigraphic imaging. *J Nucl Med Technol* 2007;35(01):10-16, quiz 17-20
- 49 Basu S, Alavi A. Multifaceted role of lymphatic mapping by SPECT/CT hybrid imaging in the multimodality management of patients with cancer. *Eur J Nucl Med Mol Imaging* 2009;36(06):1017-1018
- 50 Narushima M, Yamamoto T, Ogata F, et al. Indocyanine green lymphography findings in limb lymphedema. *J Reconstruct Microsurg* 2016;32:072-9
- 51 Ogata F, Narushima M, Mihara M, Azuma R, Morimoto Y, Koshima I. Intraoperative lymphography using indocyanine green dye for near-infrared fluorescence labeling in lymphedema. *Ann Plast Surg* 2007;59(02):180-184
- 52 Unno N, Inuzuka K, Suzuki M, et al. Preliminary experience with a novel fluorescence lymphography using indocyanine green in patients with secondary lymphedema. *J Vasc Surg* 2007;45(05):1016-1021
- 53 Liu NF, Wang CG. The role of magnetic resonance imaging in diagnosis of peripheral lymphatic disorders. *Lymphology* 1998;31(03):119-127
- 54 Liu N, Wang C, Sun M. Noncontrast three-dimensional magnetic resonance imaging vs lymphoscintigraphy in the evaluation of lymph circulation disorders: A comparative study. *J Vasc Surg* 2005;41(01):69-75
- 55 Mitsumori LM, McDonald ES, Neligan PC, Maki JH. Peripheral magnetic resonance lymphangiography: techniques and applications. *Tech Vasc Interv Radiol* 2016;19(04):262-272
- 56 Kajita H, Kishi K. High-resolution imaging of lymphatic vessels with photoacoustic lymphangiography. *Radiology* 2019;292(01):35
- 57 Suzuki Y, Kajita H, Oh A, et al. Use of photoacoustic imaging to determine the effects of aging on lower extremity lymphatic vessel function. *J Vasc Surg Venous Lymphat Disord* 2022;10(01):125-130
- 58 Suzuki Y, Kajita H, Imanishi N, Aiso S, Kishi K. Observation of a lymphatic pump in a human by using photoacoustic imaging. *Plast Reconstr Surg Glob Open* 2020;8(06):e2914
- 59 Giacalone G, Yamamoto T, Belva F, Hayashi A. Bedside 3D visualization of lymphatic vessels with a handheld multispectral photoacoustic tomography device. *J Clin Med* 2020;9(03):815
- 60 Nagae K, Asao Y, Sudo Y, et al. Real-time 3D photoacoustic visualization system with a wide field of view for imaging human limbs. *F1000 Res* 2018;7:1813
- 61 Tsuge I, Saito S, Sekiguchi H, et al. Photoacoustic tomography shows the branching pattern of anterolateral thigh perforators in vivo. *Plast Reconstr Surg* 2018;141(05):1288-1292