



Literature Review: Role of Neurosurgery in Leptomeningeal Carcinomatosis

Crítica literária: Papel da neurocirurgia na Carcinomatose Leptomeníngea

Thaís Mitie Ogasawara^{1*} Thaís Yumi Kobayashi Batista¹ Rafael Rodrigues Pinheiro dos Santos¹
Ana Carla Mondek Rampazzo¹ Caroline Amane Pessoa Badaoui¹ Igor Ruan de Araújo Caetano¹
Jonathan Vinícius Martins¹ Maria Letícia Nogueira¹ José Ângelo Guarnieri²
Carlos Alexandre Martins Zicarelli^{3,4,5,6}

¹ Department of Neuroscience, Pontifícia Universidade Católica do Paraná, Londrina, Paraná, Brazil

² Neurosurgery Residency, Hospital Evangélico de Londrina, Londrina, Paraná, Brazil

³ Department of Neurosurgery, Hospital Evangélico de Londrina, Londrina, Paraná, Brazil

⁴ Medical Internship, Pontifícia Universidade Católica do Paraná, Londrina, Paraná, Brazil

Address for correspondence Thaís Mitie Ogasawara, Medical Student, Avenida Jockey Club, 485, 86072-360, Londrina, Paraná, Brazil (e-mail: mitiethaís@gmail.com).

⁵ Rehabilitation Science Program, Universidade Estadual de Londrina, Londrina, Paraná, Brazil

⁶ Department of Health and Rehabilitation, Universidade Norte do Paraná, Londrina, Paraná, Brazil

Arq Bras Neurocir 2023;42(4):e337–e342.

Abstract

Keywords

- ▶ neurosurgery
- ▶ leptomeningeal carcinomatosis
- ▶ cerebrospinal
- ▶ treatment

Introduction Leptomeningeal carcinomatosis results from metastatic neoplastic cells that reach the leptomeninges through the cerebrospinal fluid. The presentation of the disease is variable, making prognosis challenging. However, the presence of intracranial hypertension is common, which has prompted new treatments to mitigate this effect.

Objective To report the role of neurosurgery in the treatment of leptomeningeal carcinomatosis, as well as its advances.

Methodology Literature review with a search of the PubMed database, between 2011 and 2021, using the following descriptors: *Neurosurgery*, *Leptomeningeal Carcinomatosis*, *Cerebrospinal* and *Treatment*. A total of 42 articles were found, 16 of which were selected.

Results The shunt insertion considerably improved the effects of cranial hypertension, increasing the average survival time of patients by 3.5 months after surgery. The

* Thaís Mitie Ogasawara and Thaís Yumi Kobayashi Batista collected data and wrote the manuscript.

Ana Carla Mondek Rampazzo, Caroline Amane Pessoa Badaoui, Igor Ruan de Araújo Caetano, Jonathan Vinícius Martins and Maria Letícia Nogueira collected data. Rafael Rodrigues Pinheiro dos Santos, José Ângelo Guarnieri and Carlos Alexandre Martins Zicarelli guided the study and reviewed the manuscript.

received

April 17, 2022

accepted

July 12, 2022

article published online

October 18, 2023

DOI <https://doi.org/>

10.1055/s-0042-1758210.

ISSN 0103-5355.

© 2023. Sociedade Brasileira de Neurocirurgia. All rights reserved.

This is an open access article published by Thieme under the terms of the Creative Commons Attribution-NonDerivative-NonCommercial-License, permitting copying and reproduction so long as the original work is given appropriate credit. Contents may not be used for commercial purposes, or adapted, remixed, transformed or built upon. (<https://creativecommons.org/licenses/by-nc-nd/4.0/>)

Thieme Revinter Publicações Ltda., Rua do Matoso 170, Rio de Janeiro, RJ, CEP 20270-135, Brazil

Ommaya reservoir is also a viable option due to its convenience and safety. The V-Port, on the other hand, has overcome the challenges of conventional devices, with shorter operating times (42 minutes), smaller skin incisions, and no reports of postoperative infection.

Conclusion Devices for the treatment of leptomeningeal carcinomatosis have been steadily improving, simplifying surgical procedures and benefiting patients.

Resumo

Introdução A carcinomatose leptomeníngea resulta de células neoplásicas metastáticas que atingem as leptomeninges através do líquido cefalorraquidiano. A apresentação da doença é variável, tornando o prognóstico desafiador. No entanto, a presença de hipertensão intracraniana é comum, o que levou a novos tratamentos para mitigar esse efeito.

Objetivo Relatar o papel da neurocirurgia no tratamento da carcinomatose leptomeníngea, bem como seus avanços.

Metodologia Crítica literária com busca na base de dados PubMed, entre 2011 e 2021, utilizando os seguintes descritores: Neurocirurgia, Carcinomatose Leptomeníngea, Cefalorraquidiana e Tratamento. Foram encontrados 42 artigos, dos quais 16 foram selecionados.

Resultados A inserção do shunt melhorou consideravelmente os efeitos da hipertensão craniana, aumentando o tempo médio de sobrevivência dos pacientes em 3,5 meses após a cirurgia. O reservatório de Ommaya também é uma opção viável devido à sua conveniência e segurança. O V-Port, por outro lado, superou os desafios dos dispositivos convencionais, com tempos de operação mais curtos (42 minutos), incisões cutâneas menores e sem relatos de infecção pós-operatória.

Conclusão Os dispositivos para o tratamento da carcinomatose leptomeníngea vêm melhorando constantemente, simplificando os procedimentos cirúrgicos e beneficiando os pacientes.

Palavras-chave

- ▶ neurocirurgia
- ▶ carcinomatose leptomeníngea
- ▶ cefalorraquidiano
- ▶ tratamento

Introduction

Leptomeningeal carcinomatosis (LC) was first reported in 1870 by the Swiss pathologist Karl Joseph Ebert as an attack on the meninges by metastatic tumors.¹ In the first publication on this disease, Ebert highlighted that the absence of localized signs and its variable nature made diagnosis difficult.² Then, in 1902, the term leptomeningeal carcinomatosis was proposed by Siefert, who described its clinical presentation.¹

Leptomeningeal carcinomatosis, also known as meningeal metastasis, is a consequence of tumors that metastasize. The main tumors capable of evolving into a this metastasis are lung cancer, breast cancer, and malignant melanoma.^{3,4} The most common symptoms include headache, nausea, and vomiting.⁵ Some cases may also include fever, relative devascularization, signs of meningeal irritation, increased stiffness, and alteration of the cranial nerves; furthermore, in more severe cases, convulsions and changes in the level of consciousness may occur.³ It is well known that the majority of symptoms presented by patients are a consequence of increased intracranial pressure (ICP) and the presence of hydrocephalus (HCP). Moreover, the increase in ICP and HCP reduces the effectiveness of treatment (uneven distribution

of drugs given via intrathecal or intraventricular administration) and contributes to a poor prognosis in patients with leptomeningeal carcinomatosis.⁵

The most important diagnostic measures are clinical evaluation, magnetic resonance imaging (MRI), and analysis of the cerebrospinal fluid (CSF), as it is extremely important to perform a full neurological examination to correctly identify the pathology.^{6,7} Disease progression can be well demonstrated through MRI, which is considered useful for the diagnosis of this disease.⁸ Additionally, leptomeningeal carcinomatosis is being increasingly diagnosed in patients with cancer due to improved detection through the routine use of MRI.^{9,10} It is important to stress that, in some cases, the diagnosis may not be totally accurate, when the disease is not suspected or when there are flaws in the imaging examinations.¹¹

The incidence of leptomeningeal carcinomatosis normally varies according to the type of primary tumor, occurring in approximately 5 to 8% of patients with solid tumors and 5 to 15% of patients with hematologic neoplasia. Although nearly all systemic tumors metastasize into leptomeninges, the most common solid tumors in these instances include lungs, breasts, and melanoma. Incidence by tumor type is 5 to 8% for metastatic cancers of the breast, 9 to 25% for cancer of the

lungs (greater in small-cell lung carcinomas), and 6 to 18% for melanomas.¹²

As far as survival rates are concerned, approximately 10% may survive for a year, though this varies according to the type of primary tumor.⁶ However, neither age nor gender were related to survival.¹³ On the other hand, the average survival period of leptomeningeal metastasis patients who do not receive treatment is just 4 to 6 weeks, though survival may be extended to between 4 and 6 months, depending on the treatment afforded.¹¹

The available options for the treatment of leptomeningeal metastasis are intrathecal (IT) chemotherapy, systemic therapy, radiotherapy, and surgery. In the case of HCP or symptoms resulting from focal lesions, surgery, and radiotherapy are recommended.¹¹ The factors influencing the choice of treatment depend on the type of primary tumor and the attack pattern of the disease. Accordingly, treatment must be personalized.⁶

Of the surgical methods available, the CSF shunt is an effective palliative procedure, capable of alleviating the symptoms and improving patients' quality of life.^{14,15} Various shunt types exist, including the ventriculoperitoneal shunt (VPS) and the lumboperitoneal shunt (LPS). Both safely divert the flow of CSF from a ventricle or spinal arachnoid space to the peritoneal space. The indication for each shunt type should be made according to patients' condition, with the LPS being more suitable when communicating HCP is involved, and when the patient cannot be subjected to cranial surgery. The VPS, on the other hand, does not possess so many restrictions and may be used regardless of whether the HCP is communicating or noncommunicating.⁵

Accordingly, the aim of this study is to perform a literature review on the role of neurosurgery in the treatment of leptomeningeal carcinomatosis, to explain the advances and new possibilities that have been emerging for the treatment of the disease in the surgical setting.

Methodology

For the bibliographic review, a search of the PubMed database was made, encompassing publications between 2011 and 2021. The following descriptors were employed: *neurosurgery*, *leptomeningeal carcinomatosis*, *cerebrospinal*, and *treatment*. In total, there were 42 results, from which 16 articles were selected. Among the 26 articles that were excluded, 25 did not involve surgical treatment, and 1 was unavailable.

Results

Of the 16 articles selected for the current review, 9 produced consistent results and showed detailed data of the operations, as displayed in **Table 1**, 7 dealt with VPS and LPS, 1 was a case report on the Ommaya reservoir, and 1 was a case series study in respect of the V-Port.

In terms of shunt insertion technique, according to the literature analyzed, an improvement was seen in patients' conditions with increased rates of survival. In the retrospec-

tive study conducted by Zhao et al., in which 6 individuals were assessed, it was possible to note a reduction in intracranial hypertension, which consequently improved patients' quality of life.¹⁷

Additionally, according to the retrospective analysis of Kim et al.,⁵ and the systematic review of Yoshioka et al., analyzing 70 and 14 individuals respectively, the shunt was effective in the treatment of HCP, improving patients' symptoms and prolonging their life expectancy.

In the study published by Murakami et al.,¹⁴ it was shown that 87.5% (7/8) of patients obtained an improvement in headaches after the shunt had been inserted. Moreover, according to Lin et al.,¹⁹ in their case-control study with a sample of 42 individuals, the insertion of the shunt had a significant impact on increased patient survival rates. In the systematic review conducted by Mitsuya et al.,¹¹ an average increase in life expectancy of 3.5 months was observed, postsurgery.

Thus, it is possible to determine that shunt surgery is effective in the treatment of the signs and symptoms of leptomeningeal carcinomatosis. According to the results of the study conducted by Le Rhun et al.,¹⁰ the symptoms of 93% of patients improved on using the ventriculoperitoneal shunt.

Regarding complications involving shunt, the main ones listed by Kim et al.⁵ involves hemorrhages, infections, shunt malfunction and risk of transferring cancerous cells to the peritoneal region. In their study, 51 patients underwent VPS, and 19 LPS, with 8 patients developing infections. Additionally, there was a need to review the procedure in 24% of the patients, either due to malfunction, infection, or symptoms of excessive drainage; 6 patients required a second revision surgery and 2 required a third.

As for the comparison of results obtained between the VPS and LPS, Kim et al.⁵ observed that there was no significant difference in mean survival between patients undergoing VPS and LPS procedures. On the other hand, patients who underwent LPS required more evaluations for surgical revision, due to higher rates of malfunction and infection, according to a study by Kim et al.⁵ Therefore, in the review by Zhao et al.,¹⁷ they pointed out advantages in cooperate the use of LPS with Ommaya reservoirs.

In the study by Li et al.,¹⁸ the Ommaya reservoir was considered a safe option for administering IT chemotherapy, all the more so when compared with administration via lumbar puncture. Other studies did not note any complications relating to the Ommaya reservoir. The advantages include it being a safer, more convenient procedure, with minimal pain for the patient and the possibility of draining the CSF with the device, if necessary.

According to Byun et al.,⁹ the average duration of surgery is 16 to 38 minutes. Regarding the main complications, in the studies by Murakami et al.¹⁴ and Magill et al.,¹⁶ there were no reports of complications such as infection, misalignment or obstruction of the tube, intracranial hematoma, or liquor fistula. The incidence of infection was relatively low, all the more so when compared with the LPS, ranging from 5% to 8%. There was no need for revision surgery, in patients who received the Ommaya reservoir, 7.5% required revision surgery for VPS insertion due to an increase in ICP.

Table 1 Description of operations found in the literature

Author	Type of study	Sample	Operation	Outcome
Zhao et al. (2017)	Retrospective analysis	6	Shunt	Alleviation of ICP, reduction in mortality and incapacity through intracranial hypertension, and improved quality of life in patients with cancer.
Seon et al. (2019)	Retrospective analysis	70	Shunt	80% died during the follow-up period, 48% due to progression of the LC and 23% due to progression of the systemic disease; the reason for death was unspecified in 29% of cases. The VPS or LPS are effective for patients with HCP. There was an acceptable level of complications.
Murakami et al. (2018)	Clinical study	11	Shunt	An improvement in symptoms was observed in 9 patients, and severe headache relief was reported in 7 of the 8 patients. This is an effective palliative surgical option for alleviating the symptoms.
Lin et al. (2011)	Retrospective case-control study	24	VPS	The insertion of the VPS resulted in a very low rate of postoperative complications (8.3%), as well as the absence of infection and no perioperative deaths. The patients enjoyed a longer overall average survival.
Yoshioka et al. (2021)	Systematic review of case series	14	Shunt	The shunt is an effective procedure, including for the palliative treatment of HCP symptoms.
Mitsuya et al. (2019)	Systematic review of case series	31	Shunt	There was a functional improvement of 90.3% in patients, with an increase in survival of 3.5 months after shunt surgery.
Byun et al. (2018)	Case series	9	V-Port	This implantable reservoir was superior to the others as it is safe, easy to palpate and more durable to large-bore needles.
Li et al. (2020)	Case report	1	Ommaya reservoir	The Ommaya reservoir had a positive effect when used to administer IT chemotherapy.
Le Rhun et al. (2016)	Systematic review of case series	59	VPS	Symptoms improved in 93% of the patients; complications were observed in 11.8% of the patients.

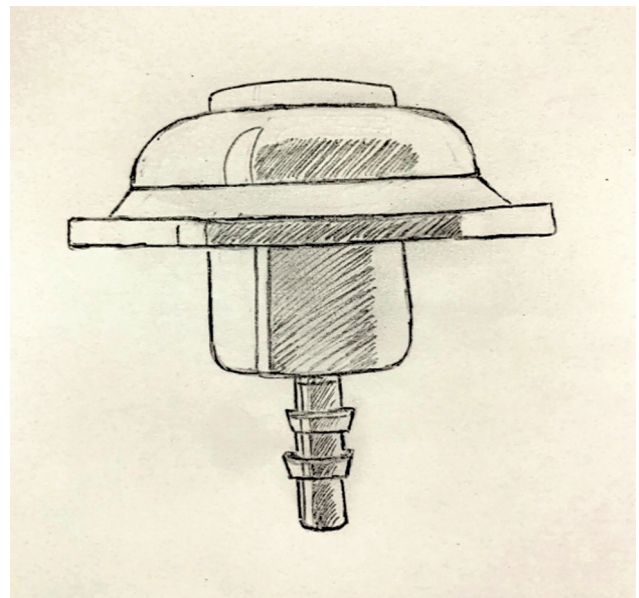
Abbreviations: HCP, hydrocephalus; ICP, intracranial pressure; IT, intrathecal; LC, leptomeningeal carcinomatosis; LPS, lumboperitoneal shunt; VPS, ventriculoperitoneal shunt.

With the aim of refining the existing implantable reservoirs, Byun et al.⁹ evaluated the V-Port (► **Fig. 1**), which demonstrated better performance than all the other options. It stood out on account of its safety and more simplified technical operation, with a low average duration of operation (42 min) and smaller skin incisions. Furthermore, the study did not observe complications such as infection, skin problems related to the V-Port, or postoperative intracranial hypertension. As for the need for revision surgery, out of a total of 9 patients, 7 (77.78%) were subjected to liquor drainage at least once to control ICP, and 2 patients (22.22%) did not have ICP controlled by intermittent drainage.

► **Table 1** summarizes the principal operations analyzed, indicating the study type, sample size, operation performed, and the respective outcome.

Discussion

Leptomeningeal carcinomatosis (LC) is the result of cancerous cells infiltrating the meninges, bringing about aseptic inflammation in these structures.¹⁷ The growth of these cells

**Fig. 1** Image of V-Port.

may be focal and/or diffuse, with the potential formation of different sizes of nodule.⁸ This condition continues to be one of the most challenging complications of cancer, as it involves a complex diagnostic process, poor prognosis, negative impact on patients' quality of life, and uncertain responses to cytotoxic treatment or standard targeted therapy.¹²

Treatment

Treatment options for leptomeningeal carcinomatosis have been limited to the effective administration of drugs, although not all patients achieve a good outcome with these types of therapy. Therefore, after the disease is diagnosed, the ideal treatment continues to be the consensus recommendation of specialists in the respective cases. However, although treatment options remain limited, advances in molecular and genetic studies into leptomeningeal carcinomatosis have been generating new, clinically effective treatment options, and better ways to predict patients' response to treatment.¹²

Ommaya Reservoir

One of the treatment options for leptomeningeal carcinomatosis is the administration of IT chemotherapy. This method manages to circumvent the blood-brain barrier and minimize the systemic side effects. The drugs may be administered via lumbar puncture or through the surgical insertion of a reservoir which, with the use of a catheter, directly feeds the ventricular system (Ommaya reservoir). The most commonly used drugs are methotrexate (a folate antagonist), thiotepa (an alkylating agent), cytarabine (a pyrimidine analogue), and sustained-release liposomal cytarabine.¹²

In a retrospective analysis of 50 patients, 34 received treatment (IT chemotherapy with liposomal cytarabine or methotrexate, systemic chemotherapy, or radiotherapy) and 16 simply received support and palliative measures. The results showed that overall average survival for patients receiving treatment was 21.2 weeks, compared with 6.38 weeks for patients who did not treat the disease.¹³

Various retrospective studies have demonstrated the positive impact on the survival rates of patients receiving conventional chemotherapy treatment.¹² However, in the quest to find more effective drugs, the study conducted by Yoshioka reported survival of a year for patients who received targeted molecular treatment postoperatively, compared with 3.7 months for patients receiving only radiotherapy.

There are limitations to the conventional methods of antineoplastic treatments, given that they are incapable of attaining effective concentrations due to the blood-brain barrier. Accordingly, Ommaya reservoirs tend to be more advantageous in administering IT chemotherapy, both in terms of the operation and the safety of the patient.¹⁸

Thus, the insertion of an Ommaya reservoir for LC is a surgical option for the administration of IT chemotherapy. However, one study found that 8 out of 107 patients (7.5%) who received the Ommaya reservoir for LC-related HCP, required revision surgery to insert a VPS due to the increase in ICP.¹⁴

Ventriculoperitoneal Shunt (VPS) and Lumboperitoneal Shunt (LPS)

As far as the surgical insertion of shunts is concerned, studies have shown that this technique can alleviate symptoms arising from high ICP. Of the 5 patients treated using shunt surgery, observed in a retrospective analysis, all of them displayed the shunt in the computed tomography of the skull after the operation. The positioning of the tube was correct and there was no operative bruising. Furthermore, no shunt-related infections were reported for any of the patients.¹⁷

One study indicated there are three aspects that contribute to a better outcome after shunting, namely: treatment with TKIs (Epidermal growth factor receptor [EGFR] tyrosine kinase inhibitors), good ECOG (Eastern Cooperative Oncology Group) performance status (the scale evaluates how the disease affects patients' everyday life skills) and controlled extracranial cancer. Of the two shunt types, lumboperitoneal and ventriculoperitoneal, the former is more effective in unfavorable conditions, precisely because it is less invasive than the latter.¹¹

The VPS technique was assessed in 59 patients suffering from leptomeningeal carcinomatosis with a condition of HCP, 40 with brain metastasis and 19 with primary brain tumors. The average duration of the surgery was 50.4 minutes. Symptoms improved in 93% of the patients. Following an average follow-up of 6.3 months, 7 patients suffered complications (11.8%). The average survival of patients who received the shunt was 6.4 months. The LPS, which is less invasive, is also a good option for the treatment of intracranial hypertension.¹⁰

Even though shunt surgery is a relatively simple neurosurgical procedure, the number of patients receiving it is lower than the rate of increase in ICP. As the prognosis of patients with LC is poor, for the most part the treatment of choice is not surgical intervention. Moreover, complications with hemorrhaging, infection, shunt malfunction, and the risk of transferring cancerous cells to the peritoneal region cause some doctors to opt not to carry out CSF shunts on their patients.⁵

In one study, 70 patients who had previously had cancer (lung cancer, breast cancer, among others) were analyzed. The main brain tumors were glioma and medulloblastoma. A total of 51 patients received a VPS, while 19 had a LPS. Following surgery, preoperative symptoms diminished in 35 patients, remained stable in 24, and did not improve in 11 patients. Shunt malfunctions and infections occurred in 8 patients, and 17 patients had to be assessed due to shunt malfunction or excessive drainage. Average overall survival was 8.7 months from the diagnosis of LC and 4.1 months after shunt surgery.⁵

Both the VPS and the LPS succeeded in safely diverting the flow of CSF from a ventricle or spinal arachnoid space to the peritoneal space. Each shunt system has its advantages and disadvantages, and, for this reason, the choice should be tailored to each patient. In general, the LPS is used in cases of communicating HCP and in patients who are not suitable for cranial surgery (i.e., idiopathic intracranial hypertension with ventricular cleft) or who wish to avoid cranial surgery. The VPS, on the other hand, can be used regardless of whether the HCP is communicating or noncommunicating.⁵

A study analyzed shunt surgeries performed on 11 patients with an average age of 58. The average Karnofsky performance status (KPS) was 40; 8 patients (73%) were treated with the VPS and 3 (27%) with the LPS. There were no reports of postoperative infections in any of the patients. The average KPS was 60 after shunt surgery. Furthermore, none of the patients developed infiltration of cancerous cells to the peritoneal region after surgery.¹⁴

It may be concluded, therefore, that surgery to insert the VPS or LPS shunt is useful for patients with HCP caused by LC, improving their symptoms and prolonging overall survival.⁵ The shunt proved to be an effective therapeutic procedure with regard to the alleviation of symptoms given that 100% of patients showed improved KPS.¹⁵ Therefore, this procedure should be considered for palliative surgical treatment of leptomeningeal carcinomatosis.¹⁴

Advances in Treatment

New improved techniques aiming to diverting CSF are in development, one of which is the insertion of an on/off valve in conjunction with the programmable ventriculoperitoneal valve (RO-VPS). The major advantage of this system is its reduced handling, as well as enabling the management of the concentration of chemotherapy drugs in the CSF in a more stable way.¹⁹

To overcome the obstacles involved with the Ommaya reservoir, Byun et al. developed the V-port, which is equipped with a noncollapsible port with a titanium connector where the ventricular catheter is inserted. This device is made out of polysulfones and epoxy instead of silicon, making it more durable to the various bores and larger needles, as well as being more easily palpated and having a lower risk of drug leakage. It also stood out because of the short duration of operations reported by neurosurgeons, the absence of complications resulting from the V-Port, and the lack of malfunction complaints.⁹

Treatment Decision

Lastly, whenever viable, treatment with the intraventricular shunt was the preferred option over IT therapy in the lumbar region, as per the study performed. In the event of shortcomings with lumbar puncture, 22.5% preferred IT chemotherapy and only 15.5% believed that radiotherapy should always be performed.⁶

Conclusion

Leptomeningeal carcinomatosis continues, therefore, to be a challenge to medicine due to the difficulty of diagnosis and treatment. However, it should be noted that the field of neurosurgery has been developing techniques capable of improving its clinical condition and increasing both the quality of life and life expectancy of patients. Furthermore, the available neurosurgical procedures have different purposes. Shunts are considered an effective option in the management of HCP, while reservoirs are used for infusion of drugs and are not very viable for the treatment of HCP. Therefore, neurosurgery plays a significant role in the treat-

ment of meningeal carcinomatosis, precisely because it is able to improve the patients' prognosis.

References

- Martins, Sandro José, et al. Meningeal carcinomatosis in solid tumors. *Arquivos de Neuro-Psiquiatria* [online] 2011 v. 69, n. 6 Accessed 21 October 2022, at: <https://doi.org/10.1590/S0004-282X2011000700024>. pp. 973-980. Epub 27 Jan 2012. ISSN 1678-4227
- Valença A, Bravo Marques JM. Carcinomatose meníngea - casuística de um ano: revisão de Literatura. Vol. 6. 1989.
- Shinohara M, Kiba K, Yamada A, et al. A case of difficult-to-diagnose carcinomatous meningitis caused by prostate cancer metastasis. *Hinyokika Kyo* 2016;62(05):265-269
- Ha B, Chung SY, Kim YJ, et al. Effects of postoperative radiotherapy on leptomeningeal carcinomatosis or dural metastasis after resection of brain metastases in breast cancer patients. *Cancer Res Treat* 2017;49(03):748-758
- Kim HS, Park JB, Gwak HS, Kwon JW, Shin SH, Yoo H. Clinical outcome of cerebrospinal fluid shunts in patients with leptomeningeal carcinomatosis. *World J Surg Oncol* 2019;17(01):59
- Le Rhun E, Rudà R, Devos P, et al. Diagnosis and treatment patterns for patients with leptomeningeal metastasis from solid tumors across Europe. *J Neurooncol* 2017;133(02):419-427
- Sekhar A, Corbo B, Das K, Biswas S. Leptomeningeal carcinomatosis: easy to miss. *J R Coll Physicians Edinb* 2017;47(04):351-352
- Chen G, Ma L, Xu M, et al. Meningeal carcinomatosis: three case-reports. *World J Surg Oncol* 2018;16(01):78
- Byun YH, Gwak HS, Kwon JW, et al. A novel implantable cerebrospinal fluid reservoir: A pilot study. *J Korean Neurosurg Soc* 2018; 61(05):640-644
- Le Rhun E, Galanis E. Leptomeningeal metastases of solid cancer. Vol. 29, *Current Opinion in Neurology*. Lippincott Williams and Wilkins; 2016. p. 797-805.
- Mitsuya K, Nakasu Y, Hayashi N, et al. Palliative cerebrospinal fluid shunting for leptomeningeal metastasis-related hydrocephalus in patients with lung adenocarcinoma: A single-center retrospective study. *PLoS One* 2019;14(01):e0210074
- Wang N, Bertalan MS, Brastianos PK. Leptomeningeal metastasis from systemic cancer: Review and update on management. Vol. 124, *Cancer*. John Wiley and Sons Inc.; 2018. p. 21-35.
- Palma JA, Fernandez-Torron R, Esteve-Belloch P, et al. Leptomeningeal carcinomatosis: prognostic value of clinical, cerebrospinal fluid, and neuroimaging features. *Clin Neurol Neurosurg* 2013; 115(01):19-25. Doi: 10.1016/j.clineuro.2012.03.048 [Internet]
- Murakami Y, Ichikawa M, Bakhit M, et al. Palliative shunt surgery for patients with leptomeningeal metastasis. *Clin Neurol Neurosurg* 2018;168:175-178
- Yoshioka H, Okuda T, Nakao T, Fujita M, Takahashi JC. Effectiveness of Palliative Cerebrospinal Fluid Shunting for Patients With Leptomeningeal Carcinomatosis-related Hydrocephalus. *Anticancer Res* 2021;41(08):4169-4172
- Magill ST, Choy W, Nguyen MP, McDermott MW. Ommaya Reservoir Insertion: A Technical Note. *Cureus* 2020;12(04):e7731
- Zhao J, Liu J, Zhang Z, et al. [Experience of shunting surgery in treatment for meningeal carcinomatosis]. *Zhong Nan Da Xue Xue Bao Yi Xue Ban* 2017;42(02):236-240
- Li H, Lin Y, Yu T, et al. Treatment response to intrathecal chemotherapy with pemetrexed via an Ommaya reservoir in EGFR-mutated leptomeningeal metastases from non-small cell lung cancer: a case report. *Ann Palliat Med* 2020;9(04): 2341-2346
- Lin N, Dunn IF, Glantz M, et al. Benefit of ventriculoperitoneal cerebrospinal fluid shunting and intrathecal chemotherapy in neoplastic meningitis: a retrospective, case-controlled study. *J Neurosurg* 2011;115(04):730-736