



Case Series of Right Colon Diverticulitis in the West: A Neglected Disease?

Lucas Faraco Sobrado^{1,2} Tarsila Gomes Caldas¹ Carolina Gracioli Facanali¹
Leonardo Bustamente-Lopez¹ Carlos Walter Sobrado^{1,2}

¹Division of Colorectal Surgery, Department of Gastroenterology, Hospital das Clínicas, Faculdade de Medicina, Universidade de São Paulo, São Paulo, São Paulo, Brazil

²Department of Oncology and Proctology, Instituto de Gastrocirurgia, Oncologia e Proctologia (IGOP), São Paulo, São Paulo, Brazil

Address for correspondence Carlos Walter Sobrado, PhD, Avenida Dr. Éneas de Carvalho Aguiar 255, São Paulo, SP, 05403-000, Brazil (e-mail: cwsobrado@hotmail.com; carlos.walter@hc.fm.usp.br).

J Coloproctol 2022;42(4):302–307.

Abstract

Introduction Right colon diverticulitis (RCD) is an uncommon condition in Western populations, but its incidence has increased over the last decades. Due to its rarity, many surgeons are unfamiliar with this disease, which is often mistakenly diagnosed as acute appendicitis. The lack of data about the diagnosis and management of RCD in Western populations makes it difficult to establish the optimal therapeutic strategy.

Objective To evaluate the outcomes of patients treated for acute RCD and to propose a therapeutic algorithm for the diagnosis and treatment.

Methods A retrospective analysis of the medical records of patients treated for acute RCD between 2008 and 2020 by a single experienced colorectal surgeon was performed.

Results In total, 12 patients were identified, 8 male and 4 female subjects, with a mean age of 49.6 years; 9 of these patients were of Western origin. The median follow-up time was of 49 months (range: 12 to 144 months). The most frequent symptoms were abdominal pain (100%) and fever (66%). Diagnostic errors in imaging exams occurred in four patients. A total of 6 patients were managed clinically, and the other 6 underwent surgical treatment with right colectomy ($n = 5$) and total colectomy ($n = 1$), 2 via laparoscopy and 4 through a laparotomy. The anatomopathological examination confirmed RCD in all operated patients. There was no incidental finding of neoplasia and there were no deaths during the study period.

Conclusion Uncomplicated RCD can be treated conservatively with a high success rate. Recurrent cases that impact quality of life or complicated forms of RCD should undergo surgical treatment, preferably through a right laparoscopic colectomy. The authors present a diagnostic and therapeutic algorithm to facilitate the diagnosis and to guide the management of this uncommon disease.

Keywords

- ▶ colon
- ▶ diverticulitis
- ▶ right colon diverticulitis
- ▶ classification
- ▶ treatment
- ▶ algorithm

received
August 12, 2022
accepted after revision
September 15, 2022

DOI <https://doi.org/10.1055/s-0042-1757953>.
ISSN 2237-9363.

© 2022. Sociedade Brasileira de Coloproctologia. All rights reserved.

This is an open access article published by Thieme under the terms of the Creative Commons Attribution-NonDerivative-NonCommercial-License, permitting copying and reproduction so long as the original work is given appropriate credit. Contents may not be used for commercial purposes, or adapted, remixed, transformed or built upon. (<https://creativecommons.org/licenses/by-nc-nd/4.0/>)

Thieme Revinter Publicações Ltda., Rua do Matoso 170, Rio de Janeiro, RJ, CEP 20270-135, Brazil

Introduction

Diverticular disease of the colon is a common condition with increasing incidence in the last decades, possibly related to changes in dietary and lifestyle patterns.¹ In Eastern populations, it is most commonly found in the right colon in up to 75% of the patients, while in the West it accounts for less than 5% of the cases.²⁻⁶

The treatment of right colon diverticulitis (RCD) depends largely on the experience of the surgeon, who is often much more familiarized with the management of left colon diverticulitis (LCD). However, approaching RCD as LCD may not be the best practice, since the clinical evolution of these two entities is distinct, and several articles have shown that RCD occurs in younger patients, and has a milder clinical course and a better response to conservative management, even in recurrent cases.⁶ While there are several guidelines that provide evidence for the best management of LCD, data regarding the treatment of RCD, especially in Western populations, is scarce.⁷⁻¹⁰

In the present study, we report our experience with the management of RCD, including diagnostic difficulties and treatment outcomes, and we propose a diagnostic and therapeutic algorithm.

Methods

We retrospectively analyzed the medical records of patients diagnosed with RCD between 2008 and 2020 who were treated by a single experienced colorectal surgeon, the senior author of the present manuscript. Data were collected regarding ethnicity, gender, age, comorbidities, clinical symptoms, diagnostic exams, treatment outcomes, number of relapses, and follow-up period. The study was approved by the Ethics Committee at our hospital (CAAE number: 52763521.4.0000.0068).

Results

We included 12 patients with RCD with a mean age of 49.6 years. In total, 8 patients were male, 9 were of Western origin, and 3 had clinical comorbidities, including obesity and arterial hypertension. All patients referred abdominal pain in the right iliac fossa, 8 (66%) had low-grade fever and 3 (25%) had nausea and vomiting. No patient presented with intestinal bleeding. The demographic and clinical data are summarized in ► **Table 1**.

Computed tomography (CT) of the abdomen was performed in 11 patients, and abdominal ultrasound, in 1. The CT findings suggested acute RCD in 8 cases, acute appendicitis in 2, and acute ileitis with a pericolic abscess suggesting Crohn's disease in 1 case. Abdominal ultrasound suggested acute appendicitis in 1 patient. In 7 subjects, the CT scan identified multiple diverticula throughout the right colon, and in 4, only an isolated diverticulum in the cecum.

Surgical treatment was undertaken in 6 patients (50%), 4 through laparotomy and 2 by laparoscopy. The surgical indications were: suspected acute appendicitis ($n = 3$), acute

Table 1 Demographic and clinical data of patients treated for right colon diverticulitis

Variable	n (%)
Total number of patients	12 (100)
Male/Female	8 (66)/4 (33)
Age in years: mean (range)	49.6 (29-72)
Ethnicity: Western/Eastern	9 (75)/3 (25)
Symptoms	
Abdominal pain	12 (100)
Fever	8 (66)
Nausea or vomiting	3 (25)
Diarrhea	2 (16)
Anorexia	2 (16)
Number of previous crises	
1	9 (75)
2	1 (8.3)
3	1 (8.3)
4 or more	1 (8.3)
Mean follow-up in months (range)	49 (12-144)

ileitis with pericolic abscess ($n = 1$), RCD complicated by pelvic abscess not amenable to percutaneous drainage ($n = 1$), and RCD with multiple previous crises that impaired quality of life ($n = 1$). Of these cases, five patients underwent right colectomy and one underwent total colectomy due to severe pandiverticulosis, all with primary anastomosis. One patient developed anastomotic fistula and was reoperated with the performance of a double-barrel ostomy. This patient underwent reconstruction of the intestinal transit after four months, without any further complications. The anatomic-pathological examination of all operated patients confirmed the diagnosis of acute RCD and none revealed malignancy.

The other 6 patients (50%) had uncomplicated RCD; they were treated with bowel rest and antibiotic therapy (intravenous ceftriaxone or ciprofloxacin plus metronidazole) and had good clinical response. Out of these six patients treated clinically, two had recurrent episodes of pain and one required re-hospitalization for clinical treatment, which was also successful. There were no deaths during follow-up.

Discussion

Relatively rare in the West, RCD accounts for 1% to 5% of patients with diverticular disease, while in the East it is responsible for 75% of the cases.²⁻⁶ Although RCD is still considered a rare disease in Western populations, its diagnosis is being made more often, which may be related to the increase in incidence but also to the improvement in accuracy of the imaging exams.^{11,12}

Historically, diverticula of the right colon were considered "true" diverticula, since all layers of the colonic wall were thought to be present in the diverticulum.¹³ More recent studies with cadavers,^{14,15} however, have shown that

diverticula in this region can also be “false,” resembling diverticulosis of the left colon, which has put into question the real pathophysiology of this disease. Currently, the most accepted theory is that RCD results from a motility disorder in the ascending colon and increased intraluminal pressure.¹⁶

From an epidemiological point of view, RCD affects younger patients in comparison to LCD, usually around the fourth and fifth decades of life, and has a milder clinical course.^{17–19} The mean age of the RCD patients in our series was 49.6 years, which is similar to other Western reports.²⁰ Most cases were uncomplicated, and only 2 patients had complicated disease with pelvic abscess not amenable to percutaneous drainage and had to undergo surgical treatment. The incidence of complicated RCD in the literature seems to be low, especially in the first episode.²¹

The clinical diagnosis of RCD is complex. Most patients present with abdominal pain in the right iliac fossa but without the classical migratory pattern associated with acute appendicitis. Fever, anorexia and vomiting are also common symptoms.²² In our series, the most common symptoms were abdominal pain and low-grade fever, which is consistent with reports by other authors.^{14,16,23}

Due to the clinical similarities to acute appendicitis and its similar incidence in young adults, diagnostic errors are common. In our series, 1/3 (25%) of the patients were misdiagnosed as having acute appendicitis or ileitis, which initially motivated the indication for surgery. Although abdominal CT plays a fundamental role in the initial investigation, the differentiation of RCD from appendicitis, right colon cancer or ileitis in Crohn disease is not always straightforward.^{5,24–26} Monari et al.²⁰ reported a rate of 33% of diagnostic errors with imaging exams in this setting. Even intraoperatively, there still may be diagnostic uncertainty, as shown in ►Figure 1.

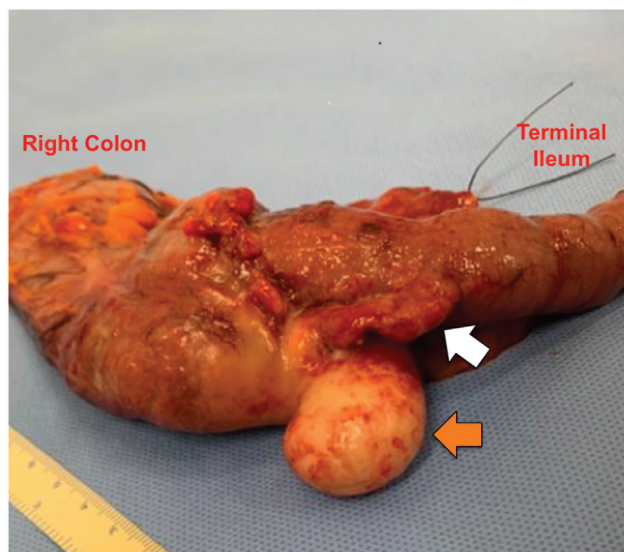


Fig. 1 Right colectomy specimen from a patient with pain in the right iliac fossa for 48 hours, whose preoperative CT revealed an inflammatory mass (orange arrow) with involvement of the cecal appendix (white arrow), and in whom complicated acute appendicitis could not be ruled out. The diagnosis of acute cecal diverticulitis was only confirmed on the anatomopathological examination.

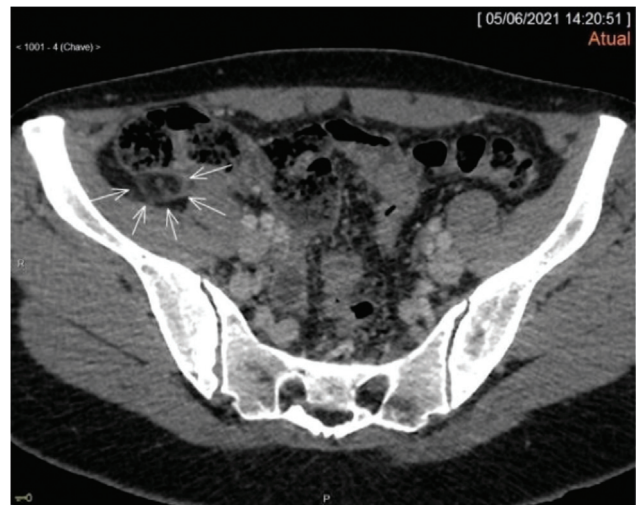

Fig. 2 Abdominal CT showing rounded densifications along the contramesenteric surface of the right colon (arrow), measuring 2 cm, suggestive of epiploic appendagitis.

As delaying the surgical treatment of acute appendicitis is associated with worse outcomes, prompt surgery is often employed in cases of diagnostic difficulty, before perforation and peritonitis occur.^{19,27} Other less common differential diagnoses include epiploic appendagitis (►Fig. 2) and omental infarction (►Fig. 3). Epiploic appendagitis is an uncommon, benign, self-limiting clinical condition that results from torsion or spontaneous venous thrombosis of the epiploic appendages. The diagnosis is made by CT of the abdomen, and this condition should be treated clinically, with analgesics and anti-inflammatory drugs.²⁸

Omental infarction is usually caused by torsion of the omentum or disturbances in the vascular supply.²⁹ Its clinical presentation is similar to that of acute appendicitis, and the diagnosis is made by abdominal CT or intraoperatively.

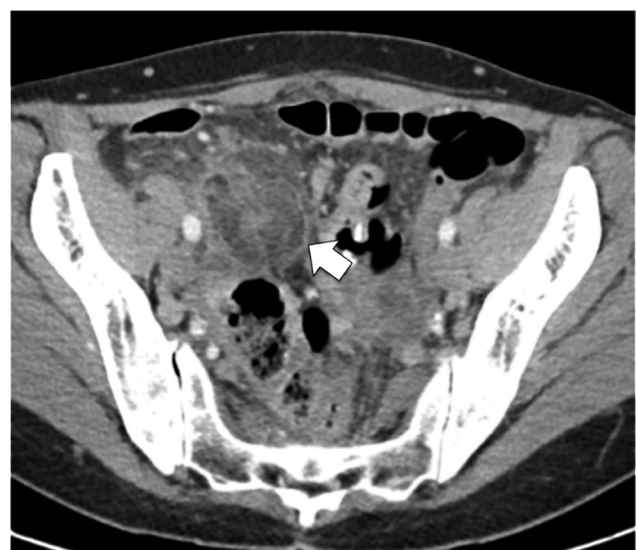


Fig. 3 Abdominal CT of a 51-year-old female patient with pain in the right hemiabdomen, fever, and nausea, with a clinical suspicion of acute appendicitis. The CT scan revealed the presence of a heterogeneous hyperdense fat mass with dense streaks in between, suggestive of omental infarction (arrow).

Table 2 Hinchey et al.³¹ classification of acute diverticulitis (1978)

Stages	Hinchey et al. ³¹ classification
I	Pericolic or phlegmon abscess
II	Abdominal, pelvic, or retroperitoneal abscess
III	Generalized purulent peritonitis
IV	Generalized fecal peritonitis

Table 3 Hinchey et al.³¹ classification modified by Wasvary et al.³² (1999)

Stages	Modified Hinchey ³¹ classification
0	Colonic wall thickening
Ia	Phlegmon, inflammation confined to the colic wall
Ib	Pericolic or mesocolic abscess
II	Abdominal, pelvic, or retroperitoneal abscess
III	Generalized purulent peritonitis
IV	Generalized fecal peritonitis

Colonoscopy has an important role in the investigation of patients with previous diverticulitis episodes, although it should not be performed in the acute setting due to the

risk of perforation. The objective is to assess the extension of colonic diverticula and to screen for adenomas and neoplasms.²² Lee et al. evaluated 330 patients with uncomplicated RCD and revealed that 20.9% had adenomas detected on follow-up colonoscopy, suggesting that routine colonoscopy should be advised even for patients with an uncomplicated crisis.³⁰

Regarding the classification of acute diverticulitis, in 1978, Hinchey et al.³¹ proposed classifying perforated diverticulitis from stages I (pericolic abscess) to IV (generalized fecal peritonitis) (► **Table 2**). Since then, with the introduction of CT to daily clinical practice, Wasvary et al.,³² in 1999, modified the original classification by adding non-complicated diverticulitis as stage 0, and subdivided stage I into two: stage Ia, with phlegmon or pericolic inflammation, and stage Ib, with pericolic or mesocolic abscess (► **Table 3**).

The treatment of RCD depends on the severity of the episode, and it ranges from clinical treatment with antibiotics to emergent Hartmann operation. For uncomplicated crises, recent studies have shown high success rates with the clinical treatment, which includes bowel rest with intravenous antibiotics, even for recurrent cases. Broad-spectrum antibiotic therapy is usually administered intravenously during hospitalization for two to four days and orally following hospital discharge.^{6,26}

In our series, 50% (6) of the patients were treated clinically, and only 2 presented recurrent episodes of

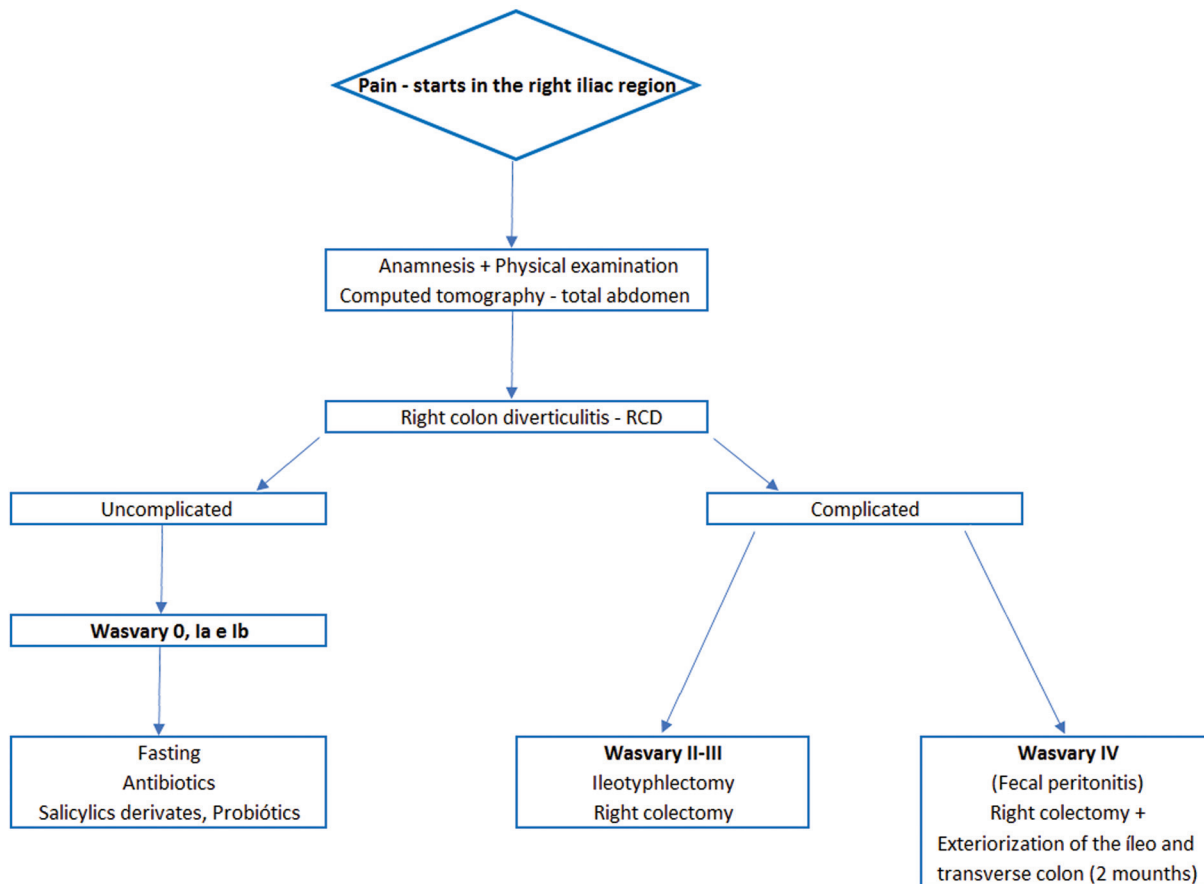


Fig. 4 Diagnostic and therapeutic algorithm for the management of right colon diverticulitis.

pain, which were also treated conservatively. Other authors^{17,21} have also reported similar findings, suggesting that RCD has a more favorable clinical course than that of LCD. The two patients with recurrent chronic pain were treated with mesalazine. Although the effectiveness of mesalazine for the prevention of diverticulitis recurrence is uncertain, since there is no robust evidence, some authors^{1,33} have shown symptomatic improvement when compared with placebo in patients with symptomatic uncomplicated diverticular disease.

Half of our patients required surgical treatment, a high proportion compared with those of other studies; this bias is due to our reference group in colorectal operations.

For more severe cases, classified as Wasvary II to IV, surgical treatment is recommended. Regarding the type of surgical procedure, in our experience right colectomy is the procedure of choice. Some Eastern authors^{6,14,21} advocate diverticulectomy in cases of single diverticula and in immunocompetent patients. The possible disadvantages of this approach are the difficulty in dissecting the inflamed diverticulum and the risk of inadequate treatment, as there is a risk of advanced adenomas and neoplasia.^{22,30} Although none of our patients had incidental findings of cancer on the anatomopathological examination, other authors^{25,30} have reported them.

In view of the success of the non-operative treatment and the risk of surgical complications, we consider that surgical treatment should be indicated only in cases with complications such as fistulas, abscess, perforation with peritonitis, and in recurrent crises with worsening quality of the life. Minimally-invasive surgery should be the method of choice if expertise is available, except for patients with generalized fecal peritonitis, in whom open surgery remains the standard approach.³⁴ Based on the experience observed in these patients and after reviewing the literature, we propose a therapeutic algorithm to guide physicians in the diagnosis and treatment of RCD when facing a patient with acute inflammatory abdomen and right iliac fossa pain (→Fig. 4).

Conclusion

Uncomplicated right colonic diverticulitis can be treated conservatively with a high success rate. Recurrent cases that impact quality of life or complicated forms of RCD should undergo surgical treatment, preferably a right laparoscopic colectomy. The authors present a diagnostic and therapeutic algorithm to facilitate the diagnosis and to guide the management of this disease.

Funding

The authors declare that they have received no funding pertaining to the present study.

Conflict of Interests

The authors have no conflict of interests to declare.

References

- 1 Tursi A, Scarpignato C, Strate LL, et al. Colonic diverticular disease. *Nat Rev Dis Primers* 2020;6(01):20. Doi: 10.1038/s41572-020-0153-5
- 2 Hughes LE. Postmortem survey of diverticular disease of the colon. I. Diverticulosis and diverticulitis. *Gut* 1969;10(05):336–344
- 3 Schuler JG, Bayley J. Diverticulitis of the cecum. *Surg Gynecol Obstet* 1983;156(06):743–748
- 4 Saad MK, Saikaly E. Right sided colonic diverticulitis: A comprehensive review. *Surg Clinics J* 2021;2(04):1033
- 5 Turner GA, O'Grady MJ, Purcell RV, Frizelle FA. The epidemiology and etiology of right-sided colonic diverticulosis: A review. *Ann Coloproctol* 2021;37(04):196–203
- 6 Lee IK. Right colonic diverticulitis. *J Korean Soc Coloproctol* 2010;26(04):241–245
- 7 Andersen JC, Bundgaard L, Elbrønd H, Laurberg S, Walker LR, Støvring J Danish Surgical Society. Danish national guidelines for treatment of diverticular disease. *Dan Med J* 2012;59(05):C4453
- 8 Cuomo R, Barbara G, Pace F, et al. Italian consensus conference for colonic diverticulosis and diverticular disease. *United European Gastroenterol J* 2014;2(05):413–442. Doi: 10.1177/2050640614547068
- 9 Schultz JK, Azhar N, Binda GA, et al. European Society of Coloproctology: guidelines for the management of diverticular disease of the colon. *Colorectal Dis* 2020;22(Suppl 2):5–28. Doi: 10.1111/codi.15140
- 10 Hall J, Hardiman K, Lee S, et al; Prepared on behalf of the Clinical Practice Guidelines Committee of the American Society of Colon and Rectal Surgeons. The American Society of Colon and Rectal Surgeons Clinical Practice Guidelines for the Treatment of Left-Sided Colonic Diverticulitis. *Dis Colon Rectum* 2020;63(06):728–747. Doi: 10.1097/DCR.0000000000001679
- 11 Cobben LPJ, Groot I, Blickman JG, Puylaert JB. Right colonic diverticulitis: MR appearance. *Abdom Imaging* 2003;28(06):794–798
- 12 Rov A, Ben-Ari A, Barlev E, Pelcman D, Susmalian S, Paran H. Right-sided diverticulitis in a Western population. *Int J Colorectal Dis* 2022;37(06):1251–1256
- 13 Morson BC. The muscle abnormality in diverticular disease of the colon. *Proc R Soc Med* 1963;56:798–800
- 14 Matsushima K. Management of right-sided diverticulitis: A retrospective review from a hospital in Japan. *Surg Today* 2010;40(04):321–325. Doi: 10.1007/s00595-008-4055-5
- 15 Zullo A. Medical hypothesis: speculating on the pathogenesis of acute diverticulitis. *Ann Gastroenterol* 2018;31(06):747–749
- 16 Imaeda H, Hibi T. The Burden of Diverticular Disease and Its Complications: West versus East. *Inflamm Intest Dis* 2018;3(02):61–68. Doi: 10.1007/BF02555537
- 17 Ferzoco LB, Raptopoulos V, Silen W. Acute diverticulitis. *N Engl J Med* 1998;338(21):1521–1526
- 18 Komuta K, Yamanaka S, Okada K, et al. Toward therapeutic guidelines for patients with acute right colonic diverticulitis. *Am J Surg* 2004;187(02):233–237. Doi: 10.1016/j.amjsurg.2003.11.009
- 19 Mohanty S, Webb SP. Uncommon Diverticular Disease. *Clin Colon Rectal Surg* 2018;31(04):258–262
- 20 Monari F, Cervellera M, Pirrera B, et al. Right-sided acute diverticulitis: A single Western center experience. *Int J Surg* 2017;44:128–131
- 21 Ha GW, Lee MR, Kim JH. Efficacy of conservative management in patients with right colonic diverticulitis. *ANZ J Surg* 2017;87(06):467–470. Doi: 10.1111/ans.13028
- 22 Yang HR, Huang HH, Wang YC, et al. Management of right colon diverticulitis: a 10-year experience. *World J Surg* 2006;30(10):1929–1934

- 23 Law WL, Lo CY, Chu KW. Emergency surgery for colonic diverticulitis: differences between right-sided and left-sided lesions. *Int J Colorectal Dis* 2001;16(05):280–284
- 24 Shyung LR, Lin SC, Shih SC, Kao CR, Chou SY. Decision making in right-sided diverticulitis. *World J Gastroenterol* 2003;9(03):606–608[PMID: 12632528 DOI: 10.3748/wjg.v9.i3.606]
- 25 Lee IK, Jung SE, Gorden DL, et al. The diagnostic criteria for right colonic diverticulitis: prospective evaluation of 100 patients. *Int J Colorectal Dis* 2008;23(12):1151–1157
- 26 Telem DA, Buch KE, Nguyen SQ, Chin EH, Weber KJ, Divino CM. Current recommendations on diagnosis and management of right-sided diverticulitis. *Gastroenterol Res Pract* 2009;2009:359485. Doi: 10.1155/2009/359485
- 27 Chen SC, Chang KJ, Wei TC, Yu SC, Wang SM. Can cecal diverticulitis be differentiated from acute appendicitis? *J Formos Med Assoc* 1994;93(03):263–265
- 28 Pignaton G, Borges AA, Mendonça R, Ribeiro C, Chindamo MC. Apendagite epiplóica: tratamento conservador. *Rev Bras Coloproctol* 2008;28(03):350–352
- 29 Epstein MG, Carvalho JZM, Piccinini I, Sipriani Júnior LV, Ribeiro Júnior MAF. TCBC-SP. Torção primária de omento como causa rara de abdome agudo - relato de caso. *Relatos Casos Cir* 2016;(03):1–2
- 30 Lee KY, Lee J, Park YY, Oh ST. Routine colonoscopy may be needed for uncomplicated acute right colonic diverticulitis. *BMC Gastroenterol* 2021;21(01):91. Doi: 10.1186/s12876-021-01672-1
- 31 Hinchey EJ, Schaal PG, Richards GK. Treatment of perforated diverticular disease of the colon. *Adv Surg* 1978;12:85–109
- 32 Wasvary H, Turfah F, Kadro O, Beauregard W. Same hospitalization resection for acute diverticulitis. *Am Surg* 1999;65(07):632–635, discussion 636
- 33 Picchio M, Elisei W, Tursi A. Mesalazine to treat symptomatic uncomplicated diverticular disease and to prevent acute diverticulitis occurrence. A systematic review with meta-analysis of randomized, placebo-controlled trials. *J Gastrointest Liver Dis* 2018;27(03):291–297
- 34 Ma Z, Liu W, Zhou J, et al. Management and long-term outcomes of acute right colonic diverticulitis and risk factors of recurrence. *BMC Surg* 2022;22(01):132. Doi: 10.1186/s12893-022-01578-z