



Demographic and Clinical Profile of Patients Presenting with COVID-19-Associated Rhino-orbito-cerebral Mucormycosis at a Tertiary Care Center

Siddharth Madan¹ Rekha Yadav¹ Jolly Rohatgi¹ Rahul Sharma² Iffat Nasir¹ Aarushi Saini¹
Nampi Tadu¹ Gopal Krushna Das¹ Pramod Kumar Sahu¹ Neelima Gupta³ Nitika Beri¹

¹Department of Ophthalmology, University College of Medical Sciences and Associated GTB Hospital, University of Delhi, Delhi, India

²Department of Community Medicine, University College of Medical Sciences and Associated GTB Hospital, University of Delhi, Delhi, India

³Department of ENT, University College of Medical Sciences and Associated GTB Hospital, University of Delhi, Delhi, India

Address for correspondence Jolly Rohatgi, MBBS, MS, Department of Ophthalmology, University College of Medical Sciences and Associated GTB Hospital, University of Delhi, Delhi 110095, India (e-mail: jollyrohatgi@gmail.com).

Ann Natl Acad Med Sci (India) 2022;58:210–219.

Abstract

Objectives Individuals affected with rhino-orbito-cerebral mucormycosis (ROCM) associated with coronavirus disease 2019 (COVID-19) increased enormously in northern India during the second wave of the novel coronavirus disease. This study determined the demographic and clinical profile including the risk factors in patients presenting to a tertiary care hospital in northern India.

Materials and Methods This is a descriptive study involving patients admitted with COVID-19-associated ROCM and were managed from May 2021 to 20th July 2021.

Statistical Analysis The data was analyzed using SPSS (IBM SPSS Statistics 20, SPSS Inc., Chicago, Illinois, United States) software and Microsoft Excel (Version 16.49). The chi-squared and Fisher's exact tests were used to compare various outcomes. A *p*-value of less than or equal to 0.05 was considered to be statistically significant.

Results One hundred and seventeen (117) patients (males: 70 [59.8%], females: 47 [40.2%]) with the average age of 51.85 ± 12.80 years presented with orbital involvement. Diabetes mellitus was noted in 100 (86.2%) patients. Of the available data from the records, oxygen supplementation for the management of COVID-19 was received by 37/108 (34.3%) patients for a median average duration of 11 days. Forty-eight patients of one-hundred-seventeen (60%) patients were treated with corticosteroids with a median duration of steroid administration being 10 days. The duration between onset of symptoms related to mucormycosis and diagnosis of COVID-19 was 0 to 75 days for 48 patients. Intravenous amphotericin B was administered in all cases. External sinonasal debridement was performed in 90 of 114 (78.9%) patients, retrobulbar amphotericin B injection was administered in 56 of 117 (47.9%), and orbital exenteration was performed in 17 of 117 (14.5%) of cases.

Keywords

- ▶ ROCM
- ▶ COVID-19
- ▶ orbital mucormycosis
- ▶ orbital exenteration
- ▶ diabetes mellitus
- ▶ corticosteroids

article published online
December 8, 2022

DOI <https://doi.org/10.1055/s-0042-1757894>.
ISSN 0379-038X.

© 2022. National Academy of Medical Sciences (India). All rights reserved.

This is an open access article published by Thieme under the terms of the Creative Commons Attribution-NonDerivative-NonCommercial-License, permitting copying and reproduction so long as the original work is given appropriate credit. Contents may not be used for commercial purposes, or adapted, remixed, transformed or built upon. (<https://creativecommons.org/licenses/by-nc-nd/4.0/>)

Thieme Medical and Scientific Publishers Pvt. Ltd., A-12, 2nd Floor, Sector 2, Noida-201301 UP, India

Conclusion Administration of corticosteroids and diabetes mellitus seem to be the major underlying causes for the development of COVID-19-associated ROCM. Prompt diagnosis and multidisciplinary management approach are essential for a reduction in mortality.

Introduction

The pandemic of coronavirus disease 2019 (COVID-19) is an ongoing problem worldwide since the end of year 2019. Over a million people succumbed to the illness. India has experienced three waves of the pandemic. India contributed to 81% of the cases of COVID-19-associated rhino-orbitocerebral mucormycosis (ROCM).¹ There is a significant increase in incidence of cases of ROCM in India as the second wave of COVID-19 evolved.^{2,3} Of the various management options that exist for COVID-19, systemic glucocorticoids remain the most effective means of improving survival and controlling the cytokine storm associated with the disease. However, nonjudicious use of corticosteroids, immunomodulator drug therapy, and oxygen supplementation for managing COVID-19 and its accompanying complications has given way to the emergence of an ongoing epidemic of ROCM amidst the pandemic. India is affected the worst, particularly the northern part of the country. ROCM is an aggressive opportunistic fungal infection caused by *Mucor* that belongs to the class phycomycetes. Although the disease is opportunistic usually observed in the immune-compromised patients, the usual presence of the organism on the body surfaces, environment, natural orifices including the nose and paranasal sinuses results in sporulation and proliferation of the fungus at these sites apart from local ocular and intracranial extension.¹ Individuals suffering from COVID-19 having no other comorbidities have also manifested the development of this fatal disease.^{2,3} Severe acute respiratory syndrome coronavirus-2 (SARS-CoV-2) causes immune dysregulation. Corticosteroids with/without the use of immunomodulatory therapy forms the basis for underlying management as these are possibly the only drugs proven to be beneficial in patients infected with SARS-CoV-2.^{4,5} However, their role in causing ROCM remains debatable. Management of ROCM requires stabilization of the systemic comorbidities including control of hyperglycemia, prompt administration of antifungal therapy in the form of amphotericin B preferably liposomal formulation, or the use of lipid complex/emulsion type of amphotericin B with early sinonasal debridement.⁶⁻⁸ Medical facilities are overwhelmed with the management of COVID-19 cases. Dedicated centers for the management of COVID-19-associated mucormycosis (CAM) patients were created by the government. A tertiary care hospital in northern India in Delhi was also dedicated for the management of patients suffering from CAM. We present our experience of cases of CAM treated in tertiary care center in northern India and describe their clinical features, risk factors apart from other clinical correlates.

Materials and Methods

We performed a retrospective descriptive study of the patients who presented to our tertiary care hospital designated for the management of patients suffering from ROCM and were admitted for their management during the COVID-19 pandemic. The medical records of the patients from May 2021 to 20th July 2021 were analyzed. This study was approved by the Institutional Ethics Committee.

The patients who presented to the casualty of our hospital with symptoms and signs suggestive of ROCM were admitted. A history of COVID-19 was elicited and the presence of ROCM was considered to be associated with COVID-19 if the patient had recovered from COVID-19 based on previous positive reverse-transcriptase polymerase chain reaction (RT-PCR) or rapid antigen test (RAT)/or currently suffering from COVID-19 with a recently positive RT-PCR/RAT within last 2 weeks or was a suspect case of COVID-19 based on a recent significant contact with a patient infected with COVID-19 or a family history of contact with a COVID-19 positive individual. The diagnosis of COVID-19 was established depending on the presence of any one of the following: Positive testing on RT-PCR/ RAT and computed tomography (CT)/magnetic resonance imaging (MRI) evidence of COVID-19 if RT-PCR test was negative in a symptomatic patient. Based on the results of a systematic review, the median time interval between the diagnosis of COVID-19 and the first evidence of mucormycosis infection or CAM diagnosis was 15 days; however, the manifestations of mucormycosis developed as late as 42 days and 90 days following diagnosis of COVID-19.^{9,10}

The patients without symptoms of COVID-19 or the ones who tested negative on RT-PCR/RAT in their current visit developed symptoms/signs of ROCM; the presentation with ROCM was considered to be associated with COVID-19 as a sudden spurt in the number of cases of ROCM in a short interval of time amidst COVID-19 pandemic gives a pointer that the clinical features of ROCM were possibly precipitated by a previous infection with SARS-CoV-2. These cases could be asymptomatic but if got tested for SARS-CoV-2, they may show test positive on RT-PCR/RAT. Confirmation is only possible if antibody titers against SARS-CoV-2 in unvaccinated individuals is checked. All patients were evaluated by physician and ear nose throat (ENT) specialist in the casualty and diagnostic nasal endoscopy (DNE) performed and findings documented. A sample for potassium hydroxide (KOH) testing to microbiology department was sent for the confirmation of the diagnosis of ROCM. Subsequently, a comprehensive ocular examination including the visual acuity (VA), ocular motility, evaluation of proptosis, anterior segment,

and dilated fundus examination was performed by the ophthalmologist. A contrast-enhanced CT/MRI scan of the paranasal sinuses, orbit, and brain was done, if a recent scan was not available with the patient. Neurosurgery opinion was sought if the imaging suggested intracranial involvement. The patients were either proven, probable, or possible cases of ROCM. If the symptoms and signs were suggestive of ROCM in the background of COVID-19, a diagnosis of possible ROCM was established. If clinical features suggested ROCM and DNE and/or imaging further supported the clinical profile, a diagnosis of probable ROCM was considered. However, a diagnosis of proven ROCM was made only if the clinical along with radiological features were observed and a microbiological confirmation on KOH testing was established. The severity of mucormycosis was staged based on the classification proposed by Honavar et al.¹¹ Stage 1 (1a,1b,1c) had involvement of the nasal mucosa; 1a—limited to the middle turbinate, 1b— involvement of the inferior turbinate or ostium of the nasolacrimal duct, 1c—involvement of the nasal septum, 1d—bilateral nasal mucosal involvement.

Stage 2 (2a,2b,2c,2d) had involvement of the paranasal sinuses; 2a—one sinus, 2b—two ipsilateral sinus, 2c—more than 2 ipsilateral sinuses and/or palate/oral cavity, 2d—bilateral paranasal sinus involvement or involvement of the zygoma or mandible.

Stage 3 had orbital involvement: Stage 3a—nasolacrimal duct, medial orbit, vision unaffected; 3b—diffuse orbital involvement, vision unaffected; Stage 3c—central retinal or ophthalmic artery occlusion or superior ophthalmic vein thrombosis, involvement of the superior or inferior orbital fissure, orbital apex with loss of vision; Stage 3d—bilateral orbital involvement.

Stage 4 had involvement of the central nervous system with the disease.

All cases of nonmucor non-COVID-19-associated ROCM were excluded from the study. All patients underwent an RT-PCR testing for COVID-19 at the time of admission and were treated as COVID-19 positive till RT-PCR report was negative. Initially systemic comorbidities were managed especially diabetes mellitus and renal failure. The patients with renal failure underwent dialysis as per the advice of the physician. The patients with newly diagnosed uncontrolled diabetes were started on insulin infusions/subcutaneous insulin/oral hypoglycemic agents or the dosage of the medication being administered previously was modified as per the advice of the endocrinologist. Initially due to limited availability of intravenous (IV) amphotericin B, patients had to be given emulsion type and lipid formulations. IV amphotericin B was administered after a test dose. Liposomal amphotericin B administration initiated later after the drug was available in sufficient quantity and was preferred in patients with deranged kidney function tests that were monitored daily for all patients along with serum electrolytes. A decision to perform sinonasal debridement was taken by ENT specialist. Patients with orbital apex involvement and with extensive intraconal disease received retrobulbar injection of amphotericin B and those with predominantly extraconal disease

received peribulbar amphotericin B injection. Both retrobulbar and peribulbar injections were administered if both extraconal and intraconal compartments were involved. All such injections were of the lipid emulsion type of amphotericin B (3.5 mg/ml) as the liposomal variety of the drug was available in a limited quantity. Patients who were systemically compromised and unfit for general anesthesia received intraorbital amphotericin B injections along with medical management using IV amphotericin B. A decision to perform orbital exenteration in the same sitting with sinonasal debridement/or at a later date was taken as per the extent of orbital involvement/worsening after debridement along with concomitant administration of IV amphotericin B. Dental opinion was sought wherever necessary. The data was analyzed using SPSS (IBM SPSS Statistics 20, SPSS Inc., Chicago, Illinois, United States) software and Microsoft Excel (Version 16.49). The chi-squared and Fisher's exact tests were used to compare various outcomes. A *p*-value of less than or equal to 0.05 was considered to be statistically significant. The consent for photographs has been obtained from the patients and/or their relatives. This study adheres to the guidelines of the Declaration of Helsinki and is approved by the Institutional Ethics Committee for Human Research (IEC-HR) of the institution. The patients consented to participate in the study and the ones who could not be contacted were included after a waiver of consent was obtained from the Institutional Review Board of the IEC-HR.

Results

Over 300 patients of ROCM presented to a tertiary care hospital in the National Capital Territory of Delhi. The medical records of 241 patients (M-158 [65.6%]; F-83 [34.4%]) admitted to the center were evaluated. Out of 241 patients that were analyzed, 117 (48.54%) (M-70 [59.8%]; F-47 [40.2%]) patients had involvement of the orbit (► **Fig. 1A–C**). History of COVID-19 was observed in 80/116 (69.96%) patients. Hundred (86.2%) such patients were suffering from type 2 diabetes mellitus, 48 (60%) of these had history of corticosteroid administration, and 37 (34.3%) patients received oxygen supplementation for the management of COVID-19. Majority (n= 69 [80.2%]) of the patients with diabetes required insulin administration for control of their blood sugar levels. There were 93 patients with rhino-orbital mucormycosis (ROM) (► **Fig. 1A–I, 2A–Q**). Intracranial involvement (ROCM) in the form of cavernous sinus thrombosis (CST) on imaging was noted in 23 patients (► **Fig. 1H**) and brain abscess was observed in 10 patients (► **Table 1**). ► **Table 1** demonstrates clinical profile of the patients with orbital involvement due to ROCM. ► **Table 2** shows comparison of different parameters between patients with and without orbital involvement. Unilateral eye involvement was noted in 105 (91.3%) patients and both eyes were involved in 10 (8.7%) subjects. The number of patients with normal VA ($\geq 6/60$) and those with no light perception (NLP) in either eye was comparable. Absence of light perception, total ophthalmoplegia, proptosis, ptosis, and exposure keratopathy/corneal ulceration were observed

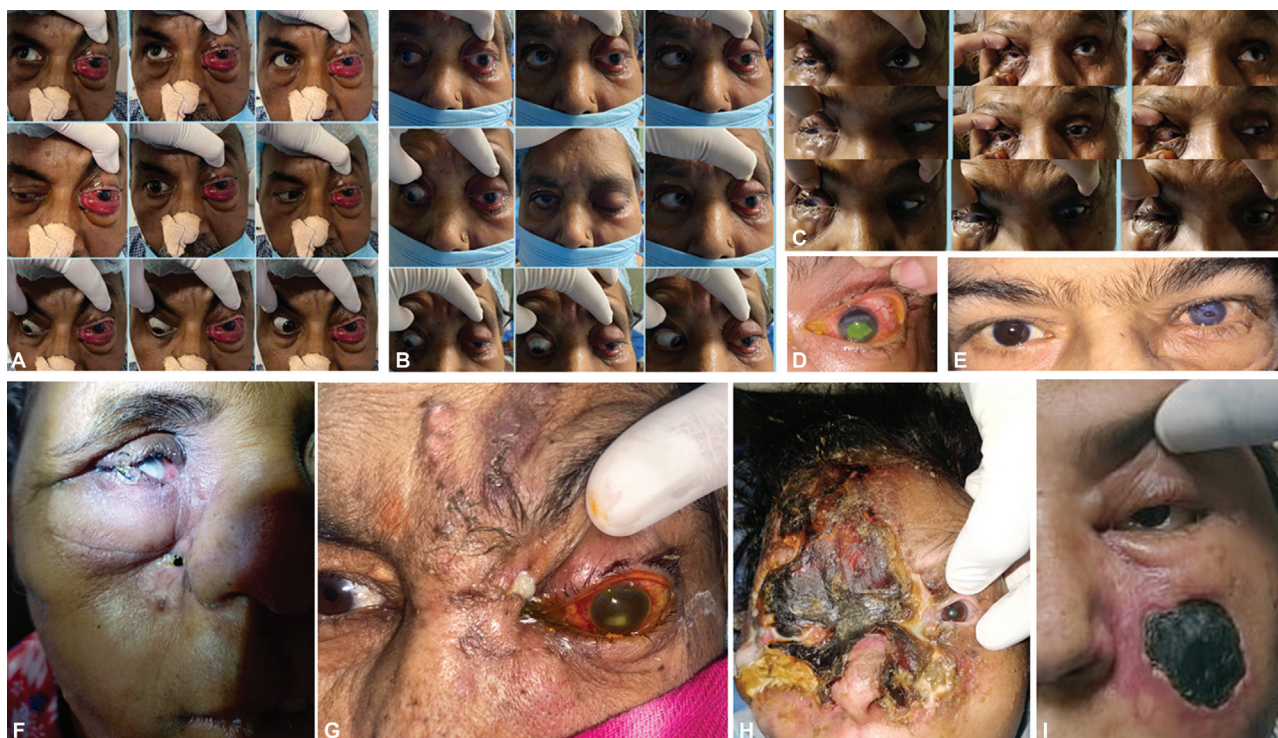

Fig. 1 (A–I): Sequential patient photographs showing various clinical manifestations of rhino-orbito-cerebral mucormycosis (ROCM). A 62-year-old male presented with orbital cellulitis demonstrating conjunctival chemosis, limitation of ocular motility in all gazes, proptosis and visual acuity reduced to no light perception (A). A 60-year-old lady presented with features suggestive of orbital apex syndrome in the form of ptosis, proptosis, total ophthalmoplegia, and visual acuity reduced to no light perception (B). An elderly lady presented with infraorbital swelling; ocular motility was preserved but had radiological manifestations of rhino-orbital mucormycosis (ROM) (C). Corneal ulcer in a patient suffering from HIV (D). The ulcer healed leaving a corneal opacity and patient presented with a central corneal perforation with iris prolapse (E). Lateral tarsorrhaphy performed in a patient with nonhealing corneal ulcer accompanied with corneal exposure (F). A 70-year-old lady with ROM had pus-filled lesions on the forehead that demonstrated mucor microbiologically (G). The patient also had a fungal corneal ulcer due to mucor (G). Extensive skin involvement with myonecrosis of the facial muscles in an adult lady with ROCM (H). An elderly lady presented with ROM with an eschar over the left cheek in the region of the left maxillary sinus (I).

in 57 (54.8%), 59 (52.7%), 69 (61.6%), 74 (67.3%), and 14 (12.6%) patients, respectively. A VA of NLP, presence of total ophthalmoplegia, proptosis, ptosis, stage 3d, stage 4, the patients who were administered insulin, and the ones who did not undergo orbital exenteration or sinonasal debridement had significantly higher mortality, p -value (≤ 0.05). Majority of the patients who underwent orbital exenteration had an eye with NLP, having total ophthalmoplegia, proptosis, and ptosis, p -value (≤ 0.05). Pansinusitis on CT scan/MRI was noted in 97 (86.6%) patients. Staging of ROCM based on the recommended criteria was performed and the number of patients in stage 3a and 3b was 34 (30.0%), 3c comprised of 52 (44.4%), 3d of 8 (6.8%), and stage 4 comprised of 19 (16.2%) patients (\rightarrow Table 1). Fifty-six (47.9%) subjects received retrobulbar injection of amphotericin B, and 23 (19.7%) patients were administered peribulbar injection of amphotericin B. Sinonasal debridement with or without endoscopic orbital decompression and orbital exenteration were performed in 90 (78.9%) and 17 (14.5%) patients, respectively. Neurosurgical intervention via external craniotomy for brain abscess or endonasal approach for sinus debridement was performed in 15 patients on the same day when orbital exenteration was performed or at a later date on case-to-case basis. Majority ($n=80$ [69%]) of the patients were discharged and 36/116 (31.03%) patients succumbed to the illness. There was no

statistically significant difference between the occurrence of stage 4 with respect to laterality of eye involvement or history of COVID-19 or dosage of COVID-19 vaccination received, p -value (≥ 0.05). There was no significant difference between mortality in stage 4 and age above 60 years. Positive history of COVID-19 or the state of residence had no statistically significant association with mortality, p -value (≥ 0.05). Mortality was more in the female gender, p -value (≤ 0.05). Presence of diabetes mellitus, immunocompromised state, and administration of corticosteroids had statistically significant correlation with mortality, p -value (≤ 0.05). Mortality was more in patients who received oxygen supplementation for the management of COVID-19, ($n=16$ [43.2%]). There was no statistically significant correlation of a patient undergoing orbital exenteration with old age, gender, positive history for COVID-19, KOH positivity, diabetes mellitus, immunocompromised state, steroid administration, antiviral treatment, oxygen administration, orbital involvement on CT scan, presence of CST, stage 4, administration of retrobulbar, or peribulbar amphotericin B injection. The patients who were suffering from diabetes mellitus, received oxygen supplementation and corticosteroids for management of COVID-19, and had a positive history of COVID-19 had significantly higher incidence of orbital involvement due to ROCM as against the patients who had no

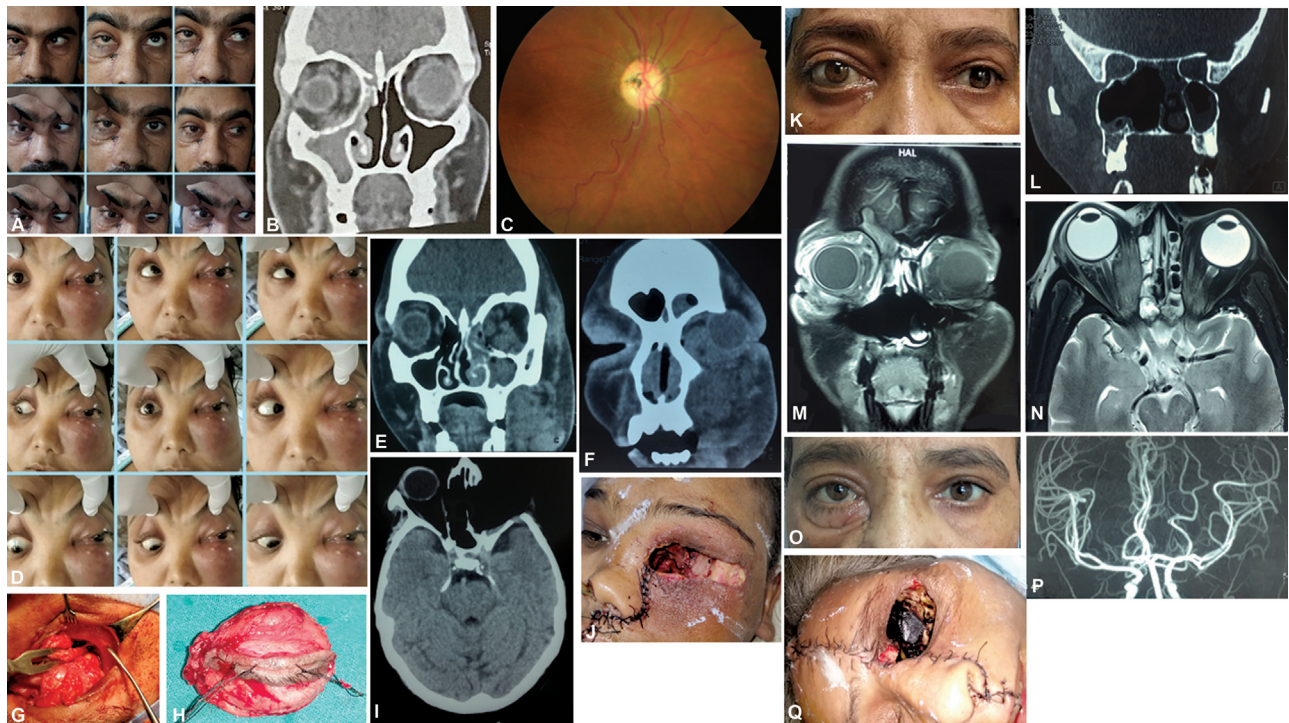


Fig. 2 (A–P): Clinical, radiological, fundus, and exenterated specimen photographs. (A) An adult male presented with partial ophthalmoplegia in his right eye along with features of orbital cellulitis on contrast-enhanced computed tomography scan (CECT [B]). Visual acuity reduced to no light perception due to central retinal artery occlusion as seen in the fundus photograph (C). A young lady developed mucor associated orbital cellulitis oculus sinister (OS) and cellulitis with pustular eruptions over the left side of the face (D) which was confirmed radiologically (E–F) on CECT scan. Intra-operative photograph of a patient who underwent orbital exenteration (G) and the exenterated specimen (H) was sent for histopathological examination. The patient in parts E–F underwent left orbital exenteration with sinonasal debridement. Postoperative CECT scan (I) following exenteration showed no recurrence and the socket appeared healthy with blood clots following surgery (J). A patient with rhino-orbital mucormycosis presented with proptosis oculus dexter (K). CT scan showed destruction of the medial orbital wall (L). Magnetic resonance imaging (MRI) of the orbit demonstrated features of orbital cellulitis (M) with the involvement of all recti, oblique muscles along with the intraconal and extraconal compartment (N). Post sinonasal debridement (O), the MR angiography that was done was normal (P). Another patient who underwent external sinonasal debridement and orbital exenteration with the incision and suture marks extending to the forehead to remove pus filled lesions on the forehead (Q).

orbital involvement (►Table 2). ►Table 3 shows the demographic profile of the patients.

Discussion

Of all cases of mucormycosis that are observed, ROCM remains the most common presentation.^{7,12} The prevalence of mucormycosis in India is observed to be 0.14 per 1000 individuals.^{1,13} Secondary bacterial or fungal infections have increased in incidence during the pandemic of COVID-19 up to 8%.^{10,11} However, the usual infection with aspergillosis and candida is most common as in literature.¹⁴ The rising number of cases of ROCM during the pandemic of COVID-19 is a matter of concern. The researchers have proposed that the infection with SARS-CoV-2 creates a hypoxic environment in the body tissues and mucosal surfaces. This coupled with high blood glucose and serum ferritin levels, administration of corticosteroids to control inflammation associated with infection with SARS CoV-2 along with reduction in the phagocytic activity of leukocytes as a result of immunosuppression caused by the virus, creates a conducive environment for the proliferation of the fungus.¹ Prolonged stay in the hospital increases susceptibility for contracting nosoco-

mial infections. The orodental hygiene of the patient is also neglected in such circumstances. Further unsupervised oxygen administration (at home with oxygen concentrators without regular cleaning of filters) and rampant use of immunosuppressants apart from poor hygienic practices in the form of repeated usage of the same face mask might be plausible mechanisms for a surge in the number of cases of ROCM.

ROM has varied ophthalmic presentations. These range from no involvement of the orbit and/or eye to potentially blinding ophthalmic sequel in the form of orbital cellulitis, proptosis, partial to total ophthalmoplegia, orbital apex involvement, and vascular sequelae in the form of central retinal artery occlusion resulting in severe visual loss.¹⁵ IV amphotericin B preferably the liposomal formulation is the drug of choice in patients suffering from ROCM.¹⁶ The mainstay of treatment in mucormycosis is surgical debridement. Sinonasal debridement is invariably needed in all cases as the primary source of the fungus lies in these cavities. Orbital involvement requires management in the form of retrobulbar amphotericin B injections.^{3,17–19}

Cases with extensive orbital involvement worsening over time with the administration of IV amphotericin B need

Table 1 Clinical profile of the patients

Clinical profile of patients with orbital involvement (n = 117)	
Right eye VA	VA ≥ 6/60–55 (48.7%) VA < 6/60 to perception of light present with inaccurate PR: 23 (20.35%) PL negative (no perception of light): 30 (26.5%) Disoriented : 5 (4.4%)
Left eye VA	VA ≥ 6/60–59 (52.2%) VA < 6/60 to perception of light present with inaccurate PR: 23 (20.35%) PL negative (no perception of light): 26 (23.0%) Disoriented: 5 (4.4%)
Variable	Yes—Y; No—N; Data in records missing for the rest (117—[Y + N])
VA—perception of light	N—57 (54.8%), Y—47(45.2%)
Total ophthalmoplegia	Y—59 (52.7%), N—53 (47.3%)
Mild limitation of ocular motility	Y—32 (30.8%), N—72 (69.2%)
Proptosis	Y—69 (61.6%), N—43 (38.4%)
Ptosis	Y—74 (67.3%), N—36 (32.7%)
Exposure keratopathy/ corneal ulcer	Y—14 (12.6%), N—97 (87.4%)
Staging	3a,3b—34 (30.0%), 3c—52 (44.4%), 3d—8 (6.8%), Stage 4—19 (16.2%)
Oral cavity involvement	Y—27 (36.5%), N—47 (63.5%) Erosion—15(20.3%), Ulcer—12 (16.2%)
Nasal involvement	Y—66 (73.3%), N—24 (26.7%), Crusting—32 (36%), Secretion—35 (39.3%), Necrosis—1 (1.1%)
Skin involvement	Y—12 (11.4%), N—93 (88.6%)

Abbreviations: PL, perception of light; PR, projection of rays; VA, visual acuity.

Table 2 Comparison of different variables between patients with and without orbital involvement

Parameter (n = 241)	Orbit involvement	No. of patients	Mean	SD	SE mean	p-Value for difference
Age	No	124	52.0	12.6	1.17	0.9
	Yes	117	51.8	12.6	1.183	
Association between different variables and orbital involvement						
Variable		Subjects without orbital involvement	Subjects with orbital involvement		p-Value for difference	
Gender	Female	No (N)—36 (43.4%)	Yes (Y) —47 (56.6%)		0.07	
	Male	N—88 (55.7%)	Y—70 (44.3%)			
Whether patient have COVID-19 history	No	N—22 (35.5%)	Y—40 (64.5%)		0.007	
	Yes	N—95(55.6%)	Y—76 (44.4%)			
Diabetes mellitus	No	N—38 (70.4%)	Y—16 (29.6%)		0.001	
	Yes	N—82 (45.3%)	Y—99 (54.7%)			
Whether received steroid	No	N—37(35.9%)	Y—66 (64.1%)		< 0.001	
	Yes	N—72 (63.7%)	Y—42 (36.3%)			
Whether oxygen support received	No	N—42 (35.9%)	Y—75 (64.1%)		< 0.001	
	Yes	N—62 (63.9%)	Y—35 (36.1%)			
Whether received insulin	No	N—28 (62.2%)	Y—17 (37.8%)		0.002	
	Yes	N—35 (35.0%)	Y—65 (65.0%)			

Abbreviations: COVID-19, coronavirus disease 2019; SD, standard deviation; SE, standard error.

Table 3 Demographic profile of the patients

Parameter	Observation in patients with orbital inv. (n = 117)
Average age less than 60 60 years or more	51.85 ± 12.80 years (22–84 years) 72.6% (85/117) 27.4% (32/117)
Sex	M–70 (59.8%); F–47 (40.2%)
State to which belongs	Delhi–52 (46%) Outside Delhi–61 (54%); data NA–4
Whether patients have COVID-19 history	Unknown–36 (31%) Y–80 (69%); data NA–1
Average no. of days of hospital stay before onset of ROCM	0–34 days for 54 patients
Average duration (in days) between diagnosis of COVID-19 and mucor	0–75 days for 48 patients
Diabetes mellitus	Y–100 (86.2%) N–16 (13.8%)
Whether received steroid therapy during treatment	Y–48 (60%) N–32 (40%)
Duration of steroid therapy	0–30 days for 29 patients (median–10 days)
Type of steroid therapy	Oral–31 (64.6%), injectable–17 (35.4%)
Antiviral treatment received	Y–5 (9.4%), N–48 (90.6%)
Tocilizumab/immunomodulator received	Tocilizumab–1 (0.9%), N–52 (44.4%)
Whether oxygen support received prior to onset of mucormycosis	Y–37 (34.3%) N–71 (65.7%)
Duration of oxygen therapy	0–30 days for 28 patients (median–11 days)
KOH testing	Positive–101 (86.3%), negative–16 (13.7%)
Insulin administration for diabetes	Y–69 (80.2%), N–17 (19.8%)
Oral hypoglycemic agent administration	Y–37 (43.5%), N–48 (56.5%)
Average hemoglobin at presentation (gm%)	9.2; Data NA–55
Final average hemoglobin (gm%)	8.09; Data NA–57
Immunocompromised status	Y–27 (23.3%), unknown–89 (76.7%)
Other comorbidities	Hypertension–22 (27.2%) others (coronary artery disease, chronic kidney disease, hypothyroidism)–59 (78.8%)
Classification of mucormycosis	ROCM–24, ROM–93
Eye involvement	RE–52 (45.2%), [LE]–53 [46.1%], (unilateral eye inv.–105 [91.3%]) BE–10 (8.7%)
Demographic profile of 117 patients with orbital involvement	
Maxillary sinusitis on CT scan/MRI	112 (95.7%)
Ethmoid sinusitis on CT scan/MRI	Y–109 (97.3%) N–3 (2.7%)
Frontal sinusitis and Pansinusitis on CT scan/MRI	Y–97 (86.6%), N–15(13.4%)
Orbital involvement on CT scan/MRI	Y–113 (98.3%), N–2(1.7%)
Cavernous sinus involvement on imaging	Y–23 (19.8%), N–93 (80.2%)
Retrobulbar injection administered	Y–56 (47.9%), N–61 (52.1%)
Peribulbar injections administered	Y–23 (19.7%), N–94 (80.3%)
Debridement done	Y–90 (78.9%), N–24 (21.1%)
Orbital exenterations done	Y–17 (14.5%), N–100 (85.5%)
Discharge/death	Discharge/under treatment–80 (69%), Death–36 (31%)

Abbreviations: BE, both eye; COVID-19, coronavirus disease 2019; CT, computed tomography; KOH, potassium hydroxide; LE, left eye; MRI, magnetic resonance imaging; ROCM, rhino-orbito-cerebral mucormycosis; ROM, rhino-orbital mucormycosis.

orbital exenteration.¹ In our study, a large cohort of patients suffering from ROCM amidst the COVID-19 pandemic were admitted. The demographic profile of the admitted patients was comparable to the observations that were made by the authors elsewhere as reported in literature.^{9,20-23} There were 70 (59.8%) males and 47 (40.2%) females with an average age of 51.85 ± 12.80 years. Of the available data for 117 patients, 100 (86.2%) patients were suffering from diabetes mellitus. Diabetes has also been reported as the most common risk factor in the study conducted by Ravani et al. This study by Ravani et al included 31 patients over a period of 4 months as against 117 patients of ROM out of a total of over 241 patients that were retrospectively evaluated over two and half months.² History of steroid use during COVID-19 was noted in 48/80 (60%) patients out of a total of 117 patients whose records were analyzed. Corticosteroid administration was rampant in the treatment of COVID-19. The benefits of corticosteroid administration in causing the reduction in mortality among patients suffering from moderate to severe COVID-19 are documented in the RECOVERY trial.²⁴ Further, based on the guidelines laid down by the government of India, methylprednisolone (0.5–1 mg/kg in two divided doses for moderate disease; 1–2 mg/kg in two divided doses for severe disease) or an equivalent dose of dexamethasone is indicated for controlling the inflammatory response in the management of COVID-19.²⁵ However a dose above 600 mg of prednisolone and 2 to 7 grams of methylprednisolone predisposes the patients who are immunocompromised to mucormycosis. Over 3 weeks of systemic administration of steroids predisposes patients having no history of COVID-19 to mucormycosis.^{26,27} The available literature suggests that 76 to 87% of patients suffering from COVID-19 who received systemic corticosteroid therapy developed ROCM.^{1,16} As per the study conducted by Ravani et al, the demographic parameters including the age, gender, positive testing for COVID-19, duration of the presence of diabetes, and systemic comorbidities apart from the options used for management in these admitted patients were not significant. Also 38.70% patients who had no positive history of COVID-19 and steroid use developed ROCM as per the study by Ravani et al.² The study by Song et al concluded that in the background of COVID-19, patients who were in an immunocompromised state as a result of long-standing diabetes, HIV infection, and malignancy apart from other comorbidities were seen to develop fungal coinfection more commonly as against the ones who were immunocompetent.²⁵ Case series in literature pertaining to ROM have also reported the important risk factors in the form of diabetes mellitus that is not controlled over a period of time along with a history of administration of systemic corticosteroids during the management for COVID-19. Various presentations of patients are described in the form of pain in the eyes with or without accompanying redness and swelling around eyes. Clinically, the patients have presented with ophthalmoplegia, ptosis with the presence or absence of visual loss. Cases have been reported in literature that have invasive mucormycosis along with concurrent presence of COVID-19.²¹⁻²³ As against the usual average incidence of mucormycosis at

our center (6–7 cases per year) prior to the COVID-19 pandemic, there was a sudden surge in cases who presented to the emergency of our hospital. It was interesting to note that of the 117 patients who had orbital involvement, history of COVID-19 was positive in 80 (69%) patients. Ongoing vaccination drive by the government of India also is on way. Among the patients who presented to us and were admitted with a diagnosis of CAM, 16 patients had received vaccination against COVID-19. Thirteen were partially immunized and three were fully vaccinated. Administration of either of the two types of vaccine (Covishield/Covaxin) administered for protection against COVID-19 did not contribute to any statistically significant difference as far as the protection from contracting mucormycosis was concerned. Oxygen supplementation for the management of COVID-19 was seen in 57% of the cases in a large-scale collaborative OPAI-IJO (The Oculoplastics Association of India- Indian Journal of Ophthalmology) study.²⁸ It was pertinent to note that 43% of the patients did not require oxygen support for the treatment of COVID-19. This gave a pointer to that the fact that oxygen administration may not be an underlying factor responsible for causing ROCM. History of remdesivir and tocilizumab use was seen in 5 (9.4%) and 1 (0.9%) of cases in our study, respectively. Remdesivir and tocilizumab administration was observed in 10 and 2.1% of the patients included in the collaborative OPAI-IJO study, respectively. This data suggested that these two agents may not have a significant role in the causation of ROCM. Patel et al in their study conducted at 12 centers over a period of 1 year from 2016 to 2017 reported that ROM is the most common presentation (67.7%) of mucormycosis.⁷ The common predisposing factor was diabetes mellitus observed in 73.5% of patients. Of 241 patients admitted at our tertiary care center who were suffering from CAM, the retrospective analysis of the records of patients with orbital involvement revealed a few important observations. There was no significant difference in mortality between patients aged under 60 years or above 60 years who presented with stage 4 of ROCM. Positive history of COVID-19 or the state of residence also had no statistically significant association with mortality. Therefore, it is presumed that many individuals having no positive COVID-19 history or a documented positive RT-PCR testing presenting during the pandemic might be asymptomatic for usual clinical manifestations of COVID-19 and may still develop ROCM possibly as a result of immune dysregulation caused by SARS CoV-2. Presence of diabetes mellitus, immunocompromised state, and administration of corticosteroids correlated significantly with mortality. There was no statistically significant correlation of a patient undergoing orbital exenteration with old age, gender, positive history for COVID-19, diabetes mellitus, immunocompromised state, steroid administration, antiviral treatment, oxygen administration, orbital involvement on CT scan, presence of CST, stage 4, and administration of retrobulbar or peribulbar amphotericin B injection. IV amphotericin B was the primary drug therapy used in 81.9% of patients, oral/IV posaconazole was used along-with amphotericin B in 11.4% of the patients, and surgery was performed in 62.2% of the patients. The

subjects who underwent combined medical and surgical treatment had better survival. This got reflected in the lower mortality observed in patients who underwent sinonasal debridement (21/90 [23.3%]) and orbital exenteration (1/17 [5.9%]) apart from receiving IV amphotericin B. Sinus debridement is necessary in nearly all cases of mucormycosis as that is the principal source of the fungus.²⁹ Exenteration might be averted in cases who are metabolically stable and have a limited orbital disease that does not show progression. Poor metabolic control of diabetes mellitus during the COVID-19 pandemic has resulted in an increasing incidence of mucormycosis cases in India. However, the surge in cases of ROCM needs further research to determine the exact etiopathogenetic mechanism underlying this disease during the COVID-19 pandemic.

Our tertiary care hospital was designated as a dedicated COVID-19 hospital during the first and the second waves of COVID-19 experienced in India. Subsequently, as the number of cases of COVID-19 started to decline, a surge of ROCM cases was noted and the ophthalmology department along with the otorhinolaryngology department was dedicated to the management of the patients suffering from mucormycosis who presented to our hospital. The management approach was multipronged and involved other specialties including microbiology, radiodiagnosis, neurosurgery, and medicine departments. The patients presented mostly from Delhi and from the national capital region. The experience of the clinicians and paraclinical specialties evolved enormously to manage this epidemic of mucormycosis in every aspect from the establishment of diagnosis to surgical management especially the decision to perform exenteration in these patients.

ROM is reported in the literature with the largest number of cases (315 in number) that were reported in India prior to the COVID-19 pandemic from 12 tertiary level hospitals over a period of 1 year and 9 months.⁷ Our study is one of the large single-center experiences in about 300 patients of ROCM who presented during this epidemic of mucormycosis in a short time frame amidst COVID-19 pandemic. The mortality in 36 (31%) patients with ROCM patients may be even higher than that observed in non-COVID patients.^{26,27,30} Other salient feature of this study is the absence of positive history of COVID-19 or a documented positive RT-PCR testing in 36/116 (31.03%) individuals suffering from ROCM. These cases did not show any symptoms and might possibly be asymptomatic for clinical manifestations of COVID-19 and may still develop ROCM. Mortality was significantly higher in patients suffering from diabetes mellitus and were in an immunocompromised state as a result of HIV, hepatitis B or C. (27/116 [23.3%]). Administration of corticosteroids correlated significantly with mortality. In the absence of a large published data on the hospitalized patients suffering from COVID-19 in India, it is difficult to conclude if patients developing ROCM had received a higher amounts of oxygen supplementation as compared to the ones who did not develop ROCM. The limitation in this study was the retrospective nature of the study design wherein the clinical and demographic data could not be completely collected for all

aspects that were evaluated in the patients. Future studies would make this clinical scenario more understandable.

Note

Informed consent was taken from the patient for inclusion of clinical photographs in the case report.

Conflict of Interest

None declared.

References

- Singh AK, Singh R, Joshi SR, Misra A. Mucormycosis in COVID-19: a systematic review of cases reported worldwide and in India. *Diabetes Metab Syndr* 2021;15(04):102146
- Ravani SA, Agrawal GA, Leuva PA, Modi PH, Amin KD. Rise of the phoenix: mucormycosis in COVID-19 times. *Indian J Ophthalmol* 2021;69(06):1563–1568
- Sarkar S, Gokhale T, Choudhury SS, Deb AK. COVID-19 and orbital mucormycosis. [published correction appears in *Indian J Ophthalmol*. 2021 Jul;69(7):1978] *Indian J Ophthalmol* 2021;69(04):1002–1004
- Reference method for broth dilution antifungal susceptibility testing of filamentous fungi: approved standard—second edition. CLSI document M38–A2. Clinical and Laboratory Standards Institute, Wayne, PA: CLSI, 2008
- WHO Rapid Evidence Appraisal for COVID-19 Therapies (REACT) Working Group, Sterne JAC, Murthy S, et al. Association Between Administration of Systemic Corticosteroids and Mortality Among Critically Ill Patients With COVID-19: Meta-analysis. *JAMA* 2020;324(13):1330–1341
- Cornely OA, Alastruey-Izquierdo A, Arenz D, et al; Mucormycosis ECMMSG Global Guideline Writing Group. Global guideline for the diagnosis and management of mucormycosis: an initiative of the European Confederation of Medical Mycology in cooperation with the Mycoses Study Group Education and Research Consortium. *Lancet Infect Dis* 2019;19(12):e405–e421
- Patel A, Kaur H, Xess I, et al. A multicentre observational study on the epidemiology, risk factors, management and outcomes of mucormycosis in India. *Clin Microbiol Infect* 2020;26(07):944.e9–944.e15
- Pandey N, Kaushal V, Puri GD, et al. Transforming a general hospital to an infectious disease hospital for COVID-19 over 2 weeks. *Front Public Health* 2020;8:382
- Sen M, Lahane S, Lahane TP, Parekh R, Honavar SG. Mucor in a viral land: a tale of two pathogens. *Indian J Ophthalmol* 2021;69(02):244–252
- Pal R, Singh B, Bhadada SK, et al. COVID-19-associated mucormycosis: an updated systematic review of literature. *Mycoses* 2021;64(12):1452–1459
- Honavar SG. Code Mucor: guidelines for the diagnosis, staging and management of rhino-orbito-cerebral mucormycosis in the setting of COVID-19. *Indian J Ophthalmol* 2021;69(06):1361–1365
- Roden MM, Zaoutis TE, Buchanan WL, et al. Epidemiology and outcome of zygomycosis: a review of 929 reported cases. *Clin Infect Dis* 2005;41(05):634–653
- Chander J, Kaur M, Singla N, et al. Mucormycosis: Battle with the deadly enemy over a five-year period in India. *J Fungi (Basel)* 2018;4(02):46. Published 2018 Apr 6. Doi: 10.3390/jof4020046
- Rawson TM, Moore LSP, Zhu N, et al. Bacterial and fungal coinfection in individuals with coronavirus: a rapid review to support COVID-19 antimicrobial prescribing. *Clin Infect Dis* 2020;71(09):2459–2468
- Rootman J, Robertson W, Lapointe JS. Inflammatory diseases. In: Rootman J, ed. *Diseases of the Orbit. A Multidisciplinary Approach*. 1st edition. Philadelphia, PA: J. B. Lippincott Company; 1988:155–6

- 16 Brunet K, Rammaert B. Mucormycosis treatment: recommendations, latest advances, and perspectives. *J Mycol Med* 2020;30(03):101007
- 17 Trief D, Gray ST, Jakobiec FA, et al. Invasive fungal disease of the sinus and orbit: a comparison between mucormycosis and *Aspergillus*. *Br J Ophthalmol* 2016;100(02):184–188
- 18 Ibrahim AS, Spellberg B, Avanesian V, Fu Y, Edwards JE Jr. *Rhizopus oryzae* adheres to, is phagocytosed by, and damages endothelial cells in vitro. *Infect Immun* 2005;73(02):778–783
- 19 Kashkoul MB, Abdolalizadeh P, Oghazian M, Hadi Y, Karimi N, Ghazizadeh M. Outcomes and factors affecting them in patients with rhino-orbito-cerebral mucormycosis. *Br J Ophthalmol* 2019;103(10):1460–1465
- 20 Song G, Liang G, Liu W. Fungal co-infections associated with global COVID-19 pandemic: a clinical and diagnostic perspective from China. *Mycopathologia* 2020;185(04):599–606
- 21 Mehta S, Pandey A. Rhino-orbital mucormycosis associated with COVID-19. *Cureus* 2020;12(09):e10726
- 22 Mekonnen ZK, Ashraf DC, Jankowski T, et al. Acute invasive rhino-orbital mucormycosis in a patient with COVID-19-associated acute respiratory distress syndrome. *Ophthal Plast Reconstr Surg* 2021;37(02):e40–e80
- 23 Werthman-Ehrenreich A. Mucormycosis with orbital compartment syndrome in a patient with COVID-19. *Am J Emerg Med* 2021;42:264.e5–264.e8
- 24 Horby P, Lim WS, Emberson JR, et al; RECOVERY Collaborative Group. Dexamethasone in hospitalized patients with Covid-19. *N Engl J Med* 2021;384(08):693–704
- 25 Clinical guidance for management of adult COVID-19 patients. Accessed May 27, 2021 at: <https://covid.aiims.edu/clinical-guidance-for-management-of-adult-covid-19-patients/>
- 26 Lionakis MS, Kontoyiannis DP. Glucocorticoids and invasive fungal infections. *Lancet* 2003;362(9398):1828–1838
- 27 Kontoyiannis DP, Lewis RE. How I treat mucormycosis. *Blood* 2011;118(05):1216–1224
- 28 Sen M, Honavar SG, Bansal R, et al; members of the Collaborative OPAI-IJO Study on Mucormycosis in COVID-19 (COSMIC) Study Group. Epidemiology, clinical profile, management, and outcome of COVID-19-associated rhino-orbital-cerebral mucormycosis in 2826 patients in India - Collaborative OPAI-IJO Study on Mucormycosis in COVID-19 (COSMIC), Report 1. *Indian J Ophthalmol* 2021;69(07):1670–1692
- 29 Nithyanandam S, Jacob MS, Battu RR, Thomas RK, Correa MA, D'Souza O. Rhino-orbito-cerebral mucormycosis. A retrospective analysis of clinical features and treatment outcomes. *Indian J Ophthalmol* 2003;51(03):231–236
- 30 de Souza R, Mhatre S, Qayyumi B, et al. Clinical course and outcome of patients with COVID-19 in Mumbai City: an observational study. *BMJ Open* 2021;11(05):e042943