



Direct Carotid-Cavernous Fistula Caused by Internal Carotid Artery Perforation by a Microcatheter Body during Mechanical Thrombectomy

Satoshi Miyamoto^{1,2,3} Noriyuki Kato¹ Tomosato Yamazaki¹ Akinari Yamano¹ Yoshimitsu Akutsu¹
Susumu Yasuda¹ Yuji Matsumaru^{2,3} Eiichi Ishikawa³

¹Department of Neurosurgery, Mito Medical Center, Mito, Ibaraki, Japan

²Division of Stroke Prevention and Treatment, Faculty of Medicine, University of Tsukuba, Tsukuba, Ibaraki, Japan

³Department of Neurosurgery, Faculty of Medicine, University of Tsukuba, Tsukuba, Ibaraki, Japan

Address for correspondence Eiichi Ishikawa, MD, PhD, Department of Neurosurgery, Faculty of Medicine, University of Tsukuba, Tsukuba, Ibaraki, 305-8575, Japan (e-mail: e-ishikawa@md.tsukuba.ac.jp).

AJNS 2022;17:638–641.

Abstract

Keywords

- ▶ direct carotid-cavernous fistula
- ▶ mechanical thrombectomy
- ▶ internal carotid artery perforation
- ▶ perforation with the microcatheter

Rapid advances in emergent mechanical thrombectomy have resulted in a higher occurrence of arterial perforations during neurointerventions. Here, we report a case of internal carotid artery (ICA) perforation during mechanical thrombectomy in a 78-year-old man with a left middle cerebral artery occlusion. The ICA was perforated by a microcatheter during thrombectomy, forming a direct carotid-cavernous fistula. A two-stage drainer occlusion was conducted because of cortical venous reflex aggravation and ocular symptoms. Here, we report the perforation details and treatment, adding to evidence that ICA perforation with the microcatheter body is a concern during mechanical thrombectomy.

Introduction

Recently, reports of internal carotid artery (ICA) perforation during neurointerventions, especially mechanical thrombectomy, have increased.^{1–4} Urgent procedures are typically performed via thrombectomy as early intervention and reperfusion strongly correlate with good prognoses⁵; however, this might be causative for the increased number of reported ICA perforations. Here, we report a rare case of an ICA perforation by the microcatheter body during mechanical thrombectomy that led to iatrogenic carotid-cavernous fistula (CCF) formation

and then discuss treatment options for iatrogenic CCF during mechanical thrombectomy based on our outcome.

Case History

A 76-year-old man with bloody stools was admitted to our hospital for a colonoscopy. His past medical history included atrial fibrillation, aortic valve stenosis, mitral valve regurgitation, hypertension, dyslipidemia, diabetes mellitus, and ascending colon cancer. He was taking apixaban for cardioembolic stroke prevention, which had been stopped for the

article published online
October 19, 2022

DOI <https://doi.org/10.1055/s-0042-1757629>.
ISSN 2248-9614.

© 2022. Asian Congress of Neurological Surgeons. All rights reserved.

This is an open access article published by Thieme under the terms of the Creative Commons Attribution-NonDerivative-NonCommercial-License, permitting copying and reproduction so long as the original work is given appropriate credit. Contents may not be used for commercial purposes, or adapted, remixed, transformed or built upon. (<https://creativecommons.org/licenses/by-nc-nd/4.0/>)

Thieme Medical and Scientific Publishers Pvt. Ltd., A-12, 2nd Floor, Sector 2, Noida-201301 UP, India

colonoscopy. Two days after the colonoscopy, right hemiparesis, aphasia, and partial deviation of the eyes to the left occurred. The National Institute of Health Stroke Scale score was 23 and magnetic resonance imaging showed a left middle cerebral artery (MCA) occlusion requiring mechanical thrombectomy.

Mechanical Thrombectomy

A 9F 25 cm sheath was placed in the right femoral artery and a 9F OPTIMO (Tokai Medical Products, Aichi, Japan) guide catheter was introduced to the cervical portion of the left ICA. Left internal carotid arteriography (ICAG) showed proximal M2 occlusion. While the Marksman microcatheter (Medtronic, Minneapolis, Minnesota, United States) was navigating to M2 over a Chikai 14 microwire (ASAHI Intecc, Aichi, Japan), strong pressure was needed to pass through the occlusion site. Suddenly, the loop shape of the microcatheter in the syphon portion changed significantly (**►Fig. 1**). Left ICAG revealed a new direct CCF formation. Right ICAG showed cross-flow through the anterior communicating artery, supplying parts of the left MCA region, even though the M2 occlusion remained. The intervention was discontinued as we anticipated that left carotid compression twice a day would spontaneously close the CCF.

Carotid-Cavernous Fistula

However, proptosis, chemosis, and left extraocular movement dysfunction appeared on postoperative day 2 and treatment for symptomatic CCF was needed. Transvenous embolization failed because of the difficulty of the cavernous sinus (CS) approach; we then tried the transarterial approach and left ICAG showed a fistula at the medial posterior side of the ICA cavernous portion. The microcatheter was placed easily in the CS through the fistula, suspected to be quite

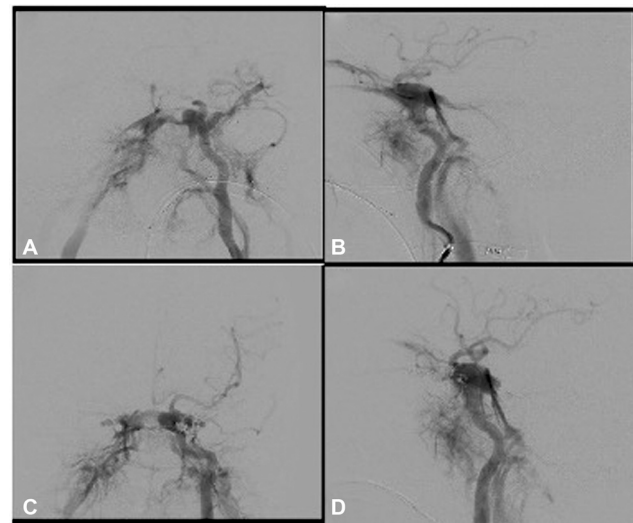


Fig. 2 The first direct CCF treatment: (A, B) ICAG before the treatment: a fistula is visible in the posterior part of the ICA cavernous segment. Dangerous draining veins, including the left SOV, SMCV, SPS, and inter-CS, were occluded. (C, D) ICAG after treatment: shunt flow reduction was achieved and distal flow is visible.

large, and a high possibility of coil migration into the ICA was likely. Therefore, we only occluded dangerous drainers, such as the left infraorbital vein, the superior orbital vein, the superficial middle cerebral vein, the superior petrosal sinus, and the inter-CS, to decrease the shunt flow (**►Fig. 2**). After the operation, left ocular symptoms improved. Carotid compression was maintained daily to induce clot formation within the direct CCF but right chemosis and proptosis appeared 3 months after the operation.

The second intervention was planned as a parental artery occlusion because of the large fistula size. Left ICAG showed

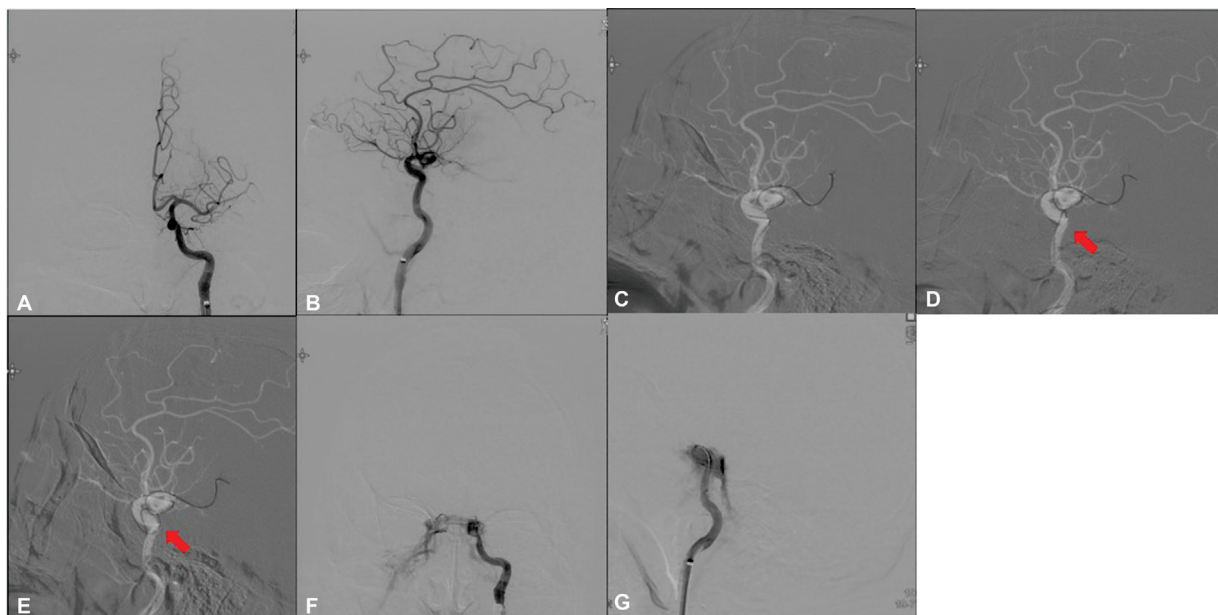


Fig. 1 Mechanical thrombectomy: (A, B) Left ICAG revealing a left M2 proximal occlusion. (C) The microcatheter was advanced over a microwire. (D, arrow) The shape of the microcatheter changed significantly in the syphon portion of the ICA. (E, arrow) The body of the microcatheter perforated the ICA wall and went into the cavernous sinus. (F, G) Left ICAG revealed a direct CCF. Shunt flow was abundant and ascending blood flow to the brain diminished. This complication halted the thrombectomy.

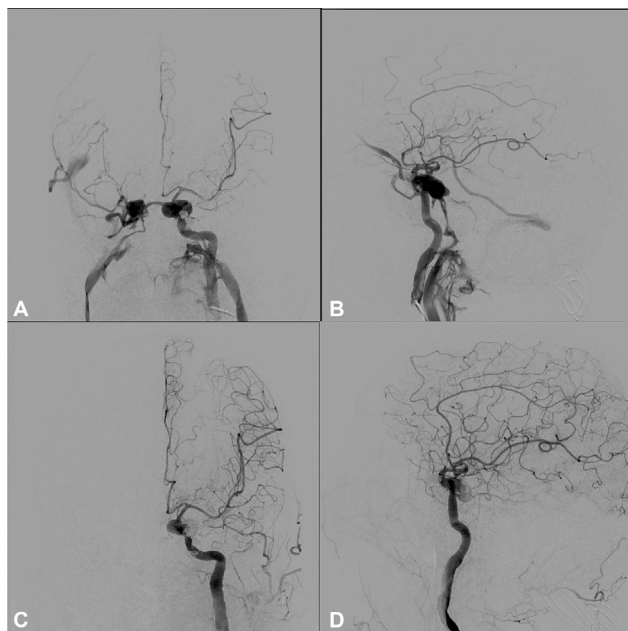


Fig. 3 The second direct CCF treatment: (A, B) ICAG before the treatment: a thin inter-CS is clearly seen. We occluded the inter-CS and left inferior petrosal sinus with a coil. (C, D) ICAG after treatment: the direct CCF is diminished with only a small hollow at the fistula. Ascending flow to the brain was recovered.

that the shunt flow drained mainly through a thin and clearly revealed inter-CS into the contralateral side of the CS. We thus switched to conduct sinus packing and occluded the inter-CS and left inferior petrosal sinus with a coil. Shunt flow diminished while antegrade flow was seen in the remaining small hollow of the CS (►Fig. 3). Right ocular

symptoms disappeared after the operation and the patient was transferred to another hospital with a modified Ranking Scale score of 5.

Discussion

Direct CCF

CCF is an abnormal connection between arteries and veins of the CS,⁶ causing ocular symptoms such as proptosis, chemosis, ocular bruit, and increased intraocular pressure, which lead to ophthalmic nerve injury and possibly severe conditions like cranial nerve palsy or cerebral infarction.^{3,6} Head trauma, ruptured aneurysm, and idiopathic CCF are the main causes of direct CCF,⁶ but some are iatrogenic in nature.^{3,6,7} Recently, reports of ICA perforation and iatrogenic CCF in neurointervention have increased because of escalating usage of the inner catheter, more and more emergent treatment, and adaptation to the elderly with often torturous or stenotic vessels.^{1,2,8} Although most iatrogenic CCF cases are type A by Barrow classification and their symptoms usually worsen rapidly,^{1,2} the ideal treatment time is still controversial.⁹ Risk factors of iatrogenic CCF are usage of distal access catheters, female sex, and paraclinoid aneurysms.⁸

Iatrogenic CCF Due to Mechanical Thrombectomy

Iatrogenic CCF occurrence is approximately 0.8% in interventional radiology, such as coil embolization of aneurysms and intracranial percutaneous transluminal angioplasty, but mechanical thrombectomy is only rarely causative.⁸ We searched PubMed with the term “thrombectomy” and/or “iatrogenic CCF” and found only nine direct CCF cases during mechanical thrombectomy^{1-3,10-12} (►Table 1); most of these (7 in 9) cases

Table 1 Summary of iatrogenic direct CCFs occurring during mechanical thrombectomy

Study (yr)	Age/sex	Occlusion site	Procedure	CCF Sx	Treatment for CCF	Follow-up
Akpınar et al (2014) ¹¹	NA	Rt. distal ICA	Stent retriever and local aspiration	NA	Conservative	Died in a few days
Alan et al (2017) ¹²	47 M	Rt. ICA terminus and MCA	Stent retriever and local aspiration	-	Conservative	Asymptomatic for 1.5 years
Alan et al (2017) ¹²	NA	Lt. ICA terminus to M1	Stent retriever and local aspiration	-	Conservative	Asymptomatic for 4 months
Alan et al (2017) ¹²	64 M	Rt. ICA and MCA	Stent retriever	+	Fistula occlusion	Asymptomatic for 2.5 years
Matsumoto et al (2018) ¹	67 F	Rt. M1	Stent retriever	+	Fistula occlusion	Asymptomatic for 3 months
Kurashiki et al (2019) ²	87 F	Rt. M1	Stent retriever	+	Fistula occlusion	NA
Sheinberg et al (2020) ³	78 F	Lt. MCA	Stent retriever and local aspiration	-	Fistula occlusion and pipeline	Asymptomatic for 6 months
Tsuji et al (2020) ¹⁰	88 F	Lt. ICA cavernous portion	Micro guide wire navigation	-	Balloon catheter to occlude ICA	Asymptomatic
Current study	76 M	Lt. M2	Microcatheter navigation	+	Drainer occlusion	Asymptomatic

Abbreviations: +, symptomatic; -, asymptomatic; CCF, carotid-cavernous fistula; ICA, internal carotid artery; Lt., left; MCA, middle cerebral artery; NA, not available; Rt., right; Sx, symptom.

occurred during the stent-retriever procedure as this straightens the ICA and risks pull-out injury of small vessels such as the meningohypophyseal trunk. Of the reported cases, four in nine cases were symptomatic, all treated with interventional radiology, while five in six treated cases, including asymptomatic cases, were without recurrence after treatment.

On the other hand, our case is the first case of direct CCF due to perforation with the microcatheter body. Regardless of cause, good reported outcomes of iatrogenic CCF during mechanical thrombectomy support interventional treatment.

ICA Damage during Microcatheter Navigation

In our case, pushing the microcatheter through hard clots led to a bent microcatheter in the ICA cavernous portion and perforation with the microcatheter body. Kurashiki et al and Matsumoto et al reported that a linearized ICA during stent retrieval leads to small branch pull-out injuries and direct CCF, especially in patients with severe atheromatous arteries,^{1,2} and, as we experienced, microcatheter bending in torturous arteries can also cause ICA injury.

As CCF due to microcatheter body compression is presumed to have a larger fistula than guidewire tip, microcatheter tip, or pull-out injuries of the meningohypophyseal trunk, simple fistula occlusion is difficult and second-line treatments, such as a flow-diverting stent, sinus packing, or parental artery occlusion, are necessary.

Reports of ICA injury due to microcatheter body compression during neurointervention radiology are currently scarce but case numbers are expected to rise because of the steep increase in neurointervention for elderly people with severe atheromatous arteries.

Conclusion

We experienced an iatrogenic CCF case due to ICA perforation with a microcatheter body during mechanical thrombectomy. We then conducted two-staged sinus packing and CCF occlusion was achieved. During mechanical thrombectomy, direct CCF formation during not only stent withdrawal but also microcatheter navigation is a constant concern.

Informed Consent

The authors certify that they have obtained all appropriate patient consent.

Conflict of Interest

Y.M. discloses lecturer fees from Medtronic, Stryker, Terumo, Johnson & Johnson, Cerenovas, Kaneka, Jimuro, and Medicos Hirata.

Acknowledgments

The authors would like to thank Dr. Alexander Zaboronok of the University of Tsukuba Faculty of Medicine Department of Neurosurgery for professional and language revision, and Dr. Bryan J. Mathis of the University of Tsukuba Hospital International Medical Center for language revision.

References

- 1 Matsumoto H, Nishiyama H, Takemoto H, Tetsuo Y, Nakao N. Carotid-cavernous fistula caused by vessel injury while withdrawing a stent retriever during mechanical thrombectomy for acute ischemic stroke: a case report. *J Neuroendovasc Therapy* 2018;12(05):235–240
- 2 Kurashiki Y, Hanaoka M, Sato K, et al. Occurrence of direct carotid-cavernous fistula during mechanical thrombectomy for middle cerebral artery occlusion. *Tokushima Red Cross Hosp Med J* 2019; 24:82–89
- 3 Sheinberg DL, Brunet MC, Chen SH, Luther E, Starke RM. Iatrogenic direct carotid-cavernous fistula following mechanical thrombectomy: a case report and review of the literature. *Cureus* 2020;12(04):e7524
- 4 Ryu CW, Lee CY, Koh JS, Choi SK, Kim EJ. Vascular perforation during coil embolization of an intracranial aneurysm: the incidence, mechanism, and clinical outcome. *Neurointervention* 2011;6(01):17–22
- 5 Bourcier R, Goyal M, Liebeskind DS, et al; HERMES Trialists Collaboration. Association of time from stroke onset to groin puncture with quality of reperfusion after mechanical thrombectomy: a meta-analysis of individual patient data from 7 randomized clinical trials. *JAMA Neurol* 2019;76(04):405–411
- 6 Henderson AD, Miller NR. Carotid-cavernous fistula: current concepts in aetiology, investigation, and management. *Eye (Lond)* 2018;32(02):164–172
- 7 Lewis AI, Tomsick TA, Tew JM Jr. Management of 100 consecutive direct carotid-cavernous fistulas: results of treatment with detachable balloons. *Neurosurgery* 1995;36(02):239–244, discussion 244–245
- 8 Ono K, Oishi H, Tanoue S, et al. Direct carotid-cavernous fistulas occurring during neurointerventional procedures. *Interv Neuroradiol* 2016;22(01):91–96
- 9 Kwon HJ, Jin SC. Spontaneous healing of iatrogenic direct carotid cavernous fistula. *Interv Neuroradiol* 2012;18(02):187–190
- 10 Tsuji Y, Miki T, Kakita H, Sato K, Yoshida T, Shimizu F. Mechanical thrombectomy for large vessel occlusion via the trans-brachial approach: case series. *Neurointervention* 2020;15(02):89–95
- 11 Akpınar SH, Gelener P, Kaymakamzade B. Complications of endovascular treatment in acute stroke patients: results from a tertiary referral center. *Int J Stroke* 2014;9:88–88
- 12 Alan N, Nwachuku E, Jovin TJ, Jankowitz BT, Jadhav AP, Ducruet AF. Management of iatrogenic direct carotid cavernous fistula occurring during endovascular treatment of stroke. *World Neurosurg* 2017;100:710.e15–710.e20