




Below Knee Angioplasty Using Drug-Eluting Balloons in Patients with Critical Limb Ischemia with Six Months Follow-Up: Single-Center Experience at Tertiary Care Hospital

Jawahar Rathod¹ Virender Sheorain² Shivprasad Jaybhay¹ Rajjat Shaikh¹  Pratik Bangde¹

¹Department of Radiodiagnosis & Intervention Radiology, Government Medical College and Hospital, Nagpur, Maharashtra, India

²Medanta The Medicity Hospital, Gurgram, Haryana, India

Address for correspondence Rajjat Shaikh, MD Radiology, Department of Radiology, GMCH, Room no 84, MARD Government Medical College and Hospital, Nagpur, Maharashtra, India-440003 (e-mail: dr.rajjat1707@gmail.com).

J Clin Interv Radiol ISVIR 2022;6:177–183.

Abstract

Purpose The aim of this study was to evaluate 6 monthly safety and primary patency rates of drug-eluting balloons (DEB) angioplasty in below-the-knee (BTK) arteries in critical limb ischemia (CLI) patients.

Methods A prospective observational study was conducted over 2 years in a tertiary care center. A total of 25 patients with CLI were enrolled in this study. Inclusion criteria were patients presenting with CLI (Rutherford class 4 or greater), equal to or more than 50% luminal stenosis or occlusion of at least one tibial artery, and agreement to 6-month evaluation. Exclusion criteria were life expectancy less than 1 year, allergy to paclitaxel, and contraindication to antiplatelet treatment.

Follow-up was performed by clinical and Doppler assessment. The primary endpoint was a 6-month primary patency rate, and secondary endpoints were changes in the Rutherford class and incidence of major amputation. Restenosis rate is defined as a reduction in the luminal diameter by 50% or greater by duplex ultrasound.

Results Six-month primary patency was achieved in 19 (76%) patients. Both Rutherford category improvement and reduction in the percentage of stenosis after angioplasty were statistically significant (p -value <0.0001). At 6 months, better patency rates were seen among diabetics (88.8%) than smokers (69.2%). Limb salvage was observed in 24 (96%) patients with one major amputation (above the ankle).

Conclusion DEBs have shown safe and promising clinical outcomes with successful performance in infrapopliteal arteries in the short-term follow-up. DEB had a substantial 6-month primary patency rate. DEB angioplasty is a safe and effective treatment option for CLI patients with BTK vascular disease.

Keywords

- ▶ drug-eluting balloon angioplasty
- ▶ Below knee angioplasty
- ▶ critical limb ischemia

article published online
October 14, 2022

DOI <https://doi.org/10.1055/s-0042-1757580>.
ISSN 2457-0214.

© 2022. Indian Society of Vascular and Interventional Radiology. All rights reserved.

This is an open access article published by Thieme under the terms of the Creative Commons Attribution-NonDerivative-NonCommercial-License, permitting copying and reproduction so long as the original work is given appropriate credit. Contents may not be used for commercial purposes, or adapted, remixed, transformed or built upon. (<https://creativecommons.org/licenses/by-nc-nd/4.0/>)

Thieme Medical and Scientific Publishers Pvt. Ltd., A-12, 2nd Floor, Sector 2, Noida-201301 UP, India

Introduction

Peripheral arterial disease (PAD) is a broad term that encapsulates a progressive disease occurring as a result of atherosclerotic plaque accumulation in the peripheral arterial system. Greater life expectancy and changed living habits have led to a progressively rising prevalence of atherosclerotic disease, making PAD an increasing burden on the healthcare system. The estimated prevalence of PAD is close to 200 million globally.¹ In India, the overall prevalence of PAD is 8.3%.² Krishnan et al reported age-adjusted prevalence of PAD was 26.7% in south India with no significant difference between rural and urban populations.³

Infrapopliteal (IP) atherosclerotic arterial disease, either alone or combined with femoropopliteal vascular disease, is the major cause of severe, function limiting, intermittent claudication, and rest pain.⁴ The incidence of IP disease is strongly correlated with the prevalence of diabetes mellitus and smoking. In its most advanced stages, patients present with ischemic rest pain or tissue loss known as critical limb ischemia (CLI). CLI is considered to be responsible for approximately 90% of the major amputations performed worldwide and is a significant cause of morbidity and mortality.^{5,6} Mortality rates as high as 20% within 6 months from diagnosis and exceeding 50% at 5 years have been reported in CLI patients due to generalized increased cardiovascular risk.⁷

Percutaneous balloon angioplasty (PBA) became the mainstay of the endovascular treatment strategy for IP artery disease. Compared with bypass surgery, the endovascular treatment appears to have lower periprocedure morbidity and mortality. However, restenosis caused by intimal hyperplasia remains the main limitation for PTA. The 1-year primary patency rate of PTA has been reported that was less than 50%.^{4,8} Drug-eluting balloon (DEB) and drug-eluting stent (DES) seem to be promising solutions for restenosis by inhibiting intima hyperplasia.

DEBs available today utilize paclitaxel in combination with different excipients.⁹ Paclitaxel is used as an antiproliferative agent for the prevention of restenosis. The purpose of this study is to determine patency rate and restenosis rate and discuss the safety and clinical efficacy of DEB angioplasty in the treatment of below-the-knee arterial lesions and the variables which affect their patency rate.

Materials and Methods

A single-center prospective observational study was conducted over 2 years in the interventional radiology department in a tertiary care hospital. Permission from the ethics committee and institutional review board was obtained. All patients presenting with CLI who were planned to undergo angioplasty of at least one BTK vessel, either alone or in conjunction with a more proximal endovascular recanalization procedure, were assessed for enrollment in this study. Most of the patients were diabetic and smokers. Written informed consent with all preinformed risks of the procedure was obtained from all the patients before the procedure. Inclusion criteria were patients presenting with CLI (Ruther-

ford category 4 or greater), equal to or more than 50% luminal stenosis or occlusion of at least one tibial artery, and agreement to 6-month evaluation. Exclusion criteria were life expectancy less than 1 year, allergy to paclitaxel, and contraindication to combined antiplatelet treatment and pregnancy.

Pretreatment ultrasonography (USG) Doppler study provided the necessary information related to the site of lesion, percentage of stenosis, plaque characteristics, peak systolic velocity (PSV) at the lesion site, and spectral waveform in the affected vessel (► **Fig. 1A**). Under all aseptic precautions, ipsilateral antegrade common femoral artery access is taken under USG guidance. Pedal puncture and pedal access were taken in the two cases. Most of the patients received antiplatelet therapy before the procedure for 1 to 2 weeks and a bolus dose at least 1 hour before the procedure. After sheath insertion, 5000 IU (70 IU/kg) heparin was administered through the intravenous route. Lower limb angiography of the affected limb was performed with inj. iohexol 350 mg/mL contrast, using headhunter/cobra catheter and guidewire through angio sheath. After identifying the lesion, the IP lesion was negotiated with the special peripheral 0.014"/0.018" guidewire with a support catheter, combined with variable tip loads; the wire was parked distal to the lesion. The stenotic lesions were dilated with a plain balloon first then an appropriate-sized DEB balloon was inflated at the lesion site in the occluded segment of the artery. The appropriate dimensions of balloons were selected to ensure a minimum coverage of not more than 5 mm both proximal and distal to the lesion and a proper ratio of the balloon to a vessel diameter of 1:1. Inflation time was at least 90 to 180 seconds. A check angiogram was performed after the angioplasty (► **Fig. 1B**).

Postangioplasty dual antiplatelet (aspirin 75 mg and clopidogrel 75 mg) daily therapy was continued for at least 6 months. A duplex USG scan was done just after the procedure. Patients were asked for follow-up at 1 and 6 months, and more frequently when needed. Follow-up included clinical assessment (Rutherford category), the incidence of any amputation or other complications, medication compliance, and duplex USG examination to estimate restenosis and to determine patency rate (► **Figs. 1C** and **2D**).

The primary endpoint was a 6-month primary patency rate, and secondary endpoints were changes in the Rutherford class and major amputations. Clinical success was defined as improvement in the Rutherford category, healing of the ulcer, or minor amputation. Limb salvage was achieved when the plantar stand (to maintain an upright position on the feet) was maintained, even if tarsometatarsal amputation had to be done. Any above-the-ankle amputation (major amputation) was considered a failure of the angioplasty. Restenosis rate is defined as a reduction in the luminal diameter by 50% or greater by duplex USG.

Baseline and procedural characteristics were described using mean and standard deviation (► **Table 1**). Statistical significance was defined as a *p*-value less than 0.05. We have used the "parametric-paired t-test," which is the method used to test the significance of changes in the mean difference between pairs of measurements (pre- and postangioplasty) in the same group. When the data was not distributed equally,

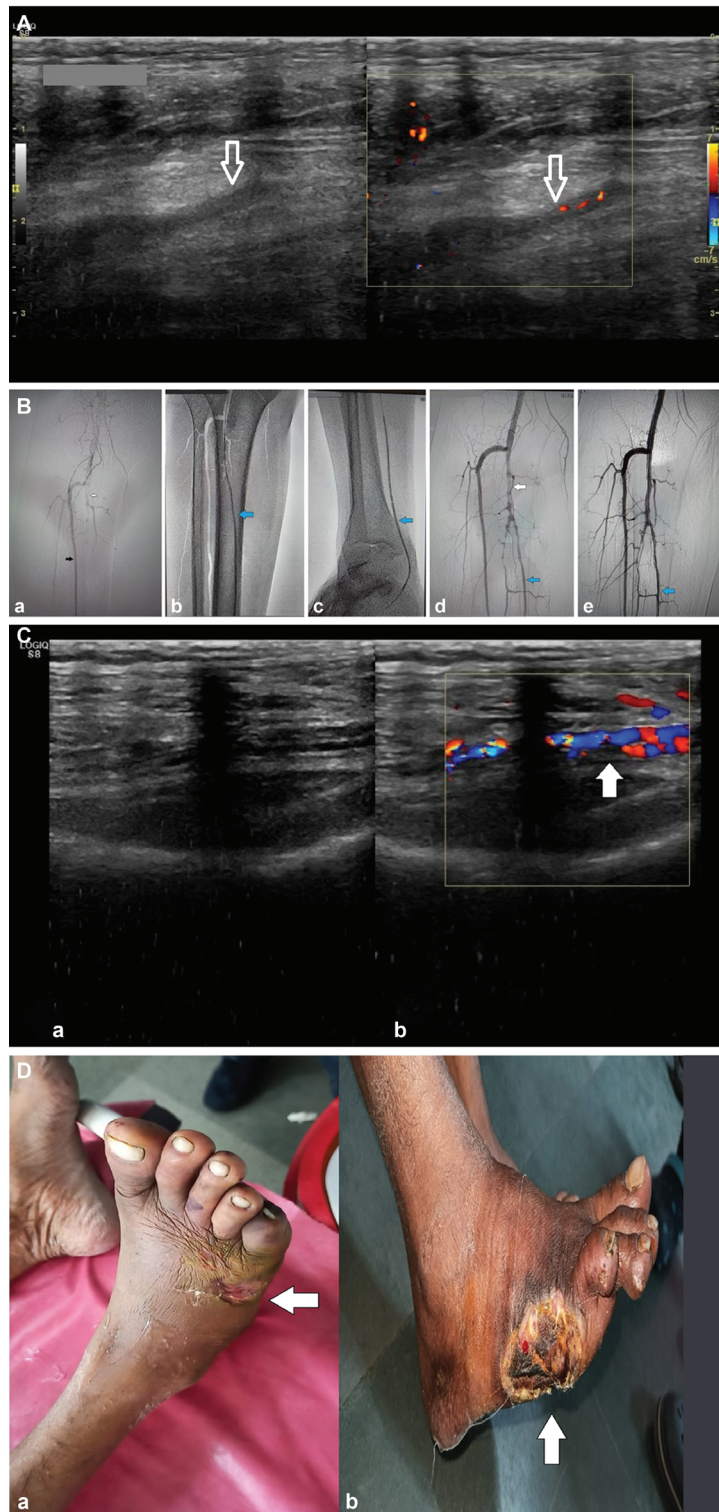


Fig. 1A Pretreatment Doppler in the longitudinal section at the middle part of the right leg reveals complete thrombotic occlusion of the right posterior tibial artery (PTA) (white arrow) with no flow detected in the vessel. **Fig. 1B** Digital subtraction angiography of below the knee arteries demonstrates: a. Faint opacification of tibioperoneal trunk (white arrow) and nonvisualization of PTA and peroneal artery. Anterior tibial artery (ATA; black arrow) shows optimal opacification. b. Balloon angioplasty of proximal PTA (blue arrow). c. Balloon angioplasty of distal PTA (blue arrow). d. Postangioplasty check angiogram revealed irregular short tight strictures of the tibioperoneal trunk (white arrow), optimal opacification PTA (blue arrow), and peroneal artery. Balloon mounted bare-metal stent was deployed in the tibioperoneal trunk to tackle the short segment strictures. e. Post-drug-eluting balloon and poststent angiogram showing good opacification of tibioperoneal trunk, PTA (blue arrow), and peroneal artery. **Fig. 1C** Follow-up Doppler at 6 months, gray scale (a) and color Doppler images (b) in longitudinal section reveal restoration of blood flow in right distal PTA (white arrow) with peak systolic velocity of 22 cm/s and residual stenosis less than 50%. **Fig. 1D** Pre- (a) and (b) postangioplasty clinical pictures of the right foot of the patient: a) Ulceration with gangrenous changes and edema seen on the lateral aspect of the right foot and fifth toe (white arrow). b) The lateral part of the right foot with the gangrenous right fifth toe was amputated; the ulcer healed well with resolution of the edema and discoloration of the rest of the foot with clinical improvement in Rutherford class (white arrow).

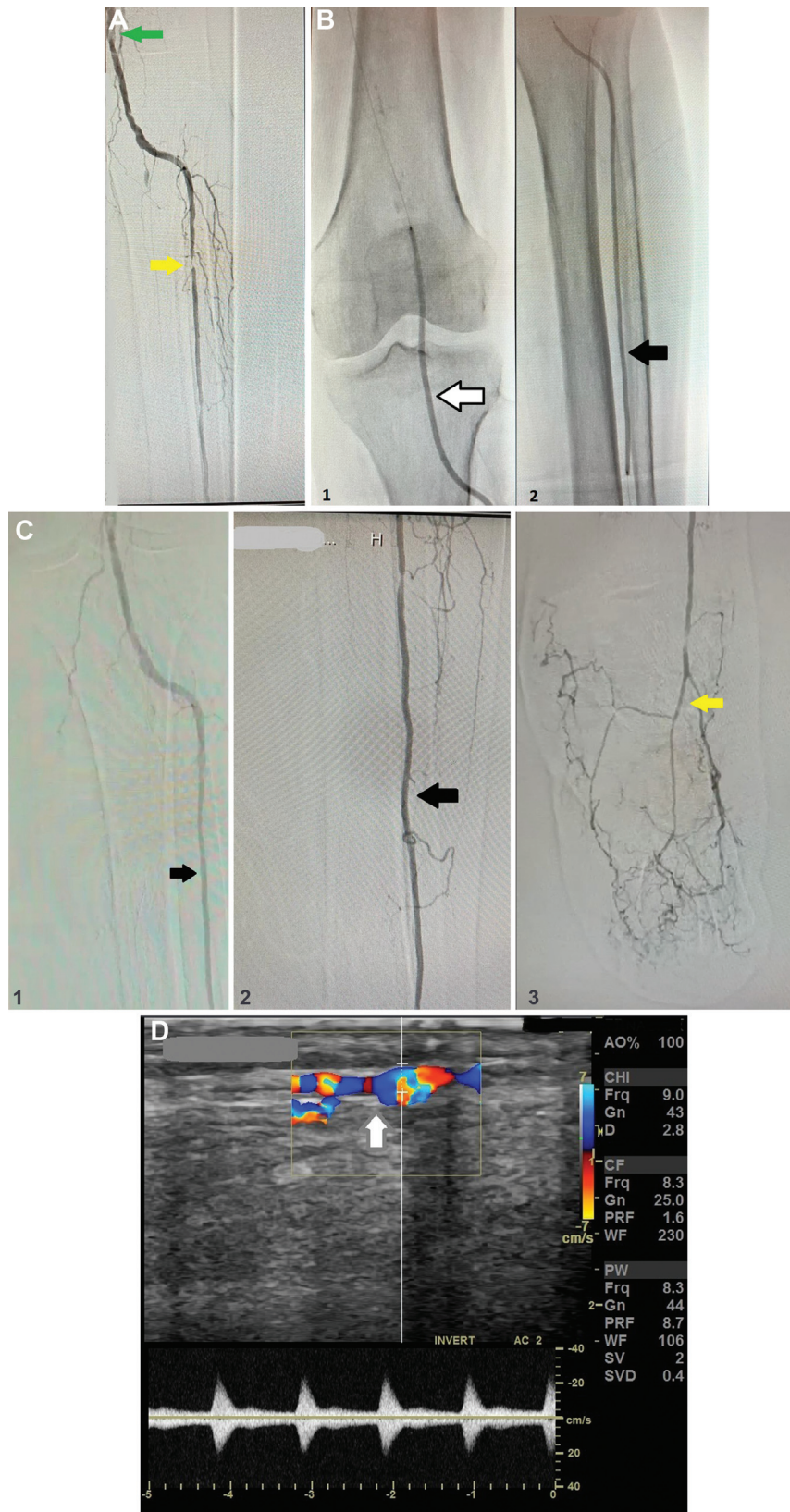


Fig. 2A : a) Pre-procedure digital subtraction angiography (DSA) of below the knee arteries of the left leg demonstrates narrow caliber proximal ATA with multiple areas of short segment critical stenosis (yellow arrow) involving the proximal and mid-ATA. Below knee popliteal artery appears narrow & irregular with filling defects suggestive of stenotic plaques (green arrow). Nonopacification of the entire PTA, and peroneal artery. **Fig. 2B** 1. Balloon angioplasty of below-knee popliteal artery (white arrow). 2. Balloon angioplasty of anterior tibial artery (ATA; black arrow). **Fig. 2C** (1,2,3) Postprocedure DSA angiogram reveals successful dilatation of popliteal artery, proximal and distal ATA (black arrow) and dorsalis pedis artery (yellow arrow). **Fig. 2D** Follow-up Doppler at 6 months, gray scale (a), and color Doppler images (b) in longitudinal section reveal restoration of blood flow in left distal ATA (white arrow) with peak systolic velocity of 26 cm/sec and biphasic waveform.

Table 1 Relevant pretreatment clinical and angiographic characteristics of the patients

Comorbidity	No. of patients	Percentage
Number of patients	25	Male–22 (88%) Female–03 (12%)
Age range (years)	38-78	
Diabetes	12	48
Smoking	16	64
Heart disease	3	12
Hypertension	10	40
Dyslipidemia	3	12
Obesity	2	8
Category IV (rest pain)	11	44
Category V (focal gangrene)	14	56
Completely occluded vessel	06	
Lesion length (Mean + SD)	13.8 ± 2.9 cm	
Patency rate (Stenosis < 50)	19	76

Abbreviation: SD, standard deviation.

we performed a “nonparametric test–Wilcoxon Signed-Rank” test to analyze the data (→Table 2).

Results

In this study, a total of 25 patients in the age group 38 to 78 years who presented with CLI were included. The most common age group was 51 to 60 years. Most of the patients were male (88%). The mean age of presentation was 53.23 years for males and 57.05 years for females. Twelve patients were diabetic (48%), and 16 patients were smokers (64%). Eleven (44%) patients presented with ischemic rest pain (grade IV), and 14 (56%) patients presented with gangrene and minor tissue loss (grade V).

More than one vessel was involved in most of the cases (→Table 3). The most commonly treated vessel was the

Table 2 Relevant pre- and postintervention clinical and imaging data correlation

	Pretreatment Mean ± SD	Posttreatment Mean ± SD	p-Value
Mean % of stenosis	94.4 ± 5.5	57 ± 22.59	< 0.0001, HS
Rutherford category	4.56 ± 0.51	3.6 ± 0.81	< 0.0001, HS
PSV (stenotic vessels)	52.2 ± 3.35	27 ± 7.6	0.0008

Abbreviations: HS, highly significant; PSV, peak systolic velocity; SD, standard deviation.

Table 3 Distribution of the disease in below the knee arteries

Site of lesion	No. of patients
ATA	22
PTA	16
Peroneal artery	05
Tibioperoneal trunk	2
Infrainguinal popliteal artery	2

One vessel involved	9	ATA
Two vessels involved	14	ATA+ PTA- 11 PTA + PERONEAL-03
Three vessels involved	2	ATA+ PTA + Peroneal

Abbreviations: ATA, anterior tibial artery; PTA, posterior tibial artery.

anterior tibial artery. The mean pretreatment PSV values were 52.2 ± 3.35 cm/s in the stenotic vessels; they reduced to 29.4 ± 2.1 cm/s immediately after the treatment and 27 ± 7.6 cm/s at 6 months follow-up. Pretreatment percentages of stenosis and Rutherford category were 94.4 ± 5.5, 0.41 ± 0.09, and 4.56 ± 0.51, respectively.

Technical success was defined as uncomplicated revascularization and residual stenosis equal to or less than 30% in the treatment of inflow lesions and it was achieved in all cases without procedure-related death within 1 month. Two (8%) patients had small puncture site hematoma formation just after the procedure that resolved automatically after proper compression bandage. No other immediate procedure-related complication was found just within 2 to 3 days of the surgery and during the first month of follow-up (→Table 4). Primary patency was achieved in 19 vessels (76%) at 6 months. Better patency rates were seen among the diabetic patients (88.8%) than the smokers (69.2%).

A higher patency rate of 90.9% was found in the patients presenting with rest pain than the patency rate of 64.3% seen in the patients presenting with minor ulcer/gangrene at 6 months of follow-up. There is a significant posttreatment reduction in the mean percentage of stenosis (57 ± 22.59, $p < 0.0001$, highly significant [HS]), and the mean Rutherford category (3.6 ± 0.81, $p < 0.0001$, HS) after DEB angioplasty at 6 months.

Table 4 Number of complications during 6-month follow-ups

	No of patient	Percentage
All-cause mortality	0	0
All amputation	7	28
Major amputation	1	4
Minor amputation	6	24
Restenosis/occlusion	6	24
Punctures site bleeding/hematoma	2	8

Reasonably good ulcer healing was observed at the end of 6 months. Seven of our patients presented in a partial/complete gangrenous state. Ulcer healing was not expected in these patients.

Angioplasty was performed in these cases to lower the amputation level, and also for better stump healing. Limb salvage was obtained in 24 (96%) patients with one major amputation (above the ankle). Minor amputations were one forefoot amputation and five toe amputations (–**Figs. 1D-a** and **1D-b**). The angioplasty improved the healing of minor ulcers and amputation stumps healed well with conservative measures after angioplasty.

Discussions

PAD is an important manifestation of atherosclerotic vascular disease and is common among middle- and old-age patients in India. Diabetes, hypertension and smoking, and obesity are important risk factors. Compared with other forms of cardiovascular disease, relatively little attention has been paid to the overall prevalence of PAD.¹⁰ PAD is at high risk for the development of CLI with nonhealing foot wounds. CLI is classically a disease with a poor prognosis concerning limb preservation.^{11,12} These patients are often not suitable surgical candidates due to concomitant disease and advanced age, making endovascular therapy preferable.

Doppler USG of the lower extremity arteries is a reliable technique, with overall sensitivities for predicting tibial artery patency (90% for the anterior tibial artery and PTA, and 82% for the peroneal). The clinical disease category had no significant effect on the accuracy of Doppler USG in below-knee vessels. Doppler USG has been shown to differentiate between stenosis with a diameter reduction larger than or less than 50% (equivalent to 70% area reduction) with a sensitivity of 77 to 82% and a specificity of 92 to 98%.

Over the past two decades, the prognosis for limb salvage and survival in CLI patients has improved, with data showing a decrease in major amputation rates in the CLI population.^{13–15} Different endovascular treatment modalities have been used for peripheral vascular recanalization. In the BTK vessels, PTA remained the most widely used method for recanalization but was significantly limited by the high restenosis or occlusion rates.^{8,16}

More recently, DEB has emerged as an effective endovascular modality that is used for recanalization in BTK vessels, with presumably higher patency rates in the long term. Apart from single-center experiences, there are few organized studies in literature properly assessing this presumption. The mechanism of balloon angioplasty consists of adventitial stretching, medial necrosis, and dissection or plaque fracture.^{17,18}

In this prospective observational study, we have evaluated the safety and efficacy in terms of 6 monthly primary patency rates of DEB in BTK arterial disease presented with CLI. The results showed that DEB achieved promising clinical outcomes with successful performance in IP arteries in the short-term follow-up with a substantial primary patency rate (76%) that is much better as compared to standard percutaneous transluminal angioplasty (38%).¹⁹ Our findings

are consistent with those reported previously in both single-center types of research that evaluated 3 months' restenosis in randomly selected CLI patients.^{20–22} These patients were treated with about the same DEB framework as in this study and the DEB in peripheral intervention for below the knee angioplasty evaluation study.^{8,23} Restenosis/occlusion (loss of patency) is a result of early failure of interventional transcatheter recanalization, which has been associated with limb loss as well as a poor prognosis.²⁴

Diabetes and smoking are important and independent risk factors for the development of peripheral vascular disease. DEB angioplasty showed a better outcome in diabetic patients than the smokers. These results are consistent with the study of Faglia et al who showed percutaneous angioplasty as the first-choice revascularization procedure in a high percentage of diabetic patients. In their study, clinical restenosis was an infrequent event and angioplasty could successfully be repeated in most cases.^{25,26}

Improved clinical status is observed in most of the patients after the DEB angioplasty in the form of a significant reduction in the Rutherford category, better ulcer and amputation stump healing. The major (above the ankle) amputation rate was very low after DEB angioplasty with few minor amputations of unsalvageable gangrenous toes and forefoot. Minor ulcers and amputation stumps healed well (–**Fig. 1D-a** and **1D-b**). This emphasizes that the DEB angioplasty improves ulcer healing and helps to lower the amputation level. Increased risk of death has been reported following the application of paclitaxel-coated balloons and stents in the femoropopliteal artery angioplasty in one of the meta-analyses.²⁷ However, in this study, no all-cause mortality has been seen during the first 6 months of follow-up.

This study has been done in a single center with a small sample size. Larger multicenter randomized trials are needed with long-term follow-up to assess whether this higher patency will reflect positively on limb salvage and to establish a more accurate and definite result that can be applied to the larger population.

Conclusions

DEBs have shown safe and good clinical outcomes with successful performance in IP arteries in the initial 6 months follow-up. DEB had a good 6-month primary patency rate with considerably better posttreatment clinical status of the patients in the form of a significant reduction in the Rutherford category and better ulcer healing. DEB angioplasty has higher technical success rates with low rates of procedure-related complications, especially in diabetic patients. DEB angioplasty has reasonably lesser major amputation rates at short-term follow-up.

Financial Support and Sponsorship
Nil.

Informed Consent

Written informed consent was obtained from all patients for publication of this clinical data and any accompanying images.

Conflicts of Interest

There are no conflicts of interest.

References

- Kokkinidis DG, Armstrong EJ. Current developments in endovascular therapy of peripheral vascular disease. *J Thorac Dis* 2020;12(04):1681–1694
- Pradeepa R, Chella S, Surendar J, Indulekha K, Anjana RM, Mohan V. Prevalence of peripheral vascular disease and its association with carotid intima-media thickness and arterial stiffness in type 2 diabetes: the Chennai urban rural epidemiology study (CURES 111). *Diab Vasc Dis Res* 2014;11(03):190–200
- Krishnan MN, Geevar Z, Mohanan PP, Venugopal K, Devika S. Prevalence of peripheral artery disease and risk factors in the elderly: a community based cross-sectional study from northern Kerala, India. *Indian Heart J* 2018;70(06):808–815
- Spiliopoulos S, Vasiniotis Kamarinos N, Brountzos E. Current evidence of drug-elution therapy for infrapopliteal arterial disease. *World J Cardiol* 2019;11(01):13–23
- Duff S, Mafilios MS, Bhounsule P, Hasegawa JT. The burden of critical limb ischemia: a review of recent literature. *Vasc Health Risk Manag* 2019;15:187–208
- Norgren L, Hiatt WR, Dormandy JA, Nehler MR, Harris KA, Fowkes FGTASC II Working Group. Inter-Society Consensus for the Management of Peripheral Arterial Disease (TASC II). *J Vasc Surg* 2007;45(Suppl S):S5–S67
- Teraa M, Conte MS, Moll FL, Verhaar MC. Critical limb ischemia: current trends and future directions. *J Am Heart Assoc* 2016;5(02):e002938. Doi: 10.1161/JAHA.115.002938
- Haddad SE, Shishani JM, Qtaish I, Rawashdeh MA, Qtaishat BS. One year primary patency of infrapopliteal angioplasty using drug-eluting balloons: single center experience at King Hussein Medical Center. *J Clin Imaging Sci* 2017;7:31. Doi: 10.4103/jcis.JCIS_34_17
- Barkat M, Torella F, Antoniou GA. Drug-eluting balloon catheters for lower limb peripheral arterial disease: the evidence to date. *Vasc Health Risk Manag* 2016;12:199–208
- Rajagopalan S, DelleGrottaglie S, Furniss AL, et al. Peripheral arterial disease in patients with end-stage renal disease: observations from the Dialysis Outcomes and Practice Patterns Study (DOPPS). *Circulation* 2006;114(18):1914–1922
- Olivieri B, Yates TE, Vianna S, Adenikinju O, Beasley RE, Houseworth J. On the cutting edge: wound care for the endovascular specialist. *Semin Intervent Radiol* 2018;35(05):406–426
- Gerhard-Herman MD, Gornik HL, Barrett C, et al. 2016 AHA/ACC guideline on the management of patients with lower extremity peripheral artery disease: executive summary: a report of the American College of Cardiology/American Heart Association Task Force on Clinical Practice Guidelines. *Circulation* 2017;135(12):e686–e725
- Hong MS, Beck AW, Nelson PR. Emerging national trends in the management and outcomes of lower extremity peripheral arterial disease. *Ann Vasc Surg* 2011;25(01):44–54
- Zhu ZR, Zou L, Xing Y, et al. Predictors of primary patency after percutaneous balloon angioplasty for stenosis of Brescia-Cimino hemodialysis arteriovenous fistula. *Br J Radiol* 2020;93(1109):20190505. Doi: 10.1259/bjr.20190505
- Patel A, Irani FG, Pua U, et al. Randomized controlled trial comparing drug-coated balloon angioplasty versus conventional balloon angioplasty for treating below-the-knee arteries in critical limb ischemia: the SINGA-PACLI trial. *Radiology* 2021;300(03):715–724
- Garcia D, Ansari M, Cardoso R, et al. Meta-analysis of drug-coated balloon versus standard balloon angioplasty for treatment of infrapopliteal lesions in critical limb ischemia. *J Am Coll Cardiol* 2016;67(13, Supplement):2254–2254
- Giannopoulos S, Ghanian S, Parikh SA, Secemsky EA, Schneider PA, Armstrong EJ. Safety and efficacy of drug-coated balloon angioplasty for the treatment of chronic limb-threatening ischemia: a systematic review and meta-analysis. *J Endovasc Ther* 2020;27(04):647–657
- Giannopoulos S, Varcoc RL, Lichtenberg M, et al. Balloon angioplasty of infrapopliteal arteries: a systematic review and proposed algorithm for optimal endovascular therapy. *J Endovasc Ther* 2020;27(04):547–564
- Ipema J, Huizing E, Schreve MA, de Vries JPM, Ünlü Ç Editor's Choice—Drug coated balloon angioplasty vs. standard percutaneous transluminal angioplasty in below the knee peripheral arterial disease: a systematic review and meta-analysis. *Eur J Vasc Endovasc Surg* 2020;59(02):265–275
- Schmidt A, Piorowski M, Werner M, et al. First experience with drug-eluting balloons in infrapopliteal arteries: restenosis rate and clinical outcome. *J Am Coll Cardiol* 2011;58(11):1105–1109
- Steiner S, Schmidt A, Bausback Y, et al. Single-center experience with Lutonix drug-coated balloons in infrapopliteal arteries. *J Endovasc Ther* 2016;23(03):417–423
- Single-Center Experience With Lutonix Drug-Coated Balloons in Infrapopliteal Arteries - PubMed Accessed September 15, 2022, at: <https://pubmed.ncbi.nlm.nih.gov/27099285/>
- Liistro F, Porto I, Angioli P, et al. Drug-eluting balloon in peripheral intervention for below the knee angioplasty evaluation (DEBATE-BTK): a randomized trial in diabetic patients with critical limb ischemia. *Circulation* 2013;128(06):615–621
- Results of second-time angioplasty and stenting for femoropopliteal occlusive disease and factors affecting outcomes - PubMed. Accessed September 15, 2022, at: <https://pubmed.ncbi.nlm.nih.gov/21129908/>
- Faglia E, Clerici G, Clerissi J, et al. Long-term prognosis of diabetic patients with critical limb ischemia: a population-based cohort study. *Diabetes Care* 2009;32(05):822–827
- Abou-Zamzam AM Jr, Gomez NR, Molkara A, et al. A prospective analysis of critical limb ischemia: factors leading to major primary amputation versus revascularization. *Ann Vasc Surg* 2007;21(04):458–463
- Katsanos K, Spiliopoulos S, Kitrou P, Krokidis M, Karnabatidis D. Risk of death following application of paclitaxel-coated balloons and stents in the femoropopliteal artery of the leg: a systematic review and meta-analysis of randomized controlled trials. *J Am Heart Assoc* 2018;7(24):e011245. Doi: 10.1161/JAHA.118.011245