



Assessment of Pleural Effusion by Means of Imaging Modalities

Swati Kumari¹ M.M. Jaseemudheen¹

¹Department of Radiodiagnosis and Imaging, KS Hegde Medical Academy (KSHEMA), Nitte (Deemed to be University), Mangalore, India

J Health Allied Sci^{NU} 2023;13:301–305.

Address for correspondence M.M. Jaseemudheen, MSc, Department of Radiodiagnosis and Imaging, KS Hegde Medical Academy (KSHEMA), Nitte (Deemed to be University), Mangalore, Karnataka 575018, India
(e-mail: jaseemudheen12@gmail.com; jaseemudheen@nitte.edu.in).

Abstract

Pleural effusion is the fluid collection in the pleural cavity between the parietal and visceral pleura. It is caused by parenchymal diseases such as inflammatory disorders or infection. Pleural effusion can be diagnosed using imaging modalities such as X-ray, computed tomography (CT) scan, ultrasound, and magnetic resonance imaging (MRI). MRI is rarely performed to investigate pleural effusion due to motion artifacts and has a poor spatial resolution. Benign and malignant pleural effusion can be diagnosed using an X-ray, CT scan, or ultrasound. Pleural effusion volume can be measured by using ultrasound. This article reviews the feasibility of investigating pleural effusion and fluid drainage in medical imaging and compares to find the best modality for its diagnosis. **Description:** This article reports the possible options to detect pleural effusion in medical imaging and compares them to find the best modality for its diagnosis.

Keywords

- ▶ pleural effusion
- ▶ pleural effusion volume
- ▶ contrast-enhanced computed tomography

Introduction

Pleural effusion is the fluid collection in the pleural cavity, which is situated between the parietal and visceral pleura. It is caused on its own or due to parenchymal diseases such as infection, inflammatory disorders, or cancer. Pleural effusion is the leading cause of respiratory mortality and morbidity.¹ A small amount of pleural fluid lubricates the membrane and allows regular breathing in all healthy individuals. The lymphatic drainage, oncotic pressure, and hydrostatic pressures control this delicate fluid balance, and disturbances in either of these systems may lead to the build-up of pleural fluid.² Based on modified Light's criteria, pleural fluid is divided into transudate or exudate. If any one of the conditions is satisfied then the fluid is considered as exudative effusion: the ratio of protein pleural fluid to serum protein is more than 0.5, the ratio of lactate dehydrogenase (LDH)/serum LDH greater than 0.6, and LDH pleural fluid exceeds two-thirds of the upper limit of serum LDH.^{3,4}

This review summarizes the various evidence-based applications of all imaging modalities in the assessment of pleural illnesses, as well as how their application improves patient safety and accuracy. The review also gives an overview of how chest radiographs, ultrasounds, and CT scans can play an important role in pleural illness.

Characteristics of Pleural Effusion

The normal amount of pleural fluid in the right and left pleural space is 8.4 ± 4.3 mL, and in non-smoker individuals, the total pleural fluid per kilogram of body mass is 0.26 ± 0.1 mL/kg.⁵ Formulas have been proposed for the quantification of pleural fluid volume under ultrasound guidance.^{6–8} Pleural fluid is identified by dynamic signs such as a change in echo-free space during the respiratory cycle,⁹ compressed lungs, or atelectatic and swirling motion in the echo-free space.¹⁰

article published online
October 17, 2022

DOI <https://doi.org/10.1055/s-0042-1757446>.
ISSN 2582-4287.

© 2022. The Author(s).

This is an open access article published by Thieme under the terms of the Creative Commons Attribution License, permitting unrestricted use, distribution, and reproduction so long as the original work is properly cited. (<https://creativecommons.org/licenses/by/4.0/>)
Thieme Medical and Scientific Publishers Pvt. Ltd., A-12, 2nd Floor, Sector 2, Noida-201301 UP, India

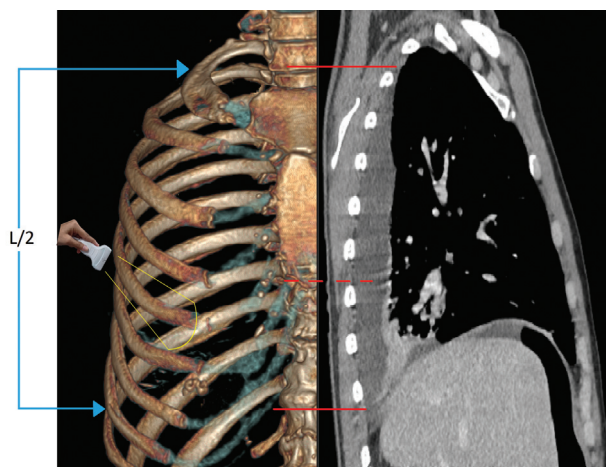


Fig. 1 Diagram depicting quantification of PE.

Quantify Pleural Effusion

The left side image shows that the ultrasound probe is placed at the level of mid-thorax for measuring the cross-sectional area of PE, and the right-side image shows right lung two-dimensional computed tomography (2D CT) reconstruction in one of the patients who had PE. The thin arrows (blue) indicate the PE length (L), and the dashed line (red) indicates the intercoastal gap where the cross-sectional area (A) of PE was measured. Then the length of each paravertebral intercostal gap was measured⁸ (**Fig. 1**).

Calculation of Pleural Effusion Volume

The patient was positioned in supine. The pleural cavity was visualized in the axial plane by placing the probe in each paravertebral intercostal space. The probe was slid posteriorly to visualize the pleural cavity. The length of PE (L_{us})

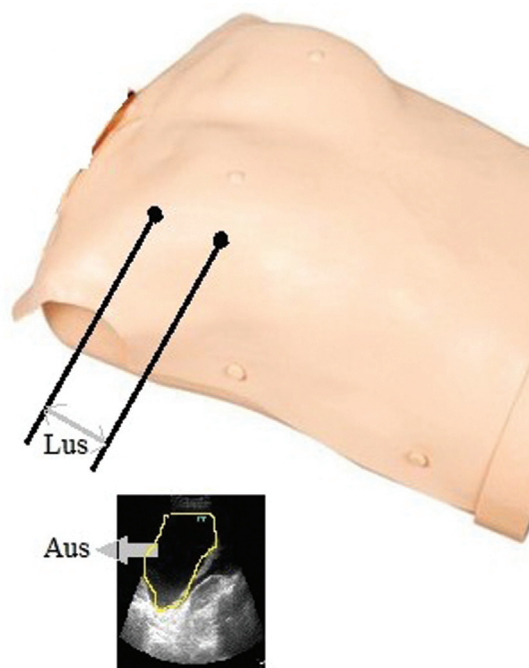


Fig. 2 Diagram showing PEV calculation.

was determined by measuring the distance between upper and lower paravertebral intercostal spaces where pleural effusion was noted. The frame where the pleural effusion was noted was frozen and the area of PE (A_{us}) was measured. The pleural effusion volume was calculated by multiplying L_{us} and A_{us} ⁸ (**Fig. 2** and **Table 1**).¹¹

Pleural Fluid-Thoracic Drainage

The patient's position during the entire procedure was up to the sonographer's choice but was generally supine to permit scanning of the lateral hemithorax. The possibility of thoracentesis was identified by a sonographic window where the fluid remained throughout the respiratory cycle. After identifying the suitable sonographic window, the angle of the sonoprobe was noticed, and the skin was marked where the needed depth of penetration was measured from the sonographic image. Under ultrasound guidance, site preparation, and thoracentesis were performed while maintaining the patient's position. During the process, the placement of needle was along a safe penetration axis according to the sonographic image.¹²

Diagnosis of Pleural Effusion

The initial step in diagnosing a pleural effusion is to identify whether it is a transudate or an exudate. When PE is an exudative effusion, additional diagnostic tests such as cytopathology, pleural biopsy, and sometimes thoracotomy can be performed to know a precise diagnosis and proper therapy for the pleural disease. On the other side, if the fluid is transudate, then therapeutic maneuvers performed for pleura are unnecessary and underlying diseases such as nephrosis, congestive heart failure, cirrhosis, or hypoproteinemia must be treated.¹³

Pleural effusion can be identified by chest radiography. Pleural effusion can cause mediastinal shift away from the diseased side seen on chest X-ray.¹⁴ Mediastinal shift can be upper or lower shift. Tracheal shift indicates upper mediastinal shift, whereas a shift in the heart position shows lower mediastinal shift. The trachea and heart shift to the opposite side in conditions such as tuberculous PE and effusion caused by other infective diseases. In case of malignant PE, the tracheal and heart are seen to be centrally or shifted to the same side as the fluid.¹⁵ In moderate pleural effusions, there might be silhouette loss between the heart borders and hemidiaphragms on chest X-ray.¹⁴ On the chest PA radiograph, the presence of pleural fluid around 200 mL is abnormal. On a lateral chest radiograph, only 50 mL of pleural fluid that leads to costophrenic angle blunting is visible.¹⁶ Lateral films can help distinguish between pleural thickening and free fluid because free fluid gravitates to the most dependent area of the chest wall.¹⁷

Ultrasound is more accurate in assessing pleural effusion volume and helps with thoracentesis than chest radiography.^{18,19} The pleural effusion was divided as echogenic or non-echogenic during the pre-procedure ultrasound. Echogenic pleural effusions were characterized as PE having

Table 1 Standardized grading method for pleural effusions¹¹

Grade	Illustration	Landmarks	Intercostal spaces
Grade 1: minimum	Limited to costophrenic sinus	Partially evident diaphragmatic dome	Limited to costophrenic sinus
Grade 2: small	Partially involved lower lung lobe	Completely evident diaphragmatic dome	Intercostal space 1
Grade 3: Small to medium	Partially collapsed lower lung lobe	Lower lung lobe partially atelectasis, pulmonary hilum not seen	Intercostal space 2–3
Grade 4: medium	Completely collapsed lower lung lobe	Lower lung lobe atelectasis, pulmonary hilum is seen	Intercostal space 3–4
Grade 5: large	Partially involved upper lung lobe	Lower lung lobe atelectasis, partially atelectasis of upper lung lobe	Intercostal space four and more
Grade 6: massive	Fully collapsed lung	Hilum is wholly seen, Whole lung atelectasis.	

debris (white specks) or echogenic cellular material within the effusion. Non-echogenic were characterized as those that had no echogenic material (echo-free, black).²⁰ Ultrasound-guided pleural aspiration should be performed if the effusion is modest or loculated as it provides a safe and accurate means of collecting fluid. Also, ultrasound allows better visualization of fibrous septations than CT scan,²¹ and an additional benefit of being portable allows bedside imaging.^{22,23}

A contrast-enhanced computed tomography (CECT) thorax scan must be performed before complete drainage of pleural effusion as it allows better visualization of pleural abnormalities.²⁴ CT scan has been found superior to chest radiography in the differentiation of pleural and parenchymal illness.²⁵

MRI has a limited role in diagnosing pleural disease because of poor spatial resolution and motion artifacts.^{26,27} MRI sequences used to image chest are T1-weighted and T2-weighted spin-echo, proton density, or short tau inversion recovery (STIR), and fast spin-echo with fat saturation.²⁸ T1-weighted images are helpful as they show a clear distinction between excess pleural fat and anomalies in the pleural space. T2-weighted images enhance the pleural fluid and provide good contrast between muscle and tumor.²⁸

Pleural Biopsy

Pleural biopsy is the most common method for obtaining diagnostic tissue^{29,30} that has been an accepted choice by patients and physicians due to its ease of use, particularly as an alternative to thoracoscopy in countries with limited healthcare resources.³¹ US-guided biopsy for thoracic lesions near the chest wall may be viable approach than CT-guided biopsy in terms of efficacy and safety.³²

Radiological Appearance

Benign Pleural Effusion

On chest X-ray, diffuse pleural thickening appears smooth and continuous pleural density that extends over at least 25%

of the chest wall. The costophrenic angle is usually blunted, and laterally there is a slight increase in the radiographic density seen on the chest X-ray.³³ The American Thoracic Society uses the presence of costophrenic angle blunting to differentiate it from widespread pleural plaque for diagnosis of the diffuse pleural thickness.³⁴

On ultrasound, most pleural collections are hypoechoic or anechoic collections demarcated by the lung echogenicity and visceral pleura. Pleural septate effusions are exudates,³⁵ whereas hypoechoic effusions can be exudates or transudates,^{35,36} and pleural thickening can be seen in the depths.³⁷

On CT scan, diffuse visceral pleural thickening is characterized as a continuous sheet of pleural thickening that is more than 8 cm long, 5 cm wide, and 3 mm thick that can occur in pleural plaques.³⁸ In contrast to pleural plaques, the diffuse pleural thickening borders are tapered.³⁹

Malignant Pleural Effusion

On chest X-ray, malignant pleural thickening typically appears irregular and nodular opacities can be seen in the lung perimeter. In 60% of cases, pleural effusions are seen as unilateral, and in 5% cases, bilateral pleural effusion.⁴⁰

On ultrasound, malignant solid pleural tumors appear as a homogenous well-delineated sheet-like lesion with breath > 1 cm in diameter.⁴¹ Pleural effusions with pleural nodularity and diaphragmatic thickness > 7 mm and parietal pleural thickness > 10 mm were found to have a high positive predictive value and specificity for underlying cancer in one of the studies.⁴²

On CT scan, parietal pleural thickening, mediastinal pleural thickening, nodular pleural thickening (>1 cm), and circumferential pleural thickening can be seen.⁴³

Conclusion

Pleural effusion can be diagnosed using imaging modalities such as chest radiograph, ultrasound, CT scan, and MRI. MRI

has a limited role in diagnosing pleural effusion because of poor spatial resolution and motion artifacts. Ultrasound is a feasible imaging modality for diagnosing pleural effusion because there is no radiation involved. Also, it is the safest modality for pleural fluid drainage and biopsy as it provides real-time imaging with better efficacy and more safety to patients.

Conflict of Interest

None declared.

References

- Kugasia IAR, Kumar A, Khatri A, Saeed F, Islam H, Epelbaum O. Primary effusion lymphoma of the pleural space: report of a rare complication of cardiac transplant with review of the literature. *Transpl Infect Dis* 2019;21(01):e13005
- Ali A, Ghuman FD, Hasan SM, Iqbal S, Ahsan, Adnan SM. Frequency of bacterial microorganisms in exudative pleural effusion. *J Liaquat Univ Med Heal Sci* 2021;20(02):148–152
- Lepus CM, Vivero M. Updates in effusion cytology. *Surg Pathol Clin* 2018;11(03):523–544
- Bedawi EO, Hassan M, Rahman NM. Recent developments in the management of pleural infection: a comprehensive review. *Clin Respir J* 2018;12(08):2309–2320
- Lee YCG, Fccp M, Fracp F. Pleural embryology and gross structure, circulation, lymphatics, and nerves. In: *Textbook of Pleural Diseases*. 2020:37–50
- Balik M, Plasil P, Waldauf P, et al. Ultrasound estimation of volume of pleural fluid in mechanically ventilated patients. *Intensive Care Med* 2006;32(02):318–321
- Usta E, Mustafa M, Ziemer G. Ultrasound estimation of volume of postoperative pleural effusion in cardiac surgery patients. *Interact Cardiovasc Thorac Surg* 2010;10(02):204–207
- Remérand F, Dellamonica J, Mao Z, et al. Multiplane ultrasound approach to quantify pleural effusion at the bedside. *Intensive Care Med* 2010;36(04):656–664
- Lichtenstein D, Hulot JS, Rabiller A, Tostivint I, Mezière G. Feasibility and safety of ultrasound-aided thoracentesis in mechanically ventilated patients. *Intensive Care Med* 1999;25(09):955–958
- Lomas DJ, Padley SG, Flower CDR. The sonographic appearances of pleural fluid. *Br J Radiol* 1993;66(787):619–624
- Smargiassi A, Inchingolo R, Zanforlin A, Valente S, Soldati G, Corbo GM. Description of free-flowing pleural effusions in medical reports after echographic assessment. *Respiration* 2013;85(05):439–441
- Mayo PH, Goltz HR, Tafreshi M, Doelken P. Safety of ultrasound-guided thoracentesis in patients receiving mechanical ventilation. *Chest* 2004;125(03):1059–1062
- Light RW, Macgregor MI, Luchsinger PC, Ball WC Jr. Pleural effusions: the diagnostic separation of transudates and exudates. *Ann Intern Med* 1972;77(04):507–513
- Bansal T, Beese R. Interpreting a chest X-ray. *Br J Hosp Med (Lond)* 2019;80(05):C75–C79
- Khajotia R. Respiratory clinics: mediastinal shift: a sign of significant clinical and radiological importance in diagnosis of malignant pleural effusion. *Malays Fam Physician* 2012;7(01):34–36
- Blackmore CC, Black WC, Dallas RV, Crow HC. Pleural fluid volume estimation: a chest radiograph prediction rule. *Acad Radiol* 1996;3(02):103–109
- O'Moore PV, Mueller PR, Simeone JF, et al. Sonographic guidance in diagnostic and therapeutic interventions in the pleural space. *Am J Roentgenol* 1987;149(01):1–5
- Eibenberger KL, Dock WI, Ammann ME, Dorffner R, Hörmann MF, Grabenwöger F. Quantification of pleural effusions: sonography versus radiography. *Radiology* 1994;191(03):681–684
- Grymiski J, Krakówka P, Lypacewicz G. The diagnosis of pleural effusion by ultrasonic and radiologic techniques. *Chest* 1976;70(01):33–37
- Asciak R, Hassan M, Mercer RM, et al. Prospective analysis of the predictive value of sonographic pleural fluid echogenicity for the diagnosis of exudative effusion. *Respiration* 2019;97(05):451–456
- Ohnishi H, Yokoyama A, Yasuhara Y, et al. Circulating KL-6 levels in patients with drug induced pneumonitis. *Thorax* 2003;58(10):872–875
- Lipscomb DJ, Flower CDR, Hadfield JW. Ultrasound of the pleura: an assessment of its clinical value. *Clin Radiol* 1981;32(03):289–290
- McLoud TCCT. CT and MR in pleural disease. *Clin Chest Med* 1998;19(02):261–276
- Traill ZC, Davies RJO, Gleeson FV. Thoracic computed tomography in patients with suspected malignant pleural effusions. *Clin Radiol* 2001;56(03):193–196
- Müller NL. Imaging of the pleura. *Radiology* 1993;186(02):297–309
- Helm EJ, Matin TN, Gleeson FV. Imaging of the pleura. *J Magn Reson Imaging* 2010;32(06):1275–1286
- White PM, Boyd J, Beattie TF, Hurst M, Hendry GM. Magnetic resonance imaging as the primary imaging modality in children presenting with acute non-traumatic hip pain. *Emerg Med J* 2001;18(01):25–29
- Hallifax RJ, Talwar A, Wrightson JM, Edey A, Gleeson FV. State-of-the-art: Radiological investigation of pleural disease. *Respir Med* 2017;124:88–99
- Abrams LD. A pleural-biopsy punch. *Lancet* 1958;1(7010):30–31
- Cope C. New pleural biopsy needle; preliminary study. *J Am Med Assoc* 1958;167(09):1107–1108
- Corcoran JP, Tazi-Mezalek R, Maldonado F, et al. State of the art thoracic ultrasound: intervention and therapeutics. *Thorax* 2017;72(09):840–849
- Yamamoto N, Watanabe T, Yamada K, et al. Efficacy and safety of ultrasound (US) guided percutaneous needle biopsy for peripheral lung or pleural lesion: comparison with computed tomography (CT) guided needle biopsy. *J Thorac Dis* 2019;11(03):936–943
- McLoud TC, Woods BO, Carrington CB, Epler GR, Gaensler EA. Diffuse pleural thickening in an asbestos-exposed population: prevalence and causes. *Am J Roentgenol* 1985;144(01):9–18
- Baumann MH, Strange C, Heffner JE, et al; AACP Pneumothorax Consensus Group. Management of spontaneous pneumothorax: an American College of Chest Physicians Delphi consensus statement. *Chest* 2001;119(02):590–602
- Yang PC, Luh KT, Chang DB, Wu HD, Yu CJ, Kuo SH. Value of sonography in determining the nature of pleural effusion: analysis of 320 cases. *Am J Roentgenol* 1992;159(01):29–33
- Hirsch JH, Rogers JV, Mack LA. Real-time sonography of pleural opacities. *AJR Am J Roentgenol* 1981;136(02):297–301
- Wernecke K. Sonographic features of pleural disease. *AJR Am J Roentgenol* 1997;168(04):1061–1066
- Lynch DA, Gamsu G, Aberle DR. Conventional and high resolution computed tomography in the diagnosis of asbestos-related diseases. *Radiographics* 1989;9(03):523–551
- Copley SJ, Wells AU, Rubens MB, et al. Functional consequences of pleural disease evaluated with chest radiography and CT. *Radiology* 2001;220(01):237–243

- 40 Karkhanis VS, Joshi JM. Pleural effusion: diagnosis, treatment, and management. *Open access emergency medicine: OAEM* 2012; 4:31
- 41 Görg C, Restrepo I, Schwerk WB. Sonography of malignant pleural effusion. *Eur Radiol* 1997;7(08):1195–1198
- 42 Qureshi NR, Rahman NM, Gleeson FV. Thoracic ultrasound in the diagnosis of malignant pleural effusion. *Thorax* 2009;64(02): 139–143
- 43 Leung AN, Müller NL, Miller RR. CT in differential diagnosis of diffuse pleural disease. *Am J Roentgenol* 1990;154(03):487–492