

Erratum: Arterial Thrombosis in Patients with Antiphospholipid Syndrome: A Review and Meta-Analysis

Jesus Aibar, MD, PhD^{1,2} Sam Schulman, MD, PhD^{2,3}

¹ Department of Internal Medicine, Hospital Clínic, IDIBAPS, University of Barcelona, Barcelona, Spain

² Department of Medicine, Thrombosis and Atherosclerosis Research Institute, McMaster University, Hamilton, Ontario, Canada

³ Department of Obstetrics and Gynecology, I.M. Sechenov First Moscow State Medical University, Moscow, Russia

Address for correspondence Sam Schulman, MD, PhD, Thrombosis Service, HHS-General Hospital, 237 Barton Street East, Hamilton ON, L8L 2 × 2, Canada (e-mail: schulms@mcmaster.ca).

Semin Thromb Hemost 2021;47:e1–e2.

ERRATUM

It has been brought to the publisher's attention that ▶**Fig. 4** published in the above article in *Seminars In Thrombosis And Hemostasis*, Volume 47, Number 6 (DOI: 10.1055/S-0041-1725057) is incorrect. The corrected figure appears as follows and is placed below.

Fig. 4 Forest plots of arterial thrombosis. Comparisons between single antiplatelet therapy (SAPT) versus vitamin K antagonist (VKA) (A), dual antiplatelet therapy (DAPT) versus SAPT (B), VKA plus SAPT versus SAPT (C), VKA plus SAPT versus VKA (D), VKA international normalized ratio (INR) 2–3 versus VKA INR 3–4 (E), DAPT versus VKA plus SAPT (F), VKA versus non-VKA oral anticoagulant (NOAC) (G).

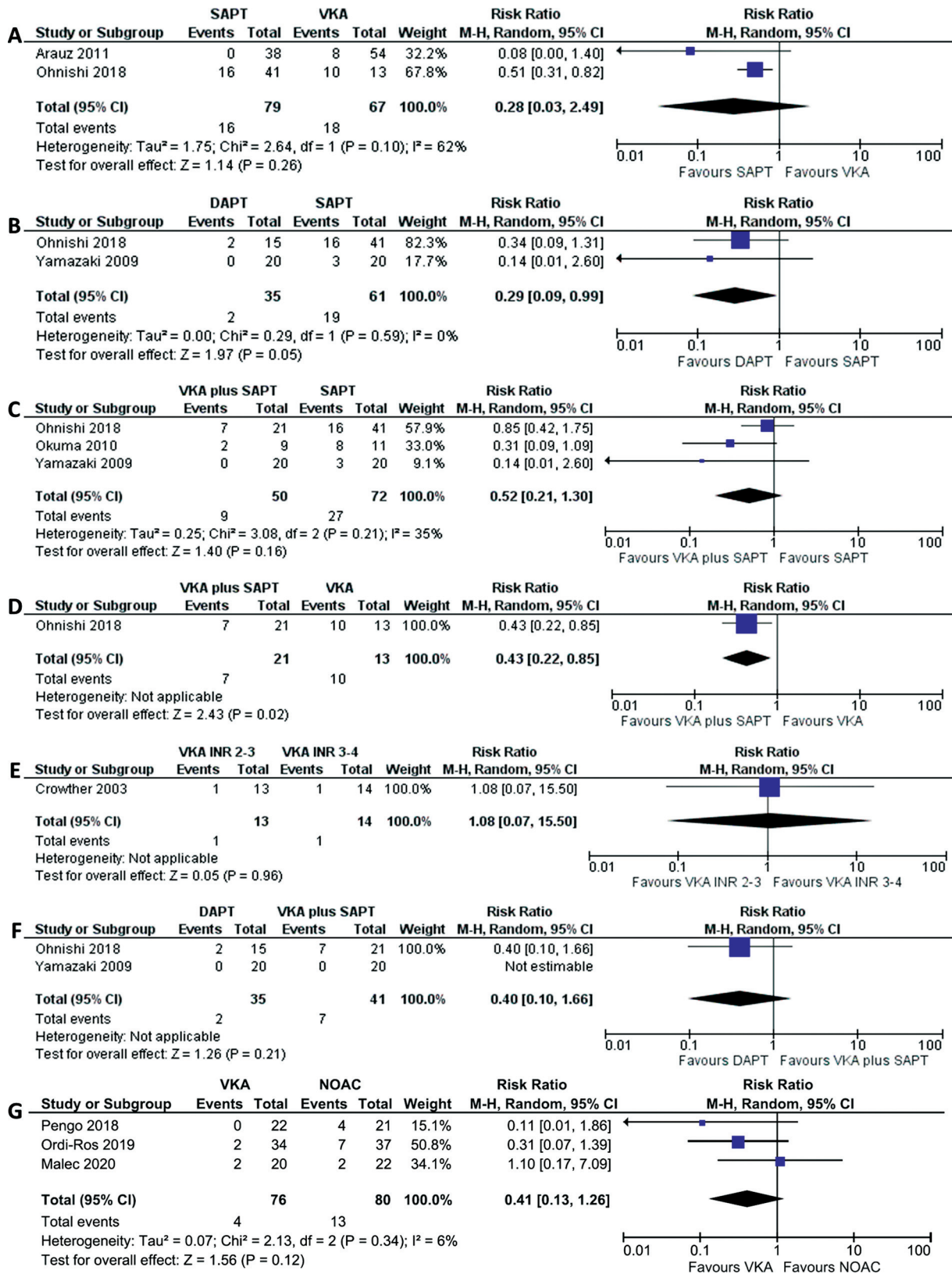


Fig. 4 Forest plots of arterial thrombosis. Comparisons between single antiplatelet therapy (SAPT) versus vitamin K antagonist (VKA) (A), dual antiplatelet therapy (DAPT) versus SAPT (B), VKA plus SAPT versus SAPT (C), VKA plus SAPT versus VKA (D), VKA international normalized ratio (INR) 2–3 versus VKA INR 3–4 (E), DAPT versus VKA plus SAPT (F), VKA versus non-VKA oral anticoagulant (NOAC) (G).