



# A Reliable Method for the Monitoring of Buried Free Flaps Using Near-Infrared Spectroscopy

Keith Sweitzer, MD<sup>1</sup> Katherine Carruthers, MD, MS<sup>2</sup> Pankaj Tiwari, MD<sup>3</sup> Ergun Kocak, MD, MS<sup>3</sup>

<sup>1</sup>Division of Plastic Surgery, Strong Memorial Hospital, University of Rochester, Rochester, New York

<sup>2</sup>Division of Plastic and Reconstructive Surgery, West Virginia University Health Sciences Center, Morgantown, West Virginia

<sup>3</sup>Midwest Breast & Aesthetic Surgery, Gahanna, Ohio

**Address for correspondence** Keith Sweitzer, MD, MS, Department of Plastic Surgery, University of Rochester, Strong Memorial Hospital, 601 Elmwood Ave, Rochester, NY 14642, Rochester, New York 14627-0001 (e-mail: keithsweitzer6@gmail.com).

J Reconstr Microsurg Open 2022;7:e44–e47.

## Abstract

**Background** In recent years, there has been a shift toward nipple-sparing mastectomy (NSM) techniques which often negates the need for reconstruction with exposed cutaneous donor flap tissues. Although techniques for the monitoring of buried flaps have been proposed, none have been able to provide the benefits that come with cutaneous monitoring via near-infrared spectroscopy (NIRS). Therefore, we herein propose a novel method for monitoring deepithelialized flap tissues deep to the mastectomy flaps using NIRS technology.

**Methods** An NSM with free flap reconstruction was performed. The flap was designed with a skin island for placement of a cutaneous NIRS probe. Next, a silicone NIRS probe was placed on a deepithelialized portion of the flap under the mastectomy flap. The readings from this tunneled device were then compared to the control measurements obtained from the cutaneous NIRS monitor. This procedure was performed on three consecutive patients. The changes in StO<sub>2</sub> recorded from both devices were compared using a paired, two-tailed Student's *t*-test.

**Results** During flap monitoring, there were no issues with probe dislodgement and signal quality averaged greater than 90. Furthermore, probe removal was easily accomplished at bedside. There was no harm to the mastectomy skin flaps by affixing the probe and the pocket which contained the probe quickly closed down after removal. Using the Student's *t*-test, a *p*-value of 0.995 was calculated indicating no statistically significant difference between the StO<sub>2</sub> readings from the cutaneous and the tunneled probes.

**Conclusion** By using this novel method, NIRS technology can reliably be applied to the monitoring of buried free flap tissues. The proposed technique could be applied to a variety of flaps beyond the realm of breast reconstruction and may prove to be particularly useful in the setting of head and neck reconstruction. The results of this study suggest that high quality postoperative flap monitoring is possible without compromising the aesthetic result.

## Keywords

- ▶ monitoring
- ▶ NIRS
- ▶ free flap

received  
March 31, 2022  
accepted  
May 29, 2022

DOI <https://doi.org/10.1055/s-0042-1757321>.  
ISSN 2377-0813.

© 2022. The Author(s).

This is an open access article published by Thieme under the terms of the Creative Commons Attribution-NonDerivative-NonCommercial-License, permitting copying and reproduction so long as the original work is given appropriate credit. Contents may not be used for commercial purposes, or adapted, remixed, transformed or built upon. (<https://creativecommons.org/licenses/by-nc-nd/4.0/>)

Thieme Medical Publishers, Inc., 333 Seventh Avenue, 18th Floor, New York, NY 10001, USA

The postoperative monitoring of microvascular free flaps has become the standard of care, with tissue oximetry (T.Ox) via near-infrared spectroscopy (NIRS) well accepted as an ideal monitoring system for cutaneous flaps.<sup>1-4</sup> NIRS probes provide continuous T.Ox measurements and allow for real-time quantitative assessment of tissue oxygenation and perfusion. The use of this system has consistently been shown to decrease the time it takes to recognize microvascular compromise and leads to improved flap salvage rates.<sup>1,5,6</sup> The traditional NIRS probe is designed for use on dry cutaneous surfaces and can be applied to flap tissues using either the provided adhesive pad or using a transparent adhesive dressing. Additionally, an alternative version of the NIRS probe has been developed for monitoring moist cutaneous surfaces, such as intraoral flaps. This second probe uses a similar core device but is surrounded in an impermeable silicone shell which may be sutured directly to the patient to allow for secure fixation. Either probe can then be connected to a monitor which allows for simultaneous bedside visualization of the tissue oxygenation and transmission of the saturation curve to a secure website for remote viewing.

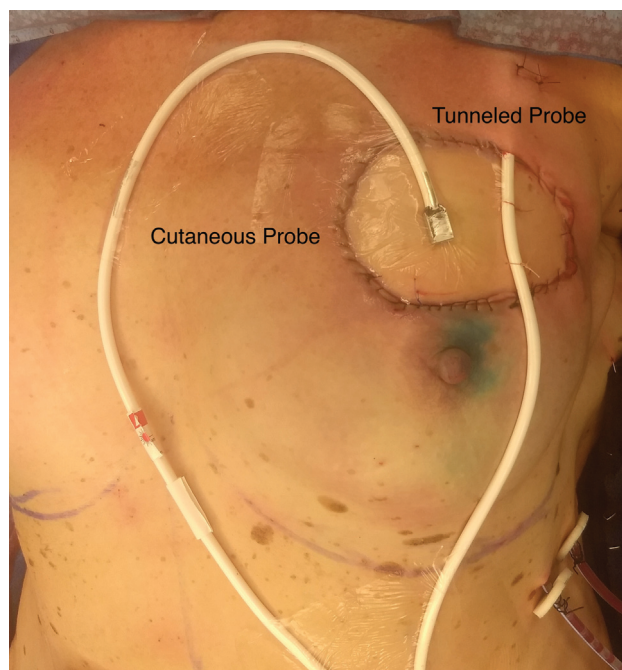
While cutaneous flap monitoring is well-established, in recent years there has been a shift toward buried free flap reconstructions, particularly in the setting of breast reconstruction following nipple-sparing mastectomy (NSM).<sup>7</sup> Although this may result in a more aesthetic reconstruction, it also eliminates exposed cutaneous flap tissues which were often used for postoperative flap monitoring.<sup>8</sup> Because of this, several techniques for the monitoring of buried flaps have been proposed. The most common choice is to externalize a cutaneous portion of the flap specifically for monitoring purposes; however, this strategy requires a second procedure at a later date to excise this excess tissue.<sup>9</sup> Alternatively, implantable Doppler probes can be employed for direct monitoring of vessel patency, but these devices have not been shown to provide the benefits that come with cutaneous monitoring.<sup>10</sup>

Therefore, we set out to determine if buried, de-epithelialized free flaps could be monitored via a novel application of the existing silicone NIRS probe, thus allowing for continuous NIRS monitoring without the need for externalized cutaneous tissues.

## Methods

### Probe Placement Technique

A standard NSM with subsequent deep inferior epigastric artery perforator (DIEP) flap reconstruction was performed. The flap was designed such that a small skin island was preserved for inset into the mastectomy skin flap defect. Although this skin island would normally be omitted for patients undergoing NSMs with buried flap reconstructions, it was maintained in this setting for use as a control for the tunneled monitoring device. As such, a typical cutaneous NIRS probe was placed on this skin island and affixed with a transparent adhesive dressing.



**Fig. 1** The silicone NIRS probe was placed on a de-epithelialized portion of the DIEP flap and affixed with two nonabsorbable sutures to the overlying mastectomy flap. The probe was in contact, face down, with the buried portion of the flap and secured in place using external sutures which could easily be removed when monitoring was no longer needed. For use as an internal control, a typical cutaneous NIRS probe was placed on the flap's skin island and affixed with a transparent adhesive dressing. DIEP, deep inferior epigastric artery perforator; NIRS, near-infrared spectroscopy.

Next, the silicone NIRS probe was placed on a de-epithelialized portion of the flap and affixed with two nonabsorbable sutures to the overlying mastectomy flap (→**Fig. 1**). By doing so, the probe was in contact, face down, with the buried portion of the flap and secured in place using external sutures which could easily be removed when monitoring was no longer needed. The readings from this device could then be compared to control measurements obtained from the standard cutaneous NIRS monitor. The flap was inset using layered closure, leaving a small area surrounding the cord of the tunneled probe open to allow for probe extraction at a later time.

### Postoperative Monitoring

Monitoring occurred on a standard surgical floor using the simultaneous dual NIRS probes. Both of the probes were connected to a single monitor to directly compare the StO<sub>2</sub> readings. The probe was left in place for continuous monitoring until the patient was discharged on postoperative day three.

### Probe Removal Technique

After a 72-hour period of flap monitoring, both NIRS probes were removed in preparation for patient discharge. In order to remove the tunneled probe, the two external sutures

securing the silicone probe to the mastectomy flap were cut. The probe was then gently pulled through the existing tunnel. The skin edges which were initially left open in order to accommodate the probe cord were then sutured closed under local anesthetic (→ **Supplementary Video 1**).

### Statistical Analysis

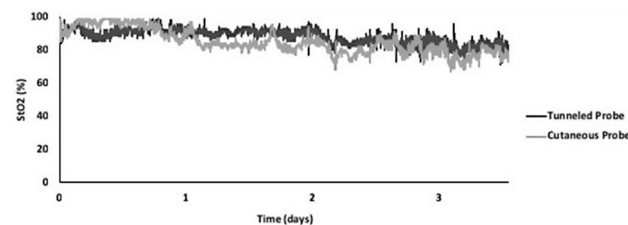
The graphed data from each of the two probes was converted into an individual StO<sub>2</sub> reading every 10 seconds for the 3-day duration of flap monitoring. Because StO<sub>2</sub> readings are variable across the surface of any flap, the changes in StO<sub>2</sub> which occurred at every 10 second interval were compared. The changes in StO<sub>2</sub> which were recorded for the tunneled probe were compared to the StO<sub>2</sub> values recorded for the cutaneous probe using a paired, two-tailed Student's *t*-test. A significant difference was defined as a *p*-value of 0.05 or lower.

### Results

The above stated protocol has been trialed on three consecutive cases. The placement of a tunneled NIRS probe added only negligible additional time to the overall duration of the procedure and the silicone probe was a comparable cost to the traditional cutaneous probe. During the 3-day monitoring period, there were no issues with probe dislodgement or poor contact with the flap, with signal quality consistently averaging greater than 90. Furthermore, probe removal was easily accomplished at bedside. There was no indication of harm to the mastectomy skin flaps by affixing the probe through this tissue and the pocket which contained the probe quickly closed down after the probe was removed, with no subsequent seroma formation. Using the Student's *t*-test as described above, a *p*-value of 0.995 was calculated indicating no statistically significant difference between the StO<sub>2</sub> readings from the cutaneous and the tunneled probes (→ **Fig. 2**).

### Discussion

The need for an accurate and reliable method for the continuous postoperative monitoring of buried free flap tissues has



**Fig. 2** StO<sub>2</sub> readings were recorded every ten seconds. Because StO<sub>2</sub> readings are variable across the surface of any flap, the changes in StO<sub>2</sub> which occurred at every ten second interval were compared for the tunneled probe and the cutaneous probe using a paired, two-tailed Student's *t*-test. A *p*-value of 0.995 was calculated indicating no statistically significant difference between the StO<sub>2</sub> readings from the cutaneous and the tunneled probes.

been growing in recent years, in parallel with the increased demand for nipple sparing mastectomies.<sup>11</sup> In an effort to combine the benefits of nipple sparing techniques with those of the NIRS monitoring system, many surgeons have adopted a two-staged flap inset strategy.<sup>9,12</sup> This protocol involves leaving a cutaneous portion of the flap intact and exposed from the mastectomy pocket so that a traditional NIRS probe can be applied and used for monitoring. Then, after postoperative monitoring is completed, a second procedure is needed to excise this remaining skin island and the newly deepithelialized flap tissues are completely buried under the mastectomy flaps. Although this technique is unquestionably successful, a more efficient, one-stage, procedure would certainly be preferred.

This issue first became apparent in the setting of head and neck reconstruction, where free tissue transfers are routinely placed in moist, poorly visualized recipient locations. While some physicians address this by opting for the two-staged procedure, as described above, others advocate for the use of implantable doppler probes in these cases.<sup>13</sup> However, a 2009 study by Keller indicated that NIRS monitoring technology could accurately predict flap complications before any changes were detectable on Doppler.<sup>14</sup> Since it is well accepted that the combination of early identification of flap compromise and prompt reoperation results in improved flap salvage rates, the use of implantable Dopplers may not be the best option.<sup>1,14</sup> As a result, the development of a silicone coated NIRS probe, which was designed to be used in moist settings, was a dramatic advancement for postoperative flap monitoring.

Although the silicone NIRS probe was primarily designed for intraoral use, the possibility of tunneling this probe under skin flaps for use on de-epithelialized flap tissues had not been formally tested. Furthermore, the application and removal of the probe posed a conceptual challenge, since a single-staged operation was the goal. Therefore, the technique described above represents a novel application for this device. While larger-scale clinical studies are still needed, our work strongly suggests that silicone coated NIRS probes can provide the same high quality flap monitoring as its cutaneous counterpart without the need for externalized skin islands.

### Conclusion

As microsurgical techniques continue to evolve, there will be a growing need for accurate and reliable postoperative monitoring of buried free flap tissues. Using novel techniques, NIRS technology can now successfully be applied in these cases without the need for additional surgical procedures. The proposed technique could be applied to a variety of flaps beyond the realm of breast reconstruction and may also prove to be particularly useful in the setting of head and neck reconstruction. The results of this study suggest that high quality postoperative flap monitoring is possible without compromising the aesthetic result.

### Conflict of Interest

None declared.

## References

- 1 Chen Y, Shen Z, Shao Z, Yu P, Wu J. Free flap monitoring using near-infrared spectroscopy: a systemic review. *Ann Plast Surg* 2016;76(05):590–597
- 2 Whitaker IS, Pratt GF, Rozen WM, et al. Near infrared spectroscopy for monitoring flap viability following breast reconstruction. *J Reconstr Microsurg* 2012;28(03):149–154
- 3 Keller A. Noninvasive tissue oximetry for flap monitoring: an initial study. *J Reconstr Microsurg* 2007;23(04):189–197
- 4 Steele MH. Three-year experience using near infrared spectroscopy tissue oximetry monitoring of free tissue transfers. *Ann Plast Surg* 2011;66(05):540–545
- 5 Lohman RF, Langevin CJ, Bozkurt M, Kundu N, Djohan R. A prospective analysis of free flap monitoring techniques: physical examination, external Doppler, implantable Doppler, and tissue oximetry. *J Reconstr Microsurg* 2013;29(01):51–56
- 6 Carruthers KH, Tiwari P, Yoshida S, Kocak E. Inpatient flap monitoring after deep inferior epigastric artery perforator flap breast reconstruction: how long is long enough? *J Reconstr Microsurg* 2019;35(09):682–687
- 7 Sisco M, Yao KA. Nipple-sparing mastectomy: a contemporary perspective. *J Surg Oncol* 2016;113(08):883–890
- 8 Levine SM, Snider C, Gerald G, et al. Buried flap reconstruction after nipple-sparing mastectomy: advancing toward single-stage breast reconstruction. *Plast Reconstr Surg* 2013;132(04):489e–497e
- 9 Frey JD, Stranix JT, Chiodo MV, et al. Evolution in monitoring of free flap autologous breast reconstruction after nipple-sparing mastectomy: is there a best way? *Plast Reconstr Surg* 2018;141(05):1086–1093
- 10 Chang EI, Ibrahim A, Zhang H, et al. Deciphering the sensitivity and specificity of the implantable doppler probe in free flap monitoring. *Plast Reconstr Surg* 2016;137(03):971–976
- 11 Orcutt ST, O'Donoghue C, Smith P, Laronga C. Expanding eligibility criteria for nipple-sparing mastectomy. *South Med J* 2017;110(10):654–659
- 12 Revenaugh PC, Waters HH, Scharpf J, Knott PD, Fritz MA. Suprastomal cutaneous monitoring paddle for free flap reconstruction of laryngopharyngectomy defects. *JAMA Facial Plast Surg* 2013;15(04):287–291
- 13 Poder TG, Fortier PH. Implantable Doppler in monitoring free flaps: a cost-effectiveness analysis based on a systematic review of the literature. *Eur Ann Otorhinolaryngol Head Neck Dis* 2013;130(02):79–85
- 14 Keller A. A new diagnostic algorithm for early prediction of vascular compromise in 208 microsurgical flaps using tissue oxygen saturation measurements. *Ann Plast Surg* 2009;62(05):538–543