




Partial Tracheal Defects Closure using Glutaraldehyde-Treated Autologous Pericardium

Shuhei Yoshida¹  Isao Matsumoto¹ Daisuke Saito¹ Yusuke Tanaka¹ Hirofumi Takemura² Akishi Oi³

¹Department of Thoracic Surgery, Kanazawa University, Kanazawa, Japan

²Department of Cardiovascular Surgery, Kanazawa University, Kanazawa, Japan

³Department of Molecular and Cellular Pathology, Kanazawa University, Kanazawa, Japan

Address for correspondence Isao Matsumoto, MD, PhD, Department of Thoracic Surgery, Kanazawa University, 13-1, Takaramachi, Kanazawa 920-8641, Japan (e-mail: isa-mat@med.kanazawa-u.ac.jp).

Thorac Cardiovasc Surg 2023;71:490–496.

Abstract

Background The usefulness of autologous pericardium treated with glutaraldehyde (GA) for tracheal defect closure is unknown. This study preliminarily evaluated whether a GA-treated autologous pericardial graft can effectively close tracheal defects in a beagle model.

Methods Defects of 10 mm × 10 mm were created on the trachea of 10 beagles and divided into a GA-treated group ($n = 5$), with tracheal reconstruction using GA-treated pericardium, and control group ($n = 5$), using fresh pericardium. Repair sites were evaluated through bronchoscopy and histology. Blood flows on graft were measured using laser Doppler technique on postoperative days (PODs) 0, 4, 7, 14, 28, and 56. Repair sites were histologically evaluated on POD 56. In addition, GA-treated pericardia of three other beagles were histologically evaluated 12 months postoperatively, for long-term follow-up.

Results All animals survived; none developed anastomotic insufficiency. The mean suturing time and frequency of additional suture were significantly shorter and lower in the GA-treated group than in the control group ($p = 0.002, 0.004$). All animals in the control group exhibited graft contraction, whereas the GA-treated group healed with most graft residual and reepithelialization in the bronchoscopic and histological findings ($p = 0.01, 0.004$). Further, all long-term GA-treated pericardia of three beagles were confirmed as residual grafts with reepithelialization, without contraction, at 12 months postoperatively. Blood flows on graft using laser Doppler technique in the GA-treated group were detected at POD 14 or thereafter.

Conclusion GA-treated pericardium was easier to handle and provided favorable scaffolding, without graft contraction, compared with the nontreated pericardium at short- and long-term follow-up.

Keywords

- ▶ trachea
- ▶ pericardium
- ▶ experimental

received
April 11, 2022
accepted after revision
August 25, 2022
article published online
October 10, 2022

DOI <https://doi.org/10.1055/s-0042-1757301>.
ISSN 0171-6425.

© 2022. The Author(s).

This is an open access article published by Thieme under the terms of the Creative Commons Attribution-NonDerivative-NonCommercial-License, permitting copying and reproduction so long as the original work is given appropriate credit. Contents may not be used for commercial purposes, or adapted, remixed, transformed or built upon. (<https://creativecommons.org/licenses/by-nc-nd/4.0/>)

Georg Thieme Verlag KG, Rüdigerstraße 14, 70469 Stuttgart, Germany

Introduction

Reconstruction of partial defects of the trachea can be closed by end-to-end anastomosis of both tracheal ends frequently. A previous study found that in adult cases, it was possible to resect approximately up to half of the trachea and perform initial anastomosis.¹ However, outcomes can be serious if anastomosis complications such as anastomotic dehiscence, bronchial stenosis, or mediastinitis develop. Therefore, the simpler and safer tracheal reconstruction may be preferable.

Previous studies have reported tracheal reconstruction methods using various types of autologous tissue, such as muscle tissue and pericardium.^{2,3} Such methods have been recognized as alternatives to tracheoplasty and bronchoplasty. Meanwhile, studies in the area of cardiovascular surgery have reported favorable outcomes in mitral valve repair, aortic valvuloplasty, and atrial septal defect closure, in which glutaraldehyde (GA)-treated autologous pericardia were used.⁴⁻⁶ An advantage of this method is that autologous graft tissue can be strengthened⁷ and handled easily⁶ while maintaining its biocompatibility.⁸

We hypothesized that it may be possible to use GA-treated autologous pericardium as a patch material for simple and effective closure of a defect in the intrathoracic trachea. Thus, we conducted a preliminary study project to evaluate the graft survival of GA-treated autologous pericardium in patch closure of partial tracheal defects compared with nontreated pericardium for larger defects in animal (dog) models.

Materials and Methods

Animals and Preparation for Operation

Three-month-old female beagle dogs (Kitayama Labes Co. Ltd., Nagano, Japan), with a mean weight of 12 kg, were used as animal models. Sedation was performed with ketamine

hydrochloride (10 mg/kg, Ketalar, Sankyo Co., Ltd., Tokyo, Japan), followed by endotracheal intubation through isoflurane inhalation. Surgery was performed under controlled respiration. Cefazolin sodium (1 g/body, Nichi-Iko Pharmaceutical Co., Ltd., Toyama, Japan) was intravenously administered immediately prior to making an incision and at the end of surgery. Dogs were sedated by inhalation of anesthetics and intermittent, intravenous administration of vecuronium (0.1 mg/kg; Fuji Pharma Co., Ltd., Tokyo, Japan). Anesthesia was maintained throughout the operation. This study was conducted in compliance with the ethics of animal research at Kanazawa University (approval ID: AP-163767, date of approval: April 21, 2017), as well as the 8th edition of the Guide for the Care and Use of Laboratory Animals.

Surgical Procedure

The intrathoracic tracheas of the animal models were exposed via right lateral thoracotomy while they were in a left lateral decubitus position. A 10 mm × 10 mm tracheal defect (approximately 1/3 circumference × 3 cartilaginous rings) was created in the right side of the tracheal cartilage using a sharp-pointed scalpel (►Fig. 1A). A 3 cm × 3 cm square pericardial piece was collected, which was fixed in 0.6% GA (Nacalai Tesque, Kyoto, Japan) solution for 10 minutes. It was rinsed twice with saline for 1 minute and used as a graft in the GA-treated group ($n = 5$). Pericardial pieces which were not fixed in GA solution were used in the control group ($n = 5$). Each tracheal defect was closed with a GA-treated or non-GA-treated pericardial graft through continuous suturing with 4-0 polydioxanone suture (Ethicon, Somerville, New Jersey, United States) (►Fig. 1B). A leak test was performed at a constant pressure of 20 cm H₂O. Additional suturing was performed using the horizontal mattress suture technique until air leakage was no longer visually observed. A drain was left indwelling, and the chest was closed. The

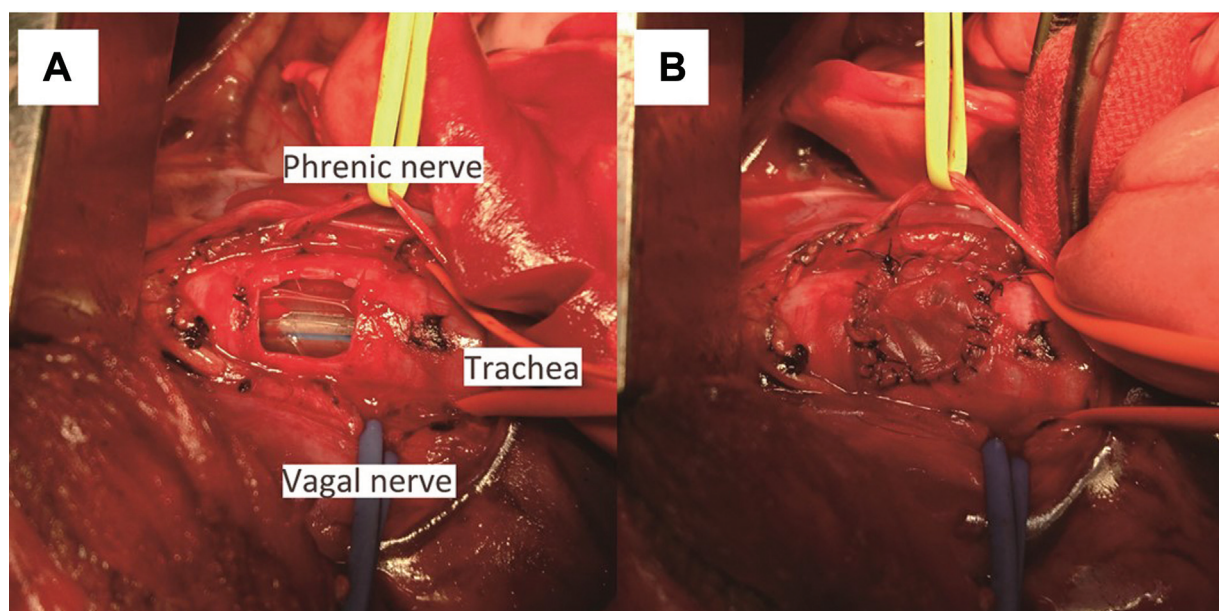


Fig. 1 Tracheal defect and pericardial patch closure. Pleural defects of 10 mm × 10 mm were created by sharp dissection (A). Pericardial patch covers the tracheal defect (B).

drain was removed prior to the removal of the tracheal tube, once it was confirmed that there was no leakage. In this study, the same surgeon performed all surgeries on all animals and alternated between the GA-treated group and the control group to avoid the technical bias.

Graft Change and Ease of Suturing after GA Treatment

The two intraoperative endpoints were established. The first was graft change (shrinkage with GA treatment and air leakage that required additional suturing). The second was ease of suturing after GA treatment, which included, the duration of suturing (time elapsed from the start of pericardial graft suturing to the completion of continuous suturing) and the number of additional sutures (the number of horizontal mattress sutures performed until leakage disappeared).

Bronchoscopic Findings and Measurement of Bronchial Mucosal Blood Flow at the Graft Site of the Trachea

To chronologically evaluate the healing process of the graft site, we set the following endpoints for bronchoscopic findings: changes in graft contraction (the area measurement of the defect covered with scar tissue expressed in four levels: I = 0–25%, II = 25–50%, III = 50–75%, IV = 75–100%), existence of regeneration of the endotracheal mucosa, and neovascularization of the graft. Areas of the defects were captured using bronchoscopic photography and measured using Photoshop (Adobe Systems Inc., San Jose, United States) software. In addition to bronchoscopic observation, bronchial mucosal blood flow (BMBF) was measured using the laser Doppler method as described below. Blood flow in the normal tracheal mucosa around the graft, and in the graft center, was measured using bronchoscopy (Olympus MAF Type GM; Olympus, Tokyo, Japan) on postoperative days (PODs) 0, 4, 7, 14, 28, and 56, under general anesthesia. BMBF was compared between the GA-treated group and the control group. Blood flow was measured while ventilation was stopped. The mean value of three measurements was adopted for each site. Changes in the blood flow in the graft were calculated relative to the blood flow in the normal trachea, as ratios (i.e., mean value in the graft site/mean value in the normal tracheal mucosa). A laser Doppler flowmeter (Omega Flow FLO-N1, Omegawave, Tokyo, Japan) was used to measure blood flow using methods previously described by Sundset et al.⁹

Histologic Findings

Animals in the GA-treated group and control group were sacrificed on POD 56. Thereafter, the trachea and its surrounding tissue, including the graft, were excised all together via median sternotomy and histologically evaluated.

The excised samples were fixed in 10% formalin and embedded in paraffin. The fixed tissue was sliced at a thickness of 5 μ m and stained with hematoxylin and eosin. Pathological images of the samples were evaluated with regard to the following aspects: amount of residual graft, regeneration of the mucosa on the graft, and neovasculari-

zation of the graft within one unit of the visual field ($\times 100$) in the regenerated submucosa. Neovascularization was defined using the following three levels: 1+, poor neovascularization (up to 10 new vessels); 2+, medium neovascularization (11–20 new vessels); and 3+, advanced neovascularization (21 or more new vessels). All histologic findings were evaluated by both the surgeon and pathologist.

Long-Term Follow-Up at 12 Months

Tracheal defect closure was performed separately in three beagle dogs using GA-treated pericardial grafts. The animals were sacrificed at month 12 for long-term histologic evaluation.

Statistical Analysis

The Mann–Whitney *U* test was performed as a distribution-free test for continuous values. In addition, Student's *t*-test was adopted for the analysis of normally distributed data and Fisher's exact test was adopted for the nonparametric analysis. The level of statistical significance was set at $p \leq 0.05$. Continuous values are presented as medians with interquartile ranges. Normally distributed data are presented as means \pm standard deviations. EZR (a modified version of R) was used in all statistical analyses.¹⁰

Results

Graft Change and Ease of Suturing after GA Treatment

No graft shrinkage associated with GA treatment was observed in the GA-treated group (**Fig. 2**). Surgical outcomes are summarized in **Table 1(A)**. In a postsuturing leak test, air leakage was observed in two of five tracheas in the GA-treated group and all five tracheas in the control group. All air leakages caused by cutting the grafts were repaired through additional sutures. Finally, all air leakages disappeared with additional sutures. The mean suturing time was significantly shorter in the GA-treated group, at 19.4 ± 3.5 minutes, than in the control group, at 29.2 ± 3.2 minutes ($p = 0.002$). The number of additional sutures was significantly fewer in the GA-treated group than in the control group ($p = 0.004$).

Bronchoscopic Findings and Measurement of BMBF at the Graft Site of the Trachea

No anastomotic failure was observed on bronchoscopy in all models, in both groups, throughout the observation period. All defects were closed, and graft respiratory fluctuation was not observed in any models. Representative bronchoscopic findings in both groups are presented in **Fig. 3** and summarized in **Table 1(B)**. Full-epithelized graft without shrinkage and tracheal stenosis were achieved in four of five tracheas in the GA-treated group, throughout the observation period. In one of five tracheas in the GA-treated group, about half of the graft area remained. Graft scar shrinkage and slight tracheal stenosis were observed in four of five tracheas in the control group during the observation period (**Fig. 3B**, PODs 28 and 56, $p = 0.01$, **Table 1(B)**). Additionally, findings that suggested mucosal regeneration on the graft were observed even in the control group at POD 14 or

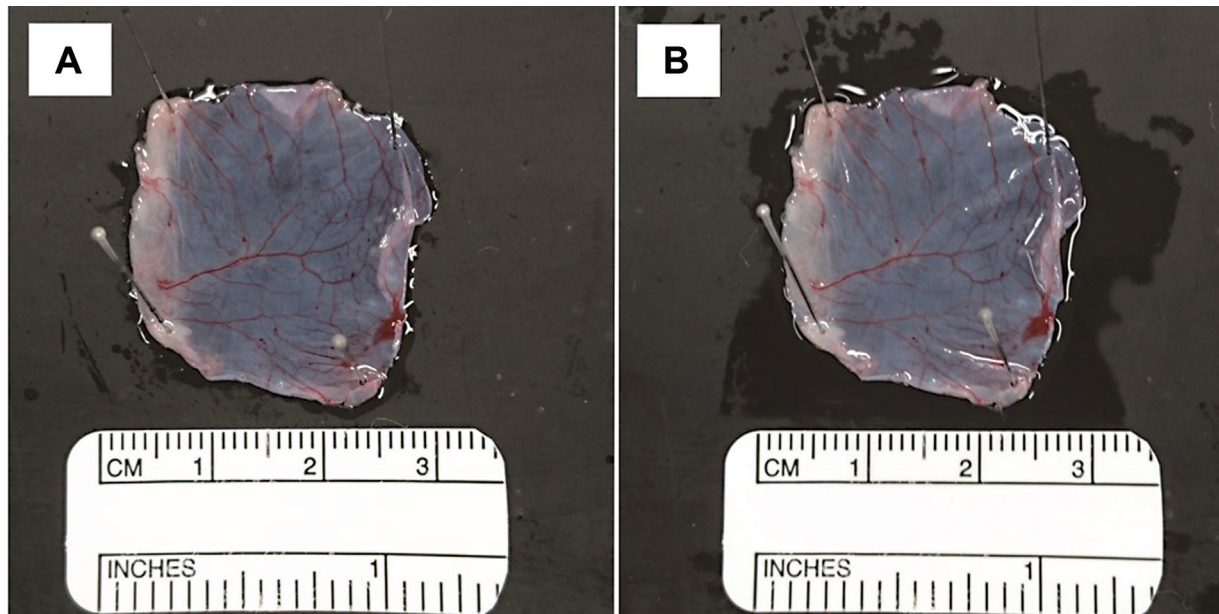


Fig. 2 No shrinkage was confirmed in pericardium treated with 0.6% glutaraldehyde for 10 minutes. Fresh pericardium before treatment (A). Pericardium treated with 0.6% glutaraldehyde for 10 minutes (B).

Table 1 Surgical outcomes, bronchoscopic and histologic findings

		(A) Surgical outcomes		(B) Bronchoscopic findings			(C) Histologic findings		
		Suturing time	Additional suture	Graft contraction	Regenerated mucosa	Neovascular vessels	Residual graft	Regenerated mucosa	Neovascular vessels
Animal no.		(min)	(no. of times)						
1 (GA-treated)		19.5	1	I	Full-epithelialized	+	Full	Full-epithelialized	2+
2 (GA-treated)		24.5	1	II	Full-epithelialized	-	~50%	Full-epithelialized	1+
3 (GA-treated)		20.0	0	I	Full-epithelialized	+	Full	Full-epithelialized	3+
4 (GA-treated)		18.0	0	I	Full-epithelialized	+	Full	Full-epithelialized	2+
5 (GA-treated)		15.0	0	I	Full-epithelialized	+	Full	Full-epithelialized	2+
	(mean ± SD)	19.4 ± 3.5	0.4 ± 0.55						
1 (Control)		29.0	2	II	Full-epithelialized	-	Undetectable	Full-epithelialized	3+
2 (Control)		33.5	3	III	Full-epithelialized	-	Undetectable	Full-epithelialized	3+
3 (Control)		31.0	2	IV	Full-epithelialized	-	Undetectable	Full-epithelialized	1+
4 (Control)		27.0	2	IV	Full-epithelialized	-	Undetectable	Full-epithelialized	2+
5 (Control)		25.5	1	III	Full-epithelialized	+	Undetectable	Full-epithelialized	2+
	(mean ± SD)	29.2 ± 3.2	2.0 ± 0.71						
p-Value		0.002 ^a	0.004 ^a	0.01 ^b		0.21 ^c	0.004 ^b		0.694 ^a

Abbreviations: GA, glutaraldehyde; SD, standard deviation.

Note: Graft contraction level: I = 0–25%, II = 25–50%, III = 50–75%, IV = 75–100%. Neovascular vessels level, 1+ : ~10, 2+ : 11~20, 3+ : 21~ (numbers of vessels within 1 unit of visual field [×100]).

^aStudent's *t*-test.

^bMann-Whitney *U* test.

^cFisher's exact test.

thereafter. Neovascularization was observed in four of five grafts in the GA-treated group and in one of five grafts in the control group at POD 28 or thereafter (►Fig. 3A, POD 28, ►Table 1(B)).

No measurement values for BMBF evaluation could be obtained at the graft site in both groups until POD 7. Blood flow was detected at POD 14 or thereafter (►Fig. 4). No significant difference in blood flow ratio at any measurement time point was observed between the two groups (►Fig. 4).

Histologic Findings

Representative histologic findings in both groups are presented in ►Fig. 5 (A, GA-treated group; B, control group). Residual grafts were observed in all models in the GA-treated group (►Fig. 5A-1, A-2), and a residual graft was observed in approximately 50% of the defect area in one model with scar shrinkage. Grafts were replaced with fibrous granulation tissue in all models in the control group; therefore, residual grafts could not be observed (►Fig. 5B-1, B-2, ►Table 1(C)),

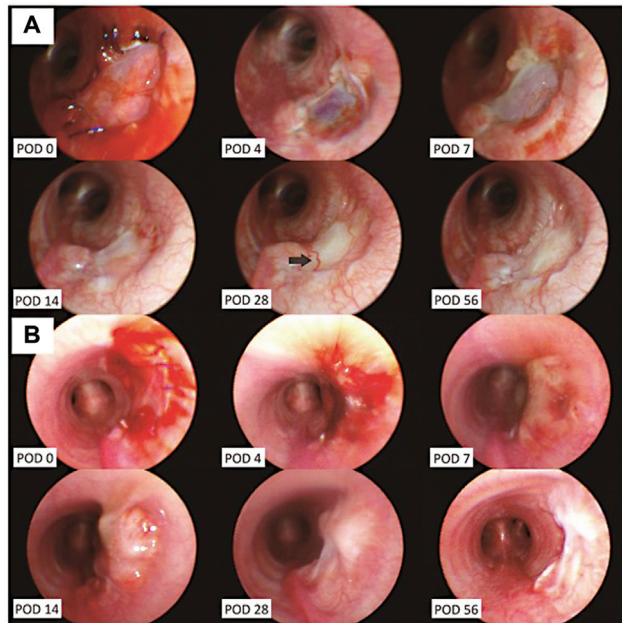


Fig. 3 Bronchoscopic findings. (A) Glutaraldehyde-treated pericardium. (B) Control. Bronchoscopic findings reveal that the grafts covered the regenerating mucosa at POD 14 in both groups. The repair site is well-healed with visible neovascular vessel in the GA-treated group compared with graft contraction at and after POD 14 in the control group. Arrow shows a visible neovascular vessel. GA, glutaraldehyde; POD, postoperative day.

$p = 0.004$). No difference in the degree of neovascularization in the regenerated submucosa, per enlarged visual field, was observed between the two groups at POD 56 (→Table 1(C)). Mucosal regeneration within the luminal surface of the graft, submucosal neovascularization, and formation of fibrous granulation tissue were observed in all tracheas in both groups. The regenerated mucosa on the graft presented as a monolayer, which differed from the stratified layer of the native tracheal mucosa.

Long-Term Follow-Up

No serious postoperative complications were observed in any of the three animals that underwent defect closure with

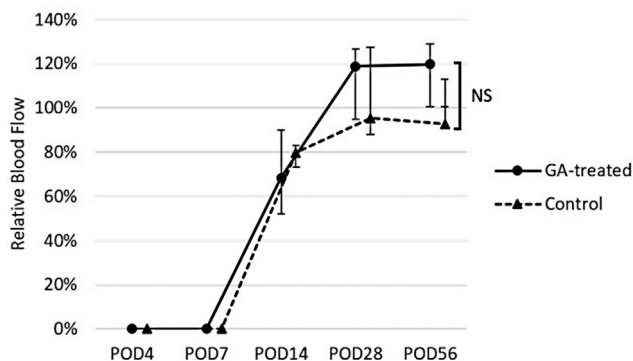


Fig. 4 Changes in relative blood flow in the graft site. Relative blood flow (graft site/normal bronchial mucosa): no significant differences were demonstrated at any time points between the arms. The flow in both arms was significantly higher at POD 14 than that at POD 7. GA, glutaraldehyde; POD, postoperative day.

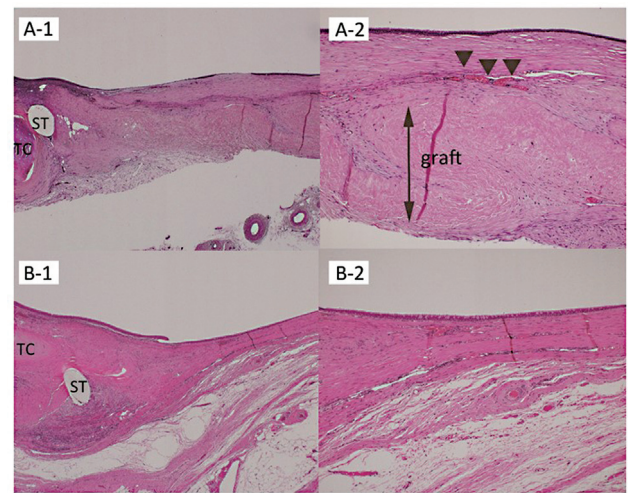


Fig. 5 Histologic findings. Postoperative hematoxylin–eosin staining visualized using a loupe (A: GA-treated pericardium; B: control). The suture site (A-1, B-1) with magnification at $\times 40$ and the graft site (A-2, B-2) with magnification at $\times 100$. GA-treated pericardial graft was detectable without contraction and resorption (double arrow). Arrows show submucosal neovascular vessels on the graft. GA, glutaraldehyde; POD, postoperative day; TC, tracheal cartilage; ST, suture thread (absorbable suture).

GA-treated pericardial tissue, throughout the long-term observation period. Moreover, tracheal stenosis was not observed on bronchoscopy in all three animals. Histologic findings indicated that the grafts were almost maintained, and the graft sites were covered with regenerated mucosa (→Fig. 6A and B). No calcification was observed in the graft sites.

Discussion

In this study, graft residual without shrinkage was observed in the GA-treated group, whereas graft shrinkage was observed in the non-GA-treated group during the healing period. Our results suggest that GA treatment prevented graft shrinkage. Fixing a graft with GA made suturing easier and shortened the suturing time as this avoids excessive elasticity and tendency to curl. Histological findings also indicated that grafts maintained the structure and that mucosal regeneration of the GA-treated grafts occurred in nearly all cases both for short and long periods. Although this is a preliminary study in relatively small tracheal defects, GA-treated pericardium can be useful for tracheal defect closure, because it is easy to handle and provides a mechanical scaffold for regenerated tissue without graft shrinkage compared with fresh pericardium. In addition, the presented method, in which autologous pericardial tissue is used, can also be implemented in emergency settings since tissue can be collected from the same surgical field.

Various studies have reported methods for reconstructing tracheal defects other than anastomotic reconstruction, such as using autologous tissue including cartilage, bone, pericardium, muscle, and fascia flaps.^{3,11}

In 1984, Idriss et al³ published the first study on tracheal reconstruction using pericardium. Fanous et al previously

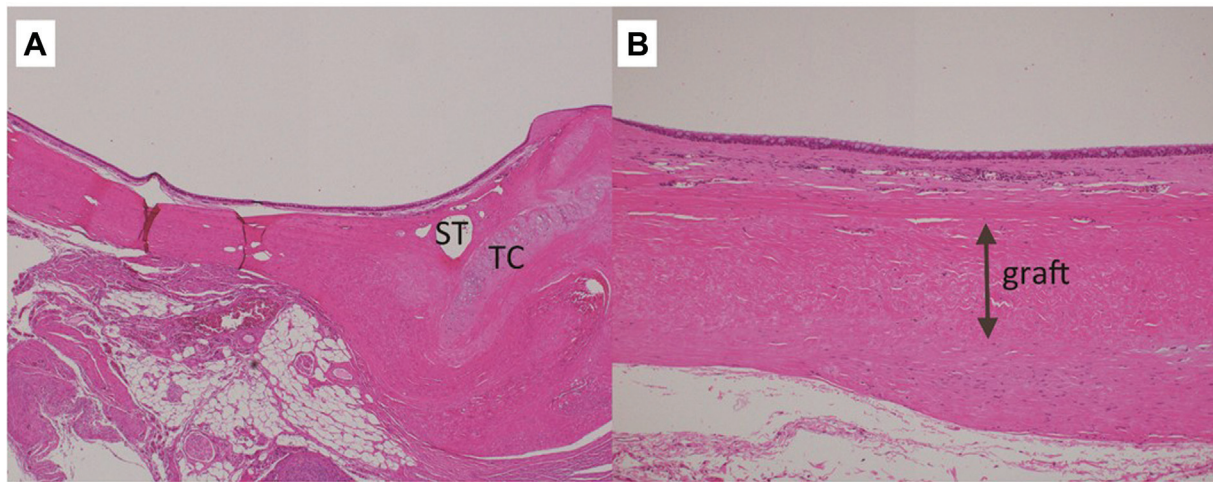


Fig. 6 Histologic findings. Postoperative hematoxylin–eosin staining visualized using a loupe (12 postoperative months). The suture site (A), magnified at $\times 40$. The graft site (B), magnified at $\times 100$. GA-treated pericardial graft was detectable without contraction and resorption in long-term follow-up (double arrow). GA, glutaraldehyde. TC, tracheal cartilage; ST, suture thread (absorbable suture).

reported favorable results in a long-term follow-up study on pericardial patch reconstruction of the trachea for short- and long-segment stenosis.¹² However, other studies have suggested that pericardial tissue may cause granuloma formation, which can cause graft shrinkage and tracheal stenosis even if favorable mucosal reformation is achieved on the patch.^{3,11} Although this study focused on the reconstruction of a slightly small defect area, compared with the control group, GA-treated grafts maintained the structure with little scar shrinkage, simply by performing a quick fixation process. Histological findings showed that scar shrinkage rarely occurred in the graft site when the graft was fixed with GA, which made a favorable scaffold for the regeneration of mucosal and submucosal tissue. By contrast, scar shrinkage occurred more frequently in the nontreated group because of graft absorption and disappearance and increased replacement with fibrous granulation tissue. Filová et al reported GA crosslinking protected the human pericardium which the scaffold is formed mainly from fibers of collagen types I and III efficiently against digestion with collagenase,¹³ the effect may reduce the absorption of the pericardial graft. Therefore, in our study, the GA-treated pericardium as the residual graft would be favorable scaffold on which vascularization and epithelial regeneration were confirmed. Moreover, sufficient, long-term graft maintenance was observed in the long-term follow-up observation. Thus, a GA-treated graft may contribute to reducing postoperative constriction.

On the other hand, due to the cytotoxicity of GA, it is possible that epithelial cell transgression and neovascularization on the GA-treated graft were scarce. In this study, the epithelial regeneration on the GA-treated graft might be achieved without graft shrinkage due to its biocompatibility as autologous graft even if without abundant submucosal regeneration and neovascularization. And systematic failure due to cytotoxicity of GA was not confirmed. Chang et al reported that compared with GA-fixed pericardium grafts, genipin-fixed grafts induce significantly weaker inflammatory reactions, and their tissue regeneration is far faster in

bovine acellular pericardium implanted subcutaneously in growing rats model.¹⁴ Crosslinking pericardium grafts with genipin therefore seems to be a promising alternative procedure to the crosslinking with GA, because it provides similarly high protection against degradation with collagenase, without cytotoxic effects.¹³

GA-treated pericardium has been occasionally used in the field of cardiovascular surgery as a material for atrial septal defect closure and aortic valvuloplasty.^{4–6} Xenopericardium, fresh pericardium, and GA-treated pericardium have been widely used in mitral valve repair. There are also reports where bovine pericardial patches were used for closure of tracheal defect.^{15,16} However, xenopericardium can cause infection and immunorejection. It can also cause graft failure due to conditions such as calcification over a long period.¹⁷ In addition, the use of xenopericardium is costly. Other studies have pointed out that issues with fresh pericardium include graft shrinkage and fibrous thickening.^{17,18} Meanwhile, Ozaki et al previously reported favorable results in a long-term follow-up study of 102 cases of aortic valve reconstruction with GA-treated autologous pericardium.⁵ And the advantage of the use of autologous patches is nearly cost free.

Various studies have reported findings related to the concentration of fixation solution and fixation time when using GA. A study found that concentration is particularly important for the purposes of strengthening tissue and preventing calcification over a long period.⁴ Sinha et al studied swine and bovine pericardium and found that concentration-dependent calcification can occur when the concentration of the fixation solution exceeds 0.6%.¹⁹ Liao et al found that excessive calcification could occur if the fixation time was 60 minutes or longer.²⁰ In this study, fixation was achieved using 0.6% GA for 10 minutes (Ozaki's procedure⁵). No clinical problem with GA treatment was observed in the follow-up duration, and no histological findings of calcification were observed either in the short term (56 days) or in the long term (12 months).

This preliminary study has some limitations. First, the tracheal defect sites were slightly small, at 10 mm × 10 mm, and limited to the right lateral wall of the intrathoracic tracheal cartilage. The study aimed to evaluate the graft survival of GA-treated autologous pericardium in tracheal reconstruction compared with nontreated pericardium. In clinical settings, the first choice for defects closure in the intrathoracic trachea may be not pericardium, but the muscular flap or pericardium reinforced with muscular flap. The use of pericardium on its own may be more appropriate for small defects when muscular flaps are not available for reasons such as reaching range and muscular damage due to trauma. Further research is required to confirm the effectiveness of the present method in the reconstruction of larger or circumferential defects. Second, GA fixation for the GA-treated group was performed for 10 minutes at a concentration of 0.6%. Further research is also required to deduce the optimal GA fixation time, optimal GA concentration level, and tissue toxicity.

In conclusion, our study demonstrated good short- and long-term healing when GA-treated autologous pericardium was used as a graft for closure of tracheal defects. GA-treated pericardium was easier to handle than nontreated pericardium and safely repaired tracheal defects. GA-treated grafts may provide favorable scaffolding, without graft contraction, compared with the nontreated pericardium. After thorough experimentation with larger defects in animal models, we will conduct to apply this method for human use.

Conflict of Interest

None declared.

References

- Grillo HC. The history of tracheal surgery. *Chest Surg Clin N Am* 2003;13(02):175–189
- Meyer AJ, Krueger T, Lepori D, et al. Closure of large intrathoracic airway defects using extrathoracic muscle flaps. *Ann Thorac Surg* 2004;77(02):397–404, discussion 405
- Idriss FS, DeLeon SY, Ilbawi MN, Gerson CR, Tucker GF, Holinger L. Tracheoplasty with pericardial patch for extensive tracheal stenosis in infants and children. *J Thorac Cardiovasc Surg* 1984;88(04):527–536
- Ng CK, Nesser J, Punzengruber C, et al. Valvuloplasty with glutaraldehyde-treated autologous pericardium in patients with complex mitral valve pathology. *Ann Thorac Surg* 2001;71(01):78–85
- Ozaki S, Kawase I, Yamashita H, et al. Reconstruction of bicuspid aortic valve with autologous pericardium—usefulness of tricuspidization. *Circ J* 2014;78(05):1144–1151
- Nishida H, Nakatsuka D, Kawano Y, Hiraiwa N, Takanashi S, Tabata M. Outcomes of totally endoscopic atrial septal defect closure using a glutaraldehyde-treated autologous pericardial patch. *Circ J* 2017;81(05):689–693
- van Noort R, Yates SP, Martin TR, Barker AT, Black MM. A study of the effects of glutaraldehyde and formaldehyde on the mechanical behaviour of bovine pericardium. *Biomaterials* 1982;3(01):21–26
- Chauvaud S, Jebara V, Chachques JC, et al. Valve extension with glutaraldehyde-preserved autologous pericardium. Results in mitral valve repair. *J Thorac Cardiovasc Surg* 1991;102(02):171–177, discussion 177–178
- Sundset A, Hansen G, Haanaes OC, Line PD, Kvernebo K. Human bronchial perfusion evaluated with endoscopic laser Doppler flowmetry. *Int J Microcirc Clin Exp* 1993;13(03):233–245
- Kanda Y. Investigation of the freely available easy-to-use software 'EZR' for medical statistics. *Bone Marrow Transplant* 2013;48(03):452–458
- deLorimier AA, Harrison MR, Hardy K, Howell LJ, Adzick NS. Tracheobronchial obstructions in infants and children. Experience with 45 cases. *Ann Surg* 1990;212(03):277–289
- Fanouf N, Husain SA, Ruzmetov M, Rodefeld MD, Turrentine MW, Brown JW. Anterior pericardial tracheoplasty for long-segment tracheal stenosis: long-term outcomes. *J Thorac Cardiovasc Surg* 2010;139(01):18–23, discussion 23–25
- Filová E, Staňková L, Eckhardt A, et al. Modification of human pericardium by chemical crosslinking. *Physiol Res* 2020;69(01):49–59
- Chang Y, Tsai CC, Liang HC, Sung HW. In vivo evaluation of cellular and acellular bovine pericardium fixed with a naturally occurring crosslinking agent (genipin). *Biomaterials* 2002;23(12):2447–2457
- Barbetakis N, Samanidis G, Paliouras D, Tsilikas C. Tracheal laceration following double-lumen intubation during Ivor Lewis esophagegastrectomy. *Interact Cardiovasc Thorac Surg* 2008;7(05):866–868
- Carter JJ, Evans D, Shah P, Ura M. Iatrogenic tracheal rupture: bovine pericardial patch repair without flap reinforcement. *Interact Cardiovasc Thorac Surg* 2012;14(04):502–503
- Shomura Y, Okada Y, Nasu M, et al. Late results of mitral valve repair with glutaraldehyde-treated autologous pericardium. *Ann Thorac Surg* 2013;95(06):2000–2005
- Hisatomi K, Isomura T, Hirano A, et al. Long-term follow-up results after reconstruction of the mitral valve by leaflet advancement. *Ann Thorac Surg* 1992;54(02):271–274, discussion 274–275
- Sinha P, Zurakowski D, Kumar TK, He D, Rossi C, Jonas RA. Effects of glutaraldehyde concentration, pretreatment time, and type of tissue (porcine versus bovine) on postimplantation calcification. *J Thorac Cardiovasc Surg* 2012;143(01):224–227
- Liao K, Frater RW, LaPietra A, Ciuffo G, Ilardi CF, Seifert E. Time-dependent effect of glutaraldehyde on the tendency to calcify of both autografts and xenografts. *Ann Thorac Surg* 1995;60(2, Suppl):S343–S347