



Positional Relationship between Two Microcatheters according to the Navigation Sequence within the Curved Vessel in Neuroendovascular Procedures

Tomotaka Ohshima¹ Megumi Koiwai² Naoki Matsuo² Shigeru Miyachi^{1,2}

¹Neuroendovascular Therapy Center, Aichi Medical University, Nagakute, Aichi, Japan

²Department of Neurosurgery, Aichi Medical University, Nagakute, Aichi, Japan

Address for correspondence Tomotaka Ohshima, MD, PhD, 1-1 Yazakokarimata, Nagakute, Aichi 480-1195, Japan (e-mail: tmtkoh@gmail.com).

Asian J Neurosurg 2024;19:349–353.

Abstract

Objective In neuroendovascular treatment, there are many opportunities to guide multiple catheters into the intracranial blood vessels. We report the relationship between two microcatheters according to the guiding order with experimental in vitro studies.

Materials and Methods We hypothesize that in a bent blood vessel such as a paraclinoid region of the internal carotid artery, the catheter that was first guided tended to pass through the inside, and the catheter that was guided later tended to pass through the outside. The in vitro verification was performed using a microcatheter and a balloon catheter in a silicone vascular aneurysmal model.

Results As a result, it was found that the two catheters were arranged according to our hypothesis. This finding was also observed during the actual operation of balloon-assisted coil embolization.

Conclusion The positional relationship between the two catheters according to the navigation order is very important, in particular during balloon-assisted coiling and stent-assisted coiling via a jailed microcatheter.

Keywords

- ▶ endovascular treatment
- ▶ intracranial aneurysms
- ▶ coil embolization
- ▶ microcatheter

Introduction

With the recent development of endovascular treatment technology and devices, there are more opportunities to treat intracranial aneurysms in previously challenging areas. Paraclinoid aneurysms are one of the anatomically difficult aneurysms for endovascular coil embolization. The para-

clinoid aneurysms are generally defined as aneurysms that arise from an ophthalmic segment of the internal carotid artery (ICA) between the roof of the cavernous sinus and the origin of the posterior communicating artery.¹ Due to the sharp curve from the carotid siphon and the large caliber of the ICA lumen, it is not always easy to maintain a stable microcatheter position while continuously delivering the

article published online
June 24, 2024

DOI <https://doi.org/10.1055/s-0042-1757216>.
ISSN 2248-9614.

© 2024. Asian Congress of Neurological Surgeons. All rights reserved.

This is an open access article published by Thieme under the terms of the Creative Commons Attribution-NonDerivative-NonCommercial-License, permitting copying and reproduction so long as the original work is given appropriate credit. Contents may not be used for commercial purposes, or adapted, remixed, transformed or built upon. (<https://creativecommons.org/licenses/by-nc-nd/4.0/>)

Thieme Medical and Scientific Publishers Pvt. Ltd., A-12, 2nd Floor, Sector 2, Noida-201301 UP, India

detachable coils into the aneurysm. Therefore, simple coiling of the paraclinoid aneurysm using only microcatheter shaping can result in incomplete packing or protrusion of the coils.²

Balloon- and stent-assisted coiling via a jailed microcatheter has been widely applied in paraclinoid aneurysms. Both assist techniques are required to navigate two catheters inside and beyond the aneurysm. We hypothesize that in a bent blood vessel, such as a paraclinoid ICA, the catheter that was first guided tended to pass through the inside, and the catheter that was guided later tended to pass through the outside. When the microcatheter for coil insertion is placed outside the balloon or stent, the tip of the microcatheter easily escapes from the aneurysmal dome to the ICA due to the balloon inflation or stent deployment. We describe the results of experimental verification and clinical experience regarding the order in which catheters are guided and the positional relationship of catheters in the curved vessel.

Materials and Methods

Our hypothesis is shown in ▶Fig. 1. When the balloon is first navigated around the aneurysmal neck and the microcatheter navigated next into the aneurysm, the microcatheter tends to place outside the balloon. Therefore, the tip of the microcatheter easily escapes from the aneurysmal dome to the parent artery due to balloon inflation. On the other hand, if the order of navigating the microcatheter and balloon is changed, the positional relationship tends to be reversed. Therefore, inflating the balloon stabilizes the tip of the microcatheter within the aneurysm.

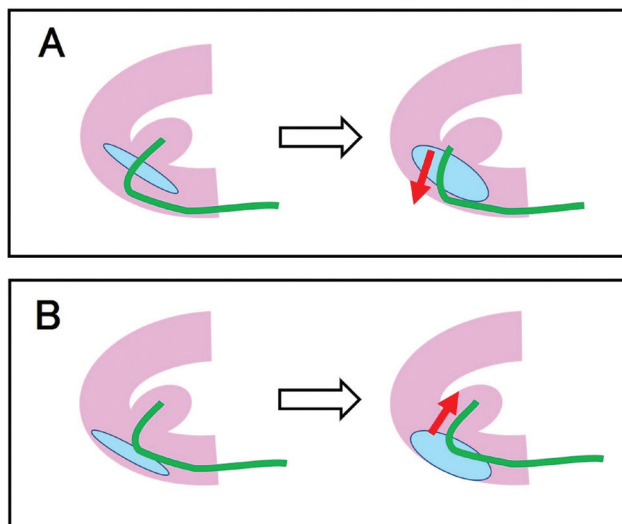


Fig. 1 Here are schematic illustrations of our hypothesis. The red arrows indicate the direction in which the catheter moves by balloon inflation. (A) When the balloon is first navigated around the aneurysmal neck and the microcatheter is next navigated into the aneurysm, the microcatheter tends to place outside the balloon. Therefore, the tip of the microcatheter easily escapes from the aneurysmal dome due to balloon inflation. (B) If the order of navigating the microcatheter and the balloon is changed, the positional relationship tends to be reversed. Hence, inflating the balloon stabilizes the tip of the microcatheter within the aneurysm.

A silicone vascular aneurysmal model (FAIN Biomedical, Okayama, Japan) was prepared (▶Fig. 2). The diameter of the parent artery was 4 mm, the aneurysm was 5 × 5 mm, and the neck size was 4 mm. The microcatheter was Phenom 17 preshaped 45 degrees (Medtronic, Irvine, California, United States), and the balloon catheter was Hyperform 4 × 7 mm (Medtronic). Colored water was used for balloon inflation to improve visibility. The positional relationship was observed five times by exchanging the guidance order of the microcatheter and the balloon catheter.

Results

When the balloon was guided ahead of the microcatheter, the microcatheter passed outside the balloon. After the inflation of the balloon, the tip of the microcatheter escaped from the aneurysm to the parent artery (▶Fig. 2A). On the other hand, when the microcatheter was guided before the balloon, the microcatheter passed inside the balloon. After the inflation of the balloon, the tip of the microcatheter was pushed up into the aneurysm and stabilized (▶Fig. 2B). Similar results were obtained in all five sessions.

Representative Case

A 64-year-old woman was referred to our hospital due to incidentally found a right ICA aneurysm. Cerebral angiography revealed an aneurysm (height 5.4 mm, length 4.1 mm, and width 4.0 mm) at the right ICA paraclinoid portion projected posteriorly from the inside of the curved ICA (▶Fig. 3). Under general anesthesia, a 6-F guiding catheter was advanced into the right ICA through the right common femoral artery. At first, a TransForm SC occlusion balloon catheter (Stryker Neurovascular, Kalamazoo, Michigan, United States) was navigated distally through the aneurysm, and then a Headway 17 microcatheter (Terumo, Tokyo, Japan), which was shaped with a hot air gun was navigated into the aneurysm. When the balloon was inflated during coil delivery into the aneurysm, the tip of the microcatheter was pushed out from the aneurysm by the balloon (▶Fig. 3A). The balloon was placed inside the parent artery rather than the microcatheter. Therefore, the balloon catheter and its inside guidewire were once withdrawn at the petrous portion of the ICA and navigated distally again. This time, the balloon was placed outside the parent artery rather than the microcatheter. When the balloon was inflated during coil delivery into the aneurysm, the tip of the microcatheter was pushed up into the aneurysm by the balloon (▶Fig. 3B). Complete obliteration of the aneurysm was achieved with four detachable coils.

Discussion

Balloon-assisted coil embolization has been used for aneurysms in various locations and has also been applied in paraclinoid aneurysms.³⁻⁵ Inflation of the balloon for the neck remodeling might have a mechanical conflict with the microcatheter in the aneurysm resulting in its displacement, especially in the tight curve of the paraclinoid ICA. When the balloon is placed between the aneurysmal neck and




Fig. 2 Here are some pictures of the experiment. The *black arrows* indicate the aneurysm. The *white arrowheads* indicate the tip of the balloon. The *white arrows* indicate the tip of the microcatheter. (A) The balloon first and then the microcatheter was guided. The microcatheter was kicked out by the inflated balloon. (B) The microcatheter first and then the balloon was guided. The microcatheter was pushed up into the aneurysm by the inflated balloon.

microcatheter, the balloon inflation may result in unexpected protrusion of the microcatheter and coils, thereby leading to incomplete or impossible coiling of the aneurysm. On the other hand, when the balloon is placed outside of the coil-delivering microcatheter, the balloon inflation may result in stabilization of the microcatheter for continuous coil insertion, thereby leading to complete coiling of the aneurysm. Needless to say, more than one loop of the coil has to be deployed into the aneurysm, before the balloon inflation to prevent unexpected aneurysmal injury by the microcatheter movement.

If the aneurysmal neck is very wide, a neck-bridging stent may eventually be required. The neck-bridging stent placement requires preceding microcatheter navigation to the distal artery beyond the aneurysmal neck. When the stent delivery catheter is placed between the aneurysmal neck and jailed coil inserting microcatheter, the stent deployment may result in an unexpected kick out of the microcatheter. Once the microcatheter in the aneurysmal dome is escaped to the parent artery, a subsequent trans-stent cell approach may often be difficult. Unlike balloon-assisted coiling, stent-assisted coiling has the disadvantage that it cannot be enforced repeatedly. On the other hand, when the stent delivery catheter is placed outside of the coil-delivering microcatheter, the stent deploy-

ment may result in stabilization of the microcatheter as well as the balloon-assisted coiling.

In this study, there are some limitations. First, the number of our experiments was quite small in the limited situation. The *in vitro* evaluation had been done only five times using the same model. Our clinical experience was confirmed in only four cases, including the presented representative cases. We had to evaluate in various *in vitro* circumstances and various patients. Shaping of the tip of the microguidewire and catheter may affect the course of tracing in curved vasculature. We believe that guiding the coil-delivering microcatheter into the aneurysm first and then the balloon catheter or stent delivery catheter distally involves the risk of aneurysmal rupture. Therefore, it is safe to guide the coil delivery microcatheter to the site beyond the aneurysm, and then guide the balloon or stent delivery catheter distally, and then pulls back the microcatheter to navigate into the aneurysm (►Fig. 4).

We found the positioning of microcatheters changes depending on the order in which the catheter is navigated to the curved vessel under both experimental and clinical situations. It was considered extremely important for safe and reliable coil embolization to realize the positional relationship of the catheters during the procedure.

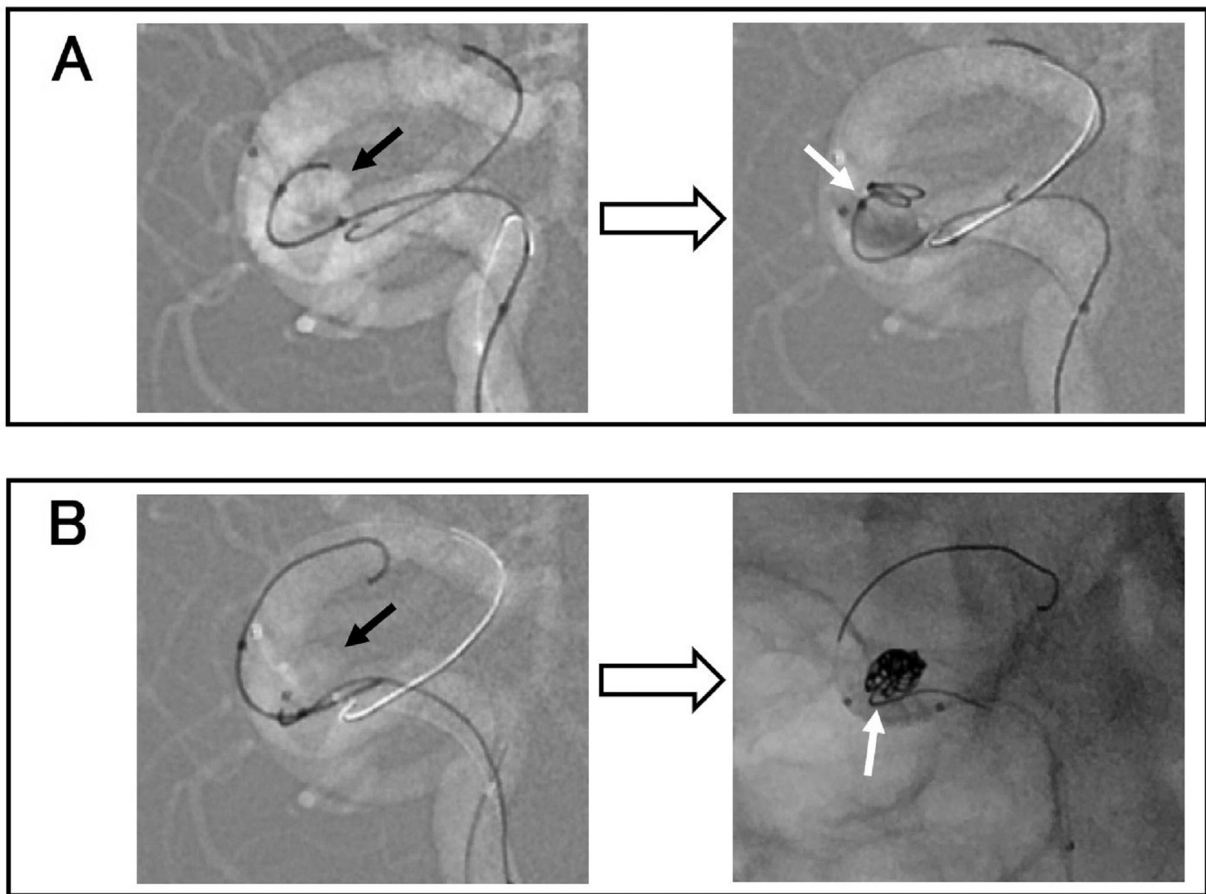


Fig. 3 Intraoperative images. The *black arrows* indicate the aneurysm. The *white arrows* indicate the tip of the microcatheter. (A) The balloon first and then the microcatheter was guided. The microcatheter was kicked out by the inflated balloon. (B) The microcatheter first and then the balloon was guided. The microcatheter was pushed up into the aneurysm by the inflated balloon.

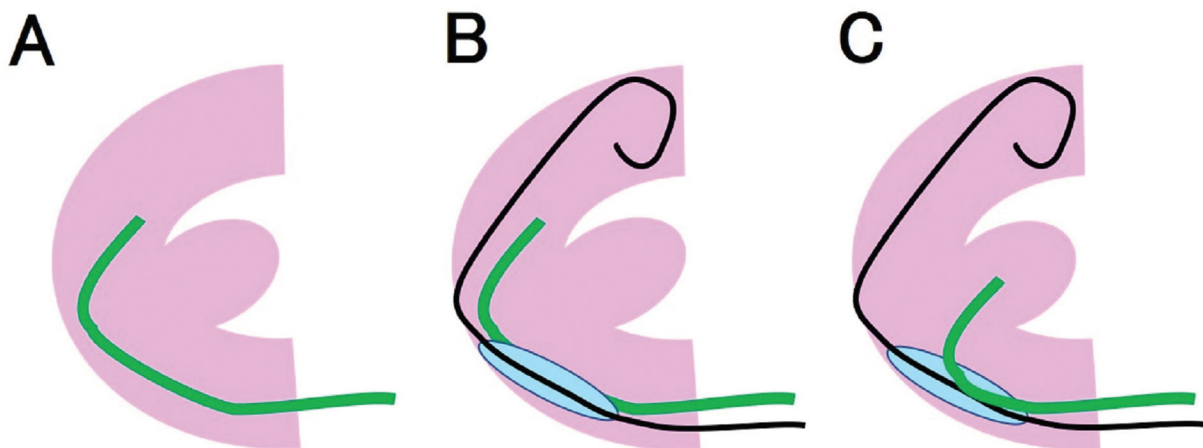


Fig. 4 Schematic drawings of our ideal procedure are showing. The coil delivery microcatheter to the site beyond the aneurysm (A), then guides the balloon catheter distally (B), and then pulls back the microcatheter to navigate into the aneurysm (C).

Authors' Contributions

Tomotaka Ohshima was involved in concepts, design, literature search, and manuscript preparation. Shigeru Miyachi edited and reviewed the manuscript. All the authors critically revised the article and provided final approval of the article.

Funding

None.

Conflict of Interest

Dr. Miyachi and Dr. Ohshima are reported speaker fees from Medtronic.

References

- 1 Bouthillier A, van Loveren HR, Keller JT. Segments of the internal carotid artery: a new classification. *Neurosurgery* 1996;38(03):425–432
- 2 Sheen JJ, Suh DC. Low-angled microcatheter approach for coil embolization of the anterior choroidal artery aneurysm. *Neuroradiology* 2017;59(10):1053–1056
- 3 Nelson PK, Levy DI. Balloon-assisted coil embolization of wide-necked aneurysms of the internal carotid artery: medium-term angiographic and clinical follow-up in 22 patients. *AJNR Am J Neuroradiol* 2001;22(01):19–26
- 4 Song Y, Kwon B, Al-Abdulwahhab AH, Kurniawan RG, Suh DC. Microcatheter stabilization technique using partially inflated balloon for coil embolization of paraclinoid aneurysms. *Neurointervention* 2021;16(02):132–140
- 5 Ohshima T, Kawaguchi R, Matsuo N, Miyachi S. Local balloon-assisted navigation of a microcatheter into an aneurysm during intracranial aneurysmal coiling: a dunk shot technique. *Asian J Neurosurg* 2021;16(02):384–386