




# A Rare Case of Transesophageal Echocardiography Probe-Induced Tongue Ulcer

Sanjay Surwade<sup>1</sup>  Ratan Chelani<sup>1</sup> Manju Butani<sup>1</sup>

<sup>1</sup>Department of Anesthesia, P. D. Hinduja National Hospital, Mumbai, Maharashtra, India

Address for correspondence Sanjay Surwade, MBBS, DA, DNB, 404/B, Rachna Apartment, Eksar Road, Borivali West, Mumbai 400091, Maharashtra, India (e-mail: sanjay.surwade17111983@gmail.com).

J Neuroanaesthesiol Crit Care 2023;10:54–55.

## Abstract

Transesophageal echocardiography (TEE) is a commonly used diagnostic and monitoring modality in anesthetic practice. It is used in neurosurgery for monitoring cardiac function and detecting venous air embolism. TEE is a semi-invasive procedure and is considered to be reasonably safe with a few complications. During neurosurgical cases, access to the head end is limited and TEE can cause injury due to prolonged contact. These injuries can be noticed only at the conclusion of the surgery. We report a rare case of tongue ulcer caused due to the use of TEE in a sitting neurosurgical procedure with a complete resolution.

## Keywords

- ▶ transesophageal echocardiography
- ▶ tongue ulcer
- ▶ neurosurgery

Transesophageal echocardiography (TEE) is a commonly used diagnostic and monitoring modality in anesthetic practice. It is used in neurosurgery<sup>1</sup> for monitoring cardiac function and detecting venous air embolism. TEE is a semi-invasive procedure and is considered to be reasonably safe with a few complications. We report a rare case of tongue ulcer caused due to the use of TEE in a sitting neurosurgical procedure with a complete resolution.

A 69-year-old, 74-kg male patient was diagnosed with a right acoustic schwannoma ( $4.6 \times 3.6 \times 4.1$  cm) at the cerebellopontine angle and was posted for excision under general anesthesia in a sitting position. The patient's physical status was ASA II due to hypertension and diabetes, which were controlled. In the operating room, general anesthesia with endotracheal intubation was done using titrated doses of propofol along with atracurium 0.5 mg/kg as a muscle relaxant. We used standard monitoring (electrocardiogram, pulse oximetry, capnography, noninvasive blood pressure, gas and inhalational agent analysis). In addition, invasive arterial blood pressure, central venous pressure, TEE, train of four, bispectral index (BIS) monitoring, and urine output were measured as per the institution's protocol. Anesthesia was maintained with a combination of propofol infusion and sevoflurane with a minimum alveolar concentration of 0.5. A

continuous infusion of atracurium was used that was titrated to maintain the train of four responses of two twitches. The hemodynamics were maintained using balanced salt solutions. The procedure was uneventful and was completed in 5 hours. During surgery, 800 mL of crystalloids were administered. The blood loss was about 300 mL and the urine output was 400 mL. Toward the end of the procedure, after the TEE probe was removed before extubation, we noticed a localized, large ( $5 \times 4$  cm), well-circumscribed, bluish black colored, superficial pressure ulcer over the left edge of the tongue (**Fig. 1**). The ulcer was located next to the endotracheal tube from where the TEE probe was put (highlighted with an arrow) and the shape of the ulcer was also reflective of TEE's shape and was going deeper along the path of TEE. There was no injury to the lips or surrounding structures.

The patient was carefully extubated using appropriate doses of neostigmine and glycopyrrolate, and then he was shifted to the intensive care unit (ICU) for postoperative monitoring for 2 days. The patient's relatives were informed about the incidence and adverse anesthesia event was reported as per the department policy.

In the ICU, the opinion of an otorhinolaryngologist was taken, who advised applying choline salicylate (9% w/v) gel

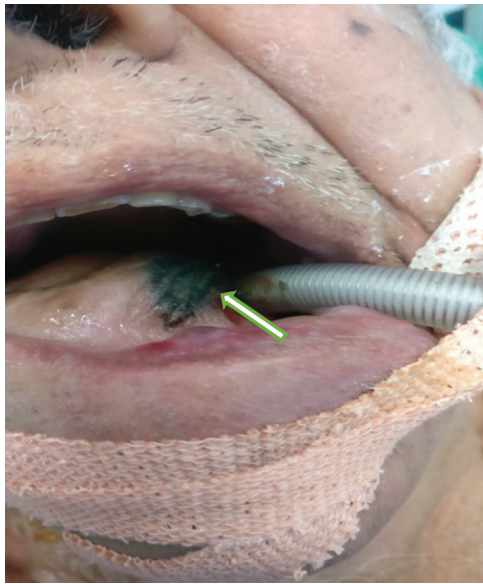article published online  
December 9, 2022

DOI <https://doi.org/10.1055/s-0042-1757169>.  
ISSN 2348-0548.

© 2022. The Author(s).

This is an open access article published by Thieme under the terms of the Creative Commons Attribution License, permitting unrestricted use, distribution, and reproduction so long as the original work is properly cited. (<https://creativecommons.org/licenses/by/4.0/>)

Thieme Medical and Scientific Publishers Pvt. Ltd., A-12, 2nd Floor, Sector 2, Noida-201301 UP, India



**Fig. 1** Tongue ulcer over the left edge of the tongue.

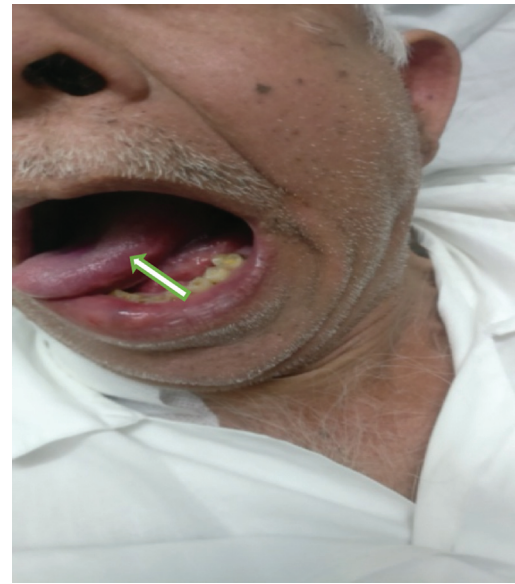three times a day. The patient was followed for 2 days, which revealed complete resolution of the tongue ulcer (► **Fig. 2**).

## Discussion

Pressure ulceration secondary to TEE probe placement is extremely rare and only a few cases have been reported. Kallmeyer et al<sup>2</sup> studied 7,200 cardiac surgery patients, with the use of intraoperative TEE, and reported a gastrointestinal (GI) complication rate of 0.2%, of which tongue ulcer cases were only four. Purza et al<sup>3</sup> did a retrospective analysis of 7,954 cases, and interestingly found a higher incidence of 1.4% GI adverse events.

The cause of the intraoral injuries is likely due to prolonged pressure and obliteration of lingual vein supplying the tongue, secondary to the intraoral devices such as an endotracheal tube or TEE probe leading to swelling and ulcerative lesion of the tongue.<sup>4</sup> Yamamoto et al<sup>5</sup> reported reversible edema of the tongue following the use of a TEE probe after 24 hours. Another rare case of tongue necrosis followed by healing and formation of the cleft was reported by Krishnan et al<sup>4</sup> during a prolonged cardiac surgery that lasted for 540 minutes.

In our case, the duration of TEE in place was 300 minutes, and due to neurosurgical draping, we had no access to observe the TEE probe until the end of the surgery, leading to prolonged contact time with the tongue. The direct weight of the probe for a longer time might also explain ulcer formation. The present injury would have been caused due to TEE only as it was noticed right after the removal of



**Fig. 2** Resolved ulcer after 2 days.

the probe, and the location was at the site of insertion and the endotracheal tube was away from the ulcer.

While using TEE, especially in cases where access to the airway is restricted, utmost care must be taken for proper positioning of the probe at the time of insertion. Whenever feasible, the probe position needs to be reconfirmed and documented. The earliest sign of upper airway injuries such as edema tongue or lips should necessitate corrective action by repositioning of TEE. Subsequent treatment should be sought for TEE-related injuries for a proper management plan, and follow-up is necessary to notice any functional or cosmetic damage to the patient.

## Conflict of Interest

None declared.

## References

- 1 Gregory WF, Elizabeth AM. A practical approach to transesophageal echocardiography: book review. *J Neurosurg Anesthesiol* 2009;3:269
- 2 Kallmeyer IJ, Collard CD, Fox JA, Body SC, Shernan SK. The safety of intraoperative transesophageal echocardiography: a case series of 7200 cardiac surgical patients. *Anesth Analg* 2001;92(05):1126–1130
- 3 Purza R, Ghosh S, Walker C, et al. Transesophageal echocardiography complications in adult cardiac surgery: a retrospective cohort study. *Ann Thorac Surg* 2017;103(03):795–802
- 4 Sriram K, Khorasani A, Mbekeani KE, Patel S. Tongue necrosis and cleft after prolonged transesophageal echocardiography probe placement. *Anesthesiology* 2006;105(03):635
- 5 Yamamoto H, Fujimura N, Namiki A. Swelling of the tongue after intraoperative monitoring by transesophageal echocardiography. *Masui* 2001;50(11):1250–1252