

# Does Lymphangiogenesis Occur through Incisional Scars?

Seungjun Lee<sup>1,\*</sup> Bakhtiyor Najmiddinov<sup>1,\*</sup> Chan Yeong Heo<sup>2</sup> Joseph Kyu-hyung Park, MD<sup>1</sup>   
Yujin Myung, MD, PhD<sup>1</sup>

<sup>1</sup> Department of Plastic and Reconstructive Surgery, Seoul National University Bundang Hospital, Seongnam-si, Republic of Korea

<sup>2</sup> Department of Plastic and Reconstructive Surgery, Seoul National University School of Medicine, Seoul, Republic of Korea

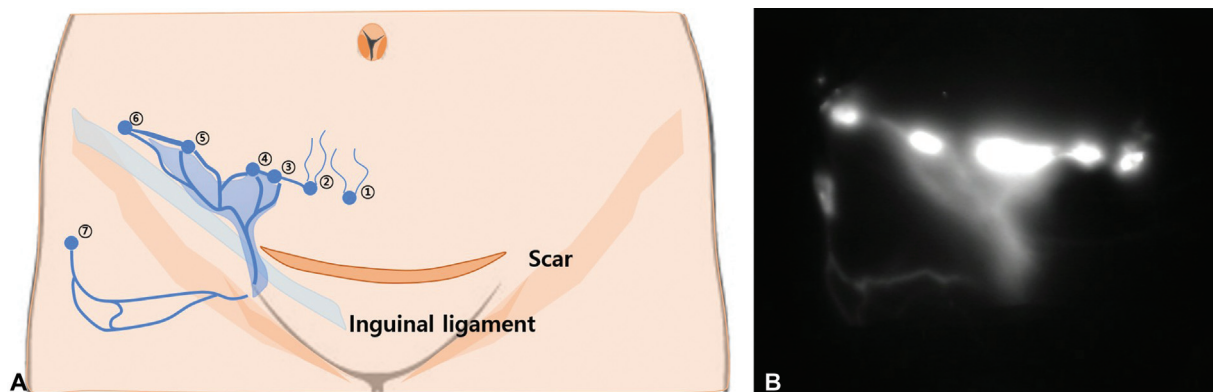
Arch Plast Surg 2022;49:701–702.

Address for correspondence Joseph Kyu-hyung Park, MD, Department of Plastic and Reconstructive Surgery, Seoul National University College of Medicine, Seoul National University Bundang Hospital, 82 Gumi-ro 173beon-gil, Bundang-gu, Seongnam-si 463-707, Republic of Korea (e-mail: josephpark85@gmail.com).

Yujin Myung, MD, PhD, Department of Plastic and Reconstructive Surgery, Seoul National University College of Medicine, Seoul National University Bundang Hospital, 82 Gumi-ro 173beon-gil, Bundang-gu, Seongnam-si 463-707, Republic of Korea (e-mail: surgene@snu.ac.kr).

Lymphangiogenesis is crucial in the homeostasis of interstitial fluids, immunity, and metabolism. Also, its importance in wound healing has been reported in animal models and clinical studies.<sup>1,2</sup> However, the current understanding of lymphangiogenesis through incisional scars is still limited. We present indocyanine green (ICG) lymphography images near a 16-year-old Pfannenstiel scar of a 43-year-old female patient. Informed consent was obtained from the patient for publication of this image report and accompanying images.

The patient underwent a total mastectomy and immediate breast reconstruction using a free transverse rectus abdominis myocutaneous flap. ICG was injected intradermally at seven points: three points superior to, three points superolateral to, and one below the inguinal ligament. Drainage of the ICG was captured using Fluobeam near-infrared fluorescence imaging camera (Fluoptics, Cambridge, MA). Lymphatic drainage from injection point 1 traveled in the cephalic direction, while injection points 2 and 3 (above



**Fig. 1** (A) A schematic illustration of the lymphatic drainage of the inguinal area: indocyanine green (ICG) was injected intradermally at 7 points (numbered). The blue line illustrates the drainage. (B) ICG lymphangiogram of the inguinal area during 10 minutes immediately after injection of the ICG.

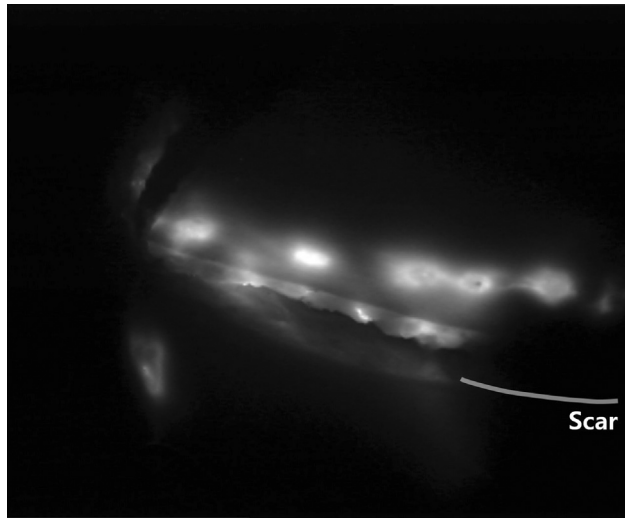
received  
January 12, 2022  
accepted after revision  
July 8, 2022

DOI <https://doi.org/10.1055/s-0042-1756504>.  
ISSN 2234-6163.

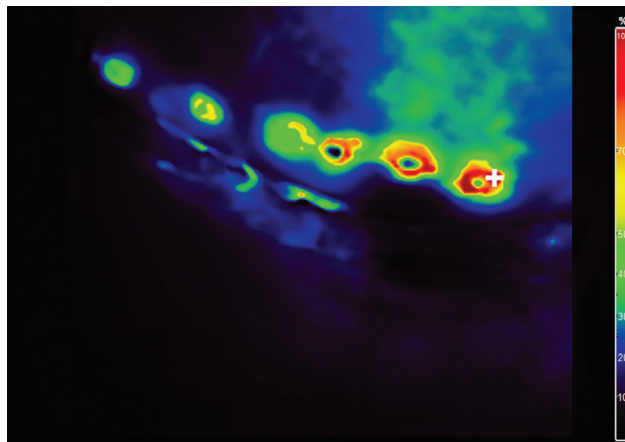
© 2022. The Korean Society of Plastic and Reconstructive Surgeons. All rights reserved.

This is an open access article published by Thieme under the terms of the Creative Commons Attribution-NonDerivative-NonCommercial-License, permitting copying and reproduction so long as the original work is given appropriate credit. Contents may not be used for commercial purposes, or adapted, remixed, transformed or built upon. (<https://creativecommons.org/licenses/by-nc-nd/4.0/>)

Thieme Medical Publishers, Inc., 333 Seventh Avenue, 18th Floor, New York, NY 10001, USA



**Fig. 2** Indocyanine green (ICG) lymphangiogram of the inguinal area 1 hour after injection. After flap elevation, multiple lymphatics were seen near the superficial fascia. However, no lymphatics were found near the Pfannenstiel scar.



**Fig. 3** Indocyanine green (ICG) quantification: Pooling of the ICG was observed in the first and second injection points. Also, only cephalic (but no caudal) collateral drainages were observed.

the scar) formed collaterals with injection point 3 (which is not above the scar). Other injection points showed the inguinal area's previously known lymphatic drainage (► Fig. 1).

One hour delayed ICG lymphography after flap elevation showed multiple lymphatic vessels near the superficial fascia. Interestingly, no lymphatic vessel was visible near the Pfannenstiel scar (► Fig. 2, above the line). ICG quantification showed pooling of the ICG in points 1 and 2, as well as collateral drainage in the cephalic direction (► Fig. 3).

In animal models, lymphangiogenesis has been evident near the wound edge 3 to 5 days after incision<sup>3</sup> with a temporary increase of new sprouts from existing lymphatic vessels.<sup>2</sup> On the contrary, our images show that human lymphangiogenesis does not occur through incisional scars. Further animal and clinical studies on lymphangiogenesis near incisional scars are needed.

#### Authors' Contributions

S.L. contributed with data curation and writing the original draft. B.N. took part in writing the original draft. C.Y.H. was involved in conceptualization and reviewing and editing the manuscript. J.K.-h.P. took part in conceptualization, data curation, and reviewing and editing the manuscript. Y.M. was involved in conceptualization, and reviewing and editing the manuscript.

#### Ethical Approval

This study was approved by the Institutional Review Board of Seoul National University Bundang Hospital (IRB# B2202-739-701). Written informed consent was obtained for this article.

#### Conflict of Interest

None declared.

#### References

- 1 Asahara T, Masuda H, Takahashi T, et al. Bone marrow origin of endothelial progenitor cells responsible for postnatal vasculogenesis in physiological and pathological neovascularization. *Circ Res* 1999;85(03):221-228
- 2 Paavonen K, Puolakkainen P, Jussila L, Jahkola T, Alitalo K. Vascular endothelial growth factor receptor-3 in lymphangiogenesis in wound healing. *Am J Pathol* 2000;156(05):1499-1504
- 3 Ji RC, Miura M, Qu P, Kato S. Expression of VEGFR-3 and 5'-nase in regenerating lymphatic vessels of the cutaneous wound healing. *Microsc Res Tech* 2004;64(03):279-286