



The Great Saphenous Vein—An Underrated Recipient Vein in Free Flap Plasty for Lower Extremity Reconstruction: A Retrospective Monocenter Study

Abdulwares Meiwandi, MD¹ Lars Kamper, PhD, MD² Lara Küenzlen, MD³
Ulrich M. Rieger, PhD, MD³ Ahmet Bozkurt, PhD, MD¹

¹ Department of Plastic, Reconstructive, Aesthetic and Hand Surgery, Helios University Hospital Wuppertal, Witten-Herdecke University, Wuppertal, Germany

² Department of Radiology, Radiology, Helios University Hospital Wuppertal, University Witten/Herdecke, Wuppertal, Germany

³ Department of Plastic and Aesthetic, Reconstructive & Hand Surgery, AGAPLESION Markus Hospital Frankfurt, Frankfurt/Main, Germany

Address for correspondence Abdulwares Meiwandi, MD, Department of Plastic, Reconstructive, Aesthetic and Hand Surgery, Helios University Hospital Wuppertal, Witten-Herdecke University, Heusnerstraße 40, 42283 Wuppertal, Germany (e-mail: a.meiwandi@icloud.com).

Arch Plast Surg 2022;49:683–688.

Abstract

Background Reconstruction of large soft tissue defects of the lower extremity often requires the use of free flaps. The main limiting factor and potential for complications lie in the selection of proper donor and recipient vessels for microvascular anastomosis. While the superficial veins of the lower leg are easier to dissect, they are thought to be more vulnerable to trauma and lead to a higher complication rate when using them instead of the deep accompanying veins as recipient vessels. No clear evidence exists that proves this concept.

Methods We retrospectively studied the outcomes of 97 patients who underwent free flap plasty to reconstruct predominantly traumatic defects of the lower extremity at our institute. The most used flap was the gracilis muscle flap. We divided the population into three groups based on the recipient veins that were used for microvascular anastomosis and compared their outcomes. The primary outcome was the major complication rate.

Results Overall flap survivability was 93.81%. The complication rates were not higher when using the great saphenous vein as a recipient vessel when comparing to utilizing the deep concomitant veins alone or the great saphenous vein in combination to the concomitant veins.

Conclusions In free flap surgery of the lower extremity, the selection of the recipient veins should not be restricted to the deep accompanying veins of the main vessels. The superficial veins, especially the great saphenous vein, offer an underrated option when performing free flap reconstruction.

Keywords

- ▶ microsurgery
- ▶ free tissue flaps
- ▶ reconstructive surgical procedures
- ▶ lower extremity

received
May 31, 2021
accepted after revision
July 16, 2022

DOI <https://doi.org/10.1055/s-0042-1756346>.
ISSN 2234-6163.

© 2022. The Korean Society of Plastic and Reconstructive Surgeons. All rights reserved.

This is an open access article published by Thieme under the terms of the Creative Commons Attribution-NonDerivative-NonCommercial-License, permitting copying and reproduction so long as the original work is given appropriate credit. Contents may not be used for commercial purposes, or adapted, remixed, transformed or built upon. (<https://creativecommons.org/licenses/by-nc-nd/4.0/>)

Thieme Medical Publishers, Inc., 333 Seventh Avenue, 18th Floor, New York, NY 10001, USA

Introduction

The possibilities for reconstruction of large-area tissue defects of the lower extremity have improved significantly in recent decades as a result of the development of reconstructive microsurgical techniques.^{1,2} Whereas historically amputation of limbs was the only option for severe trauma or infections, the focus has now shifted to limb salvation following a protocol of extensive debridement and soft tissue cover with free flap procedures.³ Nowadays, flap failure rates generally lie in the single-digit percentage due to refined microsurgical training and establishment of microsurgical centers in the recent past.^{2,4} However, the success rate is lowest in areas below the knee compared with the other anatomic regions even in the hands of most skilled surgeons. This fact is mainly owed to higher amounts of vascular complications regarding the donor and, especially, recipient vessels.⁵⁻⁷ Since the donor vessels cannot be altered easily, big emphasis should be placed on the selection and preparation of the recipient vessels.⁸⁻¹⁰ Preoperative angiography can help the surgeon identifying suitable vessels. Janhofer et al describe an additional venous duplex assessment to find any venous pathologies since venous thrombosis is considered to be a frequent source of flap failure.^{11,12} It is believed that, especially, the superficial venous system suffers from “posttraumatic vessel disease” because they are more exposed and should therefore not be primarily used.¹³ This condition has been first mentioned by Acland which describes the usual injured and fibrotic state of the vessels in the trauma zone.¹³ For that reason, location of the anastomosis is believed to be most optimal when it is placed outside the harmed field.¹⁴ Ambiguity also exists as to whether more than one vein should be anastomosed and whether the superficial system should be routinely used or should only be considered as a last resort option.^{10,15}

In this retrospective study, we want to assess the outcomes of patients who underwent free flap reconstruction in the lower extremity at our institute and examine the influence of the routine utilization of the saphenous vein as a recipient vessel. To the best of our knowledge, there exists no published study that explored this specific question when using free muscle flaps.

Methods

Study Design

We retrospectively studied the demographics and outcomes of 97 patients who underwent free flap procedures at the lower extremity of mostly posttraumatic defects at our institute in the last 3.5 years. Patients who were younger than 16 years or died within 30 days after operation were excluded from this study. We obtained the approval of the responsible ethics committee and institutional board before data acquisition and performed the study in accordance to the Declaration of Helsinki in its current version and followed the STROBE guidelines.^{16,17} The study is approved by the institutional review board (IRB; registration number: HCRI ID 2020-0135). We extracted the relevant variables from the digital patient files

and entered them into a pseudonymized database separated from the decryption key. Maximum follow-up was set to a minimum of 60 days postoperatively.

Variables and Outcomes

We extracted the following data from the patient files: age, sex, etiology, body mass index, American Society of Anesthesiologists (ASA) Physical Status Classification, relevant medical history, that is, diabetes mellitus, peripheral vascular disease (PVD), recipient vessels and technique of anastomosis, flap choice (gracilis or latissimus dorsi flap), and major and minor complications. The primary outcome was the major complication rate. The secondary outcome was the minor complication rate. Minor complications included hematomas, minor infections, and minor flap necrosis and major complications included major flap necrosis requiring flap revision and any unplanned revision due to vascular complication. Patients with incomplete data were excluded.

Statistical Methods

Patients were divided into three groups. Patients in group one exclusively had venous anastomosis at the level of the deep venous system (i.e., concomitant veins). Patients in the second group had at least one venous anastomosis utilizing the great saphenous vein and one venous anastomosis utilizing a concomitant deep vein. The third group only included patients that utilized the great saphenous vein as recipient vein. Demographics and characteristics of the groups were displayed in a contingency table by using basic descriptive statistical methods. Both the Fisher's exact test and the Freeman-Halton extension of the Fisher's exact test were used to calculate the effect of the recipient veins and the choice of flap on the rate of major and minor complications. SPSS Statistics software (version 20; SPSS Inc., Chicago, IL) was used for analysis. Results were classified as significant when *p*-values were smaller than 0.05.

Results

Descriptive Data

A total of 97 patients underwent free flap reconstruction at the lower extremity who met the inclusion criteria. Two patients were excluded because they met the exclusion criteria. All patients underwent multiple operations and negative wound pressure therapy to condition the defect prior to reconstruction. The arterial anastomosis was usually, manually sewn with Ethilon 8-0 single suture. The most often used artery was the posterior tibial artery (PTA; ▶ **Table 1**, *n* = 52) followed by the anterior tibial artery (ATA; *n* = 45). The arteries were sewn primarily in end-to-side fashion (*n* = 77). The decision on the selection of the recipient veins in each case depended on the quality of the available veins. We tried to establish at least two venous anastomoses. In 42 patients, two venous anastomoses could be established. In 55 patients, only one venous anastomosis was achievable. The venous anastomoses in our cases were mostly done via coupler-device (*n* = 133). The coupler size ranged from 1.5 to 3.0 mm. The veins were manually sewn when the size mismatch was greater than 1 mm (*n* = 6). All

Table 1 Patients demographics

	DV (n = 48)	DV + GSV (n = 26)	GSV (n = 23)
Injury cause			
● Trauma (n = 62)	32 (66.67)	15 (57.7)	15 (65.22)
● Infection (n = 17)	9 (18.75)	4 (15.38)	4 (17.39)
● Other (n = 18)	7 (14.58)	7 (26.92)	4 (17.39)
● Defect location			
● Foot and ankle (n = 50)	20 (41.67)	16	14
● Distal lower leg (n = 42)	23 (47.91)	10	9
● Proximal lower leg (n = 5)	5 (10.42)	0	0
Gender			
● Male (n = 55)	30 (62.5)	15 (57.69)	10 (43.48)
● Female (n = 42)	18 (37.5)	11 (42.31)	13 (56.52)
Mean age (y)	60.0 ± 17.96	55.81 ± 14.3	56.55 ± 20.5
Mean BMI (kg/m ²)	29.65 ± 6.4	27.24 ± 4.66	25.88 ± 6.08
PVD (n = 14)	8 (16.67)	4 (15.38)	2 (8.7)
Diabetes mellitus (n = 30)	16 (33.33)	8 (30.77)	6 (26.09)
Flap choice			
1. Gracilis (n = 80)	38 (79.17)	23 (88.46)	19 (82.61)
● Flap size (m ²)	1.26 ± 0.21	1.24 ± 0.19	1.25 ± 0.21
2. Latissimus dorsi (n = 17)	10 (20.83)	3 (11.54)	4 (17.39)
● Flap size (m ²)	4.14 ± 0.65	4.08 ± 0.93	4.10 ± 0.74
ASA Classification			
● ASA I (n = 27)	11 (22.92)	8 (30.77)	8 (34.78)
● ASA II (n = 41)	16 (33.33)	14 (53.85)	11 (47.83)
● ASA III (n = 28)	20 (41.67)	4 (15.38)	4 (17.39)
● ASA IV (n = 1)	1 (2.9)	0 (0)	0 (0)

Abbreviations: ASA, American Society of Anesthesiologists; BMI, body mass index; DV, deep vein; GSV, great saphenous vein; PVD, peripheral vascular disease.

Note: Data reported as n, n (%), or mean ± standard deviation.

anastomoses were done under the microscope. Postoperatively the patients were monitored on the intensive care unit for at least 24 hours before returning to normal care. Intensive flap monitoring was performed through clinical and Doppler examinations for at least 5 days. Nine patients suffered from minor complications (superficial skin infections: n = 4, partial loss of skin graft: n = 4, and seroma formation: n = 1). Eleven patients in total suffered from major complications requiring unplanned reoperation due to vascular complications. In all 11 cases, the arterial anastomosis was revised due to thrombosis. In five cases, the flap could be salvaged completely. In the other six cases, the flap could not be saved. All of the flap loss patients suffered from PVD and diabetes mellitus. The flap survival rate in total was 93.81%. The most prevalent cause for the defect was trauma (► **Table 2**, n = 62) followed by infection (n = 17) and other causes (n = 18) such as postoperative wound dehiscence after elective surgery. The flap size did not differ significantly between the three groups. The mean age of all patients was 57.8 ± 17.4 years. In the majority of cases, the gracilis muscle

flap (n = 80) with skin graft was chosen over the latissimus dorsi muscle flap (n = 17). In few of these patients, we harvested a skin paddle along the gracilis muscle in the sense of a transverse myocutaneous gracilis flap (TMG; ► **Fig. 1**). Forty-eight patients were organized in group one (deep veins [DV]), 26 patients formed group two (DV and great saphenous vein [GSV], i.e., DV + GSV) and 23 patients were arranged into the third group (GSV).

Outcome Data

Recipient Veins

The two-tailed Freeman–Halton extension of the Fisher's exact test statistic value comparing the effect of the three groups on the major and minor complication rate was 0.919 and 0.999, respectively (► **Table 3**). The result was not significant at $p < 0.05$.

Flap Choice

The Fisher's exact test statistic value comparing the effect of flap choice on the major complication rate was 0.022

Table 2 Characteristics of the microvascular anastomosis

	DV (n = 48)	DV + GSV (n = 26)	GSV (n = 23)
Recipient artery			
● ATA E-S (n = 34)	20 (41.67)	8 (30.77)	6 (26.08)
● ATA E-E (n = 11)	3 (6.25)	6 (23.08)	2 (8.7)
● PTA E-S (n = 43)	20 (41.67)	10 (38.46)	13 (56.52)
● PTA E-E (n = 9)	5 (10.42)	2 (7.69)	2 (8.7)
Number of venous anastomosis			
● Two (n = 42)	16 (33.33)	26 (100)	0 (0)
● One (n = 55)	32 (66.67)	0 (0)	23 (100)
Venous anastomosis technique			
● Coupled (n = 74)	59	52	22
● Hand sewn (n = 5)	5	0	1

Abbreviations: ATA, anterior tibial artery; DV, deep vein; E-E, end to end; E-S, end to side; GSV, great saphenous vein; PTA, posterior tibial artery. Note: Data reported as n or n (%).

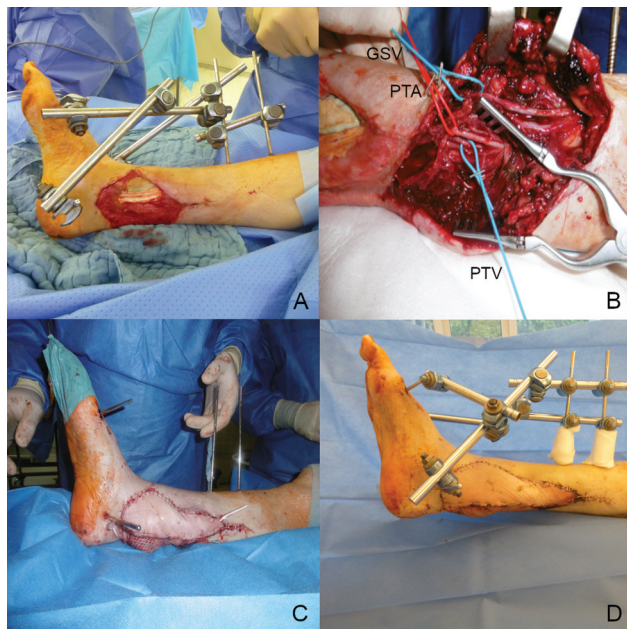


Fig. 1 Free flap reconstruction after open tibial fracture (Gustillo's type 3b) with bone and soft tissue defect. (A) Intraoperative photograph of a 74-year-old female patient with a traumatic defect at the right medial distal lower leg. (B) Intraoperative photograph of the recipient vessels. (C) Intraoperative photograph after insertion of a TMG flap. (D) Photograph at follow-up after 2 weeks postoperatively. GSV, great saphenous vein; PTA, posterior tibial artery; PTV, posterior tibial vein.

(→ **Table 4**). The result was significant at $p < 0.05$. When comparing the effect of the flap choice on the minor complications rate, the statistic value was 0.008. The result was also significant at $p < 0.05$.

Discussion

The selection of suitable recipient vessels for free flap plasty of the lower extremity remains a controversial topic. The main focus in the literature so far has been the investigation of the arterial recipient vessels.^{8,11} In this study, we took a closer look

Table 3 Outcomes regarding choice of muscle flaps

	Major complications	p-Value	minor complications	p-Value
Gracilis (n = 80)	6 (7.5%)	0.022 ^a	4 (5%)	0.008 ^a
Latissimus dorsi (n = 17)	5 (29.4%)		5 (29.4%)	

^aStatistically significant.

Table 4 Outcomes regarding choice of recipient veins

	Major complications	p-Value	Minor complications	p-Value
DV (n = 48)	5 (10.42%)	0.919	5 (10.42%)	0.999
DV + GSV (n = 26)	3 (11.54%)		2 (7.7%)	
GSV (n = 23)	3 (13.04%)		2 (8.7%)	

Abbreviations: DV, deep vein; GSV, great saphenous vein.

at venous recipient vessels, especially the saphenous vein as part of the superficial venous system. The majority of published articles avoid the use of the superficial system, as they are usually predamaged by trauma or infectious processes due to their exposed location and suffer from the so-called post-traumatic vessel disease.^{7,10,14} It is discussed whether these vessels suffer more often from vascular complications, such as venous thrombosis, after microsurgical anastomosis.^{7,10,14} Due to the communication of the superficial and the deep venous system via perforator veins, the thrombus may then pass from the superficial to the deep system. This theoretical scenario means that it must be explored whether such veins of the superficial system as potential recipient vessels should be avoided and if anastomoses should be limited to the

concomitant veins of the arteries. In clinical practice, however, there is only a limited selection of suitable venous connection vessels in the lower extremity, so that such selective demands cannot always be met.^{9,11} Reasons for the loss of function of the venous vessels can be the consequences of traumatic/infectious processes, acute (e.g., thrombophlebitis and deep vein thrombosis), and chronic venous diseases (e.g., varicosis and chronic venous insufficiency).¹⁵

Lorenzo et al also evaluated the impact of the type of venous anastomosis on the flap outcome of microsurgical lower extremity reconstruction.⁹ They describe venous insufficiency as most common cause for reexploration. The superficial venous system was associated with a higher rate of complications compared with the deep venous system. Additionally one-vein anastomosis flaps were associated with fewer complete flap failures in comparison, with two-vein anastomosis flaps. The findings in our study contradict to what Lorenzo et al described. We believe that these differences could be related to the technique of anastomosis (e.g., hand sewn anastomosis vs. coupler device).

From our clinical experience and after evaluation of our patient data, we do not consider the use of the superficial venous system, especially here the great saphenous vein to be problematic. In our study, we investigated whether the great saphenous vein as a recipient vessel would lead to an increase in the complication rate in free muscle flap plasty (gracilis and latissimus dorsi). We examined 97 patients for this purpose. In 26 patients, at least one of the two connecting vessels was the great saphenous vein. In 23 patients, the great saphenous vein was the only viable option as a recipient vein. In 48 patients, the connecting vessels were exclusively limited to the deep venous system.

The three patient collectives were comparable concerning their demographic data (► **Table 1**). Thus, all characteristics are represented with approximately the same frequency and do not show any major differences. The great saphenous vein as a superficial vein is more often exposed to the forces during high-energy traumas of the lower extremity. It is remarkable, however, that a high number of usable veins of the superficial system were still present and could be coupled in many posttraumatic states. In our clinical practice, we do not prefer one vein over the other. Only the intraoperative quality, condition, reachability, and size decide on their use. Preoperative angiography helps us to assess in advance. Our regular goal is to connect at least two veins whenever possible. Only in defects of the proximal lower leg, we find the GSV as not as suitable as the concomitant veins because of the higher distance to the arterial recipient vessel. The selection of venous anastomoses did not show a statistically significant influence on the rate of minor and major complications (► **Table 3**). In none of our cases, a venous vascular complication occurred. The reasons for major complications leading to complete flap loss were in all cases due to arterial thrombosis in patients with PVD and diabetes mellitus. These data support our approach and could show that the saphenous vein is an important recipient vessel for the microvascular connection of free flap plasty in the lower extremity and should always be considered. Microsurgical practices that regularly avoid the

superficial venous system on the lower extremity in trauma patients should be critically discussed.¹⁰

The different results regarding the choice of flap (► **Table 4**) are compatible with the literature. The latissimus dorsi flap as the largest possible muscle flap is reserved only for very large defects. In some previous studies, an increase in the complication rate with the size of the defect to be covered has been demonstrated.¹⁸

The group of patients examined here showed many previous diseases. A large proportion of them were suffering from PVD and diabetes mellitus. The average BMI value was also in the overweight range. A selection bias in favor of patients, who were too healthy, should, therefore, be excluded. Only the moderate sample size could reduce the test strength and the informative value. This was counteracted by the use of the exact Fisher's test. The knowledge gained here should apply to the general patient population with free flap surgery of the lower extremity to a limited extent, since retrospective studies can never clearly prove a causal relationship and the influence of confounding variables cannot be assessed entirely. Finally, all patients were operated by the senior surgeon and last author which should better validate our findings.

In free flap surgery of the lower extremity, the selection of the recipient veins should not be restricted to the deep accompanying veins of the main vessels. The superficial veins, especially the great saphenous vein, offer an underrated option when performing free flap reconstruction. In our retrospective study, we did not find an increased complication rate in the use of the saphenous vein as a recipient vein for free flap plasty for reconstruction of the defects of the lower extremity.

Authors' Contributions

A.M.: conception and design of the work, data collection, data analysis and interpretation, drafting the article, critical revision of the article, final approval of the version to be published; L.K.: critical revision of the article; L.K.: data collection; U.M.R.: critical revision of the article, final approval of the version to be published; A.B.: conception and design of the work, critical revision of the article, final approval of the version to be published.

Ethical Approval

Ethical approval for this study was obtained from the institutional review board (HCRI ID 2020-0135).

Patient Consent

Written informed consent was obtained from all the patients.

Conflict of Interest

None declared.

References

- Gorman PW, Barnes CL, Fischer TJ, McAndrew MP, Moore MM. Soft-tissue reconstruction in severe lower extremity trauma. A review. *Clin Orthop Relat Res* 1989;(243):57-64
- Engel H, Lin CH, Wei FC. Role of microsurgery in lower extremity reconstruction. *Plast Reconstr Surg* 2011;127(Suppl 1):228S-238S

- 3 Tomaino M, Bowen V. Reconstructive surgery for lower limb salvage. *Can J Surg* 1995;38(03):221–228
- 4 Yazar S, Lin CH, Wei FC. One-stage reconstruction of composite bone and soft-tissue defects in traumatic lower extremities. *Plast Reconstr Surg* 2004;114(06):1457–1466
- 5 Khouri RK, Shaw WW. Reconstruction of the lower extremity with microvascular free flaps: a 10-year experience with 304 consecutive cases. *J Trauma* 1989;29(08):1086–1094
- 6 Kim SY, Lee KT, Mun GH. Postoperative venous insufficiency in microsurgical lower extremity reconstruction and deep vein thrombosis potential as assessed by a caprini risk assessment model. *Plast Reconstr Surg* 2015;136(05):1094–1102
- 7 Muramatsu K, Shigetomi M, Ihara K, Kawai S, Doi K. Vascular complication in free tissue transfer to the leg. *Microsurgery* 2001;21(08):362–365
- 8 Park S, Han SH, Lee TJ. Algorithm for recipient vessel selection in free tissue transfer to the lower extremity. *Plast Reconstr Surg* 1999;103(07):1937–1948
- 9 Lorenzo AR, Lin CH, Lin CH, et al. Selection of the recipient vein in microvascular flap reconstruction of the lower extremity: analysis of 362 free-tissue transfers. *J Plast Reconstr Aesthet Surg* 2011;64(05):649–655
- 10 Yazar S, Lin CH. Selection of recipient vessel in traumatic lower extremity. *J Reconstr Microsurg* 2012;28(03):199–204
- 11 Badash I, Burt K, Leland H, et al. Effects of perioperative venous thromboembolism on outcomes in soft tissue reconstruction of traumatic lower extremity injuries. *Ann Plast Surg* 2019;82(5S, Suppl 4):S345–S349
- 12 Janhofer DE, Lakhiani C, Kim PJ, et al. The utility of preoperative arteriography for free flap planning in patients with chronic lower extremity wounds. *Plast Reconstr Surg* 2019;143(02):604–613
- 13 Acland RD. Refinements in lower extremity free flap surgery. *Clin Plast Surg* 1990;17(04):733–744
- 14 Stranix JT, Borab ZM, Rifkin WJ, et al. Proximal versus distal recipient vessels in lower extremity reconstruction: a retrospective series and systematic review. *J Reconstr Microsurg* 2018;34(05):334–340
- 15 Heidekrueger PI, Ehrl D, Heine-Geldern A, Ninkovic M, Broer PN. One versus two venous anastomoses in microvascular lower extremity reconstruction using gracilis muscle or anterolateral thigh flaps. *Injury* 2016;47(12):2828–2832
- 16 von Elm E, Altman DG, Egger M, Pocock SJ, Gøtzsche PC, Vandenbroucke JPSTROBE Initiative. The strengthening the reporting of observational studies in epidemiology (STROBE) statement: Guidelines for reporting observational studies. *Int J Surg* 2014;12(12):1495–1499
- 17 World Medical Association. World Medical Association Declaration of Helsinki. Ethical principles for medical research involving human subjects. *Bull World Health Organ* 2013;12(12):1495–1499 PubMed
- 18 Lee ZH, Abdou SA, Ramly EP, et al. Larger free flap size is associated with increased complications in lower extremity trauma reconstruction. *Microsurgery* 2020;40(04):473–478