



Rhinoplasty with Recycled Dorsum Preservation: Technique and Outcomes

Carlos A. Rodriguez, MD¹ Ali M. Al-Sakkaf, MD² Mauricio Verbauevede, MD³

¹Department of Plastic Surgery, Hospital Universitari Sant Joan de Reus, Tarragona, Spain

²Department of Plastic Surgery, Hospital de la Santa Creu i Sant Pau, Universitat Autònoma Barcelona, Barcelona, Spain

³Clínica Verbauevede, Madrid, Spain

Arch Plast Surg 2022;49:563–568.

Address for correspondence Mauricio Verbauevede, MD, Clínica Verbauevede, Gaztambide 46, Madrid 28015, Spain (e-mail: mauricioverbauevede@gmail.com).

Carlos A. Rodriguez, Department of Plastic Surgery, Hospital Universitari Sant Joan de Reus, Avinguda del Doctor Josep Laporte, 2, 43204 Reus, Tarragona, Spain (e-mail: carlosrodriguezpacci@gmail.com).

Abstract

Rhinoplasty is one of the first surgical procedures described with evidence in the history of medicine. At first, these were performed for the reconstruction of traumatic defects caused by punishments, sequels of war, and then it had been reused after suffering from diseases such as syphilis. Many techniques have been developed from the need of aesthetics outcomes in this field.

The objective of our work is to describe a modified approach of recycled dorsum preservation procedure that we have proposed as a safe and reliable technique.

In this work, we have showed that this technique has a marked advantage of preserving the natural tissue with satisfactory postoperative result. We had no functional complications up to date. We recommend that every specialist in the field of rhinoplasty should be able to use it as a reproducible and feasible alternative.

Keywords

- ▶ rhinoplasty
- ▶ nose
- ▶ hypertrophy
- ▶ nasal septum

Introduction

The treatment of the nasal dorsum is a subject of continuous debate from the beginning of rhinoplasty until the current days, due to the different treatment alternatives.

The concept of aesthetic rhinoplasty was born at the end of the 19th century, introduced by John Roe in 1891 who not only made a meticulous classification according to different ethnic groups, but also described the technique used with local anesthesia without the need for general anesthesia in five patients.¹

In 1931 Jakob Levin Joseph, published a book that set the beginning of cosmetic surgery of the face, classifying the diverse types of deformities, and describing the

surgical techniques with the instruments used.² With the advancement of these aesthetic techniques begin the expansion of rhinoplasty around the world performed by many prestigious surgeons. At that period, Jakob Levin Joseph introduce the concept of close rhinoplasty, and his technique was based on nonpreservation approach.

In 1934, Aurel Rethi proposed an open approach that allowed a wide anatomical exposure and was considered to treat hyperprojected noses through a columellar incision. Without achieving good aesthetic results at that moment, the technique was forgotten for a few years,³ till then, all the procedure were under the concept of nonpreservation until the idea of preservation was born.

received

December 11, 2021

accepted after revision

April 18, 2022

DOI <https://doi.org/>

10.1055/s-0042-1756314.

ISSN 2234-6163.

© 2022. The Korean Society of Plastic and Reconstructive Surgeons. All rights reserved.

This is an open access article published by Thieme under the terms of the Creative Commons Attribution-NonDerivative-NonCommercial-License, permitting copying and reproduction so long as the original work is given appropriate credit. Contents may not be used for commercial purposes, or adapted, remixed, transformed or built upon. (<https://creativecommons.org/licenses/by-nc-nd/4.0/>)

Thieme Medical Publishers, Inc., 333 Seventh Avenue, 18th Floor, New York, NY 10001, USA

The concept of preserving the nasal dorsum was introduced by Goodale, who describes removing the subdorsal cartilage followed by lateral osteotomies.⁴ Lothrop added bone resections and transverse osteotomies to this technique.⁵ Many authors in France began reporting successful cases with similar techniques and Maurice Cottle in 1946, reintroduced the Goodale approach under the concept of "Push Down."⁶ Drumheller and Huizing reestablished Lothrop's idea of bone resection under the concept of "Let Down."^{7,8} Different alternatives were reported by cartilaginous resection combined with bone resections but step by step the concept of the dorsum preservation of the nose was more familiar.

In 1966, Tord Skoog, combined preservation and reduction concepts in a revolutionary idea, thinking to solve the excessive resections that were made by the Joseph's original technique, as well as the asymmetries due to calculation failures.⁹

The importance of this reviewed history is to demonstrate the diversity of the techniques that have been described and the importance to know each of them, to include their concepts in our surgical practice.

We described in this article a dorsal recycled preservation technique based on a modified approach of the original Skoog's technique, our approach includes four main points: the open access, preparation of the recipient site with preservation of the caudal part of the septal cartilage, fixation of the recycled hump like a piece of puzzle to the recipient site, and the use of modern technologies which is the piezoelectric device.

We believe that recycling the hump in rhinoplasty achieves better outcomes especially after surgery when patients touch their dorsum of the nose and do not feel any irregularities, comparing with nonreplaced hump techniques.

Although the definitions of preservation and reduction sound opposite we are going to demonstrate that these two concepts are complementary, transforming rhinoplasty into a safe and reproducible procedure to achieve a natural aesthetic result.

Ideas

Our approach is based on trying not to remove natural tissues if those could be preserved and recycled, and to maintain a sustainable result over the time.

We perform an open approach with dorsal preservation technique which is different from the typical preservation approach like push down or let down, that was done for all patients with or without nasal deviations and for those with nasal drop during smiling effect.

Planning

After conducting a complete functional and aesthetic evaluation, including the preoperative risks, and assessing patients' expectations and wishes, the informed consent of the patient was completed.

The process continued with photographs which is performed with a digital camera, with static and dynamic

sequences. During this stage, facial asymmetries and the effect of the smile on the nose are recorded, where we can plan the surgery precisely even though we use the same technique. The preoperative planning is very important, especially in patients with nasal deviations or when we realize the drop of the nasal tip during smiling, our technique could solve these kinds of problems, actually it become the precise indications for those cases. Finally, the simulation software add more values specially to detect the aforementioned structural problems, the images are recreated to evaluate the postoperative changes, and to explain complications, based on real expectations of the results that we can offer to patients.^{10,11}

Surgery

The procedure is performed under general anesthesia. The surgery begins with an open rhinoplasty approach. Infiltration is performed using lidocaine with epinephrine, which allows not only the control of bleeding, but also the hydrodissection of tissues. An open rhinoplasty is performed through a Z-plasty transverse columellar incision.¹² Once the incision is completed, all planes are selectively dissected. The dermocarilaginous ligament of Pitanguy is identified, completely dissected, and cut, then left to be repaired for later plasty¹³ (► Fig. 1).

Dissection is continued through the inter-wing cartilages and the soft tissues to have a complete view of the septal cartilage. In this way, we can perform an easy, controlled, and fast dissection of the mucosa through a subperichondral plane.

Once the different anatomical elements have been exposed, we proceed to cut the upper part of the septal cartilage, preserving the caudal portion which will be useful as self-support to the tip of the nose as a natural strut.¹⁴

Considering the needs of reduction, the upper lateral cartilages are sectioned in their internal portion and

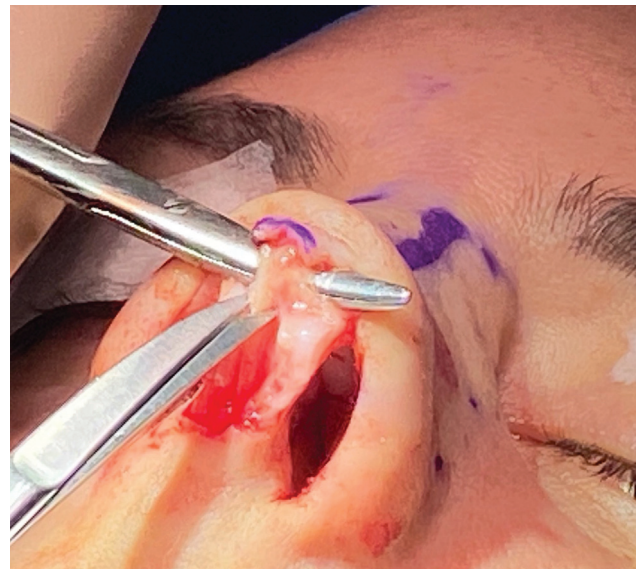

Fig. 1 Meticulous dissection of Pitanguy ligament. Dissection and cutting at the distal part of the Pitanguy ligament in open approach rhinoplasty.

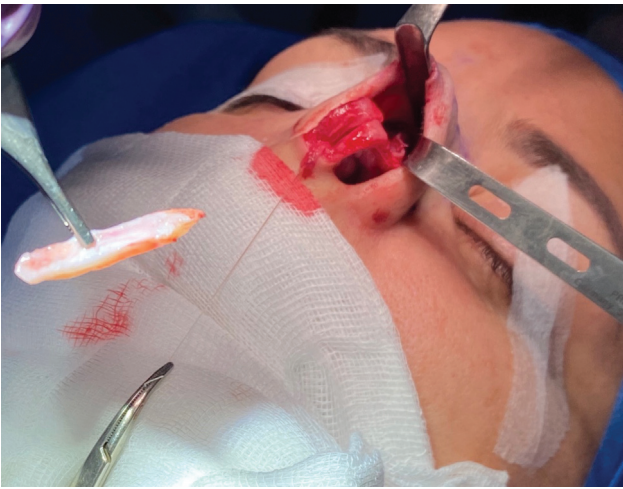

Fig. 2 Nose hump remodeling with open approach rhinoplasty. Remodeling the hump to recreate the new dorsum of the nose by cutting the excess of the nose hump but conserving the periosteum. Visualizing all the anatomical elements in open approach to facilitate the insertion of the recycled dorsum.

continued along the same line, drawing an inverted V, with perpendicular osteotomies along the nasal bones. Once this step is completed, the hump is removed and redesigned for later use as a “recycling approach” (► **Fig. 2**). Lateral osteotomies are added to allow an adaptable and stable reduction to suit the new designed size.

Once the different anatomical elements have been exposed and the hump is removed, we proceed to cut the upper part of the septal cartilage, preserving the caudal portion which will be useful as self-support to the tip of the nose as a natural strut.¹⁴ In this way, we prepare the bed to be attached to the recycled hump in a way resembling a piece of puzzle. This permits us to minimize the future complication like radix steps or abnormalities on palpations, also conceals any deviation of the upper part of the septum.

All osteotomies were performed with prior marking and subsequent section with a piezoelectric device, to have an adequate precision and better damage control.¹⁵

At final stage, once the new dorsum is recreated, we make the fixation with absorbable suture (polydioxanone) to the caudal portion of the septal cartilage (strut) and through holes that was performed by the piezoelectric device, it is also fixed to the nasal bones and the lateral cartilages. This fixation allows stability of the new hump and to avoid the possibility of any displacement (► **Fig. 3**).

Once the expected result has been achieved, the dermo-cartilaginous ligament is reinserted and repositioned in the correct position after treatment of the dorsum, this guarantees a true plasty of this anatomical element and conserving the dynamic harmony of the nose.

The procedure ends with nasal tip treatment and subsequent closure of the skin. We clarify that it is not the purpose of this article to describe this part of the surgery (the nasal tip), although we consider it as an integrative part of any rhinoplasty, because it needs a meticulous description and exceeds the objective of this work (Supplementary Material ► **Video 1**, available online only).

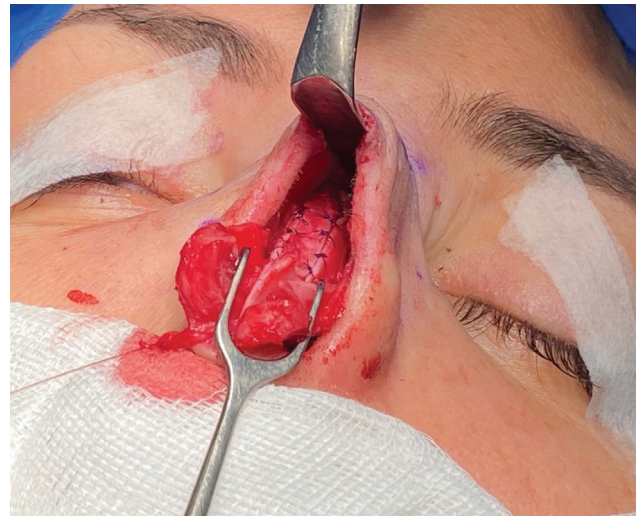

Fig. 3 Final osteocartilaginous dorsum insertion and fixation. Fixation of the reshaped dorsum with polydioxanone (PDS) suture in rhinoplasty.

Video 1

Recycled dorsal preservation approach. Step by step description of the surgical procedure. Online content including video sequences viewable at: <https://www.thieme-connect.com/products/ejournals/html/10.1055/s-0042-1756314>.

Postoperative Care and Follow-Up

The nose is immobilized with an articulated nasal splint, which is left for 7 days.

The patients were recommended to return to their daily activities as soon as possible without making positive pressure on the nose for at least 40 days.

A regular follow-up was done at 1, 2, and 6 months and then yearly followed up.

A quality questionnaire (Likert scale) was given to all patients at their 6 months postoperative follow-up to assess the sensation, to evaluate the regularity of the dorsum, patient expectation, and overall satisfaction. We believe that the postoperative sensation is very important to be preserved specially in open approach rhinoplasty to achieve a natural result and should be included as an essential goal in all rhinoplasties.

Results

From January 2018 to April 2021, we performed a series of 300 dorsal preservation rhinoplasties with the previously described technique. The intervention was performed more in women than in men with a ratio of 7:3, the range of patients' age was between 24 and 28 years.

With a period of follow-up of minimally 6 months to 4 years, there was no reported bone or cartilage resorption or mobilization of the recycled hump. There were only two patients who reported dissatisfaction with the scar of the open approach, three patients had some fibrosis and

Table 1 Reported complications after 300 rhinoplasties with dorsum preservation

Complications	Total patients no: 300 (%)
Orbital ecchymosis	15 (5)
Fibrosis	3 (1)
Scar in satisfaction	2 (0.66)
Nasal obstruction	0
Nose deviation	0
Radix step	0
CSF leakage	0
Hump recurrence	0

Abbreviation: CSF, cerebrospinal fluid.
 Note: Values are presented as number (%).

resolved completely with the infiltration of local corticoid like triamcinolone, and 5% of patients had mild ecchymosis, we consider that these complications were expected for this kind of procedure.

We did not have any report of complications such as cerebrospinal fluid leak, radix step, or hump recurrence at long-term follow-up (►Table 1).

Additionally, there was no reported lose or severe alteration regarding the dorsal skin sensation and around 80% had mild or no alterations at all. In regard to patient’s satisfaction we had the following: extremely satisfied 50%, highly satisfied 40%, and moderately satisfied only 10% (►Figs. 4 and 5).

Example of preoperative photos and the final results of our technique are shown in ►Figs. 6–8.

Discussion

Rhinoplasty is currently one of the most frequently performed surgical procedures by plastic surgeons, otolaryng-

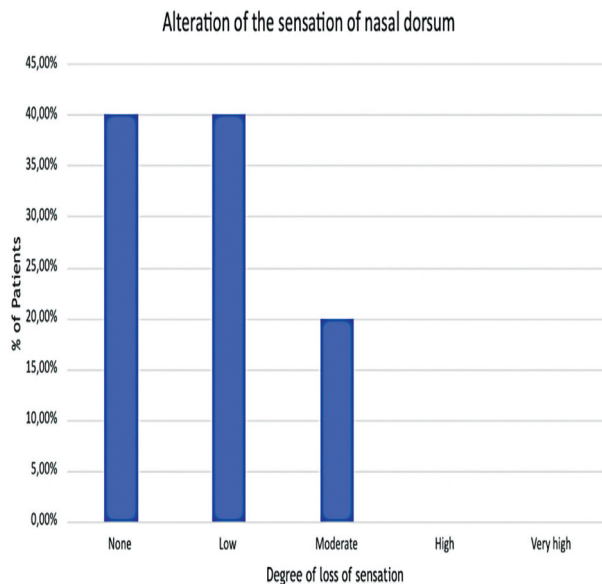


Fig. 4 Dorsal skin sensation after rhinoplasty. Patients reported result 6 months after surgery.

ologists, or maxillofacial surgeons. Our modified rhinoplasty’s main indication is primary reduction rhinoplasties, although it can be used for any degree of hump hypertrophy especially in patients with nasal deviation. Furthermore, it can be also combined with different techniques for nasal tip treatment.

Comparing to Skoog technique, who was the first to mentioned the preservation of the hump aiming to avoid any dorsal irregularities, we have described a modification to his technique by changing and adding other steps that could give a better end result.⁹

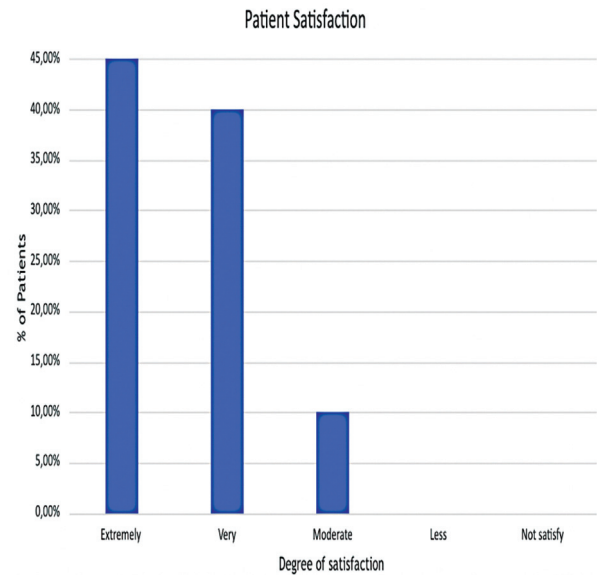


Fig. 5 Patients’ satisfactions postrhinoplasty. Patient results with this modified technique.

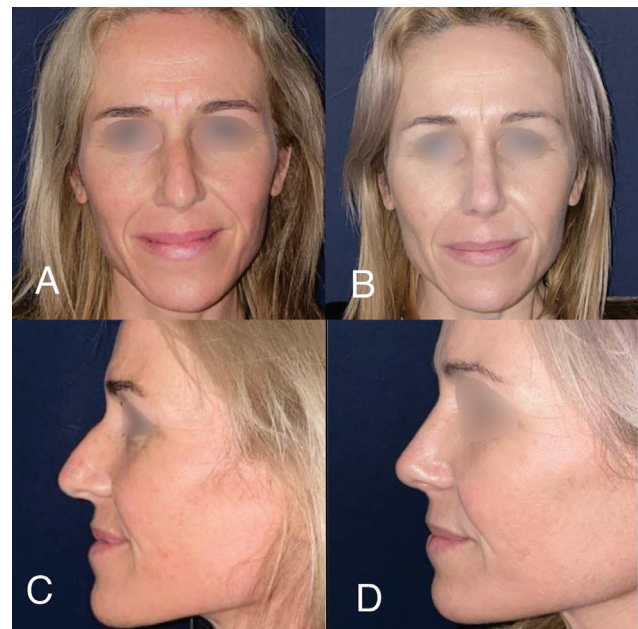

Fig. 6 Patient 1: Before and after rhinoplasty with recycled dorsum preservation. (A) Frontal view before surgery. (B) Frontal view after surgery. (C) Lateral view before surgery. (D) Lateral view after surgery.

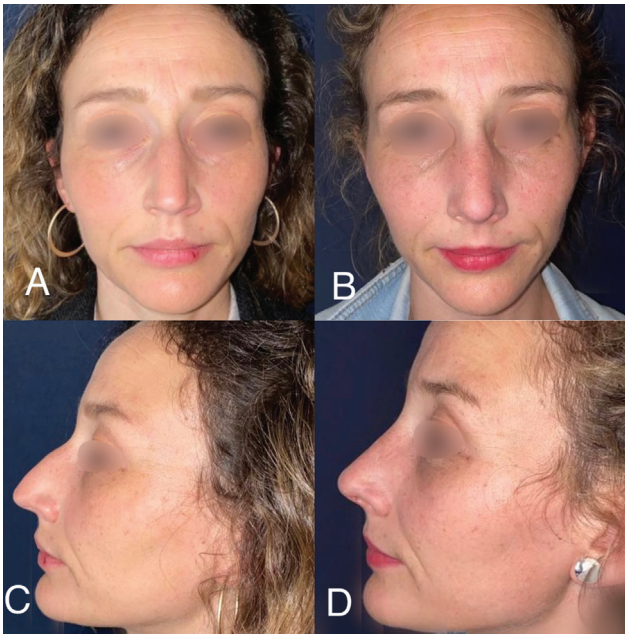

Fig. 7 Patient 2: Before and after rhinoplasty with recycled dorsum preservation. (A) Frontal view before surgery. (B) Frontal view after surgery. (C) Lateral view before surgery. (D) Lateral view after surgery.

The open approach of this modified technique not only allows us to have a wide anatomical exposure, but also gives us the additional advantages like comfort in handling of nasal tip, reducing skin when is necessary, and to avoid any respiratory complications.

We consider that the Pitanguy dermocarilaginous ligament is an essential functional element to be preserved. Many authors suggest the simple dissection of this structure is to improve the drooping of the nasal tip.¹⁶ Our concept in this point is like any other anatomical structure in our body, the fore mentioned ligament has a function in facial gestures that gives naturalness, its removal leads to lack of nasolabial dynamics, ends with nose without significant mobility, thus we usually fix it in the correct place.

We cut the osteocarilaginous hump except the caudal part to reduce the hypertrophy and to avoid the drop of the nose, then we recycled this hump as described to recreate a new dorsum providing a good aesthetic and natural outcome without losing sensitivity, combined with a regular and smooth dorsum. The fixation of the recycled hump to the specific insertion bed was done to ensure further stability.

The preservation of the caudal portion of the septal cartilage offers support not only to the tip of the nose, but also for the fixation of different elements, keeping a solid structure that gives the nose sustainability over time.

This technique showed good results without evidence of significant pain, probably because of two main factors: first, due to the damage control steps of the intervention by doing a meticulous anatomical dissection (the open approach), and second, due to the performance of osteotomies with piezoelectricity that ensured precision and decreased inflammatory process.

Dorsal preservation surgery continues to be a reliable procedure, especially with the addition of a recycled hump.

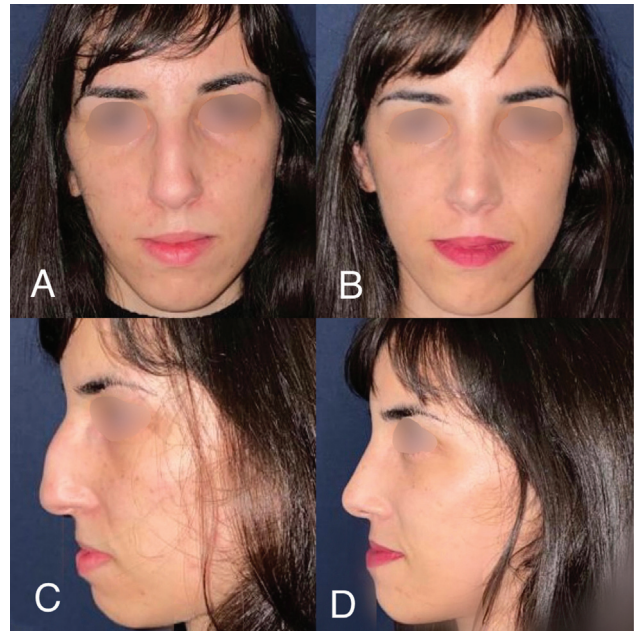


Fig. 8 Patient 3: Before and after rhinoplasty with recycled dorsum preservation. (A) Frontal view before surgery. (B) Frontal view after surgery. (C) Lateral view before surgery. (D) Lateral view after surgery.

We consider that although many rhinoplasty techniques were described years ago, the advancement of recent technologies allow us to readapt the old concepts and adjusting them to the current days. The described modified technique is reproducible, offering aesthetic, natural, and functional results that satisfy patients' needs.

Ethical Approval

This study was performed in accordance with the principles of the Declaration of Helsinki.

Patient Consent

The patients provided a written informed consent for the article publication and the use of their images.

Authors' Contributions

Conceptualization: M.V. Data curation: C.A.R., M.V. Formal analysis: C.A.R., M.V. Methodology: C.A.R., A.M.A.-S., M.V. Project administration: C.A.R., M.V. Visualization: C.A.R., M.V. Writing - original draft: C.A.R., A.M.A.-S., M.V. Writing - review and editing: C.A.R., A.M.A.-S., M.V. Approval of final manuscript: C.A.R., A.M.A.-S., M.V.

Conflict of Interest

None declared.

References

- 1 Roe JO. A classic reprint: the deformity termed "pug-nose" and its correction, by a simple operation. By John O. Roe.1887. *Aesthetic Plast Surg* 1986;10(02):89-91
- 2 Joseph J. Nasenplastik und sonstige Gesichtsplastik, nebst einem Anhang über Mammoplastik und einige weitere Operationen aus dem Gebiete der ausseren Körperplastik. *Imperial* 1931;8:843

- 3 Nguyen PS, Mazzola RF. Histoire de la rhinoplastie esthétique. *Ann Chir Plast Esthet* 2014;59(06):374–379
- 4 Goodale JL. A new method for the operative correction of exaggerated Roman nose. *Boston Med Surg J* 1899;140:112
- 5 Lothrop O. An operation for correcting the aquiline nasal deformity; the use of new instrument; report of a case. *Boston Med Surg J* 1914;170:835–837
- 6 Patel PN, Abdelwahab M, Most SP. A review and modification of dorsal preservation rhinoplasty techniques. *Facial Plast Surg Aesthet Med* 2020;22(02):71–79
- 7 Drumheller GW. The Cottle push down operation. *Am J Cosmet Surg* 1995;12(03):255–261
- 8 Huizing EH. Push-down of the external nasal pyramid by resection of wedges. *Rhinology* 1975;13(04):185–190
- 9 Skoog T. A method of hump reduction in rhinoplasty. A technique for preservation of the nasal roof. *Arch Otolaryngol* 1966;83(03):283–287
- 10 Ishii LE, Tollefson TT, Basura GJ, et al. Clinical practice guideline: improving nasal form and function after rhinoplasty. *Otolaryngol Head Neck Surg* 2017;156(2_suppl, suppl):S1–S30
- 11 Swamy RS, Sykes JM, Most SP. Principles of photography in rhinoplasty for the digital photographer. *Clin Plast Surg* 2010;37(02):213–221
- 12 Rethi A. Operation to shorten an excessively long nose. *Rev Chir Plast* 1934;2:85–85
- 13 Pitanguy I. Revisiting the dermocarilaginous ligament. *Plast Reconstr Surg* 2001;107(01):264–266
- 14 Rohrich RJ, Hoxworth RE, Kurkjian TJ. The role of the columellar strut in rhinoplasty: indications and rationale. *Plast Reconstr Surg* 2012;129(01):118e–125e
- 15 Robiony M, Polini F, Costa F, Toro C, Politi M. Ultrasound piezoelectric vibrations to perform osteotomies in rhinoplasty. *J Oral Maxillofac Surg* 2007;65(05):1035–1038
- 16 Tian J, Li Z, Luo Z, Wang H. Clinical anatomic study of Pitanguy ligament of the nose [in Chinese]. *Zhonghua Zheng Xing Shao Shang Wai Ke Za Zhi* 2014;30(02):126–129