



# Anatomical Study of the Close Association between Latissimus Dorsi and Surrounding Muscles. How to Safely Harvest the Muscle?

Sangho Oh, MD<sup>1</sup> Hyunju Kim, MD<sup>2</sup> Jae-Ho Lee, MD, PhD<sup>3</sup> Daegu Son, MD, PhD<sup>4</sup>

<sup>1</sup> Saeson Hospital, Daejeon, South Korea

<sup>2</sup> Opera Plastic Surgery, Seoul, South Korea

<sup>3</sup> Department of Anatomy, Keimyung University School of Medicine, Daegu, South Korea

<sup>4</sup> Department of Plastic and Reconstructive Surgery, Keimyung University Dongsan Hospital, Daegu, South Korea

Address for correspondence Daegu Son, MD, PhD, Department of Plastic and Reconstructive Surgery, Keimyung University Dongsan Hospital, 1035, Dalgubeol-daero, Dalseo-gu, Daegu, Republic of Korea (e-mail: handson@dsmc.or.kr).

Arch Plast Surg 2022;49:596–603.

## Abstracts

**Background** We suggested an easy and effective harvesting technique to avoid injury to tissues adjacent to the latissimus dorsi (LD).

**Methods** Between 2007 and 2017, breast reconstruction was performed with an LD flap using the “bottom-up” technique. Medical records were retrospectively reviewed. Data on postoperative complications, results, and follow-up were obtained. Nine cadaveric dissections were performed to assess positional relationships between LD and adjacent muscles based on the ribs where relevant muscles and LD attach. Overall, 78 LD flaps were harvested without complications.

**Results** Average age was 45.4 years. The mean operation time was 260 minutes. There were no abnormalities or injuries in the adjacent fascia and muscles during the flap harvest. Drains were removed at an average of 21.9 days postoperatively. In all cadavers, there was conjoined fascia between the thoracolumbar and LD fasciae. The average level of the merging point between the LD and external oblique muscle (EOM) was 8.9 to 11.1 ribs. The average level of the overlapping point between the LD and serratus posterior inferior (SPI) was 9.5 to 11.1 ribs.

**Conclusions** There are three dangerous zones during LD flap harvesting. The first zone is where the conjoined fascia encompasses the LD and thoracolumbar fasciae. The second zone is where the LD merges with the EOM and the serratus anterior. The third zone is the lower part where the LD merges with the SPI and EOM. The “bottom-up” technique enables a more meticulous and atraumatic operation by beginner flap surgeons.

## Keywords

- ▶ breast reconstruction
- ▶ latissimus dorsi
- ▶ surgical flaps
- ▶ myocutaneous flap

## Introduction

The latissimus dorsi (LD), a musculocutaneous flap, was introduced in 1906 by Iginio Tansini.<sup>1</sup> The LD flap is known as the universal flap. Pedicled LD musculocutaneous flaps are

used for medium-sized breast reconstruction mainly in Korea.<sup>2</sup> A pedicled or a free flap can cover defects at the back, at the chest wall, and in the lower extremities because of its reliably large area. Furthermore, pedicled LD musculocutaneous flaps are relatively easy to harvest. This explains

received

December 9, 2021

accepted after revision

March 29, 2022

DOI <https://doi.org/10.1055/s-0042-1756293>.

ISSN 2234-6163.

© 2022. The Korean Society of Plastic and Reconstructive Surgeons. All rights reserved.

This is an open access article published by Thieme under the terms of the Creative Commons Attribution-NonDerivative-NonCommercial-License, permitting copying and reproduction so long as the original work is given appropriate credit. Contents may not be used for commercial purposes, or adapted, remixed, transformed or built upon. (<https://creativecommons.org/licenses/by-nc-nd/4.0/>)

Thieme Medical Publishers, Inc., 333 Seventh Avenue, 18th Floor, New York, NY 10001, USA

why most novice plastic surgeons commonly use this procedure for soft tissue reconstruction.<sup>3</sup> To achieve better outcomes and to reduce postoperative complications, preoperative, intraoperative, and postoperative managements are important. Of these, the most important factor is to harvest the flap safely without injuring the adjacent structures using a procedure called the atraumatic harvest technique.

There are many muscles around the LD. The trapezius, a muscle on the back, is more superficial than the LD. On the other hand, the thoracolumbar fascia (TLF), serratus anterior muscle (SAM), and external oblique muscle (EOM) are located underneath the LD. During LD harvest, the surgeon must check the margin of each muscle and resect them correctly. However, there are points that may cause confusion during LD harvest. These points include the merging and overlapping points. The merging point is where the three structures, namely, the TLF, EOM, and serratus posterior inferior (SPI), converge. The overlapping point is where the trapezius, SAMs, and teres major overlap. Recognizing these two points and performing a pure LD harvest without injuring the adjacent tissues results in fewer postoperative complications.

Several studies and textbooks have discussed LD harvest techniques,<sup>4-6</sup> including flap design and approach modality. In general, the choice of flap design and approach modality relies on situational circumstances. For a novice flap surgeon, factors such as anatomical complexity and atraumatic operative technique are more important. However, these studies did not address the anatomical and technical details of an LD flap harvest.

For these reasons, this study aimed to propose a novel technique in harvesting LD flaps without injuring the adjacent tissues. The technique is called the “bottom-up” technique. We also observed the relationship between the LD and its adjacent muscles by means of cadaveric dissections to verify their anatomy and resolve confusing points, such as the merging and overlapping points, during LD harvest.

## Methods

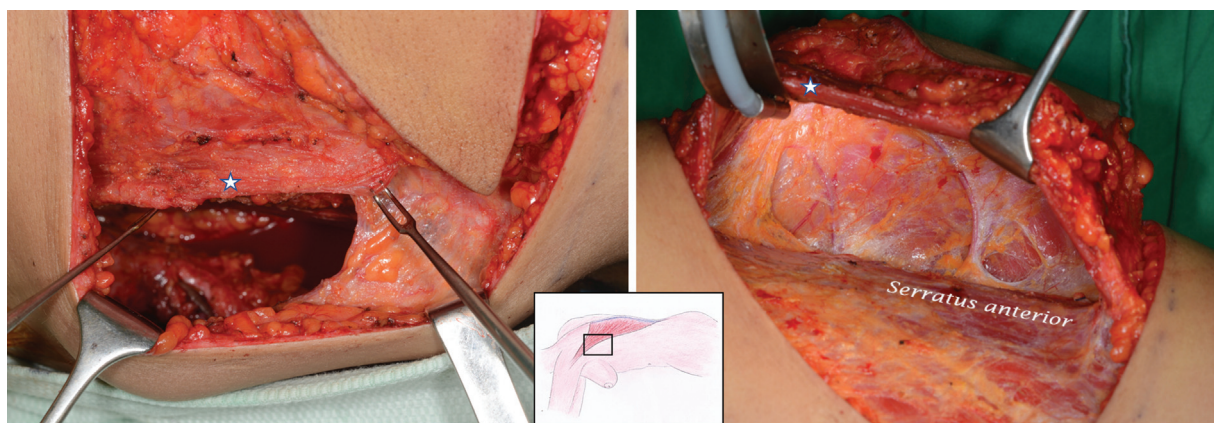
Between August 2007 and August 2017, 78 LD flaps were performed for autologous breast reconstruction by a senior

plastic surgeon. The institutional review board at our hospital reviewed and approved this study (approval no.: DSMC-2017-07-042). The inclusion criteria were as follows: (1) breast cancer patients with immediate breast reconstruction using LD flaps and (2) patients with a small-to-moderate breast volume. There were no exclusion criteria in this study. Medical records were reviewed retrospectively. Data on operative notes, postoperative complications, results, and follow-up were obtained. Based on medical records, patients visited our outpatient clinic 3, 6, and 12 months postoperatively. Thereafter, patients came for follow-up check-ups annually. Clinical photographs were taken at 3, 6, and 12 months postoperatively. Informed consent was obtained from all patients.

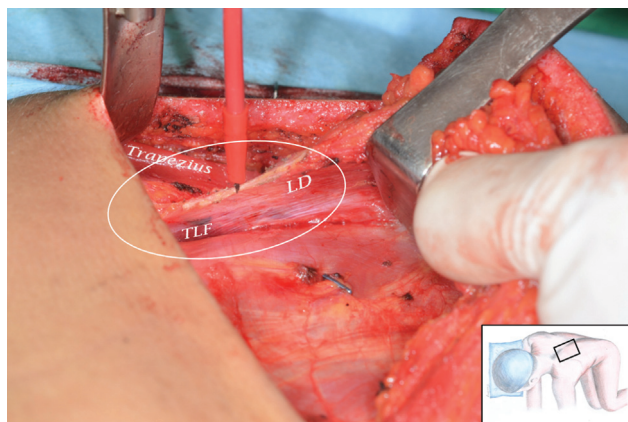
## Operative Technique

Patients were positioned in the lateral decubitus or prone position. If an LD muscle flap was needed, we incised along the posterior axillary line. If an LD musculocutaneous flap was needed, we incised along the upper and lower borders of the cutaneous flap. We then dissected the LD, located its fascial plane, and partially exposed it. Subsequently, we dissected the LD muscle anteriorly to locate its anterior border near the posterior axillary line. The anterior border of the LD muscle was very thin and usually found between the subcutaneous fat. The mobile anterior border of the LD was then identified. It extended from the posterior axillary fold to the point where the SAM and EOM were intimately joined together. The anterior border of the LD was away from the chest wall which made entering its undersurface from its anterior border easy. It was as if we were opening a window to enter the muscle's undersurface. We continued dissecting the loose areolar tissue which was located underneath the LD. On reaching the superior border of the LD, the lower digitations of the SAMs and the teres major muscles with the LD were safely detached (►Fig. 1).

We dissected the surface of the LD muscle medially to reach the lateral border of the trapezius muscle. We then dissected inferiorly until the trapezius muscle got separated from the LD. We were careful enough not to damage any of the adjacent structures. Continuing the dissection, the



**Fig. 1** Window entering LD muscle's underneath. (Left) The stars showed the anterior border of latissimus dorsi muscle. If surgeons found this thin point between the subcutaneous fat, muscle dissection was taken along the underneath of latissimus dorsi. (Right) Serratus anterior muscle was safely detached with latissimus dorsi muscle. LD, latissimus dorsi.



**Fig. 2** The danger zone 1. After retracting the trapezius and latissimus dorsi muscles, the whitish conjoined thoracolumbar fascia was found. LD, latissimus dorsi; TLF, thoracolumbar fascia.

muscles underneath the LD medially until the midline was reached, the TLF attached to the LD and the TLF attached to the long muscle of the back and the SPI were easily separated. We then cut the isolated glistening fascia using the Bovie electrocautery device from the interior to the exterior surface. This procedure did not damage any fascia located underneath. This was dangerous area for beginner surgeons to operate on due to the high incidence of injury to the underlying TLF muscles (►Figs. 2 and 3).

When the fascial structure of the LD muscle was resected inferiorly, there was a secured surgical field. The muscle and the fascia underneath the LD which included the SPI muscle, and the TLF was safely detached. At this point, the lateral inferior connection of the LD with the EOM could be clearly observed to be in the shape of a staircase. After the LD muscle was released sufficiently from the medial side, the muscle could be sufficiently reversed spatially. At this time, the surgeon observed the direction of the muscle fibers because the LD and EOM meet at almost right angles. By examining this well by means of in and out cutting, the LD could be safely separated without injuring the LD and EOM. This was the second most dangerous area where a beginner surgeon could make a mistake (►Fig. 4).►Video 1 (available in the

online version) shows the dissection technique in danger zone 2.

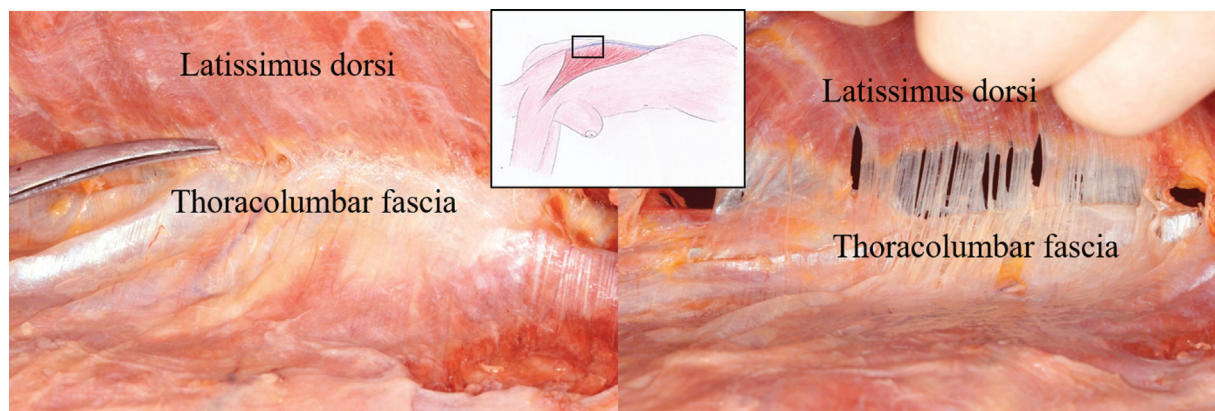
#### Video 1

The external oblique abdominis muscle merge with latissimus dorsi. See the “Bottom-up technique” cutting directions from inner side to outer side with monopolar electrocautery in danger zone 2. Online content including video sequences viewable at: <https://www.thieme-connect.com/products/ejournals/html/10.1055/s-0042-1756293>.

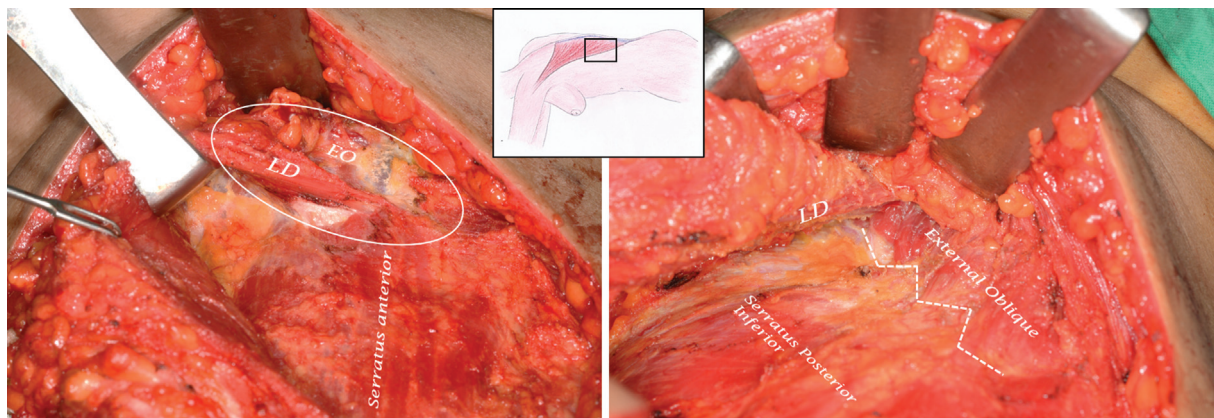
The remaining part was the inferior LD which was connected to the muscle that originated from the iliac crest and fascial system. We incised the muscle or fascia using the Bovie electrocautery from underneath the muscle until the yellow fat layer was exposed. This method did not injure the subcutaneous fat layer. Since this part was relatively deep, it might not have been possible to distinguish the muscles from each other. However, our method of cutting the muscles from the bottom to the outside could safely separate the LD. This was considered the third most dangerous area for beginner surgeons. The muscles that could potentially be damaged in this area were the SPI and the EOM (►Figs. 5 and 6). ►Video 2 (available in the online version only) shows the dissection technique in danger zone 3.

#### Video 2

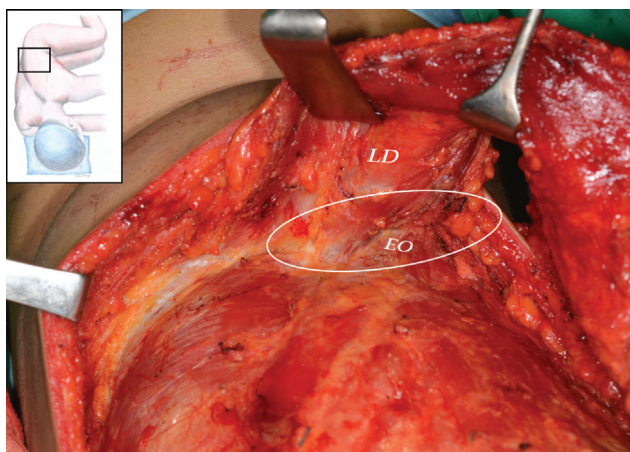
The serratus posterior inferior muscle merge with latissimus dorsi. See the “bottom-up technique” cutting directions from inner side to outer side with monopolar electrocautery in danger zone 3. Online content including video sequences viewable at: <https://www.thieme-connect.com/products/ejournals/html/10.1055/s-0042-1756293>.



**Fig. 3** (Left) In cadaver dissection, conjoined fascia between thoracolumbar fascia and latissimus dorsi fascia was found. (Right) Retract the latissimus dorsi during the operation, we can see where the monopolar electrocautery should go. LD, latissimus dorsi.



**Fig. 4** (Left) The danger zone 2. The white circle showed the latero-inferior of the latissimus dorsi connection with the external oblique abdominis muscles with right angles. Surgeons need to cut this conjoined fascial structure sharply. (Right) The stairstep-shaped latissimus muscle merging point with the external oblique abdominis muscle was found after sharp release of the LD. EO, external oblique; LD, latissimus dorsi.

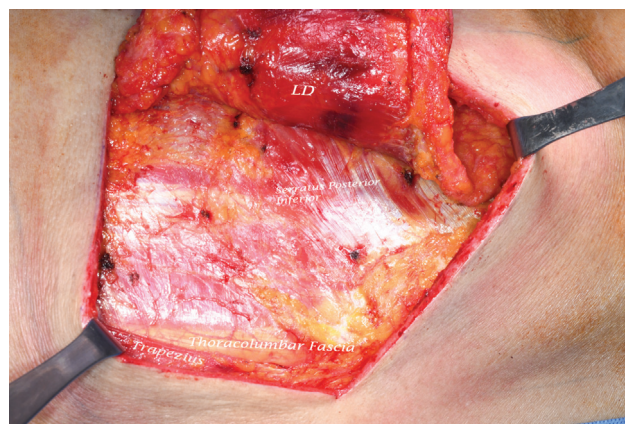


**Fig. 5** The Danger zone 3. In caudal portion of latissimus dorsi, the latissimus dorsi muscle was connected to external oblique abdominis and serratus posterior inferior muscle. The white circle showed conjoined area between latissimus dorsi and external oblique abdominis muscle. This point should be dissected from the bottom to the outside, called the “bottom-up” technique. EO, external oblique; LD, latissimus dorsi.

**Anatomical Study**

We used nine embalmed specimens from the Department of Anatomy at our hospital. Considering the variation of cadaver specifications, we determined the positional relationship of the LD and its adjacent muscles as the basis of operation. The positional relationship was relative to the rib which was the attachment site of the LD and its adjacent muscles. We used an axillary approach to the inferior glenohumeral capsule and the tendon of the LD. The surrounding muscles and capsules were not initially resected. The belly of the biceps brachii, the deltoid, and the pectoralis major muscles were reflected laterally to confirm the insertion of the LD.

In the prone position, the skin and subcutaneous tissues of the back were carefully resected. The LD, the trapezius muscles, and their borders were identified. The length of the anterior border of the LD (AL) from the iliac crest to its insertion was measured and used as the reference. From the



**Fig. 6** The trapezius, thoracolumbar fascia, and serratus posterior inferior were preserved intact and completely well separated from the LD muscle. LD, latissimus dorsi.

anterior border of the LD, the muscular part of the LD was separated from the underlying tissues and muscles using the “bottom-up” technique. During this process, the merging point of the LD with the SAM and the EOM was checked, and their lengths from their insertion sites and the rib level of the EOM were measured.

To identify the overlapping point of the LD with the trapezius and the SPI muscles, the vertical length of the spinal origin of the LD from the lower point of LD to the upper point of LD along the vertebral column was defined as the reference (SL). The overlapping points of the LD with the trapezius and the SPI muscles were measured. The absolute point was presented by means of rib level, while the relative merging point was calculated as the ratio of the reference (SAM / LL × 100, EOM / LL × 100, trapezius / SL × 100, SPI / SL × 100).

**Results**

**Clinical Series**

We performed 37 LD flaps and harvested 41 extended LD musculocutaneous flaps. Immediate reconstruction was

performed in 77 patients who underwent breast reconstruction, while delayed reconstruction was performed in one. The mean patient age was 45.4 years (range, 24–84 years). The mean body mass index was 23.36 kg/m<sup>2</sup> (range, 17.62–39.12 kg/m<sup>2</sup>). The mean operation time was 260 minutes (range, 210–440 minutes). The mean follow-up period was 13.7 months (range, 6–30 months). The average number of days of hospitalization was 11.4 days (range, 3–30 days). The mean postoperative period was 9.3 days (2–30 days).

There were no abnormalities or injuries in the adjacent fascia and muscles due to flap harvest in any of the cases. Donor negative drains were removed when the drains contained only less than 30 cc over 2 consecutive days. The mean time from the surgical date to the removal of the drain at the donor site was 21.9 days (range, 7–50 days).

In the reconstructed breasts of four patients, there was partial necrosis of the skin island paddles. The necrotic skin healed after debridement and primary closure. In addition, there were no contour changes that could be attributed to skin paddle necrosis. A total of 15 patients experienced chronic seroma formation at the donor site; four underwent capsulectomy and reinsertion of the negative drain. Another patient underwent needle aspiration as an outpatient. Two patients complained of discomfort during shoulder abduction without limitation of movement and pain during extension of the back and during scapular movement. Otherwise, there were no complaints

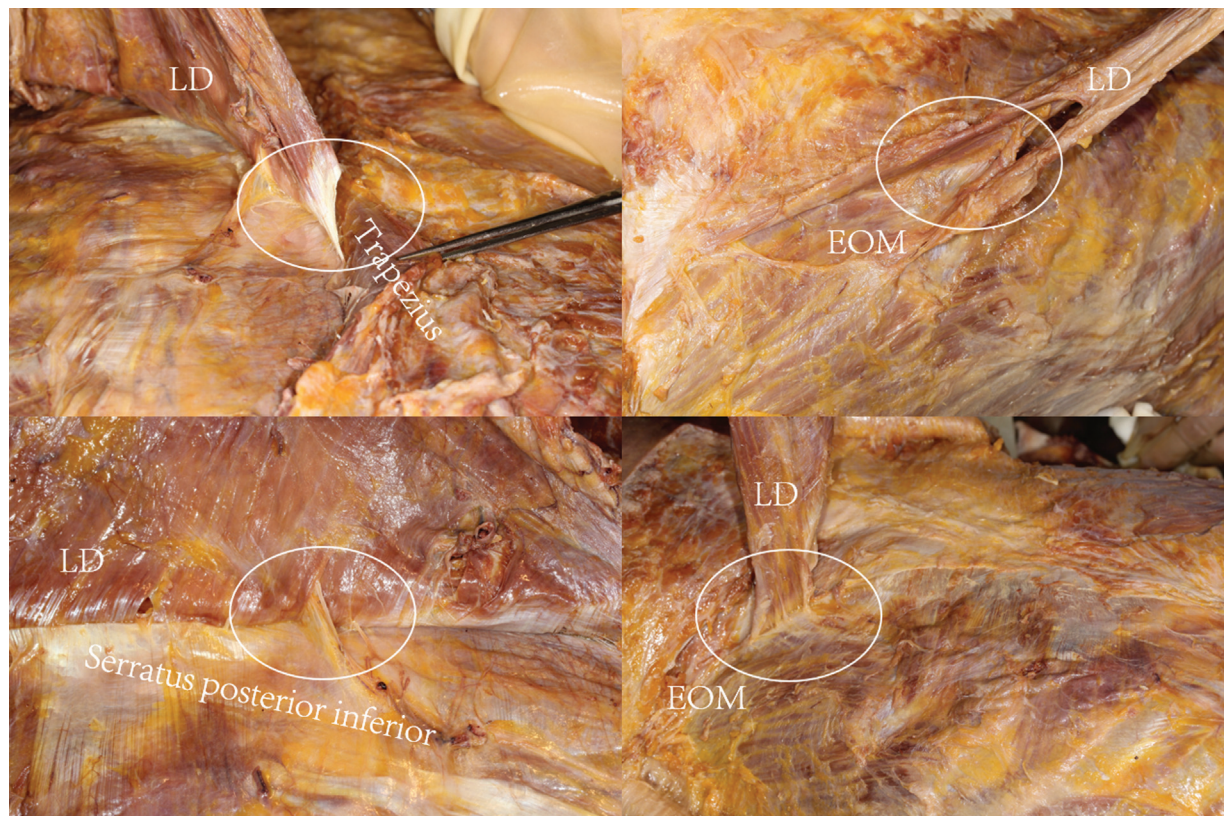of pain or tenderness at the donor sites of patients who were in the supine or lateral decubitus position during surgery.

### Anatomical Study

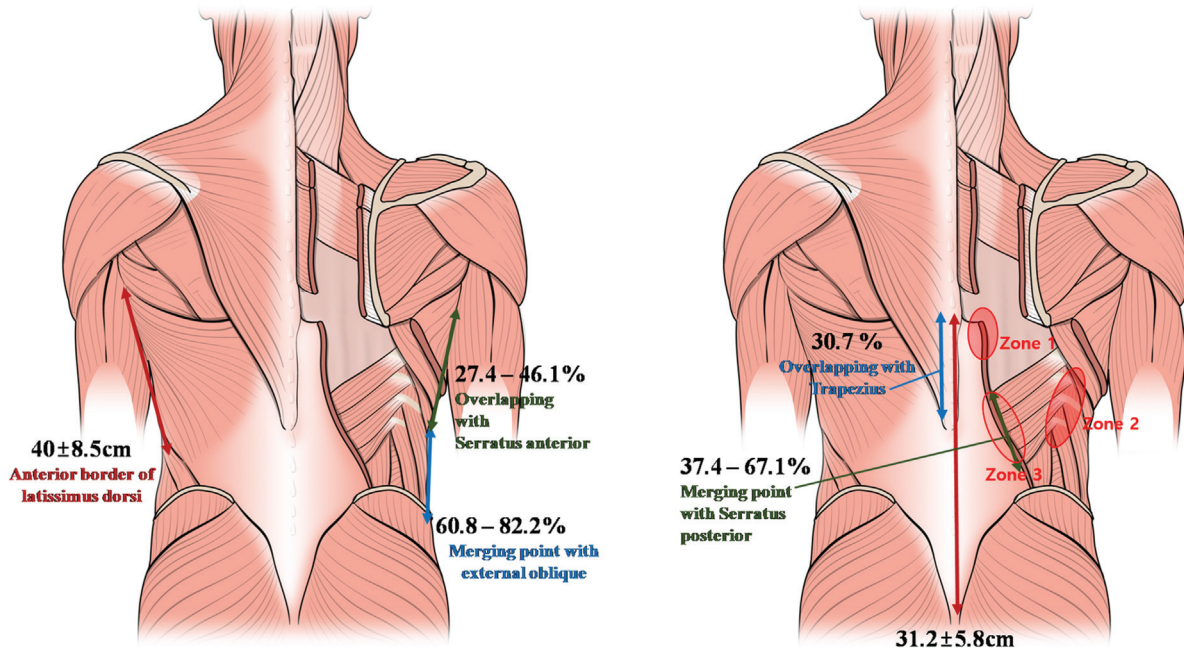
In nine cadavers, a topographical analysis of the LD and its association with the other muscles were examined. The margins of the LD, EOM, trapezius, and SPI were identified. In all cadavers, there was a conjoined fascia between the thoracolumbar and LD fasciae (►Fig. 3). The conjoined fascia was positively identified on the medial side of the LD. There was a merging point connecting the EOM, SPI, and LD in all cadavers, although the merging degree varied in each cadaver (►Fig. 7).

The mean length of the anterior border of LD was 40.5 ± 8.5 cm. The LD was merged with SAM and EOM at 27.4 to 46.1% and 60.8 to 82.2% of the reference line, respectively. The average level of the merging point between the LD and the EOM was 8.9 to 11.1 ribs (►Fig. 8).

The mean length of the spinal origin of the LD (SL) was 31.2 ± 5.8 cm. The trapezius and the SPI overlapped with the LD, with a 0 to 30.7% and 37.4 to 67.1% distance from the reference line, respectively. The average level of the overlapping point between the LD and SPI was 9.5 to 11.1 ribs (►Table 1). ►Table 2 shows the position of the merging points between the EOM, SPI, and LD muscles based on rib number in nine cadavers.



**Fig. 7** (Above, left) The danger zone 1. After trapezius was retracted, conjoined fascia was found on the medial side of the latissimus dorsi. (Above, right) The danger zone 2. The merging point between the external oblique abdominis and latissimus dorsi muscle (Below, left) The danger zone 3. The merging point between the serratus posterior and latissimus dorsi muscle (Below, right) The danger zone 3. The merging point between the external oblique abdominis and latissimus dorsi muscle in caudal portion. EOM, external oblique muscle; LD, latissimus dorsi.



**Fig. 8** The distance of the anterior border and spinal border of the latissimus dorsi and danger zones. Relative percentages based on the reference of merging, overlapping point with the latissimus dorsi muscle.

**Table 1** Mean length, percentage, and rib level in cadaver dissection

	Length (cm)	Percentage (%)	Rib level
Anterior border of the latissimus dorsi (AL)	40.5 ± 8.5	Reference	
Merging with the serratus anterior muscle (SAM)		27.4-46.1	
Merging with external oblique abdominis muscle (EOM)		60.8-82.2	8.9-11.1
Spinal origin of the latissimus dorsi (SL)	31.2 ± 5.8	Reference	
Trapezius overlapping (TO)		0-30.7	
Serratus posterior inferior overlapping (SO)		37.4-67.1	9.5-11.1

**Table 2** Rib level of merging points of the external oblique and serratus posterior inferior with the latissimus dorsi in cadaver dissections

	External oblique right	External oblique left	Serratus posterior inferior right	Serratus posterior inferior left
Cadaver 1	8-10	9-10	8-10	7-9
Cadaver 2	9-11		8-12	8-12
Cadaver 3	8-9		7-10	7-10
Cadaver 4		9-12	9-11	
Cadaver 5		9-11	7-12	8-12
Cadaver 6	10-12	9-12	10-12	10-11
Cadaver 7	9-11	9-11	9-11	9-11
Cadaver 8	9-12	9-12	8-11	8-11
Cadaver 9	9-11	9-11	11	10-12

## Discussion

The LD flap is a versatile flap with a wide range of applications in filling soft tissue defects. The reliable anatomy of its pedicle vessels and the large amount of tissue available account for its versatility.<sup>7</sup> Pedicled flaps are especially useful for and are preferred by surgeons who are new to flap reconstruction. The pedicle's vessels are long (mean, 8.5 cm; range, 6.5–12 cm) and large (mean, 3 mm; range, 2–4 mm).<sup>213058</sup> The abundant blood supply and the easily distinguishable flap components result in a relatively simple flap harvest and dissection. However, there are various flap designs and approach modalities.<sup>9</sup> Several studies suggested the utilization of an endoscopic-assisted harvesting technique to reduce donor site morbidity.<sup>10,11</sup> Furthermore, other studies suggested the employment of a robot-assisted harvesting technique which is a less-invasive approach.<sup>12,13</sup>

Although this is an easily accessible surgery for beginner surgeons, care should be taken in performing this procedure because it involves a relatively large muscle that is anatomically complex with many surrounding muscles. Our study showed the relationship between the LD and the fasciae through medical records of previous surgical operations and through cadaveric dissections. The LD originates from the spine and iliac crest through thin tendinous components and enters the bicipital groove of the humerus in a superolateral direction. The SAM originates from the first to ninth ribs and enters the medial border of the scapula in a superomedial direction. The EOM originates at the 5th to 12th ribs and enters the iliac crest from the pubis. The LD muscle fibers merge with the SAM and EOM vertically. In the spinal origin of the LD, the conjoined fascia consists of a thin tendinous component of the LD and the TLF (→Fig. 3). If this conjoined fascia is overlooked, important adjacent muscles and the underlying fascia could be damaged. For this reason, the authors designated this part as danger zone 1, overlapping with trapezius by about 30%, and conjoined with TLF. Therefore, if you do not use the in and out technique, that is, the “bottom up technique,” when separating the LD fascia, it may damage the TLF fascia.

The TLF, the girdling structure on the human back, encircles the paraspinal muscles of the lower back and the sacral regions. The TLF has numerous functions, including modulation of tension and stiffness; facilitation of the equilibrium of the lumbar spine; and the sacroiliac joints, posture, and load transfer and respiration among others. The TLF is a critical part of the myofascial girdle of the lower body. If it is injured, paraspinal muscle hernia, chronic back pain, and scoliosis due to postural instability could occur. If the degree of injury worsens, respiratory problems might arise.<sup>14</sup> Furthermore, TLF injury could result in postoperative and chronic back pain and fibrosis and adhesion, thereby causing a loss of independent motion and restriction of body movement. It ultimately results in alterations in connective tissue physiology.<sup>15</sup>

The SAM and the trapezius muscles are responsible for scapular movement and stability and are the main components of the shoulder joint. SAM or trapezius muscle injury could lead to chronic pain in the subscapular area or to a winging scapula. If this worsens, it could cause instability of the shoulder joint which could also affect the abduction and flexion of the arm.<sup>16</sup> The EOM and the internal oblique muscle are responsible for the lateral support of the trunk, rotatory movement, and appropriate compression of the abdominal cavity by pulling the chest downward. Injury of this muscle interferes with postural stability and ambulatory movements, such as walking or running.<sup>17</sup> Because each muscle has its own function, flap harvest using the atraumatic technique is required to reduce postoperative complaints, and complications.

On cadaver dissection, we measured the mean distance of the lateral border of the LD, relative percentage of the merging point based on the distance of the lateral border of the LD, mean distance of the spinal origin of the LD, and the relative percentage of the overlapping point based on the distance of the spinal origin of the LD. Using this reference, we predicted the merging and overlapping points (→Fig. 7). The merging point, that is, the most difficult point of dissection and the most dangerous point in terms of adjacent tissue injuries, was located at the rib's fixed point on the body. If the merging point on the EOM could be predicted, mistakes could be avoided. Effort should be made to find the anterior border of the LD around the merging point on the EOM because the EOM merging point is very complicated. Buncke<sup>18</sup> stated that a sharp elevation of the anterior border of the LD was necessary because it was intimately attached to the SAM. The authors designated this area as danger zone 2 which corresponds to the 8th to 11th ribs, and the LD overlaps the EOM by about 60 to 80% (→Fig. 4).

Della Rovere et al<sup>2130519</sup> showed that meticulous dissection was needed to prevent SPI damage when separating the TLF.<sup>2130519</sup> This description was similar to the meticulous dissection of the merging and overlapping points in our study results. The authors marked this part as danger zone 3 which corresponds to the 9th to the 11th ribs and overlaps LD and SPI by 37 to 67%. In particular, since this area is quite deep, if the operator's field of view is not sufficiently secured, the surrounding muscles may be injured (→Fig. 5).

We defined the principle of resecting from the deep to superficial structures to identify and separate each fascial layer and muscle fiber to minimize damage to adjacent tissues. This was called the “bottom-up” technique. Using this technique, reconstructed breasts showed no specific complications. During the flap harvest, the central part of the LD was separated from the underlying structures (thoracic wall and serratus posterior muscle) perfectly through the loose areolar tissue. Because the loose areolar tissue layer was an avascular plane, it could be dissected easily. Nevertheless, in the margin of the muscles, the LD closely adjoined the surrounding muscles and fascia, including the SAM, trapezius, EOM, and TLF. It was difficult to perform

atraumatic dissection without causing injury for beginner flap surgeons. We created this new effective method precisely to avoid injury to the adjacent tissues.

The “bottom-up” technique can be used to confirm the merging point such as the stair-step appearance containing the fibers of the LD that extended inferomedially to superolaterally, fibers of the SPI that extended inferolaterally to superomedially, and fibers of the EOM. The surgeon separated this merging point accurately. The “bottom-up” technique can also be used to resect the LD fascia without injuring the TLF or paraspinal muscles after division of the TLF and LD fascia completely at the spinal origin of the LD (► Fig. 6).

In addition, during flap harvest, there was good visualization of the critically adjoined area and the sequential series of procedure for reducing operation time. Several relevant studies lack the anatomical and technical details of the LD flap.

This study has several limitations. It was a retrospective study; therefore, we depended on electronic medical records and clinical images. We could not consider variables other than those described in the study. Finally, the operation time was recorded only from the start to finish of the operation; therefore, we were not able to analyze the harvest times.

In conclusion, using a “bottom-up” technique, it can be used to harvest the LD to avoid injury to the adjacent tissues with fewer complications. These technical tips can help flap surgeons to perform more meticulous and atraumatic operations.

#### Ethical Approval

The institutional review board at our hospital reviewed and approved this study (DSMC-2017-07-042).

#### Patient Consent

Required patient consents were received from the patients for this study.

#### Authors' Contributions

Study concept and design: S.D.G. Data acquisition: K.H.J., O.S.H. Cadaveric study: L.J.H.. Data analysis and interpretation: S.D.G., L.K.H. Drafting of the manuscript: O.S.H. Approval of final manuscript: all authors.

#### Funding

None.

#### Conflict of Interest

None declared.

#### Acknowledgment

The authors would like to acknowledge Dr. Xiao Yang for her medical illustration. The authors are also grateful to Prof. Won Kee Lee for his statistical analysis.

#### References

- Maxwell GP. Iginio Tansini and the origin of the latissimus dorsi musculocutaneous flap. *Plast Reconstr Surg* 1980;65(05):686–692
- Bang S, Yang E. Breast reconstruction using extended latissimus dorsi muscle flap. *J Korean Med Assoc* 2011;54:61–69
- Lee KT, Mun GH. A systematic review of functional donor-site morbidity after latissimus dorsi muscle transfer. *Plast Reconstr Surg* 2014;134(02):303–314
- Hammond DC. Latissimus dorsi flap breast reconstruction. *Clin Plast Surg* 2007;34(01):75–82, abstract vi–vii
- Abolhoda A, Wirth GA, Bui TD, Milliken JC. Harvest technique for pedicled transposition of latissimus dorsi muscle: an old trade revisited. *Eur J Cardiothorac Surg* 2008;33(05):928–930
- Chang DW, Youssef A, Cha S, Reece GP. Autologous breast reconstruction with the extended latissimus dorsi flap. *Plast Reconstr Surg* 2002;110(03):751–759, discussion 760–761
- Zhang YX, Messmer C, Pang FK, et al. A novel design of the multilobed latissimus dorsi myocutaneous flap to achieve primary donor-site closure in the reconstruction of large defects. *Plast Reconstr Surg* 2013;131(05):752e–758e
- Günter Germann MÖ Latissimus dorsi flap. In: Wei FC, ed. *Flap and Reconstructive Surgery*. Philadelphia, PA: Elsevier; 2009:284–290
- Scomaço I, Freitas R, Tolazzi A, et al. Breast reconstruction using latissimus dorsi muscle flap: a novel surgical technique with reduced scarring. *Rev Bras Cir Plást* 2001;26:655–658
- Karp NS, Bass LS, Kasabian AK, Eidelman Y, Hausman MR. Balloon assisted endoscopic harvest of the latissimus dorsi muscle. *Plast Reconstr Surg* 1997;100(05):1161–1167
- Lin CH, Wei FC, Levin LS, Chen MC. Donor-site morbidity comparison between endoscopically assisted and traditional harvest of free latissimus dorsi muscle flap. *Plast Reconstr Surg* 1999;104(04):1070–1077, quiz 1078
- Selber JC, Baumann DP, Holsinger FC. Robotic latissimus dorsi muscle harvest: a case series. *Plast Reconstr Surg* 2012;129(06):1305–1312
- Selber JC. Robotic latissimus dorsi muscle harvest. *Plast Reconstr Surg* 2011;128(02):88e–90e
- Willard FH, Vleeming A, Schuenke MD, Danneels L, Schleip R. The thoracolumbar fascia: anatomy, function and clinical considerations. *J Anat* 2012;221(06):507–536
- Langevin HM, Fox JR, Koptiuch C, et al. Reduced thoracolumbar fascia shear strain in human chronic low back pain. *BMC Musculoskelet Disord* 2011;12:203
- Martin RM, Fish DE. Scapular winging: anatomical review, diagnosis, and treatments. *Curr Rev Musculoskelet Med* 2008;1(01):1–11
- Blondeel N, Boeckx WD, Vanderstraeten GG, et al. The fate of the oblique abdominal muscles after free TRAM flap surgery. *Br J Plast Surg* 1997;50(05):315–321
- Buncke HJ. Microsurgical research—a personal experience. *Microsurgery* 1995;16(04):186–190
- della Rovere GQ, Benson JR, Nava M, eds. *Oncoplastic and Reconstructive Surgery of the Breast (Oncology Surgery)*. London, United Kingdom: Informa Healthcare; 2011