



# Use of Connectomes in Deep Brain Stimulation for the Treatment of Obsessive-Compulsive Disorder

## *Uso de conectomas na estimulação cerebral profunda para tratamento de transtorno obsessivo-compulsivo*

Isabella Amaral Oliveira<sup>1</sup> Maria Clara Rocha Elias Dib<sup>1</sup> Ledismar José da Silva<sup>1</sup>

<sup>1</sup> School of Medicine, Pontifícia Universidade Católica de Goiás, Goiânia, GO, Brazil

Address for correspondence Ledismar José da Silva, MSc, School of Medicine, Pontifícia Universidade Católica de Goiás (PUC-Goiás), Avenida Universitária, 1440, Setor Universitário, 74605-010, Goiânia, GO, Brazil (e-mail: ledismarsilva@gmail.com).

Arq Bras Neurocir 2023;42(4):e328–e336.

### Abstract

Obsessive-compulsive disorder (OCD) is a psychiatric disorder characterized by the performance of repetitive behaviors in response to an obsession, which currently ranks as the tenth cause of disability in the world. Patients who are refractory to conventional treatment are candidates for the neurosurgical treatment of deep brain stimulation (DBS). In this procedure, electrodes are implanted in specific anatomical brain targets. The present systematic literature review aimed to describe the main connectomes and associate them with their respective targets involved in DBS for the treatment of OCD, to understand the connectomes related to OCD and their contributions to DBS, and to describe the main targets used in DBS surgery for OCD. Based on the present results, the stimulated targets that showed better clinical outcomes were the anterior limb of the internal capsule, the nucleus accumbens, the subthalamic nucleus, and the ventral capsule/striatal capsule. The target associated with the worst clinical results was the posterior limb of the anterior commissure. The variable stimulation of certain regions of the brain determines different clinical results. However, an individualized investigation of the OCD patient is essential for choosing the best target for DBS.

### Keywords

- ▶ obsessive-compulsive disorder
- ▶ OCD
- ▶ deep brain stimulation
- ▶ DBS
- ▶ connectome

### Resumo

#### Palavras-chave

- ▶ transtorno obsessivo-compulsivo
- ▶ TOC
- ▶ estimulação cerebral profunda
- ▶ ECP
- ▶ conectoma

O transtorno obsessivo-compulsivo (TOC) é uma doença psiquiátrica caracterizada pela realização de comportamentos repetitivos em resposta a uma obsessão, que atualmente se enquadra como a décima causa de incapacidade do mundo. Pacientes refratários ao tratamento convencional são candidatos para o tratamento neurocirúrgico de estimulação cerebral profunda (ECP). Neste procedimento, eletrodos são implantados em alvos anatômicos específicos do cérebro. A presente revisão sistemática da literatura teve como objetivo descrever os principais conectomas e associá-los aos seus respectivos alvos envolvidos no ECP para o tratamento de TOC, compreender os conectomas relacionados ao TOC e suas contribuições para o ECP e descrever os

received  
May 24, 2022  
accepted  
June 21, 2022

DOI <https://doi.org/10.1055/s-0042-1756143>.  
ISSN 0103-5355.

© 2023, Sociedade Brasileira de Neurocirurgia. All rights reserved. This is an open access article published by Thieme under the terms of the Creative Commons Attribution-NonDerivative-NonCommercial-License, permitting copying and reproduction so long as the original work is given appropriate credit. Contents may not be used for commercial purposes, or adapted, remixed, transformed or built upon. (<https://creativecommons.org/licenses/by-nc-nd/4.0/>)  
Thieme Revinter Publicações Ltda., Rua do Matoso 170, Rio de Janeiro, RJ, CEP 20270-135, Brazil

principais alvos utilizados na cirurgia de ECP para TOC. Com base nos nossos resultados, os alvos estimulados que apresentaram melhores resultados clínicos foram o membro anterior da cápsula interna, o núcleo accumbens, o núcleo subtalâmico e cápsula ventral/cápsula estriatal. O alvo associado aos piores resultados clínicos foi o membro posterior da comissura anterior. A estimulação variável de determinadas regiões do cérebro determina resultados clínicos diferentes. No entanto, uma investigação individualizada do paciente com TOC é essencial para a escolha do melhor alvo para ECP.

## Introduction

Obsessive-compulsive disorder (OCD) is a chronic neuropsychiatric condition characterized by performing repetitive behaviors in response to an obsession or obeying rules that have to be applied thoroughly.<sup>1</sup> Obsessions are mental events such as thoughts, ideas, and images that generate discomfort. Compulsions are repetitive behaviors or mental acts that occur to reduce the discomfort and anxiety caused by obsessions or a ritual to prevent some feared event or situation.<sup>2</sup> These rituals are not manias and cause suffering and damage, mainly because they consume the time of the individuals.<sup>3</sup> According to the World Health Organization (WHO), OCD is currently the tenth cause of disability in the world.<sup>3</sup>

Among the most prevalent obsessions of OCD are afflictions with dirt or contamination, somatic obsessions, aggressive obsessions, and self-extinction. The most common compulsions are: frequently washing objects and hands, likely causing dermatitis; counting; obeying symmetry such as the position of books, clothes on a clothesline, among others; collecting and not getting rid of mostly unnecessary objects; and several other rituals such as remembering, touching, and praying.<sup>3</sup>

The psychological changes of OCD are experienced as obsessions and/or compulsions responsible for mental discomfort such as anxiety. The disorder can affect the social (isolation), affective (family overload), and professional areas (unemployment), and this may lead to financial dependence and personal dissatisfaction. In addition, a significant evolution to depression throughout life in patients with OCD has been reported. Another aggravating factor is that, most often, patients make the disorder a secret due to denial of the disease, because of shame or fear of judgment, making the diagnosis and treatment more difficult. This disorder has significant epidemiological data associated with depression, suicide, and anxiety.<sup>3</sup>

From the pathophysiological perspective, OCD occurs due to the abnormal functioning of anatomical structures in the brain, causing deficits in the neurocircuits and neurotransmitters. Neuroimaging of patients with OCD detects hyperactivity of the orbitofrontal cortex (OFC), both in resting and active states. Thus, the corticostriatalthalamocortical neurocircuitry is a good parameter to identify the pathophysiological cause of OCD.<sup>3</sup>

Based on the baseline model of OCD, the basal ganglia would not select cortical impulses, affecting the thalamic activity. Consequently, the excitatory impulses from the thalamus would reach the OFC, intensifying certain cravings that would be considered irrelevant in the absence of OCD.<sup>4</sup> The individualized assessment of symptoms, the degree of perception by the patient, and the extent of comorbidity are equally important, since OCD is quite heterogeneous and each type of neurobiological alteration has its specific brain circuits.<sup>5</sup>

The diagnostic criteria for OCD, in general, are: presence of obsessions, compulsions, or both; the obsessions or compulsions take time or cause relevant suffering or damage to social development, professional performance, or in other areas; the obsessive-compulsive symptoms are not physiological effects of a substance or other medical condition and the agitation is not best understood by symptoms of another mental disorder.<sup>1</sup> The differential diagnosis should be made by means of a general psychiatric evaluation to distinguish OCD from other psychiatric conditions or the absence of them. Intrusive thoughts and repetitive behaviors that are time-consuming (> 1 hour per day), and that generate substantial distress or functional impairment are characteristic of OCD.<sup>5</sup>

Patients with refractory OCD, who remain severely impaired despite having been exposed to first- and second-line therapies, are candidates for the neurosurgery approach, a procedure that changes the activity of the neural networks involved in the illness. It is important to note that presenting with severe symptoms is a necessary requirement, but not sufficient to undergo this type of neurosurgery. The severity of OCD is usually scored using the Yale-Brown Obsessive Compulsive Scale (Y-BOCS), a 40-item scale encompassing 20 questions for obsessions and 20 for compulsions that patients should answer. High Y-BOCS scores reveal more severe OCD symptoms.<sup>6</sup>

It is known that 20 to 30% of OCD patients are refractory to drug or cognitive behavioral therapies. Given this reality, a possible treatment of choice is deep brain stimulation (DBS).<sup>5</sup> It consists of reversible stimulation for the treatment of resistant neurological disorders by delivering electrical currents to the brain using electrodes connected to implanted pulse generators. These electrodes are permanently applied to specific anatomical targets.<sup>7</sup> The stimulation is defined with focal, adjustable, and reversible neuromodulation.<sup>8</sup> The

electric field generated by DBS is three-dimensionally sent throughout the brain. The neurons directly affected by the stimulation influence the activity of the network, and the response of the network depends on the types of neurons affected and their interconnections.<sup>7</sup> In general, the effects are mild, transient, and reversible after shaping the stimulation properties. An efficient programming of the electric current that shapes the magnetic field of DBS aims to ensure a better prognosis.<sup>8</sup>

This surgical procedure has been used for ~ 30 years to regulate defective brain networks caused by various diseases such as Parkinson disease and essential tremor.<sup>9</sup> In 2009, the United States Food and Drug Administration, the American federal government agency that regulates food, drugs, cosmetics, and medical products, approved DBS as a treatment for severe OCD.<sup>10</sup>

A 60% response rate has been reported in patients submitted to this neurosurgery. From a prognostic perspective, the anterior limb of the internal capsule (ALIC), the nucleus accumbens (NAcc), and the cingulum are targets that show good postoperative responses. Studies of neuroimaging and anatomical connectivity of OCD patients have pointed to alterations in the frontostriatohalamocortical network. This anatomical connectivity can be determined by diffusion-weighted imaging, acquired by magnetic resonance imaging (MRI), and followed by tractography reconstructions to provide the trajectory and density of the white matter of the brain. Additionally, functional connectivity, via functional MRI, has also been used to guide the implantation of electrodes in DBS.<sup>11</sup>

Given that OCD is a very heterogeneous psychiatric disorder that involves a dysfunction of the whole brain network, there is not a single universal target for its modulation in DBS. The importance of identifying these patient-specific connectivity profiles suggests the feasibility of a personalized DBS.<sup>12</sup> Hence, functional imaging supports the analysis of these correlations with the detection of several directly stimulated fibers and their corresponding cortical or subcortical regions modified by DBS. Furthermore, diffusion tensor imaging tractography facilitates the detection of axonal trajectories around DBS electrodes.<sup>7</sup>

Therefore, the present systematic literature review aimed to describe the main connectomes and associate them with their respective targets involved in DBS for the treatment of OCD, understand the OCD-related connectomes and their contributions to DBS, and describe the main targets used in DBS surgery for OCD.

## Methods

The present systematic literature review was performed searching on the Public/Publisher MEDLINE (PubMed), Scientific Electronic Library Online (SciELO), Virtual Health Library (VHL), Cochrane Library, and Portal de Periódicos da Coordenação de Aperfeiçoamento de Pessoal de Nível Superior do Ministério da Educação (CAPES/MEC, in the Portuguese acronym) databases applying the protocol of Preferred Reporting Items for Systematic Reviews and

Meta-Analyses (PRISMA).<sup>13</sup> The following descriptors searched on the Descriptors of Health Sciences (DeCS) and associated with the Boolean operators AND and OR were employed: (*obsessive compulsive disorder* OR *OCD*) AND *connectome* AND (*deep brain stimulation* OR *DBS*). For article selection, five inclusion criteria were elected: 1. full-length original articles; 2. studies performed in humans; 3. studies that responded to the proposed objectives; 4. articles published in the past 10 years (2011 to 2021); and 5. articles in English, Portuguese, or Spanish. The exclusion criteria were: 1. review articles; 2. meta-analyses; and 3. duplicate articles.

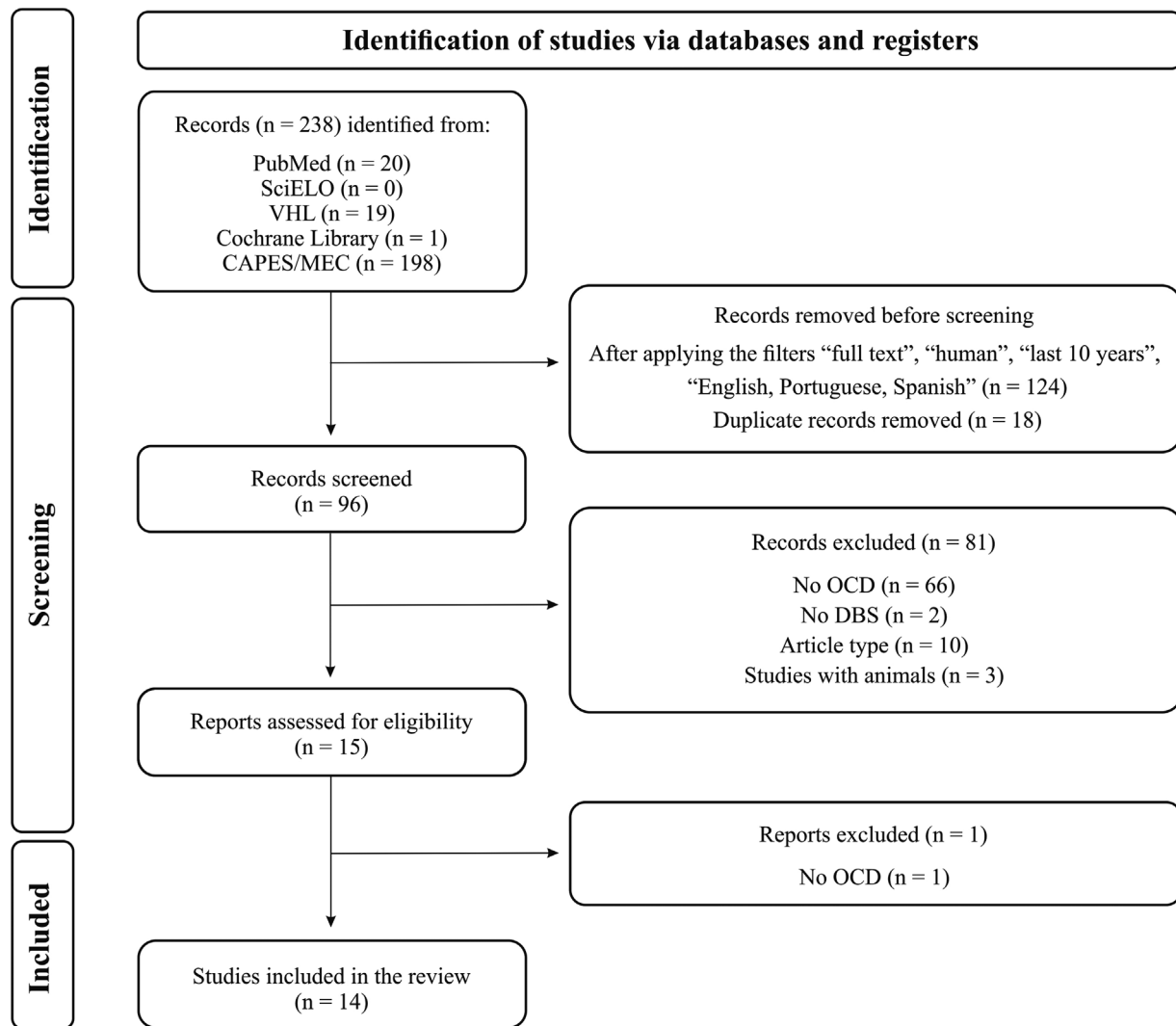
## Results

In total, 238 studies were found in the initial search. Before screening, 124 articles were excluded after applying the filters “full text,” “human,” “last 10 years,” and “English, Portuguese, Spanish,” whereas 18 were excluded because they were duplicates. Therefore, 96 records were selected for careful reading of the titles and abstracts, 81 of which were excluded for not meeting the inclusion criteria, and 15 were assessed for eligibility. Finally, after the exclusion of 1 more record, 14 articles were included in the qualitative analysis (► Fig. 1 and ► Table 1).

Several studies have already demonstrated that DBS is a promising procedure for the treatment of refractory OCD with the reduction of symptoms.<sup>18</sup> Based on the analysis of the selected articles, the main targets used in DBS for the treatment of OCD were the ALIC, the subthalamic nucleus (STN), and the NAcc.

In a retrospective cohort with a sample of 50 patients who underwent stimulation of different targets to control OCD, namely ALIC, STN, NAcc, and ALIC-STN, similar results were found for all of them. The best clinical result, however, was observed with the stimulation of the hyperdirect pathway, which was connected from the dorsal anterior cingulate cortex (ACC) to the STN. Conversely, the posterior limb of the anterior commissure showed the worst clinical results. Although different targets were used, they all converged to the same fiber bundle, called the ventral tegmental area projection pathway, with modulation of both ALIC and STN. This tract interacts with multiple brain areas, resulting in clinical improvement of OCD symptoms over time.<sup>23</sup> Another study including this same cohort of patients showed that different targets share the same network, that is, although the targets of choice were ALIC, STN, NAcc, or STN-ALIC, they connected to common brain areas, including the insula, the superior frontal gyrus, the ACC, and the anterior thalamus.<sup>24</sup>

In a study conducted in Germany, 22 patients, all with severe OCD refractory to treatment according to Y-BOCS, underwent DBS in the ALIC/NAcc. These targets were chosen from a normative and patient-specific connectome. A fiber bundle was evidenced within the ventral ALIC, which crosses the ventral striatum (VS), next to the stria terminalis bed, which connects the medial prefrontal cortex (PFC) to the thalamus. In a volume of activated tissue, this bundle of fibers reached apical and posterior white matter areas of the NAcc, leading to a significant improvement in the clinical



**Fig. 1** Flow diagram showing the study design following to the protocol of Preferred Reporting Items for Systematic Reviews and Meta-Analyses (PRISMA).<sup>13</sup> CAPES/MEC, Portal de Periódicos da Coordenação de Aperfeiçoamento de Pessoal de Nível Superior do Ministério da Educação; DBS, deep brain stimulation; OCD, obsessive-compulsive disorder; PubMed, Public/Publisher MEDLINE; SciELO, Scientific Electronic Library Online; VHL, Virtual Health Library.

symptoms analyzed, with the participation of both medial and lateral PFC in positive results. Nevertheless, the tract in flux to the medial prosencephalic bundle, to the posterior limb of the anterior commissure, and to the fibers within the inferior lateral fascicle were associated with negative results. After 1 year, an improvement in the symptoms associated with OCD was observed after DBS in the ALIC/NAcc with the insertion of electrodes in the frontostriothalamic pathway.<sup>19</sup> From a physiological point of view, another study also admitted abnormalities in the frontostriatal circuitry linked to OCD.<sup>17</sup>

In another retrospective cohort, including eight patients diagnosed with severe OCD based on the Diagnostic and Statistical Manual of Mental Disorders: Fifth Edition (DSM-5)<sup>1</sup> and a Y-BOCS score of at least 30/40, the ventral capsule (VC)/VS target was chosen. The inclusion criteria were persistence of symptoms for a minimum of 5 years, accompanied by intolerance to 2 selective serotonin reuptake inhibitors, clomipramine, antipsychotic medications, and

cognitive behavioral therapy. At the end of the study, 5 patients responded to surgery, with a mean drop of 16.6 in total Y-BOCS, whereas 3 patients continued nonresponsive; that is, a 63% response rate was achieved. In this sample that underwent stimulation in the VC/VS, it was observed that an ALIC subpart, which connects the PFC with the STN in front of the medial nucleus of the thalamus, is associated with a favorable clinical response to refractory OCD. The fibers unfavorable to a decrease in Y-BOCS were those in the posterior limb of the anterior commissure that connect with the bilateral temporal cortices and the cingulum fiber bundles.<sup>26</sup>

In a diffusion MRI analysis of 29 healthy patients, 29 human connectomes were constructed. Among these patients, the case of a 30-year-old individual with OCD symptoms since adolescence caught the attention of the researchers. Therefore, DBS surgery was proposed due to the fact that, previously, the patient had responded neither to medication such as clomipramine and serotonergic agents, nor to cognitive behavioral

**Table 1** Articles selected for the present systematic literature review

Study design	Sample	Target stimulated in DBS	Conclusions	Reference
Case studies	29 controls, 1 patient	VC/VS	The current surgical model is based on identifying identical stereotaxic coordinates for different patients in the VC/VS target. However, it has been observed that the individual connectome approach is crucial to improve the accuracy of DBS for the treatment of OCD	Makris et al. <sup>14</sup>
Clinical study	8 patients	NA	Using specific mapping of each patient's brain, the goal is to obtain brain network models for a personalized stimulation, improving the surgical intervention	Muldoon et al. <sup>15</sup>
Comparative study	842 controls	ALIC	Due to the high variability of the frontal structural connectivity of the ALIC, tractography and individual analysis of the connectomes of each patient corroborate a better neurosurgical direction	Nanda et al. <sup>16</sup>
Construction of a whole-brain rs-fMRI-based biomarker using a data-driven approach	108 patients	NA	Construction of a biomarker to better understand OCD	Takagi et al. <sup>17</sup>
Discussions about how to interpret results from the recent pivotal trials of DBS for OCD and depression, views on neuromodulation for psychiatric disorders, criteria for moving forward with new trials, the best way of confirming safety and efficacy of these therapies, and the next steps in the journey to new neuromodulatory therapies for OCD	NA	NA	DBS has shown promising results for several psychiatric disorders	Bari et al. <sup>18</sup>
Cohort	Total of 22 patients, 13 females	ALIC, NAcc	Stimulation pathways that are more closely connected to the frontothalamic pathway predict varying degrees of relief in clinical symptoms	Baldermann et al. <sup>19</sup>
Descriptive study	8 patients	sIMFB	HAMLET refines the surgical fiber of the sIMFB through deterministic tractography and therefore assists in accurate surgical planning	Coenen et al. <sup>20</sup>
Cohort	200 patients	NA	Regions targeted for OCD converge on subcortical portions of the reward network that is associated with OCD	Coenen et al. <sup>21</sup>
Precision functional mapping	NA	NA	The diverse clinical responses of DBS occur due to nonspecific stimulation of subparts of brain structures	Greene et al. <sup>22</sup>

Table 1 (Continued)

Study design	Sample	Target stimulated in DBS	Conclusions	Reference
Retrospective cohort	Total of 50 patients: <i>n</i> = 22, ALIC-DBS, in Colony, Germany; <i>n</i> = 14, STN-DBS, in Grenoble, France; <i>n</i> = 8, bilateral NAcc, in Madrid, Spain; <i>n</i> = 6, STN-ALIC, in London, United Kingdom	ALIC, STN, NAcc, STN-ALIC	Electrode activation of the STN and the ALIC enhances their connection with various parts of the brain. Modulation of the STN and the ALIC is linked to the same fiber bundle that responds to clinical improvements	Li et al. <sup>23</sup>
Retrospective cohort	Total of 50 patients: <i>n</i> = 22, ALIC-DBS, in Colony, Germany; <i>n</i> = 14, STN-DBS, in Grenoble, France; <i>n</i> = 8, bilateral NAcc, in Madrid, Spain; <i>n</i> = 6, STN-ALIC, in London, United Kingdom	ALIC, STN, NAcc, STN-ALIC	A group of functionally connected brain regions was identified; thus, regardless of the target region of choice, good results were obtained	Li et al. <sup>24</sup>
Randomized, double-blind, sham-controlled trial	9 patients	BNST/NAcc	BNST target stimulation showed better results compared with placebo	Mosley et al. <sup>25</sup>
Retrospective cohort	8 patients	VC/VS	VC/VS neuromodulation has shown good clinical results and is linked to the neuronal networks responsible for symptoms of OCD	van der Vliet et al. <sup>26</sup>
Prognostic study	8 patients	VC/VS	It has been held that the connection of the anterior cingulate cortex to the thalamus and the basal ganglia are part of the DBS response in the VC/VS target	Widge et al. <sup>27</sup>

Abbreviations: ALIC, anterior limb of the internal capsule; BNST, bed nucleus of the stria terminalis; DBS, deep brain stimulation; HAMLET, Hierarchical Harmonic Filters for Learning Tracts from Diffusion Magnetic Resonance Imaging; NA, not available; NAcc, nucleus accumbens; OCD, obsessive-compulsive disorder; rs-fMRI, resting-state functional magnetic resonance imaging; sIMFB, superolateral medial forebrain bundle; STN, subthalamic nucleus; VC/VS, ventral capsule/ventral striatum.



therapy. The surgery included bilateral VC/VS implantation and, after 6 months, following proper adjustments, a decrease by 35% in Y-BOCS was noted, as well as improvements in quality of life. It is known that DBS in this region establishes reciprocal excitation between the OFC and the thalamus, and consequently weakens abnormal activity within the OFC-caudate-pallidal-thalamic circuit. Therefore, the orbitofrontal-thalamic connections are important in the pathophysiology and clinic of OCD, since these fibers connect to several thalamic nuclei, primarily the dorsal medial, intralaminar midline, medial pulvinar, and anterior medial nuclei. Nonetheless, these fibers that cross the VC/VS region display high variability between individuals, so their most precise and individual localization determines a better post-surgical outcome.<sup>14</sup>

In a normative cohort encompassing 200 patients, with data collected from the Human Connectome Project (HCP), 4 networks associated with OCD were described, namely affect, reward, cognitive control, and default. Patients diagnosed with OCD exhibit cognitive inflexibilities related to the cognitive control network. Furthermore, the target regions in OCD have fibers confluent to the subcortical parts that belong to the reward network, since this interacts with the affect system in dynamic equilibrium. Another important point of the study was the analysis of eight projection points, all of which pass through the anterior branch of the internal capsule and reach the frontal cortex. In parallel, the reward and affect network tracts are also located in the ALIC, in a ventral/inferior position, while the cognitive control network tract is positioned more dorsally.<sup>21</sup>

The precision functional mapping of 10 individuals evidenced that regions of the subcortex are connected to multiple cortex networks. The subcortical structures have several functions, one of which is acting in the reward network. The most commonly affected subcortical fiber bundles among individuals may explain the different psychiatric disorders involved and are targets for improving subcortical interventions in DBS.<sup>22</sup>

In one analysis using diffusion imaging, a sample of eight patients presenting with OCD underwent DBS in the VC/VS region. The average improvement in Y-BOCS was 46.6%. The targets with positive responses were the cingulate and lateral OFC, whereas the ones that caused negative responses were the medial OFC and the ventrolateral PFC. The authors reaffirmed the relevance of the relationship between the circuits connecting the ACC to the thalamus and the basal ganglia to the response of electrode deployment in the VC/VS in DBS. Individual variability of fiber passage in the internal capsule was supported, ratifying that patient-specific imaging plays a crucial role in the accuracy of surgical target choice.<sup>27</sup>

In a randomized, double-blind, sham-controlled study conducted with nine Australian participants diagnosed with refractory OCD based on criteria defined by the DSM-5<sup>1</sup> and severity based on Y-BOCS and preoperative neuroimaging by structural MRI, the effects of DBS on the bed nucleus of the stria terminalis (BNST) was analyzed. Thus, from stimulation of this target, a 49.6% reduction in the Y-BOCS of the participants was noted.<sup>25</sup>

In a study with 842 HCP controls, portions of the ALIC were compared using diffusion tensor tractography to analyze structural patterns of frontal connectivity, in addition to the prefrontal-subcortical tracts. From these, 40 individuals in which the subdivisions of the ALIC diverged were randomly selected. However, there were sites of compatibility, mainly in the region connected to Brodmann's area 11 located in the OFC, which is a target widely used in DBS for OCD. Furthermore, the presence of a tract that crosses the ALIC and connects the prefrontal and subcortical regions was observed. The involvement of the ALIC in the pathophysiology of neuropsychiatric conditions is notorious, and dysfunctions in this portion produce cognitive and limbic feedback. Multiple diffusion imaging has evidenced that fractional anisotropy is abnormal in the ALIC of patients with OCD. Functional imaging studies have also shown that metabolic activity is increased in OCD patients at rest in nodes of the frontal subcortical circuits spanning the OFC, the PFC, and the thalamus.<sup>16</sup>

Aiming to identify connectome architecture more precisely, one study used a novel tract learning algorithm named Hierarchical Harmonic Filters for Learning Tracts from Diffusion Magnetic Resonance Imaging. This device tracks complex fiber bundles more finely than tractography. To better understand the region of the superolateral medial forebrain bundle in DBS for OCD and major depression, the technique was able to refine surgical planning discarding excess fibers, thus improving the accuracy of targeting in psychiatric disorders.<sup>20</sup>

Another study identified that variable stimulation of certain regions of the brain determines different clinical results. Thus, the specific regional stimulation of each individual can determine better prognoses.<sup>15</sup>

## Discussion

The main focus of the present study was to analyze the main targets used in DBS in individuals presenting with OCD. In accordance with this systematic literature review, the ALIC connected to its different subparts is a promising region to achieve clinical response in patients affected by this neuropsychiatric condition.<sup>19,26</sup> As already elucidated in previous studies, the corticostriatohalamic networks cross the ALIC and its abnormalities are, therefore, involved in the pathophysiology of OCD.<sup>28</sup> In contrast, the posterior limb of the anterior commissure, the medial prosencephalic bundle, and the fibers of the inferior lateral fascicle were the targets most related to unsatisfactory results in DBS for OCD.<sup>11,19,24,26</sup>

Regarding its pathophysiology, OCD is associated with the basal ganglia, the caudate nucleus and putamen, the STN, the globus pallidus, and the substantia nigra. Alterations in the frontocorticostriatohalamocortical circuitry are the main evidence of the behavioral aspects of OCD, already confirmed in other research.<sup>2,17,19</sup> The excitatory impulses from the thalamus would be activated, since the caudate nucleus would not be able to stop the cortical impulses correctly, reaching the OFC. Therefore, the OFC would present an excitatory overload, which would make it impossible for the patient with OCD to

defocus attention from insignificant concerns.<sup>2</sup> This circuit is essential for behavioral or cognitive responses inasmuch as it processes information in the cortex.<sup>29</sup>

In healthy individuals, the direct pathway is constituted by striatal activation, through the glutamatergic output of the OFC and ACC, consequently increasing the excitatory glutamatergic output of the thalamus to the frontal cortex. This pathway, in turn, is recontrolled by the indirect pathway, which does not happen satisfactorily in OCD patients. Consequently, the STN excites the globus pallidus interna and the substantia nigra reticulata, which inhibit the thalamus. Furthermore, when the STN receives projections from the cortex, it forms the hyperdirect pathway. With the hyperactivation of the orbitofrontal-subcortical pathway come excessive preoccupations with a threatening content, characterizing the obsessions and later the compulsions, compatible with the neutralization of the supposed threat.<sup>11</sup> As results have shown, the stimulation of this hyperdirect pathway has been promising in DBS for OCD.<sup>23</sup>

Patients with intractable OCD must meet the following eligibility criteria to be candidates for DBS: have OCD as the main diagnosis, have Y-BOCS  $\geq 28$  (or  $\geq 14$  if only obsessions or only compulsions are present), have made adequate use of at least 3 serotonin reuptake inhibitors (at least 1 with clomipramine), present with severe OCD symptoms even if they have already received psychomedical treatment for at least 5 years, have had at least 2 escalation strategies, present with refractoriness to treatment, have completed 20 hours of OCD-specific cognitive behavioral therapy, be between 18 and 75 years old, provide informed consent and awareness of surgical outcomes.<sup>5</sup>

From a neuroimaging perspective, HCP presented the architecture, organization, topography, and connectivity of the brain in MRI. Among its contributions to the scientific community, HCP has enhanced neuroimaging data, improving the understanding of various neuropsychiatric disorders.<sup>30</sup> The use of DBS for the treatment of both OCD and other brain disorders has benefited from these connectomic discoveries, since the high definition of specific networks provided by these neuroimaging and tractography data for each patient allows the refinement of surgical targeting and, as a consequence, a better therapeutic response.<sup>31</sup>

Searching for neurosurgical refinement, the individualization of DBS, possible because of the precision of neural networks among the various targets, enables the acquisition of a circuit that is more suitable for each patient according to their profile and symptom development. In parallel, the excitation of various portions of the involved tract excels over a fixed anatomical locus for a more favorable clinical response. Neuro-modulation procedures must also target underlying dysfunctional neural networks that cause other behavioral effects. Hence, consideration of individual characteristics is critical for the most accurate choice of the common neuronal network.<sup>11</sup>

## Conclusion

The main targets that provided the post-DBS clinical improvements found in the reviewed literature were the ALIC, the STN,

the NAcc, the VC/VS, and the BNST. In addition to the presurgical choice of a target, insight into the common neural network and the underlying networks to which the various targets of choice relate is critical. Consequently, the modulation of this common tract from the different DBS stimulation sites is able to reduce OCD symptoms.

Furthermore, the variability of both the symptoms and the anatomical portion of the structures involved among individuals with OCD, as verified by neuroimaging, results in different profiles of specific connectivity. Therefore, the connectomic science, along with the advances in neuroimaging, play a fundamental role in the understanding of the affected neuronal networks. Because of this, before performing DBS, it is fundamental to do an individualized analysis of the neural connections in the brain for a more precise procedure. Given the facts presented herein, the combination of normative and patient-specific connectomes can result in a more personalized, and therefore more effective, DBS procedure for the treatment of refractory OCD patients, less susceptible to readjustments and side effects.

## Conflict of Interests

The authors have no conflict of interests to declare.

## References

- 1 American Psychiatric Association. Diagnostic and statistical manual of mental disorders: fifth edition, DSM-5™. Washington, DC: American Psychiatric Association; 2013
- 2 Rosario-Campos MC, Mercadante MT. Transtorno obsessivo-compulsivo. *Rev Bras Psychiatr* 2000;22(Supl. II):16–19
- 3 Mariano JLP, Araújo DLM, Mendes Júnior FS, Corrêa IN, Santos LL, Gomes EC. Características gerais do transtorno obsessivo-compulsivo: artigo de revisão. *Rev Atenas Higeia* 2020;02(03):22–29
- 4 Mercadante MT, Rosario-Campos MC, Quarantini LC, Sato FP. [The neurobiological bases of obsessive-compulsive disorder and Tourette syndrome]. *J Pediatr (Rio J)* 2004;80(2, Suppl):S35–S44
- 5 Stein DJ, Costa DLC, Lochner C, et al. Obsessive-compulsive disorder. *Nat Rev Dis Primers* 2019;5(01):52
- 6 Hamani C, Pilitis J, Rughani AI, et al; American Society for Stereotactic and Functional Neurosurgery Congress of Neurological Surgeons CNS and American Association of Neurological Surgeons. Deep brain stimulation for obsessive-compulsive disorder: systematic review and evidence-based guideline sponsored by the American Society for Stereotactic and Functional Neurosurgery and the Congress of Neurological Surgeons (CNS) and endorsed by the CNS and American Association of Neurological Surgeons. *Neurosurgery* 2014;75(04):327–333, quiz 333
- 7 Lujan JL, Chaturvedi A, McIntyre CC. Tracking the mechanisms of deep brain stimulation for neuropsychiatric disorders. *Front Biosci* 2008;13(15):5892–5904
- 8 Greenberg BD, Rauch SL, Haber SN. Invasive circuitry-based neurotherapeutics: stereotactic ablation and deep brain stimulation for OCD. *Neuropsychopharmacology* 2010;35(01):317–336
- 9 Silva LJ, Naciff TH, Oliveira MFV. Deep brain stimulation as a treatment approach for anorexia nervosa: A systematic literature review. *Braz Neurosurg* 2019;38(03):175–182
- 10 Aum DJ, Tierney TS. Deep brain stimulation: foundations and future trends. *Front Biosci* 2018;23(01):162–182
- 11 Senova S, Clair AH, Palfi S, Yelnik J, Domenech P, Mallet L. Deep brain stimulation for refractory obsessive-compulsive disorder: towards an individualized approach. *Front Psychiatry* 2019; 10:905



- 12 Wong JK, Middlebrooks EH, Grewal SS, Almeida L, Hess CW, Okun MS. A comprehensive review of brain connectomics and imaging to improve deep brain stimulation outcomes. *Mov Disord* 2020; 35(05):741–751
- 13 Page MJ, McKenzie JE, Bossuyt PM, et al. The PRISMA 2020 statement: an updated guideline for reporting systematic reviews. *BMJ* 2021;372(71):n71
- 14 Makris N, Rathi Y, Mouradian P, et al. Variability and anatomical specificity of the orbitofrontothalamic fibers of passage in the ventral capsule/ventral striatum (VC/VS): precision care for patient-specific tractography-guided targeting of deep brain stimulation (DBS) in obsessive compulsive disorder (OCD). *Brain Imaging Behav* 2016;10(04):1054–1067
- 15 Muldoon SF, Pasqualetti F, Gu S, et al. Stimulation-based control of dynamic brain networks. *PLOS Comput Biol* 2016;12(09):e1005076
- 16 Nanda P, Banks GP, Pathak YJ, Sheth SA. Connectivity-based parcellation of the anterior limb of the internal capsule. *Hum Brain Mapp* 2017;38(12):6107–6117
- 17 Takagi Y, Sakai Y, Lisi G, et al. A neural marker of obsessive-compulsive disorder from whole-brain functional connectivity. *Sci Rep* 2017;7(01):7538
- 18 Bari AA, Mikell CB, Abosch A, et al. Charting the road forward in psychiatric neurosurgery: proceedings of the 2016 American Society for Stereotactic and Functional Neurosurgery workshop on neuromodulation for psychiatric disorders. *J Neurol Neurosurg Psychiatry* 2018;89(08):886–896
- 19 Baldermann JC, Melzer C, Zapf A, et al. Connectivity profile predictive of effective deep brain stimulation in obsessive-compulsive disorder. *Biol Psychiatry* 2019;85(09):735–743
- 20 Coenen VA, Schlaepfer TE, Reinacher PC, Mast H, Urbach H, Reisert M. Machine learning-aided personalized DTI tractographic planning for deep brain stimulation of the superolateral medial forebrain bundle using HAMLET. *Acta Neurochir (Wien)* 2019; 161(08):1559–1569
- 21 Coenen VA, Schlaepfer TE, Sajonz B, et al. Tractographic description of major subcortical projection pathways passing the anterior limb of the internal capsule. Corticopetal organization of networks relevant for psychiatric disorders. *Neuroimage Clin* 2020;25:102165
- 22 Greene DJ, Marek S, Gordon EM, et al. Integrative and network-specific connectivity of the basal ganglia and thalamus defined in individuals. *Neuron* 2020;105(04):742–758.e6
- 23 Li N, Baldermann JC, Kibleur A, et al. A unified connectomic target for deep brain stimulation in obsessive-compulsive disorder. *Nat Commun* 2020;11(01):3364
- 24 Li N, Hollunder B, Baldermann JC, et al. A unified functional network target for deep brain stimulation in obsessive-compulsive disorder. *Biol Psychiatry* 2021;90(10):701–713
- 25 Mosley PE, Windels F, Morris J, et al. A randomised, double-blind, sham-controlled trial of deep brain stimulation of the bed nucleus of the stria terminalis for treatment-resistant obsessive-compulsive disorder. *Transl Psychiatry* 2021;11(01):190
- 26 van der Vlis TAMB, Ackermans L, Mulders AEP, et al. Ventral capsule/ventral striatum stimulation in obsessive-compulsive disorder: toward a unified connectomic target for deep brain stimulation? *Neuromodulation* 2021;24(02):316–323
- 27 Widge AS, Zhang F, Gosai A, et al. Patient-specific connectomic models correlate with, but do not reliably predict, outcomes in deep brain stimulation for obsessive-compulsive disorder. *Neuropsychopharmacology* 2022;47(04):965–972
- 28 Zhang C, Kim SG, Li J, et al. Anterior limb of the internal capsule tractography: relationship with capsulotomy outcomes in obsessive-compulsive disorder. *J Neurol Neurosurg Psychiatry* 2021;92(06):637–644
- 29 Lacerda ALT, Dalgalarondo P, Camargo EE. Achados de neuroimagem no transtorno obsessivo-compulsivo. *Br J Psychiatry* 2001;23(suppl. 01):24–27
- 30 Glasser MF, Smith SM, Marcus DS, et al. The Human Connectome Project's neuroimaging approach. *Nat Neurosci* 2016;19(09): 1175–1187
- 31 Vieira EV, Arantes PR, Hamani C, et al. Neurocircuitry of deep brain stimulation for obsessive-compulsive disorder as revealed by tractography: a systematic review. *Front Psychiatry* 2021; 12:680484