



A Novel Balloon-Assisted Snaring Technique for Retrieval of Dislodged Port Catheter

S. Murthy Chennapragada^{1,2}

¹ Sydney Interventional Radiology Associates, SAN Clinic, Wahroonga, NSW, Australia

² Sydney Medical School, University of Sydney, NSW, Australia

J Clin Interv Radiol ISVIR 2023;7:131–132.

Address for correspondence S. Murthy Chennapragada, MBBS, DMRD, DNB, FRANZCR, Department of Medical Imaging, Children's Hospital at Westmead, Sydney, NSW 2153, Australia (e-mail: murthy.c@gmail.com).

Case Report

A 59-year-old female presented with a dysfunctional port. She also noticed that the subcutaneous segment of the port catheter on the chest wall was also impalpable. The patient denied any chest pain or palpitations. A chest radiograph (► **Fig. 1**) revealed the catheter separated from the chamber and migrated into the heart straddling the atrioventricular (AV) valve; the central tip extended into the right ventricle (RV), while its peripheral end was in the superior vena cava (SVC). On ultrasound examination, the catheter tip was just visible in the low right internal jugular vein (IJV) with thrombus surrounding the tip and extending to the vessel wall. Urgent percutaneous retrieval of the dislodged port catheter was planned. In the angiography suite using ultrasound guidance, right IJV and right common femoral venous (CFV) access were established. Initially capture of the peripheral tip of the catheter in the IJV was contemplated. However, the tip embedded in thrombus made it difficult for simple loop snare technique. Because of its location, other techniques were thought either challenging or to increase the risk of its dislodgement and embolization further into the RV and pulmonary artery (PA). Via the CFV access, a 14 mm × 40 mm Armada angioplasty balloon (Abbot Vascular, Santa Clara, CA) was introduced over a guidewire and advanced into the SVC alongside the port catheter taking care not to dislodge it. The balloon was gently inflated to “tack” the port catheter to the SVC wall and fix it (► **Fig. 2A**). Once its position was secured, a 6 to 10 mm trilobed snare device (EN Snare, Merit medical Systems) was introduced from the IJV access. The tip of the stabilized catheter was released free of the wall thrombus. It was then captured and extracted from the neck access, while simultaneously deflating the balloon in the SVC

(► **Fig. 2B**). Following this the port chamber was also removed from the chest wall. The patient made an uneventful recovery.

Discussion

Intravascular foreign bodies (IFBs) occur commonly because of complication of endovascular therapy or due to failure of endovascular devices. Detached and embolized venous lines are among the commonest IFBs; others include guidewires, coils, and stents.¹ Although in the majority instances these remain asymptomatic, it is recommended that the retained IFBs be removed to prevent serious adverse consequences.²

Several retrieval techniques with high technical success rates and low complication rates have been described to capture the IFBs.^{1,3,5} The optimum technique depends largely on the location and configuration of the IFB.¹ Typically, a snare is used to capture to the free tip of a dislodged port catheter often from its proximal end closest to the access.⁴ In our case, the peripheral (proximal) tip was noted to be surrounded by thrombus and hence not free. The farther (central) tip across the AV valve extended into the RV and hence was not easily accessible either. Alternative options included lateral grasp with a loop snare or using a forceps or using a pigtail catheter to loop around the midsegment of the catheter to withdraw into IVC followed by its retrieval.^{1,3,5} However, all these techniques required manipulation of these tools and the port catheter within the heart, with the risk of trauma, arrhythmias, and increased risk of further migration of the catheter itself during the manipulation.

Fixing the dislodged catheter in position to reduce the risk of its movement was achieved using an angioplasty balloon

article published online
September 12, 2022

DOI <https://doi.org/10.1055/s-0042-1755594>.
ISSN 2457-0214.

© 2022. Indian Society of Vascular and Interventional Radiology. All rights reserved.

This is an open access article published by Thieme under the terms of the Creative Commons Attribution-NonDerivative-NonCommercial-License, permitting copying and reproduction so long as the original work is given appropriate credit. Contents may not be used for commercial purposes, or adapted, remixed, transformed or built upon. (<https://creativecommons.org/licenses/by-nc-nd/4.0/>)

Thieme Medical and Scientific Publishers Pvt. Ltd., A-12, 2nd Floor, Sector 2, Noida-201301 UP, India

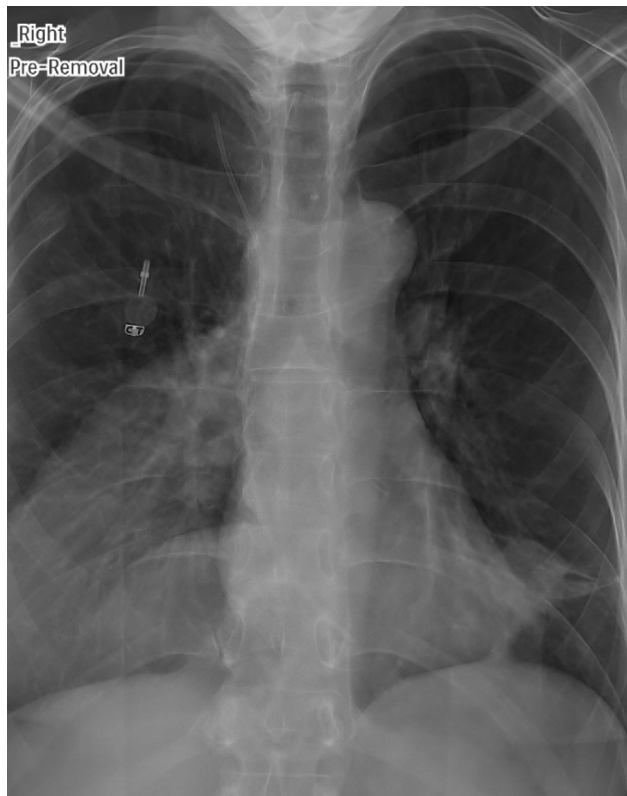

Fig. 1 Frontal chest radiograph depicts the chest wall port chamber with its catheter detached and dislodged, one end of which is seen in the SVC and the other projected over the proximal right ventricle.

inflated alongside the port catheter. This allowed for a trilobed snare to be introduced from the neck access to manipulate the proximal tip free of the thrombus and then to capture and retrieve it. Thus, the balloon minimized the risk of pushing the port catheter as well as the associated clot further into the RV/PA during the process.

The use of an angioplasty balloon has been described to assist in IFB retrieval, but this is usually in the context of the balloon inflated within the IFB (typically a migrated stent, sometimes a catheter) to capture it and retrieve it.^{1,3} In our case, we used the balloon outside the lumen of the IFB to stabilize it and to retain its position within the vessel. This

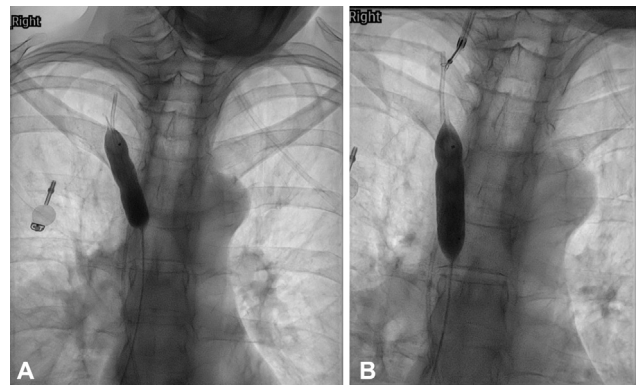


Fig. 2 (A) A balloon is inflated in the SVC to “fix” the position of the loose end of the dislodged catheter, (B) The free end of the “fixed” catheter is captured using a snare from jugular venous access.

facilitated the use of another retrieval device from a separate access to capture the IFB.

The technique can be particularly useful to minimize migration especially when additional manipulation of the IFB is anticipated during capture. We believe that this novel technique adds one more trick to the interventional radiology repertoire for successful IFB retrieval.

Conflict of Interest

None declared.

References

- 1 Woodhouse JB, Uberoi R. Techniques for intravascular foreign body retrieval. *Cardiovasc Intervent Radiol* 2013;36(04): 888–897
- 2 Fisher RG, Ferreyro R. Evaluation of current techniques for non-surgical removal of intravascular iatrogenic foreign bodies. *AJR Am J Roentgenol* 1978;130(03):541–548
- 3 Rossi UG, Rollandi GA, Ierardi AM, et al. Materials and techniques for percutaneous retrieval of intravascular foreign bodies. *J Vasc Access* 2019;20(01):87–94
- 4 Carroll MI, Ahanchi SS, Kim JH, Panneton JM. Endovascular foreign body retrieval. *J Vasc Surg* 2013;57(02):459–463
- 5 Mousa AY, Gill G, Aburahma AF. New trick for removal of intravascular retained foreign body: a case report and review of literature. *Vasc Endovascular Surg* 2014;48(01):55–57