

## Ovarian Cancer

# Evaluation of Outcomes of Mucinous Ovarian Cancer Treated at a Tertiary Care Cancer Hospital in Pakistan

Syed Abdul Mannan Hamdani<sup>1</sup> Musa Azhar<sup>1</sup> Abdul Wahab<sup>1</sup> Tahira Yasmeen<sup>1</sup> Neelam Siddiqui<sup>1</sup>

<sup>1</sup>Department of Medical Oncology, Shaukat Khanum Cancer Hospital, Lahore, Pakistan

**Address for correspondence** Syed Abdul Mannan Hamdani, MBBS, FCPS, Department of Medical Oncology, Shaukat Khanum Memorial Cancer Hospital and Research Centre, 7A, Khayaban-e-Firdousi, Block R3 Block R 3 M.A Johar Town, Lahore, Punjab (e-mail: mannanhamdani@skm.org.pk).

*South Asian J Cancer* 2023;12(1):81–86.

## Abstract



Syed Abdul Mannan Hamdani

**Objective** To evaluate the clinicopathological features and survival outcomes of mucinous ovarian cancer (MOC) patients in an Asian population.

**Study Design** Descriptive observational study.

**Place and Duration of Study** Shaukat Khanum Memorial Cancer Hospital, Lahore, Pakistan, from January 2001 to December 2016.

**Methods** Data of MOC were evaluated for demographics, tumor stage, clinical characteristics, tumor markers, treatment modalities, and outcomes from electronic Hospital Information System.

**Results** Nine-hundred patients with primary ovarian cancer were reviewed, out of which 94 patients (10.4%) had MOC. The median age was  $36 \pm 12.4$  years. The most common presentation was abdominal distension 51 (54.3%), while the rest presented with abdominal pain and irregular menstruation. Using FIGO (The International Federation of Gynecology and Obstetrics) staging, 72 (76.6%) had stage I, 3 (3.2%) stage II, stage III in 12 (12.8%), and 7 (7.4%) had stage IV disease. The majority of patients 75 (79.8%) had early-stage (stage I/II), while 19 (20.2%) presented with advanced-stage (III & IV). The median follow-up duration was 52 months (range 1–199 months). Among patients with early-stage (I&II), 3- and 5-year progression-free survival (PFS) was 95%, while for advanced stage (III&IV), PFS was 16% and 8%, respectively. The overall survival (OS) in early-stage I&II was 97%, while for advanced stages III & IV, the OS was 26%.

**Conclusion** MOC is a challenging and rare subtype of ovarian cancer requiring special attention and recognition. Most patients treated at our center presented with early stages and had excellent outcomes, while advanced-stage disease had dismal results.

## Keywords

- ▶ mucinous ovarian cancer
- ▶ rare subtype

DOI <https://doi.org/10.1055/s-0042-1755582> ISSN 2278-330X

**How to cite this article:** Hamdani SAM, Azhar M, Wahab A, et al. Evaluation of Outcomes of Mucinous Ovarian Cancer Treated at a Tertiary Care Cancer Hospital in Pakistan. *South Asian J Cancer* 2023;12(1):81–86.

© 2022. MedIntel Services Pvt Ltd. All rights reserved.

This is an open access article published by Thieme under the terms of the Creative Commons Attribution-NonDerivative-NonCommercial-License, permitting copying and reproduction so long as the original work is given appropriate credit. Contents may not be used for commercial purposes, or adapted, remixed, transformed or built upon. (<https://creativecommons.org/licenses/by-nc-nd/4.0/>)

Thieme Medical and Scientific Publishers Pvt. Ltd., A-12, 2nd Floor, Sector 2, Noida-201301 UP, India

## Introduction

Epithelial ovarian cancers (EOC) are the second-most common gynecologic malignancy. The main subtypes are serous, mucinous, endometrioid, and clear cell carcinomas. These types show significant differences in clinical, genetic, and molecular behaviors.<sup>1</sup> Mucinous ovarian cancer (MOC) is a rare subtype of malignant ovarian cancer. It accounts for 3 to 10% of all epithelial ovarian cancers.<sup>1-4</sup> MOC has a different natural history, biology, behavior, and molecular profile, with different chemotherapy responses compared with other histological subtypes.<sup>1,2,5,6</sup> It can primarily be of ovarian origin or metastatic from the gastrointestinal (GI) tract.<sup>7</sup> Previously, there was a dilemma in finding the exact pathology because of limited diagnostic techniques and knowledge about the disease. With recent advancements in pathology, gene expression profiling, identification of subtypes and various modalities available for exploring the GI tract, it has become possible to find the precise origin of mucinous tumors.<sup>8</sup> The unilaterality and increase in size indicates that it is of ovarian origin.<sup>1,5,7</sup> Diagnosis is often made in the early stages as it usually presents with huge abdominal masses. MOC is mostly diagnosed in patients at a younger age than patients with other types of epithelial ovarian cancers and the only clinical risk factor associated is tobacco smoking.<sup>1,9</sup>

Around 65 to 80% of MOCs are stage I or II, according to the FIGO staging system.<sup>1</sup> MOC treatment is the same as other histological subtypes, i.e., upfront debulking surgery where possible, followed by platinum-based chemotherapy when indicated.<sup>4,9</sup> Twenty-six percent of MOC are diagnosed in younger females who are less than 44 years of age, and fertility-sparing surgery (FSS) with curative intent is offered to eligible patients.<sup>10</sup> Early-stage disease carries a better prognosis than the advanced stage because of less chemotherapy sensitivity of MOC.<sup>8,11</sup> The median survivals of stage III and IV MOC disease are only up to 15 to 33 months compared with 50 months for advanced stage serous and endometrioid subtypes of EOC.<sup>2,11-13</sup> This study highlights the incidence, tumor characteristics, management, and outcomes of MOC treated at our institute. We hypothesized that our results would be different from western data, considering resource limitation with mainly non-availability of molecular profiling/targeted agents.

## Materials and Methods

Between January 2001 and December 2016, all patients who presented to Shaukat Khanum Memorial Cancer Hospital & Research Center (SKMCH&RC), Lahore, Pakistan, with Stage I to IV MOC were included in the study. Patient's data were extracted from the electronic hospital information system after getting approval from the Institutional Review Board (IRB). The need for patient-informed consent was waived off by IRB because of the retrospective nature of the study. All the patients had initial diagnostic surgery performed outside SKMCH&RC by gynecologists, upon confirmation of malignancy they were referred to our center. Here, the pathologies were reviewed by SKMCH&RC pathology laboratory, and

then they were accepted into our hospital. Mixed histologies were excluded. The majority of our patients underwent upper and lower GI endoscopies. All our patients were adequately staged. Computed tomography (CT) scans were used for radiological staging. All cases were discussed in multi-disciplinary team (MDT) meeting for treatment planning after the completion of diagnostic work up as per the hospital policy. Those patients who were planned for surgery in MDT, their surgeries were performed by a gynecology surgeon. Patients with stage IA had fertility sparing surgery in which unilateral salpingo-oophorectomy, pelvic washings, omentectomy, peritoneal biopsies, pelvic and para-aortic lymphadenectomy, and appendectomy if there was suspicion of appendix being involved were performed. While all others who underwent surgery had radical surgery performed as per the ovarian protocol. The most common chemotherapy regimen used was carboplatin/paclitaxel; however, in a few patients, capecitabine and oxaliplatin were also used. It was as per treating the oncologist's choice. Standard doses of chemotherapy were used. All patients were followed up by CT scans and tumor markers CA-125 and CEA. The demographics, age, tumor characteristics, tumor markers, details of interventions, and outcomes were recorded in the data analysis software.

## Statistical Analysis

Statistical Package of Social Sciences (SPSS) software (version 20.0; Chicago, IL, USA) was used for statistical analysis of the data. Mean  $\pm$  standard deviation was used for continuous variables, while frequencies and percentages were reported for categorical variables. Progression-free survival (PFS) was defined as the time between the date of diagnosis and the date of progression, death or last follow-up. The overall survival (OS) was the interval between diagnosis and death from any cause or last follow-up. The Kaplan-Meier method was used to estimate survival as a function of time, and survival differences were analyzed using the log-rank test.

## Results

Ninety-four patients with a histologically confirmed diagnosis of MOC were identified. There was no history of smoking in any of our patients. Patient and tumor characteristics are outlined in **Table 1**. The largest tumor size recorded was 40 cm. Most of the patients, 42 (44.7%), had right-sided tumors. The most common metastatic site seen was omentum in 10 (10.6%) patients. The majority of the patients, 51 (54.3%), presented with abdominal distension. Of most of our patients, 72 (76.6%) had stage I at diagnosis. Eighty-six patients (91.4%) had ECOG PS 0-1. Investigations and treatment modalities are outlined in **Table 2**. Diagnostic upper and lower GI endoscopies were done in 74 (78.7%) patients. FSS was done in 27 (28.7%) patients. The most commonly used first-line chemotherapy in our patients was carboplatin and paclitaxel. Neoadjuvant chemotherapy was given in 14 (14.9%), 40 (42.6%) had adjuvant chemotherapy, while 40

**Table 1** Patient and tumor characteristics

Characteristics	Values
Median duration of follow-up	52 months (1–199 months)
Median age at presentation (years)	36 years (15–69 years)
Mean serum CA-125 levels (IU/mL)	133 (2–2802)
Mean serum CEA (IU/mL)	21.69 (0–245)
Tumor size (cm)	16.57 ± 6.7
Tumor grade	
Well-differentiated	20 (21.3%)
Moderately differentiated	22 (23.4%)
Poorly differentiated	7 (7.4%)
Not> recorded	45 (47.9%)
Laterality	
Left	35 (37.2%)
Right	42 (44.7%)
Bilateral	12 (12.8%)
Not recorded	5 (5.3%)
Malignant ascites	
Yes	19 (20.2%)
No	75 (79.7%)
Metastatic site	
Omentum	10 (10.6%)
Liver	3 (3.2%)
Lung	3 (3.2%)
Colon	1 (1.1%)
Pleura	1 (1.1%)
No metastases	76 (80.9%)
Stages	
I	72 (76.6%)
II	3 (3.2%)
III	12 (12.8%)
IV	7 (7.4%)
Clinical presentation at diagnosis	
Abdominal distension	51 (54.3%)
Abdominal pain	20 (21.3%)
Abdominal pain/distension	20 (21.3%)
Irregular menstruation	3 (3.2%)

Abbreviation: CEA, carcinoembryonic antigen.

(42.6%) had no chemotherapy as the majority of patients had stage I disease (►Table 2).

Overall, in 74 (78.7%) patients, the disease was in remission, 9 (9.6%) had relapsed, and 11 (11.7%) had progressive disease. Out of 94 patients, 78 (83%) were alive, while 16 (17%) had died.

**Table 2** Investigations and treatment modalities used

Investigations and treatment modalities used	
Diagnostic endoscopy	
Yes	74 (78.7%)
No	20 (21.3%)
Debulking surgery	
Fertility-sparing surgery	27 (28.7%)
Radical cytoreductive	42 (44.7%)
Other surgery (diagnostic surgery not on the ovarian protocol)	25 (26.6%)

Among patients having stage I disease, 4 (5.6%) patients relapsed, in stage II no relapses were seen, while 10 (83.3%) patients had relapse or progression in stage III, 7 (100%) patients with stage IV had disease progression.

The 3- and 5-years PFS for early-stage (I&II) was 95%, while for advanced stage (III&IV), 3-year PFS was 16%, and 5-year PFS was 8%. The median PFS for early-stage (I&II) was 59 months while for advanced stage (III&IV) was 3 months. The 3- and 5-year OS for early-stage (I&II) was 97% and for advanced stages (III&IV) 26%. The median OS for early stage (I&II) was 59 months while for advanced stage (III&IV) was 16 months (►Table 3).

The 3- and 5-year PFS and OS in months and percentages for individual stages I, II, III, IV are shown in ►Table 4.

The survival graphs are shown in ►Fig. 1A–D.

The 5-year PFS and OS for patients undergoing FSS, radical completion surgery, and only suboptimal surgeries done for diagnostic purposes outside hospital is mentioned in ►Table 5.

## Discussion

Ovarian cancer is the fifth commonest cancer in Pakistani women.<sup>14</sup>

The mucinous histology is rare. In our study, in 16 years, only 94 cases of 900 EOC were found, comprising 10.4% of the total cases. As a result of this, conducting randomized controlled trials of sufficient statistical power and exploring potential therapeutic targets is difficult.

We previously reported a 13.4% frequency of MOC among 544 EOC patients from our center.<sup>15</sup> To the best of our knowledge, this is the first study of primary mucinous ovarian cancer as a separate entity, from Pakistan.

The exact incidence of MOC is controversial, as there is no reliable method to distinguish between primary MOC and mucinous adenocarcinoma metastatic to the ovary. The incidence ranges from 3 to 11.9% in different studies.<sup>1,11</sup> Different algorithms incorporating size, laterality, immunohistochemical markers, morphological characteristics such as expansile and infiltrative growth patterns, and inspection of digestive organs have been used to differentiate between primary and metastatic MOC of the ovary.<sup>7,11,16</sup>

**Table 3** Survival outcomes in early and advanced stage diseases

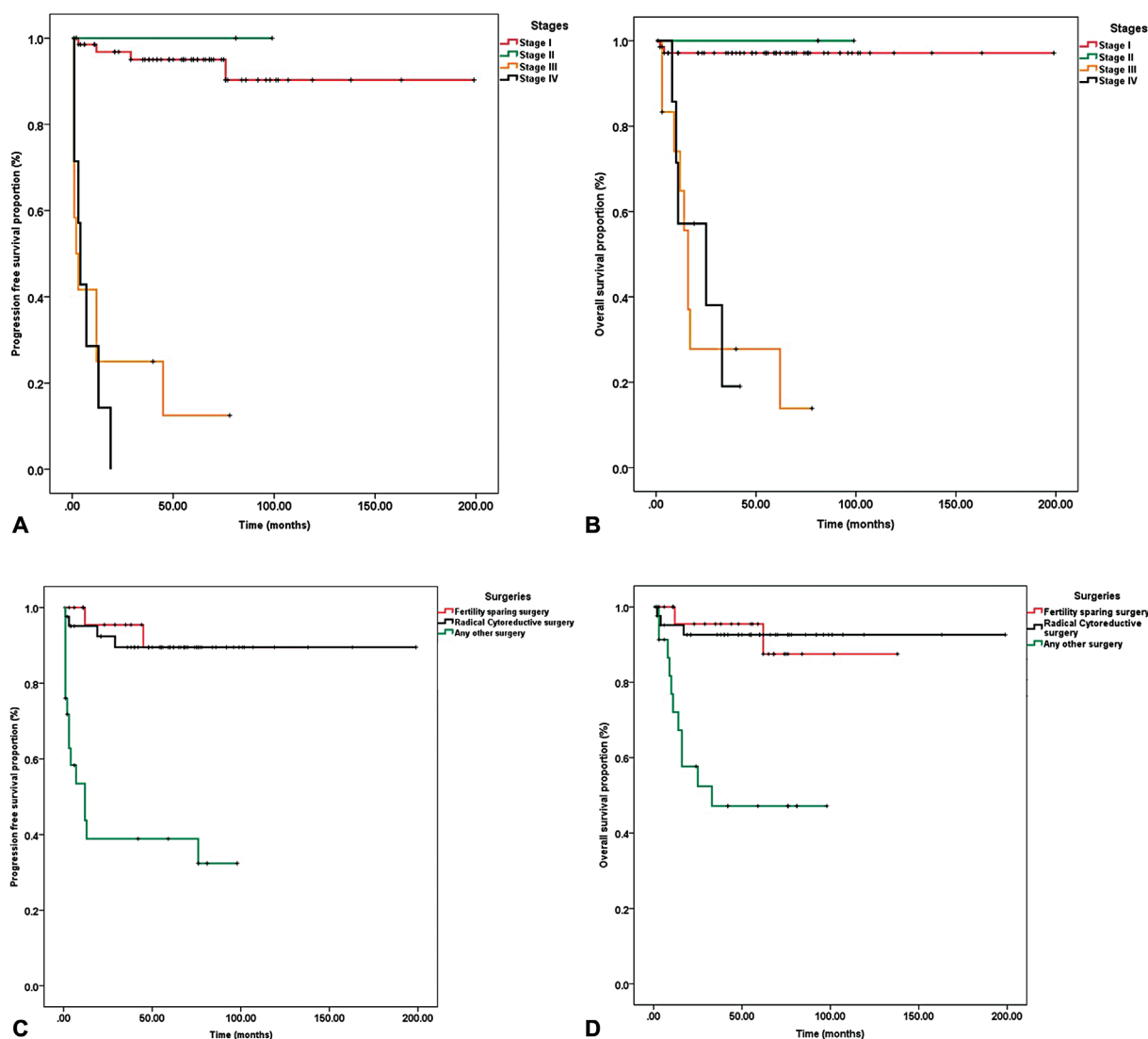
Stage group	3 years PFS (%)	5 years PFS (%)	3 years OS (%)	5 years OS (%)	PFS months	OS months
Early (I and II)	95	95	97	97	59	59
Advanced (III and IV)	16	8	26	26	3	16

Abbreviations: 3 years, 3 years; 5 years, 5 years; OS, overall survival; PFS, progression free survival.

**Table 4** Stage-wise survival outcomes

Stage	3 years PFS (%)	5 years PFS (%)	3 years OS (%)	5 years OS (%)	PFS months	OS months
Stage I	95	95	97	97	55 (1-199)	57 (1-199)
Stage II	100	100	100	100	81 (81-99)	81 (81-99)
Stage III	25	12	28	28	4 (1-78)	15 (3-78)
Stage IV	Could Not reach	Could Not reach	19	Could Not reach	3 (1-19)	19 (8-42)

Abbreviations: 3 years, 3 years; 5 years, 5 years; OS, overall survival; PFS, progression free survival.



**Fig. 1** (A) Stage-wise progression-free survival (PFS). (B) Stage-wise overall survival (OS). (C) Progression-free survival with regards to surgery. (D) Overall survival with regard to surgery.

The diagnosis of primary MOC requires careful pathological and diagnostic assessment. About 80% of the mucinous carcinomas of the ovary are metastatic from another site.

Hence comes the role of diagnostic upper and lower GI endoscopies. In an earlier study done at our center, 17.6% of patients who were initially suspected to have primary

**Table 5** Survival outcomes with regard to surgery performed

	PFS	OS %
FSS	89%	95
Radical cytoreductive surgery	89%	92
Only diagnostic surgery	39%	47

Abbreviations: FSS, fertility-sparing surgery; OS, overall survival; PFS, progression free survival.

MOC were diagnosed as having primary colonic carcinoma based on endoscopic findings.<sup>17</sup> Seventy-eight percent of patients in the current study underwent these procedures.

In our study, the mucinous adenocarcinoma was considered to have primary ovarian origin based on clinical history, examination, histological and immunohistochemical features along with thorough digestive tract evaluation.

Primary mucinous adenocarcinomas are most often diagnosed in the early stages because these are quite symptomatic owing to large sizes. Different studies have shown that up to 83% of these cases present in stage I or II.<sup>7,16</sup> Our study showed that 79.8% of women had early-stage MOC.

Cancer antigen CA125 (CA-125) is widely used as a tumor marker in epithelial ovarian cancer. In serous ovarian cancer, CA-125 is high in around 85% of cases; however, in MOC, it is reported to be elevated in only 12% of cases. The mean value reported for CA-125 in mucinous carcinoma stage I is 44.2 U/mL, while stage II-IV is 176.7 U/mL. In another study, the mean value of CA 125 was 240 for the stages included.<sup>2</sup> Our study's mean value of CA-125 was 133 U/mL, which is on the lower side, possibly because most of our patients had early-stage disease. In contrast, carcinoembryonic antigen (CEA), a marker of colorectal cancer, has been reported to be as high as 85% in MOC.<sup>18</sup> In our patients, 30% of the patients had high CEA although it was done only in 51 patients.

Because early-stage MOC is mostly found in younger women, fertility preservation is an area of great interest compared with other subtypes of EOC.<sup>19</sup> In a study by Lee et al, 38.9% of the patients underwent FSS.<sup>19</sup> Among our patients, 28.7% underwent FSS, while 44.7% had radical cytoreductive surgery. In one study, there were no compelling differences in 5-year survival rates, DFS (84% vs. 78%) or OS (84% vs. 82%) comparing FSS to standard surgical staging.<sup>20</sup> In our study, 5-year PFS of 89% and OS of 95% in patients who had undergone FSS were comparable to reports from Japan and Korea with 5-year DFS approaching 90% and OS of 97.3%.<sup>21</sup>

Although MOCs are less sensitive to chemotherapy compared with serous ovarian cancers, carboplatin and paclitaxel remain the standard first-line chemotherapy regimen for this disease.<sup>1,11,22</sup> There have been trials off late (ICON7, AURELIA, and GOG241) incorporating bevacizumab in advanced-stage and relapsed ovarian cancers, including those with mucinous pathology.<sup>1</sup> However, no conclusive evidence is available regarding the role of bevacizumab in MOC due to the rarity of this disease. None of our patients received bevacizumab until 2016 due to financial constraints, and carboplatin and paclitaxel remained the most used first-line chemotherapy.

Early-stage MOC is associated with excellent outcomes with 5-year survival rates approaching 90%, whereas the advanced stage disease is associated with inferior prognosis.<sup>23-25</sup> Data from seven prospective studies involving stage III-IV patients showed a median OS of 14.6 months.<sup>26</sup> The reason for a good prognosis in the early stages is the low propensity of nodal and peritoneal metastasis.<sup>7</sup> In contrast, poor prognosis in advanced-stage disease may be attributed to low chemotherapy sensitivity of this disease.<sup>1</sup> Our study showed a median OS of 57.5 months for stage I disease (range 1–199 months), while 81 months for stage II disease probably because of lesser number of patients with stage II disease, and second, all patients in stage II received chemotherapy. For stage III, the median OS was 15 months, and for stage IV disease, the median OS was 19 months. Pactasides et al found OS of 33.6 and 23.4 months, respectively, for stage III and IV disease. Morrice et al reported the median OS of 33 and 12 months for stage III and IV MOC, respectively.<sup>1</sup> For stage III and IV disease, PFS was 4 and 3 months, respectively, in our study. In a retrospective study, the PFS reported was 13 months for stage III and 6.9 months for stage IV.<sup>7</sup> In another study, the median PFS for stage III and IV MOC was 5.7 months.<sup>2</sup> These differences are not statistically significant. The 5-year OS reported for stages I&II combined are 86%, while for advanced stage III&IV are 28%.<sup>27</sup> Our study showed 5-year OS for early stage I&II of 97%, while for advanced stage III&IV the OS was 26%.

In recent years, molecular testing has enhanced the understanding of the biology of primary mucinous ovarian cancer, which may have an impact on the treatment and outcomes of MOC. The MOC is associated with defects in KRAS, BRAF, HER2, EGFR, ALK, MSI, PTEN, PI3KCA, and Src alterations.<sup>1,4,16</sup> These genetic alterations are shifting the paradigm of MOC toward targeted therapies. Unfortunately, the molecular testing was missing in our patients, probably because the study included the patients diagnosed until 2016 and second because of cost constraints.

There were some limitations of our study, including small sample size from a single institution and retrospective analysis. Twenty-six percent patients had diagnostic surgery done outside surgery, where there may lack proper surgical oncology skills. MOC was diagnosed on surgical specimens or referred blocks sent to our pathology laboratory, with incomplete information in some cases. In several cases, the exact size of the tumor and sometimes even laterality was not mentioned. Similarly, in several cases pathological grade and subtypes (expansile and infiltrative) were also not available.

On the contrary, this study has probably the largest patient number and previously no such research has taken place in Pakistan, which explicitly sees clinicopathological characteristics and outcomes of MOC.

## Conclusion

Mucinous ovarian cancer is a disease in constant evolution. Results of our study show that the OS is higher for patients presenting with early stage disease as compared with those

with non-mucinous histologic subtypes of ovarian cancer. However, for women with stage III/IV, mucinous ovarian cancer prognosis is poor with significantly lower survival rates. These results correspond with published western literature. Because of limited resources leading to lack of use of targeted therapy, these results seem encouraging and outcomes could have been better with availability of targeted therapy such as bevacizumab.

#### Funding

None.

#### Conflict of Interest

None declared.

#### References

- Morice P, Gouy S, Leary A. Mucinous ovarian carcinoma. *N Engl J Med* 2019;380(13):1256–1266
- Hess V, A'Hern R, Nasiri N, et al. Mucinous epithelial ovarian cancer: a separate entity requiring specific treatment. *J Clin Oncol* 2004;22(06):1040–1044
- Gorringer KL, Cheasley D, Wakefield MJ, et al. Therapeutic options for mucinous ovarian carcinoma. *Gynecol Oncol* 2020;156(03):552–560
- Xu W, Rush J, Rickett K, Coward JL. Mucinous ovarian cancer: a therapeutic review. *Crit Rev Oncol Hematol* 2016;102:26–36
- Brown J, Frumovitz M. Mucinous tumors of the ovary: current thoughts on diagnosis and management. *Curr Oncol Rep* 2014;16(06):389
- Ricci F, Affatato R, Carrassa L, Damia G. Recent insights into mucinous ovarian carcinoma. *Int J Mol Sci* 2018;19(06):1569
- Seidman JD, Kurman RJ, Ronnett BM. Primary and metastatic mucinous adenocarcinomas in the ovaries: incidence in routine practice with a new approach to improve intraoperative diagnosis. *Am J Surg Pathol* 2003;27(07):985–993
- Zaino RJ, Brady MF, Lele SM, Michael H, Greer B, Bookman MA. Advanced stage mucinous adenocarcinoma of the ovary is both rare and highly lethal: a Gynecologic Oncology Group study. *Cancer* 2011;117(03):554–562
- Bamias A, Psaltopoulou T, Sotiropoulou M, et al. Mucinous but not clear cell histology is associated with inferior survival in patients with advanced stage ovarian carcinoma treated with platinum-paclitaxel chemotherapy. *Cancer* 2010;116(06):1462–1468
- Peres LC, Cushing-Haugen KL, Köbel M, et al. Invasive epithelial ovarian cancer survival by histotype and disease stage. *J Natl Cancer Inst* 2019;111(01):60–68
- Schiavone MB, Herzog TJ, Lewin SN, et al. Natural history and outcome of mucinous carcinoma of the ovary. *Am J Obstet Gynecol* 2011;205(05):480.e1–480.e8
- Pectasides D, Fountzilias G, Aravantinos G, et al. Advanced stage mucinous epithelial ovarian cancer: the Hellenic Cooperative Oncology Group experience. *Gynecol Oncol* 2005;97(02):436–441
- Simons M, Ezendam N, Bulten J, Nagtegaal I, Massuger L. Survival of patients with mucinous ovarian carcinoma and ovarian metastases: a population-based cancer registry study. *Int J Gynecol Cancer* 2015;25(07):1208–1215
- Ahmad Z, Idrees R, Fatima S, et al. Commonest cancers in Pakistan-findings and histopathological perspective from a premier surgical pathology center in Pakistan. *Asian Pac J Cancer Prev* 2016;17(03):1061–1075
- Sarwar CM, Siddiqui N, Khokhar RA, Badar F. Epithelial ovarian cancer at a cancer hospital in a developing country. *Asian Pac J Cancer Prev* 2006;7(04):595–598
- Shimada M, Kigawa J, Ohishi Y, et al. Clinicopathological characteristics of mucinous adenocarcinoma of the ovary. *Gynecol Oncol* 2009;113(03):331–334
- Mehmood S, Khan MQ. Mucinous adenocarcinoma ovary: diagnostic dilemma and the usefulness of colonoscopy. *J Ayub Med Coll Abbottabad* 2015;27(02):280–283
- Choi JH, Sohn GS, Chay DB, Cho HB, Kim J-H. Preoperative serum levels of cancer antigen 125 and carcinoembryonic antigen ratio can improve differentiation between mucinous ovarian carcinoma and other epithelial ovarian carcinomas. *Obstet Gynecol Sci* 2018;61(03):344–351
- Lee JY, Jo YR, Kim TH, et al. Safety of fertility-sparing surgery in primary mucinous carcinoma of the ovary. *Cancer Res Treat* 2015;47(02):290–297
- Kajiyama H, Shibata K, Suzuki S, et al. Fertility-sparing surgery in young women with invasive epithelial ovarian cancer. *Eur J Surg Oncol* 2010;36(04):404–408(EJSO)
- Kajiyama H, Shibata K, Mizuno M, et al. Fertility-sparing surgery in young women with mucinous adenocarcinoma of the ovary. *Gynecol Oncol* 2011;122(02):334–338
- Perren TJ. Mucinous epithelial ovarian carcinoma. *Ann Oncol* 2016;27(Suppl 1):i53–i57
- Nasioudis D, Albright BB, Ko EM, et al. Advanced stage primary mucinous ovarian carcinoma. Where do we stand? *Arch Gynecol Obstet* 2020;301(04):1047–1054
- Crane EK, Brown J. Early stage mucinous ovarian cancer: a review. *Gynecol Oncol* 2018;149(03):598–604
- Mueller JJ, Lajer H, Mosgaard BJ, et al. International study of primary mucinous ovarian carcinomas managed at tertiary medical centers. *Int J Gynecol Cancer* 2018;28(05):915–924
- Mackay HJ, Brady MF, Oza AM, et al; Gynecologic Cancer Inter-Group. Prognostic relevance of uncommon ovarian histology in women with stage III/IV epithelial ovarian cancer. *Int J Gynecol Cancer* 2010;20(06):945–952
- Das G, Sridevi V, Natarajan M. A tertiary cancer center experience of 52 cases of primary ovarian mucinous adenocarcinomas. *South Asian J Cancer* 2020;9(02):90–92