



The Utility of the Marshmallow Barium Swallow Esophagogram for Investigation of Ineffective Esophageal Motility: A Systematic and Narrative Review

H. Wilson¹ V. Mocanu² C. Wong^{3,*} S. Karmali^{2,*}

¹ Faculty of Medicine and Dentistry, University of Alberta, Edmonton, Alberta, Canada

² Department of Surgery, University of Alberta, Edmonton, Alberta, Canada

³ Division of Gastroenterology, University of Alberta, Edmonton, Alberta, Canada

Address for correspondence H. Wilson, RD, Faculty of Medicine and Dentistry, University of Alberta, Edmonton, Alberta, T6G 2R7, Canada (e-mail: haw@ualberta.ca).

J Gastrointestinal Abdominal Radiol ISGAR 2023;6:1–7.

Abstract

Objectives Current gold standard investigations to determine the pathology of ineffective esophageal motility (IEM) are invasive and resource-intensive. Marshmallow barium swallow esophagogram (MBSE) is emerging as a more feasible modality; however, our understanding of its role in the clinical setting is limited. Our aim was to appraise the current literature and describe the effectiveness and limitations of MBSE as a potential diagnostic tool when investigating the pathological cause of IEM.

Methods A search in PubMed was conducted on May 23, 2021. Search terms included “marshmallow” AND “barium.” We included all studies which examined MBSE in the context of esophageal disease. The primary outcome of interest was to characterize the use of MBSE in current literature.

Results A total of 12 studies were retrieved after initial search with 9 studies meeting final inclusion criteria. A total of 375 patients were included, with 296 patients (79%) having a relevant diagnosis or symptom prompting investigation with MBSE. The most common diagnoses included referral to a gastroenterology clinic for a barium swallow (44%), post-Angelchik insertion (23%), and dysphagia (13%). Esophageal disease was identified in both the MBSE and other screening tests in 63% participants, whereas in 27% participants abnormalities were only seen using the MBSE.

Conclusion There is currently limited high-quality evidence on the use of MBSE to diagnose IEM. Further large-scale studies comparing its use in patients with different pathologic causes of IEM and of older age are required to further delineate the optimal delivery of this emerging diagnostic modality.

Keywords

- ▶ marshmallow
- ▶ barium swallow
- ▶ esophageal motility
- ▶ dysphagia

* Shared senior authors.

article published online
August 15, 2022

DOI <https://doi.org/10.1055/s-0042-1751256>.
ISSN 2581-9933.

© 2022. Indian Society of Gastrointestinal and Abdominal Radiology. All rights reserved.

This is an open access article published by Thieme under the terms of the Creative Commons Attribution-NonDerivative-NonCommercial-License, permitting copying and reproduction so long as the original work is given appropriate credit. Contents may not be used for commercial purposes, or adapted, remixed, transformed or built upon. (<https://creativecommons.org/licenses/by-nc-nd/4.0/>)

Thieme Medical and Scientific Publishers Pvt. Ltd., A-12, 2nd Floor, Sector 2, Noida-201301 UP, India

Introduction

Ineffective esophageal motility (IEM) comprises nearly half of all diagnosed esophageal motility disorders.¹ While a thorough history can often provide valuable guidance to the underlying pathophysiologic process, subsequent investigation using resource-intensive diagnostic modalities are often required.² Identifying abnormal esophageal motility and the presence of associated disorders can be untimely with diagnostic modalities currently available and often leads to delays in evaluation and management.³ For many patients with a history suggestive of IEM, the widely accepted strategy is formal esophageal motility probe testing, also known as manometry.^{4,5} While these tests remain the gold standard tools to investigate IEM-associated pathologies, they are invasive, time-consuming, and pose a burden on health care resources.^{6,7}

To address these current challenges, alternative diagnostic approaches which strive to more accurately risk-stratify patients have been proposed. Fundamentally, their aim is to potentially expedite tests for high-risk patients while avoiding unnecessary investigations in low-risk patients. The marshmallow barium swallow esophagogram (MBSE)—one such promising approach—is a modification of the standard liquid barium swallow (LBS). In the MBSE patients swallow a barium-labeled marshmallow instead of or in addition to liquid barium to aid in identifying areas of restriction or esophageal abnormalities radiographically.⁸ Emerging evidence suggests that the MBSE may offer an advantage over the LBS, as the viscoelastic marshmallow may increase the sensitivity of the LBS and involve additional swallowing mechanisms that elicit esophageal pathology.⁹ Further, the MBSE may be as sensitive as traditional manometry testing for identifying IEM while utilizing fewer resources and improving patient tolerance.^{9,10} These promising characteristics make the MBSE an ideal first test to investigate patients presenting with IEM to potentially rule out esophageal pathology. However, while promising, there is a paucity of high-quality evidence for its use, which has limited support for its clinical implementation.

The goal of the present review was to appraise the current literature and provide a narrative overview of the effectiveness and limitations of MBSE as a potential initial modality to investigate the pathological cause of IEM. An efficient, accurate, and low-cost screening test may allow for prompt diagnosis and initiation of treatment for patients suffering from these conditions.

Materials and Methods

Search Strategy

A search in PubMed was conducted on May 23, 2021 using the following search terms: “marshmallow” AND “barium.” No language or date limits were applied. A total of 12 results were retrieved and screened by initial title and abstract. No duplicate articles were present. Gray literature was assessed using a Google Scholar search with the same terms revealing no additional studies of interest.

Eligibility Criteria

The Population, Intervention, Comparison, Outcomes and Study design framework was used to frame the design of this systematic review. The population of interest was adult subjects with IEM. The intervention was use of MBSE, in which patients attempt to swallow a barium-labeled marshmallow and areas of restriction or esophageal abnormalities are identified radiographically.⁸ Our primary outcome of interest was to characterize the use of MBSE in current literature. Secondary outcomes were to see if we could compare outcome differences of the MBSE to currently employed diagnostic tests, and findings from the MBSE in common esophageal pathologies, including IEM. Due to the limited number of studies available based on our preliminary exploratory search, our only inclusion criteria was defined simply as original studies which examined MBSE in the context of esophageal disease. Only studies where full text could not be retrieved were excluded.

Ethical Approval

Due to the nature of this review, ethical approval was not required.

Data Extraction

Titles and abstracts were screened by one author (H.W.), and two authors (H.W. and V.M.) subsequently screened full-text articles. Discrepancies were resolved by consensus.

Pertinent data was collected from selected trials using an Excel spreadsheet by one reviewer (H.W.) and verified by a second reviewer (V.M.). Included studies were then assessed for methodological quality and bias using the methodological index for non-randomized studies (MINORS) tool for nonrandomized trials.¹¹

Data Synthesis

The findings are summarized narratively as included studies had significant limitations making any pooled estimate of the effect size of limited clinical value.

Results

Study Selection

Preliminary database search of the literature yielded 12 articles (→ Fig. 1). After initial screening of titles and abstracts, 10 studies underwent full-text assessment for eligibility. Nine manuscripts^{10,12–19} met inclusion criteria and were included in the final review. All nine studies were comparative trials, eight comparing MBSE to another diagnostic modality^{10,12,14–19} and five prospective cohort studies comparing the findings of MBSE in different patient populations.^{10,12–14,17}

Variations in MBSE Delivery

MBSE was defined as a swallow of liquid before and after the marshmallow in two studies,^{10,12} a swallow of liquid before or after the marshmallow in four studies,^{14,16,18} a marshmallow or viscoelastic bolus with the consistency of a marshmallow in two studies,^{15,17} and no definition provided

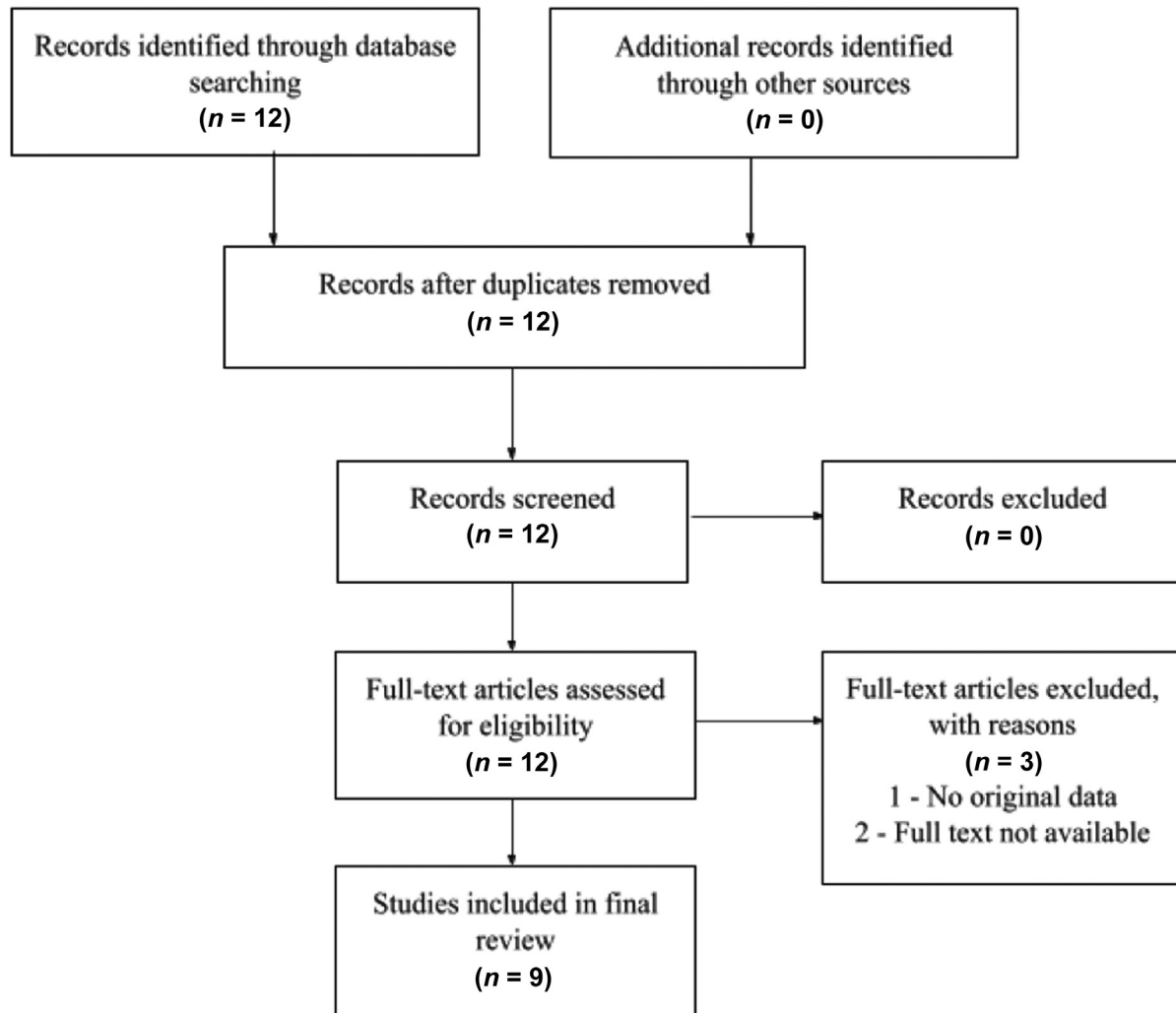


Fig. 1 Preferred Reporting Items for Systematic Reviews and Meta-Analyses (PRISMA) flow diagram for study search selection.

in two studies^{13,19} (► **Table 1**). Participants were allowed to chew the marshmallow in one study.¹⁴ The approximate diameter of the marshmallow used ranged from 10 to 20 mm.

Affected Patient Populations and Comparative Diagnostic Tests

Patient populations included patients referred to a gastroenterology clinic for a barium swallow, post-Angelchik insertion, complaint of dysphagia, eosinophilic esophagitis, post-fundoplication, presence of hiatal hernias, and hypertensive lower esophageal sphincter. Comparator diagnostic tests included LBS, solid barium swallow, endoscopy, manometry, and radionuclide solid esophageal emptying study.

Baseline Demographics of Study Population

A total of 375 patients were identified within the nine studies included (► **Table 1**). Of those, 296 patients (79%) had a relevant diagnosis or symptom prompting investigation with a MBSE while 79 patients (21%) were included in the control group. Evaluation of basic characteristics of all participants enrolled in these studies revealed a male predomi-

nance in the affected group ($n = 154$, 53%) and a female predominance in the control group ($n = 29$, 58%). Mean weighted ages were 47 (range 16–90) years for affected patients and 42 (range 22–72) years for control patients.

The proportion of each of the affected patient groups indicating an MBSE in the included studies is shown in ► **Fig. 2**. Affected patient groups included patients referred to a gastroenterology clinic for a barium swallow with cause not specified ($n = 130$, 44%; 1 study), post-Angelchik insertion ($n = 68$, 23%; 2 studies), complaint of dysphagia ($n = 37$, 13%; 1 study), eosinophilic esophagitis ($n = 34$, 11%; 2 studies), post-fundoplication ($n = 19$, 6%; 2 studies), presence of hiatal hernias ($n = 7$, 2%; 1 study), and hypertensive lower esophageal sphincter ($n = 1$, 0.3%; 1 study). Control groups included participants with no known esophageal reflux or disease ($n = 44$, 65%; 3 studies) and participants with non-cardiac chest pain ($n = 24$, 35%; 1 study).

Comparison of Abnormal Results on MBSE Compared with Another Screening Test

A total of eight^{10,12,14–19} studies compared MBSE to another screening test for evaluation of dysphagia and esophageal

Table 1 Baseline demographics of included studies

Study	Study design	Esophageal pathology	Patients (n)	Comparative group	MBSE delivery	Comparative diagnostic test	Study arms	Patients (n)	Age (y)	Female (%)	Proportion of abnormalities identified on MBSE (%)
Kahrilas et al 1998	Prospective cohort	Post-fundoplication OR symptomatic hiatal hernia	21	No known esophageal reflux or disease	Swallow of liquid barium pre and post 13 mm marshmallow	Liquid barium swallow and manometry	Pathologic	14	Fundoplication 41 Hiatal hernia 44	Fundoplication 31 Hiatal hernia -	Fundoplication 100 Hiatal hernia 0
Maxwell-Armstrong et al 1997	Prospective cohort	AngeliChik prosthesis in situ	43	Post-AngeliChik prosthesis removal ± fundoplication	-	-	Control Pathologic	7 32	38 53	- 44	100 -
Meshkinpour and Eckerling 1996	Prospective cohort	Dysphagia with no abnormalities on barium esophagram, esophagoscopy, or manometry	61	Noncardiac arrest chest pain	Swallow of water and 5 cm cubed marshmallow, allowed to chew	Liquid barium swallow	Pathologic Control	37 24	42 46	68 58	- -
Potter et al 2004	Prospective observational	Eosinophilic esophagitis	29	-	10 mm diameter marshmallow	Endoscopy	Pathologic PPI	29 25	35	28	67
Robertson et al 1989	Prospective cohort	AngeliChik prosthesis in situ	53	No known esophageal reflux or disease	Swallow of liquid barium pre and post half a standard marshmallow	Manometry	Pathologic Control	36 17	52 ^a 48 ^a	40 53	100 100
Smith et al 1998	Prospective observational	Referred to a gastroenterology clinic for a barium swallow	130	-	Half or a third of a standard marshmallow followed by liquid barium	Esophageal motility study and VFSS	Pathologic H2 blockers and/or PPI	130 43	50 42	48 23	62
Tatum et al 2000	Prospective cohort	Post-fundoplication	32	No known esophageal reflux or disease	5 mL quantity of a semisolid radio-opaque viscoelastic bolus	Liquid and solid barium swallows	Pathologic Control	12 20	46 35	- -	- -
Vasilopoulos et al 2002	Prospective observational	Eosinophilic esophagitis	5	-	Progressively increased portions of a standard marshmallow followed by liquid barium	Manometry, Bernstein test, and endoscopy	Pathologic PPI	5 620	Range of 15-30 years 64 ^a	0 34	50
Waterman et al 1989	Prospective observational	Hypertensive lower esophageal sphincter	1	-	-	Manometry, Bernstein test, and radionuclide solid esophageal emptying study	Pathologic H2 blockers	1 26	53 67	80 54	100

Abbreviations: MBSE, marshmallow barium swallow esophagogram; VFSS, video fluoroscopic swallow study.

^aIndicates medians, means reported if not otherwise indicated.

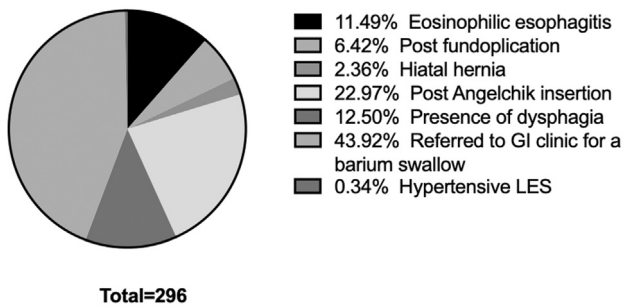


Fig. 2 Proportion of affected patient populations. GI, gastroenterology; LES, lower esophageal sphincter.

disease. Esophageal disease was identified in both the MBSE and correlated to comparator diagnostic tests in 61% of cases ($n=56$, 6 studies),^{10,12,15,16,18,19} whereas in 23% participants ($n=21$, 5 studies)^{10,12,16,18,19} abnormalities were only seen using the MBSE. Contrastingly, abnormalities were not seen on MBSE compared with endoscopy in 16% of participants ($n=14$, 2 studies)^{15,18} and in 1% of participants when compared with the LBS ($n=1$, 1 study), respectively.¹⁸

Abnormalities identified by both MBSE and manometry accounted for 48% of cases in which the esophageal abnormality was identified on both tests. These included patients post-fundoplication, patients post-Angelchik in situ, lower esophageal mucosal rings, and hypertensive lower esophageal sphincter ($n=27$, 4 studies).^{10,12,16,19} A total of 30% of cases seen on both tests were identified on MBSE and LBS. These pathologies included lower esophageal mucosal rings and small caliber eosinophilic esophagitis ($n=17$, 2 studies).^{16,18}

The remaining 21% of the esophageal pathology identified by both tests were found on both MBSE and endoscopy, which included the principle abnormality not specified in patients with eosinophilic esophagitis and small caliber esophagus ($n=12$, 2 studies).^{15,18}

MBSE was found to have identified additional esophageal pathology in cases where there was an impairment in marshmallow transit, either defined as a “hang up” or impaction of the marshmallow during swallowing, and the comparative test results were unremarkable. This included 15 cases of additional esophageal pathology compared with manometry (71%, 4 studies),^{10,12,16,18} 5 additional cases compared with LBS (24%, 2 studies),^{16,18} and 1 additional case compared with radionuclide solid esophageal emptying study (5%, 1 study).¹⁹ Pathologies not identified on manometry included primarily structural abnormalities, including patients post-fundoplication or post-Angelchik in situ, lower esophageal rings, and small caliber eosinophilic esophagitis. Lower esophageal rings and small caliber eosinophilic esophagitis were also not identified on LBS when an abnormality in the MBSE was found. The radionuclide solid esophageal emptying study did not identify the patient with a hypertensive lower esophageal sphincter, which was found on MBSE.

Esophageal abnormalities that were missed by MBSE were primarily subtle structural abnormalities. These included six

cases of small caliber esophagus, three proximal esophageal stenosis, and six corrugated ring-like formations, which were all identified on endoscopy (93%, 2 studies),^{15,18} other than one case of small caliber esophagus, which was identified on LBS (7%, 1 study).¹⁸

MBSE Results in Common Pathologies Causing IEM

In the five studies assessing this outcome, participants with esophageal pathology were more likely to have an abnormal MBSE result compared with the control participants.^{10,12–14,17} Of fundoplication patients, 57% of participants had a positive MBSE test ($n=4$, 1 study)¹² and significantly increased transit time compared with normal participants ($n=12$, 1 study).¹⁷ Participants with Angelchik prosthesis in situ also had significantly prolonged marshmallow transit times compared with normal participants or participants with the prosthesis removed ($n=52$, 2 studies).^{10,13} Peristaltic amplitude was significantly lower in participants with dysphagia when compared with normal participants ($n=37$, 1 study).¹⁴ No participants with hiatal hernias had an abnormal MBSE ($n=7$, 1 study).¹² The two studies investigating patients with eosinophilic esophagitis did not have a comparison group, although cumulatively they found that 67% ($n=12$) of patients who had an abnormal endoscopy also had a positive MBSE.^{15,18}

Risk of Bias for Included Studies

Included studies were assessed for bias and methodology using the MINORS criteria, summarized in online **Supplementary Table S1** (available in the online version only). No study met ideal criteria as all studies lacked a prospective calculation of study size. Further, the majority of studies lacked inclusion of consecutive patients. Despite these limitations, the majority of studies scored full marks in the remaining categories; therefore, the overall risk of bias assessment of included studies was low.

Discussion

To the best of our knowledge, the present review is the largest to date evaluating MBSE as a potential diagnostic tool for the pathological causes of IEM. We found nine relevant studies that reported on a total 296 affected participants and 79 controls. Indications for the MBSE were diverse, ranging from patients referred to a gastroenterology clinic for a barium swallow, post-Angelchik insertion, complaint of dysphagia, eosinophilic esophagitis, post-fundoplication, presence of hiatal hernias, and hypertensive lower esophageal sphincter. MBSE identified an esophageal abnormality that was also found on the comparative diagnostic tests in 61% of participants from the included studies and identified missed abnormal pathology in 23% of participants. While promising, the clinical impact of these observed benefits are not clear and warrant further evaluation.

One proposed explanation for the theoretical increased sensitivity of MBSE compared with the traditional LBS is the ability of MBSE to assess secondary peristalsis, which is heavily dependent on bolus size.^{20,21} Our findings were

consistent with this theory, as in comparison of LBS and MBSE, 74% of abnormalities were identified on both diagnostic tests, and 22% were only seen on MBSE. These included structural narrowings of the esophagus, specifically lower esophageal mucosal rings and small caliber eosinophilic esophagitis. LBS identified only one case of small caliber esophagus that had an unremarkable MBSE result. Taken together, these findings suggest that MBSE may be a viable alternative to the LBS in investigating patients with structural esophageal narrowing.

Comparison of the MBSE to endoscopy in the current literature was confined to patients with eosinophilic esophagitis, a chronic, immune antigen-mediated esophageal disease characterized by esophageal dysfunction and eosinophil-predominant inflammation, often leading to esophageal fibrosis and strictures.²² Our findings suggest that MBSE may be more sensitive to functional rather than purely structural esophageal abnormalities, as both Vasilopoulos et al and Potter et al found that in participants with eosinophilic esophagitis, MBSE failed to identify multiple patients with structural abnormalities found on endoscopy.^{15,18} Notably, Potter et al reported that MBSE failed to identify all patients with small caliber esophagus diagnosed endoscopically.¹⁵ Although MBSE may be a viable alternative to the LBS for structural esophageal narrowing, the current literature does not support its use as an alternative to endoscopy when investigating suspected structural esophageal abnormalities. Symptoms in patients with IEM that are consistent with structural esophageal pathologies and would warrant further investigation with endoscopy include dysphagia that is consistently present, rapidly progressive, and initially affected by solids more than liquids.²³

We found a lack of high-quality evidence comparing manometry to the MBSE, as the five studies that did compare these diagnostic tests were published before the era of high-resolution manometry, which decreases the applicability of their findings to current clinical practice.^{10,12,16,18,19} Additionally, patients in these studies had primarily structural abnormalities including eosinophilic esophagitis and Angelchik in situ, which are not typical patient populations that would benefit from motility investigations. Motility investigations such as manometry are designed to diagnose functional abnormalities by indicating if propulsive contraction reaches the lower esophageal sphincter, which may affect bolus transit, and if high intrabolus pressure is present, which may impair peristalsis.²¹ The lack of evidence comparing these two modalities in a variety of patient populations, including those with IEM, strongly suggests that comparative trials in this area are warranted. However, given the delays and limited tolerance in manometry, these findings perhaps suggest a role for MBSE in risk stratifying which patients may benefit from further manometry investigation.

Other studies have demonstrated that the MBSE can play an important role in the diagnosis of IEM. A systematic review by Reedy et al²⁴ found that 49% of participants in included studies were identified to have an esophageal abnormality when visualization was included as part of

the MBSE. This supports the foundational concept that there is a relationship between the oral, pharyngeal, and esophageal phases of swallowing, and that visualization is a critical component of IEM investigations. The proportion of participants that had an abnormal MBSE result was much lower in this systematic review compared with our findings. This is likely a consequence of a lack of standardized protocols across published studies, as marshmallow bolus sizes, liquid provided, and chewing of the bolus were inconsistent between studies. As mentioned by Reedy et al, a standardized, validated, and reliable protocol will be needed if MBSE is to be successfully implemented into clinical practice.²⁴

Taken together, our results suggest that there is a paucity of recent high quality studies investigating the accuracy and clinical utility of the MBSE. As a result, the MBSE has yet to be widely implemented. While the MBSE has shown promise as an effective diagnostic tool, it currently lacks the capacity to allow for simultaneous therapeutic treatment. Endoscopy remains the test of choice in high-risk patients, as esophageal dilatations and biopsies can be performed during the test and expedite treatment. This may contribute to the hesitancy to introduce the MBSE as in some cases it may delay a necessary endoscopy. Additionally, although the MBSE is cost effective, advances in other testing modalities, including the introduction of high-resolution manometry, have made currently used tools more resource efficient.²⁵ A clear benefit of the MBSE will likely need to be demonstrated before it becomes more widely utilized.

Our study is limited by the inherent limitations of literature reviews. The current literature revealed a small number of highly heterogeneous studies with small sample sizes. Comparative groups were not present in four of the nine included studies.^{15,17,19,20} Heterogeneous study populations and testing protocols made it difficult to compare findings between studies. Only three of the nine included studies had a mean or median participant age over 50 years.^{10,13,19} While IEM can occur in younger adults, the majority of patients presenting with IEM, particularly with the symptom of dysphagia, are older adults.²⁶ This may affect study validity and generalizability. Therefore, future MBSE studies should include older aged participants in studies and assess for potential age-mediated differences in diagnostic results. Additionally, trials comparing findings of MBSE in patients with different pathologic causes of IEM are warranted to delineate the optimal use of this test.

Despite these limitations, we report the most comprehensive analysis of the utility of the MBSE as a diagnostic tool in patients presenting with IEM. We found there is insufficient evidence available to inform clinical guidelines regarding the use of the MBSE in investigating IEM. Currently available data are dated and heterogeneous, highlighting the need for further large-scale MBSE studies comparing modalities for diagnosing the underlying cause of IEM. If successful, MBSE has the possibility to optimize care for patients with IEM by reducing waiting times, improving patient comfort, and more efficiently allocating resources, while maintaining diagnostic accuracy.

Conclusion

There is currently limited high-quality evidence on the use of MBSE to diagnose IEM. Further large-scale studies comparing its use in patients with different pathologic causes of dysphagia and of older age are required to further delineate the optimal delivery of this emerging diagnostic modality.

Conflict of Interest

None declared.

References

- Alani M, Al-Jashaami L, Mills M, Guha S, Ratuapli SK. Prevalence of esophageal motility disorders in an open access hybrid "academic - community setting" patient population. *Am J of Gastro* 2018; 113:S180-S181
- Cook IJ. Diagnostic evaluation of dysphagia. *Nat Clin Pract Gastroenterol Hepatol* 2008;5(07):393-403
- Hewson EG, Ott DJ, Dalton CB, Chen YM, Wu WC, Richter JE. Manometry and radiology. Complementary studies in the assessment of esophageal motility disorders. *Gastroenterology* 1990;98(03):626-632
- Kahrilas PJ, Bredenoord AJ, Carlson DA, Pandolfino JE. Advances in management of esophageal motility disorders. *Clin Gastroenterol Hepatol* 2018;16(11):1692-1700
- Kuo P, Holloway RH, Nguyen NQ. Current and future techniques in the evaluation of dysphagia. *J Gastroenterol Hepatol* 2012;27(05):873-881
- Christian KE, Morris JD, Xie G. Endoscopy- and monitored anesthesia care-assisted high-resolution impedance manometry improves clinical management. *Case Rep Gastrointest Med* 2018;2018:9720243
- Inadomi JM, Somsouk M, Madanick RD, Thomas JP, Shaheen NJ. A cost-utility analysis of ablative therapy for Barrett's esophagus. *Gastroenterology* 2009;136(07):2101-2114.e1, 6
- Kelly JE Jr. The marshmallow as an aid to radiologic examination of the esophagus. *N Engl J Med* 1961;265:1306-1307
- McNally EF, Del Gaudio W. The radiopaque esophageal marshmallow bolus. *Am J Roentgenol Radium Ther Nucl Med* 1967;101(02):485-489
- Robertson CS, Smart H, Amar SS, Morris DL. Oesophageal transit of marshmallow after the Angelchik procedure. *Br J Surg* 1989;76(03):245-247
- Higgins JPT, Thompson SG, Deeks JJ, Altman DG. Measuring inconsistency in meta-analyses. *BMJ* 2003;327(7414):557-560
- Kahrilas PJ, Lin S, Spiess AE, Brasseur JG, Joehl RJ, Manka M. Impact of fundoplication on bolus transit across esophagogastric junction. *Am J Physiol* 1998;275(06):G1386-G1393
- Maxwell-Armstrong CA, Steele RJ, Amar SS, et al. Long-term results of the Angelchik prosthesis for gastro-oesophageal reflux. *Br J Surg* 1997;84(06):862-864
- Meshkinpour H, Eckerling G. Unexplained dysphagia: viscous swallow-induced esophageal dysmotility. *Dysphagia* 1996;11(02):125-128
- Potter JW, Saeian K, Staff D, et al. Eosinophilic esophagitis in adults: an emerging problem with unique esophageal features. *Gastrointest Endosc* 2004;59(03):355-361
- Smith DF, Ott DJ, Gelfand DW, Chen MY. Lower esophageal mucosal ring: correlation of referred symptoms with radiographic findings using a marshmallow bolus. *AJR Am J Roentgenol* 1998;171(05):1361-1365
- Tatum RP, Shi G, Manka MA, Brasseur JG, Joehl RJ, Kahrilas PJ. Bolus transit assessed by an esophageal stress test in postfundoplication dysphagia. *J Surg Res* 2000;91(01):56-60
- Vasilopoulos S, Murphy P, Auerbach A, et al. The small-caliber esophagus: an unappreciated cause of dysphagia for solids in patients with eosinophilic esophagitis. *Gastrointest Endosc* 2002; 55(01):99-106
- Waterman DC, Dalton CB, Ott DJ, et al. Hypertensive lower esophageal sphincter: what does it mean? *J Clin Gastroenterol* 1989;11(02):139-146
- Kahrilas PJ, Pandolfino JE Hiatus Hernia. *GI Motility Online*. Published May 6, 2006. Accessed June 11, 2021 at: <https://www.nature.com/gimo/contents/pt1/full/gimo48.html>
- Chen JH. Ineffective esophageal motility and the vagus: current challenges and future prospects. *Clin Exp Gastroenterol* 2016; 9:291-299
- Furuta GT, Katzka DA. Eosinophilic esophagitis. *N Engl J Med* 2015;373(17):1640-1648
- Liu LWC, Andrews CN, Armstrong D, et al. Clinical practice guidelines for the assessment of uninvestigated esophageal dysphagia. *J Can Assoc Gastroenterol* 2018;1(01):5-19
- Reedy EL, Herbert TL, Bonilha HS. Visualizing the esophagus during modified barium swallow studies: a systematic review. *Am J Speech Lang Pathol* 2021;30(02):761-771
- Sadowski DC, Broenink L. High-resolution esophageal manometry: a time motion study. *Can J Gastroenterol* 2008;22(04): 365-368
- Aslam M, Vaezi MF. Dysphagia in the elderly. *Gastroenterol Hepatol (N Y)* 2013;9(12):784-795