



Ultrasound-guided Glossopharyngeal Nerve Block—A New Paradigm in Pain Management

Mukesh K. Yadav¹ Vishnu Prasad Pulappadi¹ Vikram Pratap Singh² Sachidanand J. Bharati²
Barun Bagga^{1,3}

¹Departments of Radiodiagnosis & Interventional Radiology, Dr. B R Ambedkar Institute Rotary Cancer Hospital, All India Institute of Medical Sciences, New Delhi, India

²Departments of Onco-anaesthesiology & Palliative Medicine, Dr. B R Ambedkar Institute Rotary Cancer Hospital, All India Institute of Medical Sciences, New Delhi, India

³New York University School of Medicine, New York, United States

Address for correspondence Dr. Mukesh K. Yadav, MBBS, MD, Department of Radiodiagnosis and Interventional Radiology, Dr. B R Ambedkar Institute Rotary Cancer Hospital, All India Institute of Medical Sciences, New Delhi, India
(e-mail: mukeshyadav11@gmail.com).

J Clin Interv Radiol ISVIR 2023;7:122–125.

Abstract

We report eight cases of oropharyngeal carcinoma in which ultrasound-guided percutaneous distal glossopharyngeal nerve (GPN) block was performed for pain relief. Mean age of the patients was 52 ± 11.5 [SD] years and median baseline pain score was 7 (IQR, 5–8). Under ultrasound guidance, mixture of ropivacaine and dexamethasone was injected into parapharyngeal space. Pain reduced after four weeks in all patients (median [IQR], 4 [2.5–5]). Median quality of life score improved as compared with baseline in physical health (63 [44–69] vs 50 [44–63]) and psychological domains (56 [56–63] vs 50 [50–63]), reduced in social relationships domain (31 [19–44] vs 44 [31–44]), remained same in environment domain (56 [44–69] vs 56 [56–56]). Seven patients showed improvement on Patients' Global Impression of Change scale, while six showed improvement on Clinical Global Impressions scale. These early results show that ultrasound guided distal GPN block can reduce pain intensity in oropharyngeal carcinoma patients.

Keywords

- ▶ glossopharyngeal nerve
- ▶ nerve block
- ▶ ultrasonography

Introduction

The glossopharyngeal nerve (GPN) is a mixed cranial nerve carrying sensory input from different structures of the head and neck, particularly the oropharynx. Conventional techniques of GPN block include topical, intraoral and extraoral peri-styloid approaches, out of which the latter two work well for deeper tissue pathologies.^{1–3} However, both the approaches have a risk of accidental intravascular injection and concurrent blockade of the vagus, spinal accessory, and hypoglossal nerves, all po-

tentially leading to serious complications ranging from hoarseness of voice to life-threatening respiratory difficulty.^{2,4}

Optimal pain management in a cancer patient is essential for providing the best quality of life (QOL), particularly in patients for whom definitive treatment cannot be provided. However, inadequate analgesia is a common problem in cancer patients and can be due to disease progression, opioid tolerance, superimposed infections and local trauma. In this background, interventional nerve block techniques have a

article published online
July 18, 2022

DOI <https://doi.org/10.1055/s-0042-1751251>.
ISSN 2457-0214.

© 2022. Indian Society of Vascular and Interventional Radiology. All rights reserved.

This is an open access article published by Thieme under the terms of the Creative Commons Attribution-NonDerivative-NonCommercial-License, permitting copying and reproduction so long as the original work is given appropriate credit. Contents may not be used for commercial purposes, or adapted, remixed, transformed or built upon. (<https://creativecommons.org/licenses/by-nc-nd/4.0/>)

Thieme Medical and Scientific Publishers Pvt. Ltd., A-12, 2nd Floor, Sector 2, Noida-201301 UP, India

niche role to play as an adjunct to analgesics, instead of being the “last-resort” option.

GPN exits from the jugular foramen and descends posterior to the stylopharyngeus muscle. After innervating it, it enters the pharynx between the superior and middle pharyngeal constrictors to supply the oropharyngeal mucosa. As opposed to the conventional approaches, GPN block within the parapharyngeal space, just before its entry into the pharynx can potentially preserve the motor branches of GPN with a lower risk of injury to other cranial nerves and major vascular structures.

We report a series of eight cases of oropharyngeal carcinoma in which we performed ultrasound guided distal GPN block for pain relief.

Case Report

The institutional review board approval was obtained for a trial comparing the efficacy of 0.75% ropivacaine and 10% lignocaine in GPN block. However, due to the COVID-19 pandemic, we were able to perform only the former arm of the study, the results of which are being presented here. After obtaining written informed consent, the procedure was performed on eight patients aged >18 years with biopsy proven carcinoma of the oropharynx and estimated survival of at least three months presenting to pain clinic between July 2019 and March 2022. These patients had been experiencing pain for at least two weeks with average intensity ≥ 5 on the 11-point numeric rating scale (NRS), refractory to opioids and non-steroidal anti-inflammatory drugs (NSAIDs). The procedure was performed after excluding any contraindications including local infection or skin ulceration at the puncture site, local anesthetic allergy, and psychiatric illnesses compromising patient cooperation.

The ultrasound-guided percutaneous approach, previously described in a cadaveric study and single-patient case reports, was used.⁵⁻⁷ High frequency 6–15 MHz linear array ultrasound probe (Fujifilm Sonosite M turbo, Bothell, Washington, USA) was placed with its medial end near the lateral end of greater horn of hyoid bone and its lateral end near the angle of mandible (►Fig. 1). A 22G lumbar puncture needle was inserted using the in-plane technique into the parapharyngeal space just superficial to the pharyngeal constrictor muscles, which outlines the air within the oropharyngeal lumen (►Fig. 2). Care was taken to avoid the facial artery. At this level, 3 ml 0.75% ropivacaine and 1 ml of 4mg/L dexamethasone were injected.

The mean age of the patients was 52 ± 11.5 (standard deviation, SD) years and seven of them were males. The median pain score at baseline was 7 (interquartile range [IQR], 5–8). The facial pain was predominantly periauricular in location and it increased during deglutition. This indicated that the nerve affected is the GPN. The procedure was successfully performed in all patients without any complications. The patient demographics, clinical parameters, pain before and after the procedure are summarized in ►Table 1.

All patients reported pain reduction 30 minutes after the procedure (median [IQR], 3 [1–4]). There was a gradual

increase in the pain intensity at one week (median [IQR], 2.5 [2–4]) and four weeks (median [IQR], 4 [2.5–5]), as compared with immediately after the procedure, as result of weaning anesthetic effect of the injectate. The pain intensity at four weeks was lower than the baseline value in all patients. In one patient, however, the pain intensity immediately after the procedure was just one point lower than the baseline value. In this patient, there was extensive involvement of the supraglottic larynx and the pterygoid muscles by the tumor, which was not present in the other patients and could have been the potential reason for inadequate pain relief.

QOL was assessed at baseline and after four weeks, using World Health Organization QOL instrument (WHOQOL-BREF)- Hindi/English.⁸ QOL score showed improvement at four weeks, as compared with the baseline, in physical health (median [IQR], 63 [44–69] vs 50 [44–63]) and psychological domains (median [IQR], 56 [56–63] vs 50 [50–63]) but reduced in social relationships domain (median [IQR], 31 [19–44] vs 44 [31–44]). There was no change in environment domain score at four weeks as compared with the baseline (median [IQR], 56 [44–69] vs 56 [56–56]). On assessing the impact of the treatment at four weeks using the Patients' Global Impression of Change (PGIC) scale,⁹ one patient reported that he felt a great deal better (score-7) and two patients each reported that they felt better (score-6), moderately better (score-5) and somewhat better (score-4) with regards to their activity limitations, symptoms, emotions and overall QOL, while one patient reported no change at all (score-1). The clinical status of the patients was assessed at four weeks using the Clinical Global Impressions (CGI) scale¹⁰ and the status was very much improved (score-1) in two, much improved (score-2) in three and minimally improved (score-3) in one patient. Two patients had no change (score-4) in the clinical status at all. Six patients had adequate pain relief on the same dosage of analgesics for four weeks, while reduction in the dosage was possible in two patients.

Discussion

Glossopharyngeal neuralgia is characterized by pain in the regions supplied by the branches of the nerve, including the pharynx, oral cavity and ear, that is triggered by deglutition, chewing, coughing and talking. GPN block, that is conventionally performed in the peri-styloid region, has been shown to be effective for pain control in such patients.¹⁻³ The feasibility of distal GPN block was first assessed in a cadaveric study conducted by Ažman et al., in which methylene blue injected into the parapharyngeal space under ultrasound-guided injection was confirmed to infiltrate around the GPN on dissection.⁵ We could perform distal GPN block successfully performed in all patients under ultrasound guidance and pain relief was obtained in all patients. Prior reports on this technique have also shown similar promising results.^{6,7} Unlike the peri-styloid block, which is associated with complications like hoarseness of voice, dysphagia and tachycardia, due to blockade of the

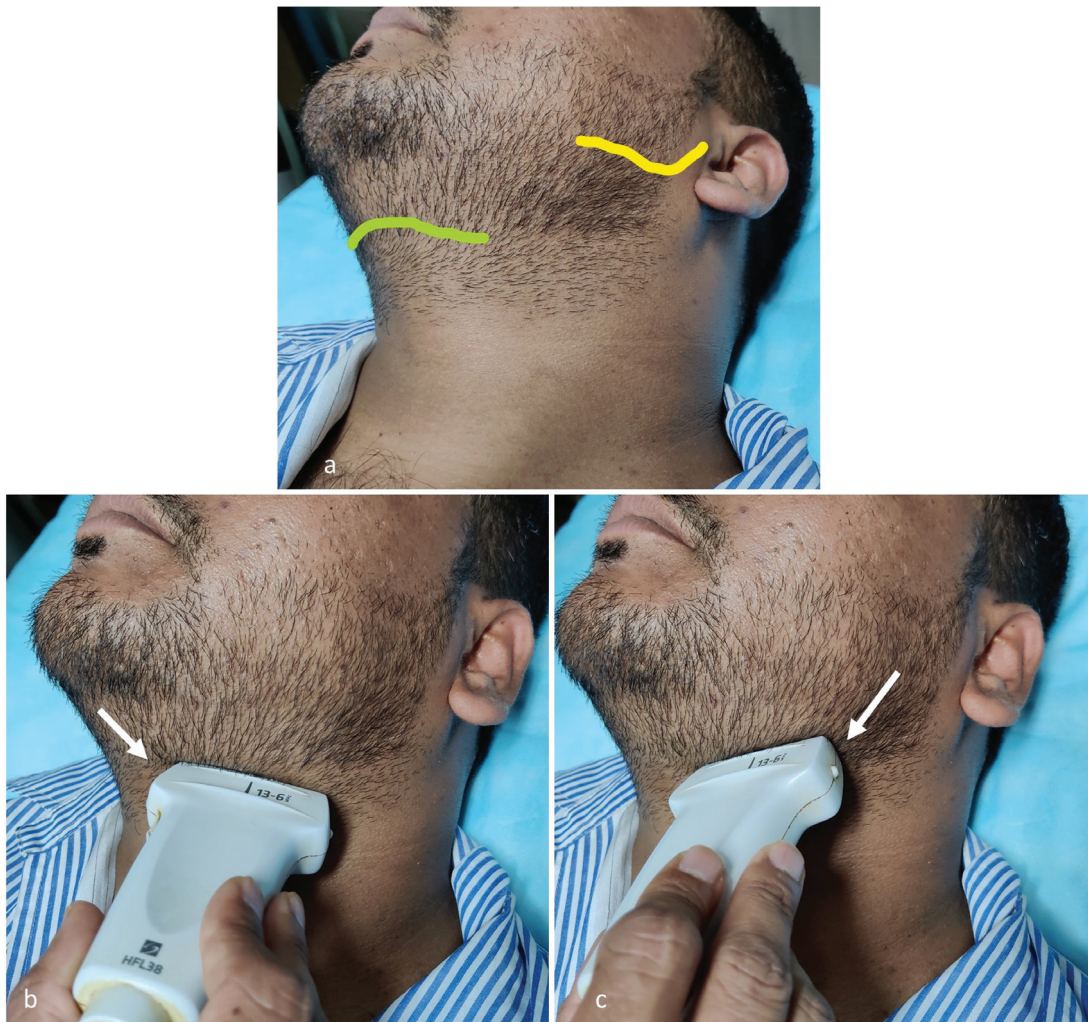

Fig. 1 (a) Clinical Photograph showing the surface markings for hyoid bone (green line) and angle of mandible (yellow line) that are used as landmarks during the procedure. (b, c) Clinical photographs showing the position of ultrasound probe, that is initially kept along the lateral end of greater horn of hyoid bone (arrow in b) and then tilted counterclockwise so that the lateral end of the probe lies near the angle of mandible (arrow in c).

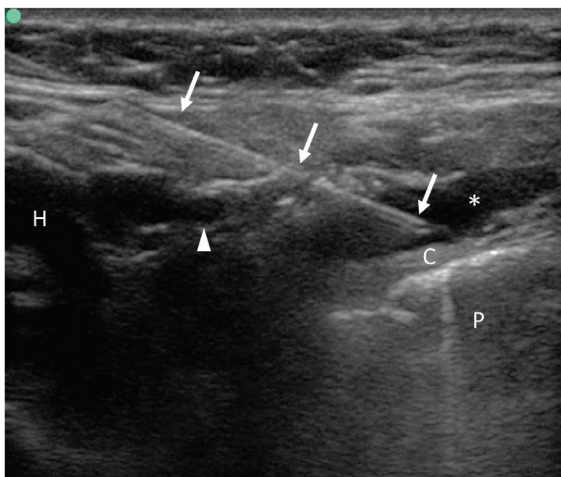


Fig. 2 Ultrasonography image shows local anesthetic agent being injected (*) just superficial to the pharyngeal constrictor muscles (C) that outline the pharyngeal lumen (P) through a 22G lumbar puncture needle (arrows), using lateral end of greater horn of hyoid bone (H) as the landmark, and avoiding the facial artery (arrowhead).

vagus nerve in its vicinity, the distal block performed in our cases was not associated with any complications.² In addition, the landmarks used in the distal block are easier to identify on ultrasonography as compared with peri-styloid block. When compared with fluoroscopic and landmark guided injections, ultrasound-guided block has the advantage of avoiding radiation exposure and facilitating direct visualization of blood vessels, resulting in lower risk of vascular injury. Fluoroscopy cannot be used for distal GPN block due to the absence of any bony landmarks in this region. CT can be used to guide the injection, but suffers from the drawback of inability to accurately localize the branches of external carotid artery that lie in close proximity to the GPN. Ultrasound guidance can help in real time visualization of the needle tip due to the superficial location of the parapharyngeal space and also in avoiding injury to the adjoining vessels.

There was improvement in the QOL scores in the physical health and psychological domains. However, there was a reduction in the score in social relationships domain and no

Table 1 Demographics, clinical details and outcome parameters

Patient No.	Age (years)	Sex	Duration of pain while on analgesics (days)	Cancer site	Site of maximum pain	Numeric rating scale				PGIC score	CGI score
						Baseline	After 30 minutes	After 1 week	After 4 weeks		
1	32	M	30	Left base of tongue	Face	5	0	3	2	6	2
2	66	M	45	Left base of tongue and vallecula	Face, neck, and ear	5	4	2	4	4	3
3	55	F	45	Right vallecula	Face, neck, and ear	10	2	8	8	1	4
4	56	M	45	Left base of tongue	Neck and ear	8	4	2	1	7	1
5	54	M	90	Left base of tongue and vallecula	Face, neck, and ear	5	0	2	4	5	2
6	40	M	240	Right base of tongue and vallecula	Face, neck and ear	8	3	2	3	6	1
7	49	M	60	Right base of tongue	Neck and ear	7	4	4	6	4	4
8	64	M	300	Left base of tongue	Ear	7	3	4	4	5	2

Abbreviations: CGI, Clinical Global Impressions; PGIC, Patients' Global Impression of Change.

change in the environment domain. Most of the patients showed an improvement in their clinical status. None of the patients required an increase in the dosage of analgesics. These outcome parameters show the potential utility of this technique in patients with intractable pain.

Studies with larger sample sizes are required to validate the results obtained in this study. Although we did not encounter any difficulty with the procedure, one potential limitation that may arise is difficulty in placing the ultrasound probe on the small available neck area in patients with skin ulcer or tracheostomy. We suggest that in such cases, an ultrasound probe with a small footprint may be used. Another limitation is that it is not possible to document the spread of the injectate with USG alone. To overcome this limitation, we suggest that a small amount (0.5 ml) of non-ionic iodinated contrast agent be injected into the space along with the local anesthetic followed by acquisition of a non-contrast CT of the neck to ascertain the spread in a better way.

Conclusion

To conclude, ultrasound-guided percutaneous distal GPN block is technically feasible and promising early results show that it can be effectively used to reduce the pain intensity and improve the QOL in patients with intractable cancer related pain from oropharyngeal carcinoma.

Conflict of Interest
None declared.

References

- Ortega Ramírez M, Linares Segovia B, García Cuevas MA, et al. Glossopharyngeal nerve block versus lidocaine spray to improve tolerance in upper gastrointestinal endoscopy. *Gastroenterol Res Pract* 2013;2013:264509
- Liu Q, Zhong Q, Tang G, He G. Ultrasound-guided glossopharyngeal nerve block via the styloid process for glossopharyngeal neuralgia: a retrospective study. *J Pain Res* 2019;12: 2503–2510
- Singh N, Singh S, Mishra NK, Kumar V, Gautam SHemlata. Comparison of extraoral and intraoral routes of glossopharyngeal nerve block for pain relief in patient with carcinoma tongue: A prospective randomized study. *J Cancer Res Ther* 2020;16(03):534–538
- Bean-Lijewski JD. Glossopharyngeal nerve block for pain relief after pediatric tonsillectomy: retrospective analysis and two cases of life-threatening upper airway obstruction from an interrupted trial. *Anesth Analg* 1997;84(06):1232–1238
- Azman J, Stopar Pintaric T, Cvetko E, Vlassakov K. Ultrasound-guided glossopharyngeal nerve block: A cadaver and a volunteer sonoanatomy study. *Reg Anesth Pain Med* 2017;42(02):252–258
- Sirohiya P, Kumar V, Yadav P, Bharti SJ. Ultrasound-guided glossopharyngeal nerve block at pharyngeal wall level in a patient with carcinoma tongue. *Indian J Palliat Care* 2020;26(01):140–141
- Manoharan D, Bharati SJ, Yadav MK. A novel technique of ultrasound-guided glossopharyngeal nerve block to relieve cancer pain. *Saudi J Anaesth* 2019;13(03):279–280
- Saxena S, Chandiramani K, Bhargava RWorld Health Organization Quality of Life. WHOQOL-Hindi: a questionnaire for assessing quality of life in health care settings in India. *Natl Med J India* 1998;11(04):160–165
- Hurst H, Bolton J. Assessing the clinical significance of change scores recorded on subjective outcome measures. *J Manipulative Physiol Ther* 2004;27(01):26–35
- Busner J, Targum SD. The clinical global impressions scale: applying a research tool in clinical practice. *Psychiatry (Edmont)* 2007;4(07):28–37