



# Patellar Groove Replacement in a Cat

Janusz Jaworski<sup>1</sup> Maciej Krukowski<sup>1</sup> Mark Gosling<sup>1</sup> Neil Burton<sup>1</sup>

<sup>1</sup> Department of Orthopaedics, Wear Referrals Veterinary Specialists, Bradbury, Stockton-on-Tees, United Kingdom

Address for correspondence Janusz Jaworski, CertAVP, BSAVA, PGCertSAS, GPCert(DI), MRCVS, Wear Referrals Veterinary Specialists, Bradbury, Stockton-on-Tees TS21 2ES, United Kingdom (e-mail: j.jaworski88@gmail.com).

VCOT Open 2022;5:e71–e77.

## Abstract

The aim of this study was to report patellar groove replacement in a 6-year-old domestic short hair cat with chronic unilateral pelvic limb lameness and severe femoro-patellar osteoarthritis due to medial patellar luxation. This study is a case report. Computed tomographic scan of the affected limb revealed marked periarticular osteophytosis, medial trochlear ridge erosion, marked flattening of femoral trochlea, ectopic pseudo-trochlear groove, and medial patellar luxation. Femoral trochlear ostectomy with patellar groove replacement, release of the medial fibrocartilage, partial parasagittal patellectomy, and lateral tibial tuberosity were performed. Clinical review and radiographs performed 53 days post-surgery revealed no complications and substantial decrease in lameness. Thirteen months postoperatively the cat scored 2/72 on the Feline Musculoskeletal Pain Index questionnaire by the owner, indicating good mobility, minimal discomfort, and good quality of life. As far as the authors are aware, this is the first report of the use of patellar groove replacement in the management of feline medial patellar luxation. Patellar groove replacement, in combination with adjunctive procedures, resulted in a substantial improvement in lameness in this cat with chronic medial patellar luxation and severe femoro-patellar osteoarthritis.

## Keywords

- ▶ feline
- ▶ medial patellar luxation
- ▶ patellar groove replacement
- ▶ CT

## Introduction

Patellar luxation is an infrequent orthopaedic condition affecting cats.<sup>1</sup> Sagittal alignment of the quadriceps mechanism, patella, trochlear groove, and tibial tuberosity is necessary to establish correct patellar tracking.<sup>2</sup> Deviation of the quadriceps mechanism and patella from the long axis of the femur may lead to either medial or lateral patellar luxation.<sup>2</sup> Cats are more commonly affected with medial patellar luxation (MPL) and the condition can be either unilateral or bilateral.<sup>3</sup> There is conflicting evidence whether feline MPL is developmental or traumatic in origin or whether both manifestations may exist.<sup>4</sup> Poor correlation between MPL and presence of hip dysplasia has also been reported in cats.<sup>5</sup>

Clinical signs associated with patellar luxation vary in cats and depend on the grade of the luxation<sup>6</sup>; signs may include

intermittent locking of the stifle following extension or a shuffling/crouching gait.<sup>1</sup> In contrast, normal cats may exhibit femoro-patellar laxity resulting in palpable patellar subluxation without exhibiting clinical signs of lameness.<sup>5</sup> The patella is larger in cats than in dogs with reference to the femoral trochlea.<sup>7</sup> Techniques reported for the correction of MPL include femoral trochlear sulcoplasty, tibial tuberosity transposition, lateral retinacular imbrication, medial soft tissue release<sup>1</sup> distal femoral corrective osteotomy,<sup>8</sup> and partial parasagittal patellectomy.<sup>9</sup> Patellar groove replacement (PGR) has been reported in the literature as a surgical technique for the treatment of canine patellar luxation associated with severe femoro-patellar osteoarthritis.<sup>10</sup> To the authors' knowledge, this is the first case of PGR in a cat in published literature.

received

December 6, 2021

accepted after revision

May 2, 2022

DOI <https://doi.org/>

10.1055/s-0042-1751071.

ISSN 2625-2325.

© 2022. The Author(s).

This is an open access article published by Thieme under the terms of the Creative Commons Attribution License, permitting unrestricted use, distribution, and reproduction so long as the original work is properly cited. (<https://creativecommons.org/licenses/by/4.0/>)

Georg Thieme Verlag KG, Rüdigerstraße 14, 70469 Stuttgart, Germany

## Case Report

A 6-years and 8-month-old, neutered, male, domestic short hair cat with the body condition score 4/9 weighing 2.9 kg presented with chronic right pelvic limb lameness of 3 years duration. The cat was previously diagnosed with bilateral blindness and idiopathic epilepsy, the latter being well controlled with phenobarbital (Epiphen, Vetoquinol) 3.8 mg/kg orally q12h and levetiracetam (Keppra, GSK) 24 mg/kg orally q8h.

Physical examination revealed 5/10<sup>11</sup> right pelvic limb lameness with marked right stifle periarticular thickening, moderate reduction in femoral muscle mass, and grade IV MPL.<sup>6</sup> Neurological examination revealed lack of menace reflex. The remainder of the clinical examination was unremarkable.

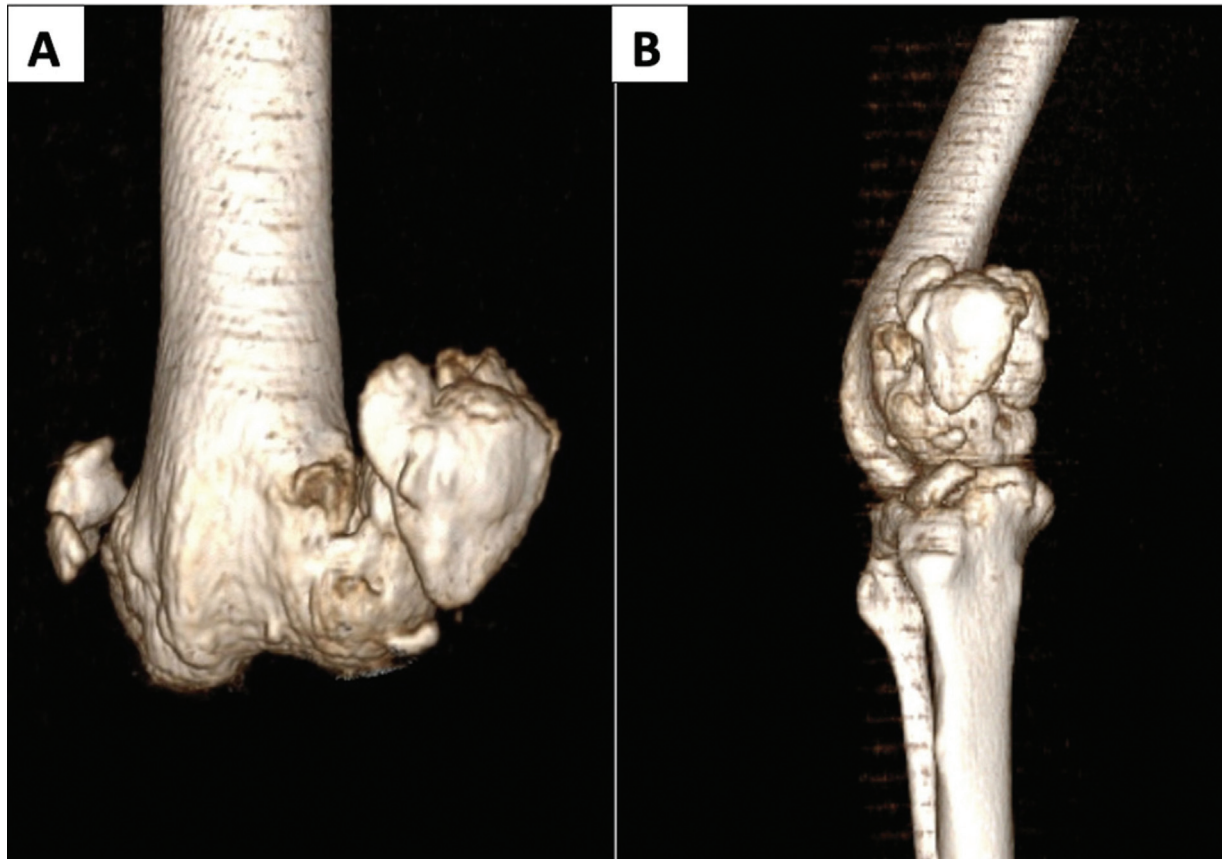
The cat was premedicated with midazolam (Midazolam, Hameln) and methadone (Comfortan, Dechra) intravenously. Induction of anaesthesia was performed with alfaxalone (Alfaxan, Jurox) intravenously, the cat was intubated and maintained with isoflurane (IsoFlo, Zoetis, United Kingdom). Computed tomographic (CT) scan of the pelvic limbs was performed. This revealed marked periarticular osteophytosis, intraarticular calcification, medial trochlear ridge erosion, marked flattening of femoral trochlea, enthesophytosis of proximal and distal aspect of patella, mineralization of joint capsule, and medial meniscus and MPL (► Fig. 1A, B).

Due to the severity of both the femoral trochlear malformation and secondary osteoarthritic changes evident on CT, a trochleoplasty was not considered an appropriate treatment for the management of patellar luxation in this case. Patellar groove replacement surgery was considered as an option for case management as it was either continued as conservative management or limb amputation.

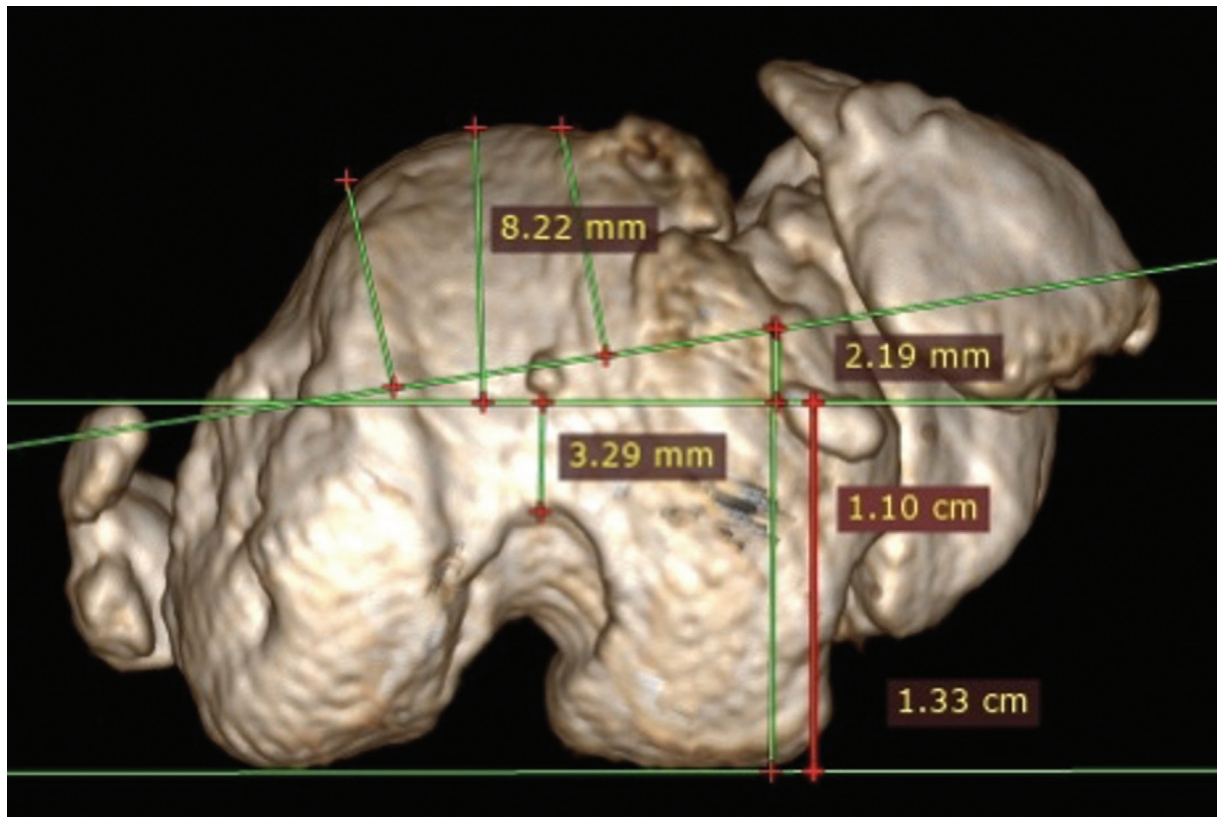
The owner did not want to pursue continued conservative management and, in their opinion, as the patient suffered from bilateral blindness and epilepsy it was believed that amputation may negatively affect the cat's quality of life and this as a treatment was declined. As such, PGR surgery was the elected treatment of choice for this patient.

Feasibility of placing a canine PGR prosthesis in a feline patient was discussed with the implant manufacturer prior to the surgery. CT measurement was made to define distal femoral alignment<sup>13</sup> which was 6 degrees varus. Depth of trochlear ridges and selection of an appropriate size of prosthesis were based on sagittal and coronal CT plane (► Fig. 2) and 3D CT rendering of the femur with a PGR acetate template placed on the computer screen (► Fig. 3A, B). The criteria for selection of the appropriate size prosthesis were performed as previously described in the dog.<sup>10</sup>

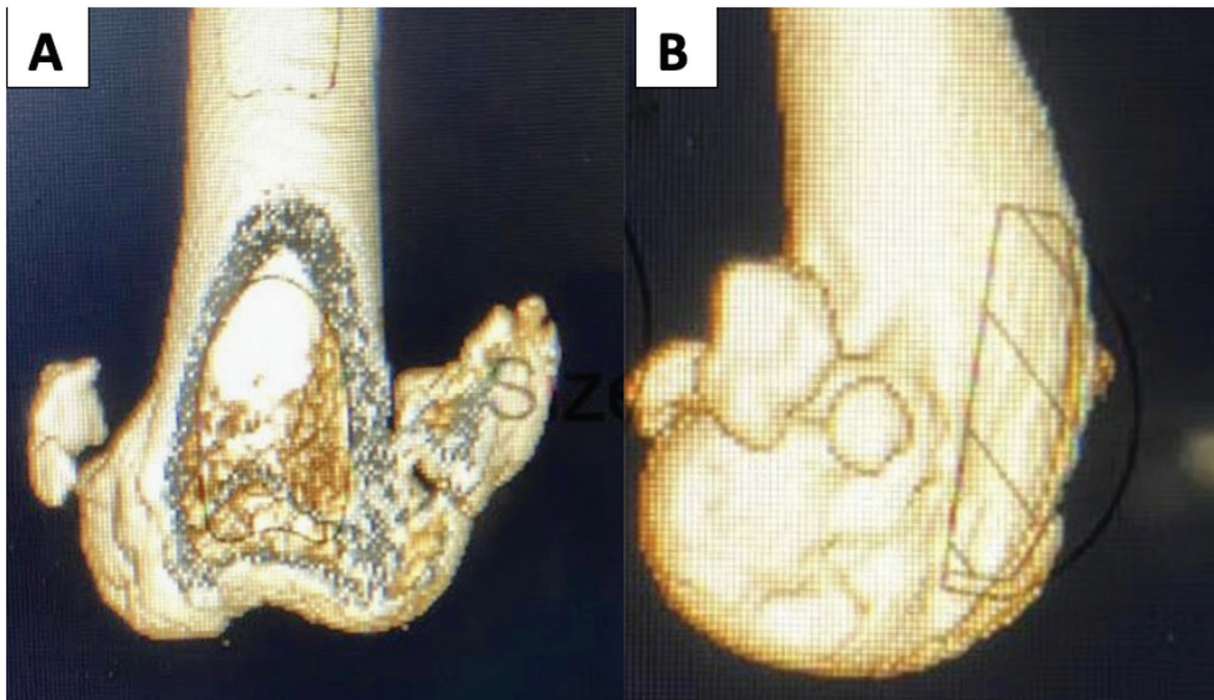
The cat was anaesthetized as previously described with the addition of cefuroxime (Zinacef, GSK) intravenously 30 minutes prior to surgery and meloxicam (Metacam, Boehringer Ingelheim) subcutaneously. A lateral parapatellar



**Fig. 1** Transverse (A) and sagittal plane (B) computed tomography volume rendering three-dimensional reconstruction of the right stifle demonstrating osteoarthritic changes of the distal femur, patella, fabella, and proximal tibia.

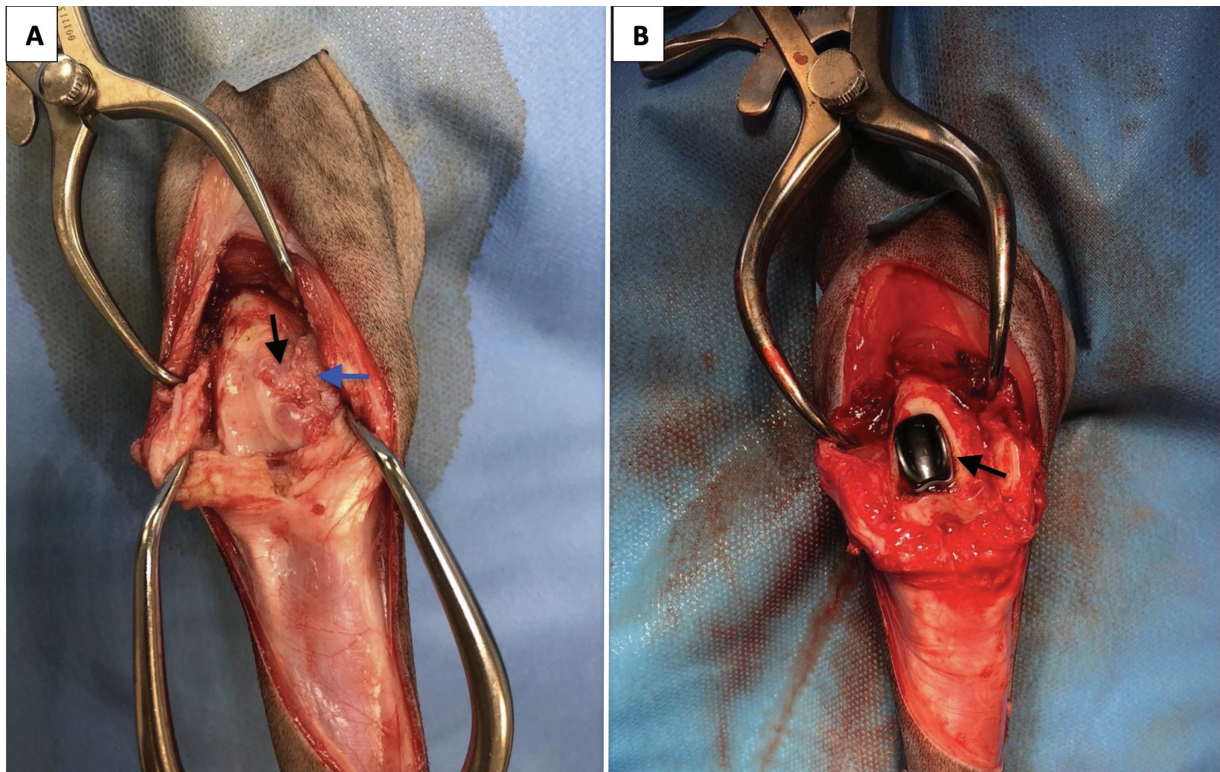


**Fig. 2** Coronal computed tomographic projection of the distal femur demonstrating presurgical planning. Preoperative planning included the measurement of distal femoral varus, depth of trochlear ridges, and selection of the patellar groove replacement implants size. Femoral measurements confirmed minor, six degrees distal femoral varus. Coronal computed tomographic view revealed similar anteversion angles in both femurs when measurements were based on the line of caudal edges of femoral condyles. Measurement of femoral trochlea revealed significant difference between lateral (9.62 mm) and medial (8.05 mm) trochlear ridges giving the false-positive appearance of the distal femoral external torsion.



**Fig. 3** Presurgical planning and selection of patellar groove replacement implant size consisting of placing patellar groove replacement acetate template on transverse (A) and sagittal (B) computed tomography volume rendering three-dimensional reconstruction of the distal femur. The three-dimensional rendered image was scaled to that of a scale on an acetate template for patellar groove replacement measurement and then the template overlaid on the computer screen for measurement.





**Fig. 4** Intraoperative images demonstrating severe osteoarthritic changes affecting femoro-patellar joint (A). *Black arrow* indicates advanced degenerative changes affecting medial femoral trochlear ridge whereas *blue arrow* shows fibrocartilaginous pseudo-trochlear groove. (B) Fixed trochlear prosthesis. *Black arrow* indicates trochlear prosthesis fixed to the base plate.

arthrotomy was performed.<sup>14</sup> Inspection of the joint revealed marked synovitis, a grossly thickened joint capsule, marked osteophytosis, and cartilage erosion of the medial portion of the femoral condyle (►Fig. 4A). Fibrocartilaginous pseudo-trochlear groove formation was evident between the medial portion of the medial femoral condyle and caudal articular surface of the patella (►Fig. 4A). Fibrocartilaginous tissue was removed from the medial aspect of the medial portion of the femoral condyle using blunt and sharp dissection. Substantial contracture of the medial retinaculum/patellofemoral ligament required release of the medial fibrocartilage to allow manual reduction of the patella.

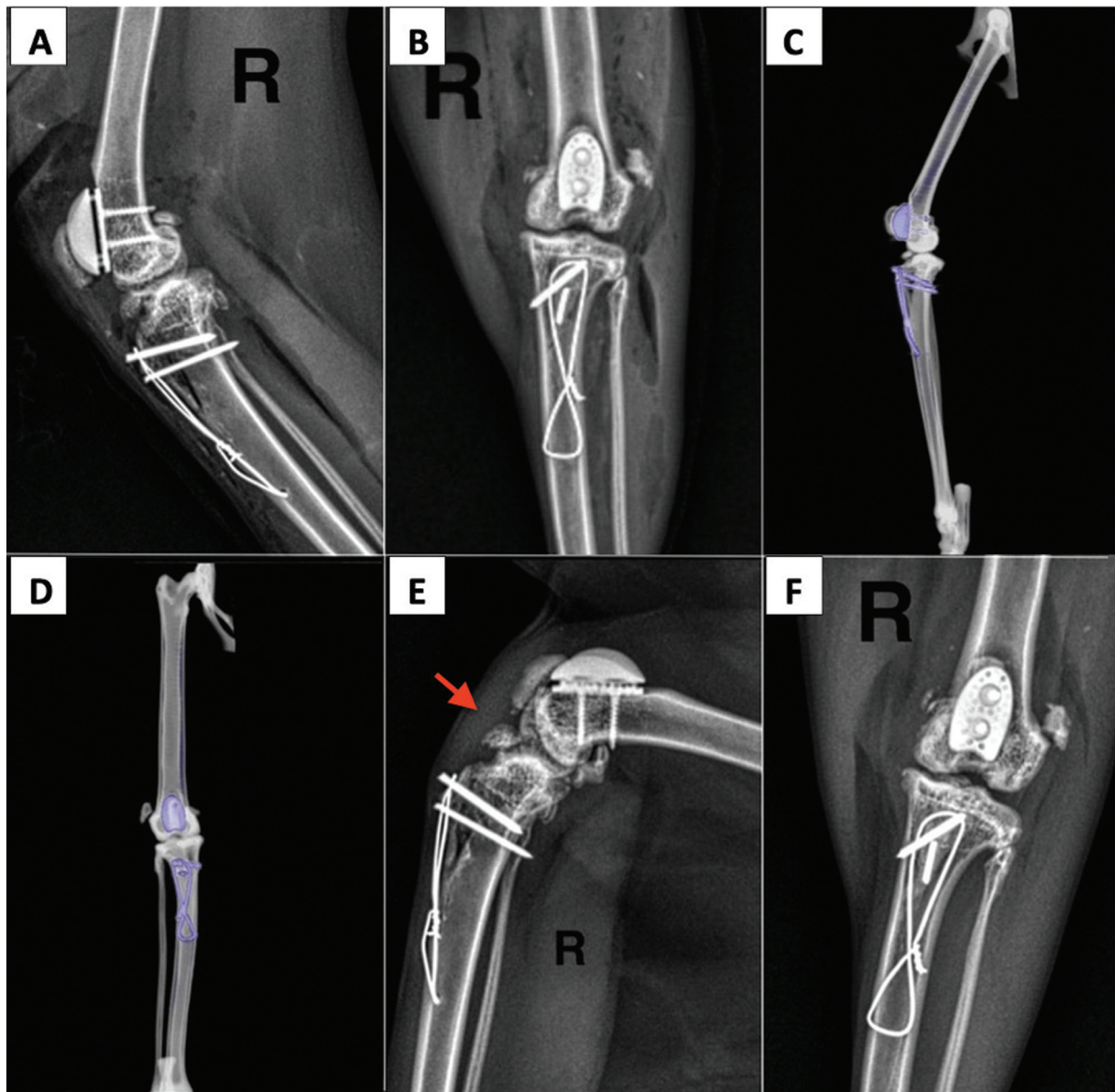
Patellar groove replacement was performed in line with previous description of the surgery in dogs.<sup>10</sup> Osteotomy of the femoral trochlea was determined by presurgical measurements and incorporated a deeper medial osteotomy to remove proliferative osteophytosis at this level. A size 2 trial trochlear prosthesis was temporarily placed on the osteotomy site and the patella was reduced. Examination of the patella articular surface revealed severe cartilage erosion with subchondral bone changes compatible with Grade IV Modified Outerbridge Score.<sup>15</sup>

Removal of fibrotic tissue attached to the patella was performed using sagittal saw to allow appropriate reduction of the patella into trochlear prosthesis. The most suitable position of the trochlear prosthesis, with reference to both mediolateral and proximodistal orientation of the prosthesis on the femoral osteotomy site was marked with diathermy.

The trial trochlear prosthesis was removed, a size 2 base plate of PGR prosthesis was temporarily fixed to the osteotomy surface using three 23-gauge needles. Permanent fixation of the base plate was subsequently performed with two 1.5-mm cortical screws. The trochlear prosthesis was tapped into position onto the baseplate using the polytetrafluoroethylene handle of the periosteal elevator to minimize microdamage to the surface of the implant (►Fig. 4B).

The patella was reduced and fit assessed within the prosthetic trochlea. Patella width exceeded the width of the sulcular part of the trochlear prosthesis and, as such, accurate patella-to-trochlear prosthesis fitting was deemed to be suboptimal; the patella rode on trochlear ridges rather than being in contact with prosthesis sulcus. Partial parasagittal patellectomy was performed<sup>9</sup> which, subjectively, improved patella fit and contact within the prosthetic trochlea.

Following reduction of the patella within the trochlear prosthesis, sagittal alignment of the quadriceps mechanism was assessed. Lateral tibial crest transposition was performed and secured with a 1.4 mm and 1.1 mm Kirschner wire and a 0.6-mm tension band wire. The surgical site was copiously lavaged. The lateral joint capsule was closed using 2 metric polydioxanone (PDS, Ethicon) in a simple continuous suture pattern. Medial joint capsule and released medial fibrocartilage were not closed due to a substantial soft tissue deficit. Subcutaneous tissue and skin were closed using 2 metric poliglecaprone (Monocryl, Ethicon) using a simple



**Fig. 5** Immediate postoperative medio-lateral (A) and caudo-cranial (B) radiographs demonstrating satisfactory implant placement. Computed tomography with decreased metallic algorithm consisting of showing prosthesis alignment with long axis of the femur (C and D). 53 days postoperative medio-lateral (E) and cranio-caudal (F) radiographs demonstrating thickening of patella tendon (red arrow).

continuous suture pattern and intradermal suture pattern, respectively. Postoperative radiographs revealed satisfactory position of implants (►Fig. 5A, B). Postoperative CT was performed concurrently with a decreased metallic algorithm to assess prosthesis position with respect to the sagittal long axis of the femur. This confirmed the PGR long axis was appropriately aligned with the femoral long axis with an improvement in patellofemoral varus orientation (►Fig. 5C, D).

The cat was pain scored at regular intervals postoperatively using a short-form Glasgow Composite Measure Pain Scale.<sup>16</sup> Postoperative analgesia comprised methadone (Comfortan, Dechra) every 4 hours for 24 hours. Thirty-six hours following surgery the patient was discharged with meloxicam (Metacam, Boehringer Ingelheim) orally for 28 days and buprenorphine (Buprecare, Animalcare)

sublingually for 5 days. Cage rest was recommended for 4 weeks.

The cat presented for review appointment and radiographs 53 days following surgery. The owner reported no complications with the cat's postoperative recovery. The cat was one-tenth<sup>11</sup> lame on the right pelvic limb when walking. Orthopaedic examination revealed that the patella was reduced in the PGR and stable through stifle range of motion. Postoperative radiographs showed uneventful healing of the tibial osteotomy and no implant-related complications (►Fig. 5E, F). Although the radiographs revealed increased thickening of the patella tendon consistent with a degree of patellar tendonitis (►Fig. 5E), the patient showed no clinical signs associated with this. The owner was advised to allow the cat a controlled return to normal house activity and the cat was discharged.



The owner was contacted 13 months after the surgery for review of the cat's progress. The owner reported the cat had normal activity and was on not any analgesic medication. A Feline Musculoskeletal Pain Index questionnaire<sup>17</sup> was performed. The cat scored 2/72, indicating good mobility, minimal discomfort, and good quality of life.

## Discussion

Patellar groove replacement surgery is a relatively novel technique to restore satisfactory patellar function in dogs with severe femoro-patellar arthritis.<sup>10</sup> There are no reports of use of this prosthesis in cats to date but the case described herein subjectively achieved good long-term function following its use.

The distal femur was severely deformed on CT with osteophytic remodelling and, at the time of surgery, marked cartilage erosion was confirmed affecting the femoral trochlea. Trochleoplasty could have been attempted in this case in conjunction with tibial tuberosity transposition and retinacular release/imbrication and satisfactory outcome could have been obtained. However, in dogs with this severity of distal femoral articular pathology, it is suggested that trochleoplasty is contraindicated.<sup>10</sup> It was similarly our concern that trochleoplasty in this case may have failed to adequately stabilize the patella, would have resulted in a grossly abnormal patellofemoral articulation and may have resulted in persistent lameness secondary to advanced patellofemoral osteoarthritis.

The authors believe that CT evaluation of the femur in this case was important in surgical planning although this is not an imaging modality routinely described in the preoperative planning of this surgery in dogs.<sup>10</sup> Measurement of femoral condylar depth revealed substantial differences between medial (6.95 mm) and lateral (8.52 mm) trochlear ridge heights, resulting in a false-positive appearance of the distal femoral and trochlear external torsion. Failure to correct this topography of the distal femur with the femoral trochlear ostectomy could predispose to increased risk of patellar luxation. Measurement of the distance for the line of osteotomy with reference to caudal extent of medial and lateral portion of femoral condyle as a reference rather than femoral trochlea facilitated correct positioning of the ostectomy line.

The feline patella is wider in a medio-lateral plane in comparison to the corresponding femoral trochlea.<sup>7</sup> Therefore, block sulcoplasty alone may not be sufficient to ensure appropriate recession of the patella into the femoral trochlear groove which could predispose to suboptimal outcome.<sup>18</sup> Following PGR placement in this case there was a size mismatch between the patella width and the prosthetic groove when the patella was reduced and patella-to-prosthetic sulcus was assessed. A partial parasagittal patellectomy<sup>18</sup> was performed which subjectively improved recession of the patella and patello-to-prosthetic sulcus contact. Partial parasagittal patellectomy has not been previously described in concert with PGR and this technique should be used with caution due to lack of long-term follow-up. Should a feline-specific PGR prosthesis be developed in

the future then developing a wider prosthetic sulcus could potentially circumvent the need for adjunctive partial patellectomy.

The reported complication rate associated with correction of feline MPL using traditional techniques is 26% and may include patellar re-luxation, tibial fracture, implant-associated complications, seroma formation, soft tissue oedema, surgical site infection, and septic arthritis.<sup>4</sup> Major complications were significantly more likely when tibial tuberosity transposition was performed.<sup>4</sup> Complications associated with PGR in dogs include prosthesis dislodgment, reoccurrence of patellar luxation, progression of the osteoarthritis, slippage of patella over the distal end of the prosthesis, inappropriate implant selection, and capsular thickening.<sup>10,19</sup> Although postoperative radiographs revealed thickening of the patella tendon, physical examination revealed no clinical signs associated with this. Further research incorporating a larger number of patients would be required to evaluate frequency and clinical significance of this finding.

Multiple corrective techniques were employed in the management of patellar luxation in this case. As such, the precise contribution of PGR to the success of outcome in this case is difficult to elucidate. Further studies are required to objectively evaluate the biomechanical consequences of this procedure in cats as well as definitive indications/contraindications of its use, either alone or in combination with adjective techniques (e.g., TTT, soft tissue release/imbrication). Potential catastrophic complication such as infection could potentiate either amputation or euthanasia in such a case and careful owner counselling and transparent disclosure of all options for management are paramount.

In summary, in this cat with chronic grade 4 MPL and severe femoro-patellar osteoarthritis, PGR (as part of multi-level surgery) achieved a substantial subjective improvement in lameness and a good quality of life. Further work is required to ascertain the suitability of PGR in cats and whether species-specific adaptations to component design may be required.

### Note

The authors would like to confirm that the case report followed Animal Care Guidelines.

### Authors' Contribution

J.J. drafted the manuscript and approved the final version, M.K. performed the surgery, co-authored the manuscript and approved the final version, N.B. co-authored the manuscript, approved the final version, and edited the figures. M.G. performed the initial assessment, diagnostic work-up of the patient, co-authored the manuscript, and approved the final version.

### Funding

None.

### Conflict of Interest

None declared.

## References

- 1 Loughin CA, Kerwin SC, Hosgood G, et al. Clinical signs and results of treatment in cats with patellar luxation: 42 cases (1992-2002). *J Am Vet Med Assoc* 2006;228(09):1370–1375
- 2 Kowaleski MP, Boudrieau RK, Pozzi A. Stifle Joint. In: Tobias KM, Johnston SA, eds. *Small Animal Veterinary Surgery*. 1st ed. St. Louis: Elsevier; 2012:906–998
- 3 Johnson ME. Feline patellar luxation: a retrospective case study. *J Am Anim Hosp Assoc* 1986;22:835–838
- 4 Rutherford L, Langley-Hobbs SJ, Whitelock RJ, Arthurs GI. Complications associated with corrective surgery for patellar luxation in 85 feline surgical cases. *J Feline Med Surg* 2015;17(04):312–317
- 5 Smith GK, Langenbach A, Green PA, Rhodes WH, Gregor TP, Giger U. Evaluation of the association between medial patellar luxation and hip dysplasia in cats. *J Am Vet Med Assoc* 1999;215(01):40–45
- 6 Singleton WB. The surgical correction of stifle deformities in the dog. *J Small Anim Pract* 1969;10(02):59–69
- 7 Voss K, Langley-Hobbs SJ, Montavon PM. Patellar luxation. In: Montavon PM, Voss K, Langley-Hobbs SJ, eds. *Feline Orthopedic Surgery and Musculoskeletal Disease*. Philadelphia: Saunders Elsevier; 2009:477–479
- 8 Brower BE, Kowaleski MP, Peruski AM, et al. Distal femoral lateral closing wedge osteotomy as a component of comprehensive treatment of medial patellar luxation and distal femoral varus in dogs. *Vet Comp Orthop Traumatol* 2017;30(01):20–27
- 9 Brioschi V, Rutherford L, Newell K, Trotter C, Arthurs GI. Computed tomographic assessment of block recession trochleoplasty and partial parasagittal patellectomy in cats. *Vet Comp Orthop Traumatol* 2020;33(02):102–109
- 10 Dokic Z, Lorinson D, Weigel JP, Vezzoni A. Patellar groove replacement in patellar luxation with severe femoro-patellar osteoarthritis. *Vet Comp Orthop Traumatol* 2015;28(02):124–130
- 11 Sumner-Smith G. Gait analysis and orthopedic examination. Slatter DS, ed. *Textbook of Small Animal Surgery* 2nd ed. W.B. Saunders/Philadelphia1993:1578
- 12 Kyon. PGR – Patellar Groove Replacement. Kyon. Updated August 24, 2021. Accessed 10 November 2021 at: <https://www.kyon.ch/products-solutions/pgr-patellar-groove-replacement/>
- 13 Oxley B, Gemmill TJ, Pink J, et al. Precision of a novel computed tomographic method for quantification of femoral varus in dogs and an assessment of the effect of femoral malpositioning. *Vet Surg* 2013;42(06):751–758
- 14 Piermattei DL, Johnson KA. Approach to stifle joint through a lateral incision. In: Piermattei DL, Johnson KA, eds. *An Atlas of Surgical Approaches to the Bones and Joints of the Dog and Cat*. 4th ed. Philadelphia: Saunders Elsevier; 2004:342–345
- 15 Cameron ML, Briggs KK, Steadman JR. Reproducibility and reliability of the outerbridge classification for grading chondral lesions of the knee arthroscopically. *Am J Sports Med* 2003; 31(01):83–86
- 16 Reid J, Nolan AM, Hughes JML, Lascelles D, Pawson P, Scott EM. Development of the short-form Glasgow Composite Measure Pain Scale (CMPS-SF) and derivation of an analgesic intervention score. *Anim Welf* 2007;16:97–104
- 17 Lascelles DX. The Feline Musculoskeletal Pain Index (FMPI). *Pain Free Cats*. Updated 2018. Accessed November 18, 2021 at: <http://painfreecats.org/the-fmpi/>
- 18 Rutherford L, Arthurs GI. Partial parasagittal patellectomy: a novel method for augmenting surgical correction of patellar luxation in four cats. *J Feline Med Surg* 2014;16(08):689–694
- 19 Kim Y, Park Y, Park J, et al. Bilateral patellar groove replacement in a dog with iatrogenic trochlear groove damage. *J Vet Clin* 2016; 33(05):295–299