



# A Brachial Artery Pseudoaneurysm Treated with a Bifurcated Y-Shaped Artificial Vessel Graft

Joon seok Oh<sup>1</sup> Seokchan Eun<sup>1</sup>

<sup>1</sup>Department of Plastic and Reconstructive Surgery, Seoul National University College of Medicine, Seoul National University Bundang Hospital, Seongnam, Korea

Arch Plast Surg 2022;49:755–759.

Address for correspondence Seokchan Eun, MD, Department of Plastic and Reconstructive Surgery, Seoul National University College of Medicine, Seoul National University Bundang Hospital, 82 Gumi-ro 173beon-gil, Bundang-gu, Seongnam 463-707, Korea (e-mail: sceun@snu.ac.kr).

## Abstract

Brachial artery aneurysms are rare diseases that may be caused by infection or trauma. We report a case of a 71-year-old man who presented with a mass in his right antecubital fossa that increased in size slowly over time. Three years ago, the patient underwent ascending and total-arch replacement with artificial vessel graft to treat aortic root and ascending aorta aneurysm. Preoperative physical examination of right upper extremity showed a nonpulsatile mass with normal pulse of axillary, brachial, and radial arteries. The mass was removed and brachial artery reconstruction was done initially using saphenous vein graft. Two months later, the patient revisited with recurrent pseudoaneurysm, involving the bifurcation point of brachial artery. Aneurysm was totally resected and the brachial artery was reconstructed by interposition graft using a bifurcated GORE-TEX artificial vessel graft. The patient healed without complication and no recurrence was observed. Artificial vessel graft is an available option for reconstruction, and revascularization of vessel defect after excision of brachial artery aneurysm may involve bifurcation point.

## Keywords

- ▶ pseudoaneurysm
- ▶ artificial vessel graft
- ▶ brachial artery

## Introduction

Arterial pseudoaneurysms occur when a hematoma forms after disruption of the arterial wall. This presents as a pulsatile hematoma in the artery. It frequently occurs in the cerebral arteries and brachial arteries are affected in 3 to 10% of the time.<sup>1</sup> Brachial artery aneurysm is a rare disease. It usually occurs as a false aneurysm secondarily caused by infection, trauma, or iatrogenic event.<sup>2</sup> Specifically, brachial mycotic pseudoaneurysm can arise rarely after infective endocarditis.<sup>1,3,4</sup> With infection of the arterial wall, pseudoaneurysm formation can occur without any iatrogenic injury from surgical or endovascular arterial intervention.<sup>1</sup> This is referred as mycotic aneurysms.

Mycotic aneurysm commonly occurs from septic emboli created by native or prosthetic valve endocarditis, intravenous drug abuse, or invasive endovascular catheter use.<sup>1</sup> Mycotic pseudoaneurysm occurs in the upper limb in 10% of the cases and the prevalence is known to be 0.03% annually.<sup>1</sup> Despite its low incidence, prompt diagnosis and treatment are necessary to prevent severe complications such as limb amputation.<sup>5</sup>

## Case

We report a case of a 71-year-old male who presented with a mass in his right antecubital fossa that increased in size slowly over time. Three years ago, the patient underwent

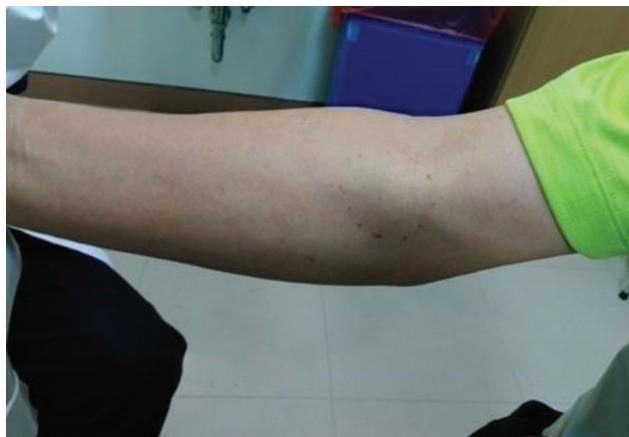
received  
September 30, 2021  
accepted after revision  
March 29, 2022

DOI <https://doi.org/10.1055/s-0042-1751025>.  
eISSN 2234-6171.

© 2022. The Korean Society of Plastic and Reconstructive Surgeons. All rights reserved.

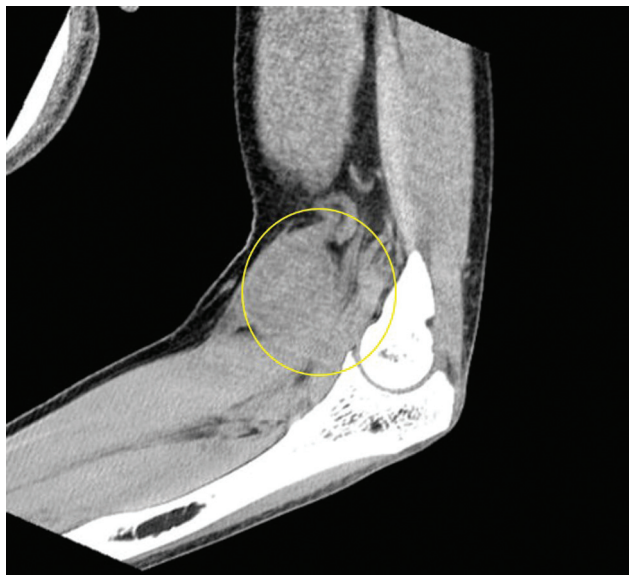
This is an open access article published by Thieme under the terms of the Creative Commons Attribution-NonDerivative-NonCommercial-License, permitting copying and reproduction so long as the original work is given appropriate credit. Contents may not be used for commercial purposes, or adapted, remixed, transformed or built upon. (<https://creativecommons.org/licenses/by-nc-nd/4.0/>)

Thieme Medical Publishers, Inc., 333 Seventh Avenue, 18th Floor, New York, NY 10001, USA



**Fig. 1** Preoperative clinical photo showing palpable mass in patient's elbow.

ascending and total arch replacement with artificial vessel graft to treat aortic root and ascending aorta aneurysm. One year ago, the patient was admitted for treatment of infective endocarditis. Infection subsided without complication. Preoperative physical examination of right upper extremity showed a nonpulsatile mass with normal pulse of axillary, brachial, and radial arteries. No signs of inflammation or infection were present. Preoperative clinical photo of the patient's arm is shown in ►**Fig. 1**. Initially, the authors' first impression of the disease was a simple hematoma. Preoperative computed tomography (CT) showed an 8 cm × 2.8 cm × 3.5 cm soft tissue mass as shown in ►**Fig. 2**. Thus, further CT angiography or invasive arteriography were not performed. Intraoperatively, a mass encircling the brachial artery was identified. The mass along with part of the brachial artery was removed. A 1.5-cm length defect of the brachial artery was replaced by a 1.5-cm sized circumferen-



**Fig. 2** Preoperative computed tomography showing an 8 cm × 2.8 cm × 3.5 cm soft tissue mass.

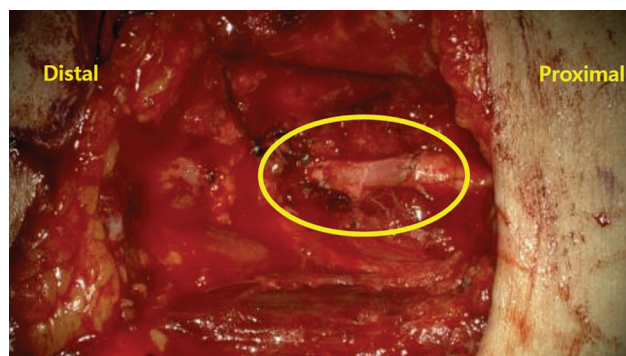
tial great saphenous vein was harvested to reconstruct the removed portion of the brachial artery as shown in ►**Fig. 3**.

Two months later, the patient presented with pain and limited range of motion of his elbow. Severe bruising and edema were present, but no sign of vascular ischemia was present at the distal end as shown in ►**Fig. 4A**. A pulsatile mass was presented in his elbow. For further evaluation, CT angiography revealed a 7 cm × 7 cm sized pseudoaneurysm in the right brachial artery as shown in ►**Fig. 4B**. Surgical exploration was done in the operation room. The patient was laid supine with right upper arm abducted. A longitudinal incision on the medial side of the arm and transverse incision along the antecubital fossa were made. Unlike the first operation, the authors had to overcome some difficulties. Diffuse swelling, edema, and fibrotic tissue were present in the entire elbow. This made identification of anatomical landmarks and dissection very difficult, leading to increased operation time. Due to increased operation time, arm tourniquet had to be disabled frequently. Even with tourniquet apply, sluggish venous oozing was present in the operation field.

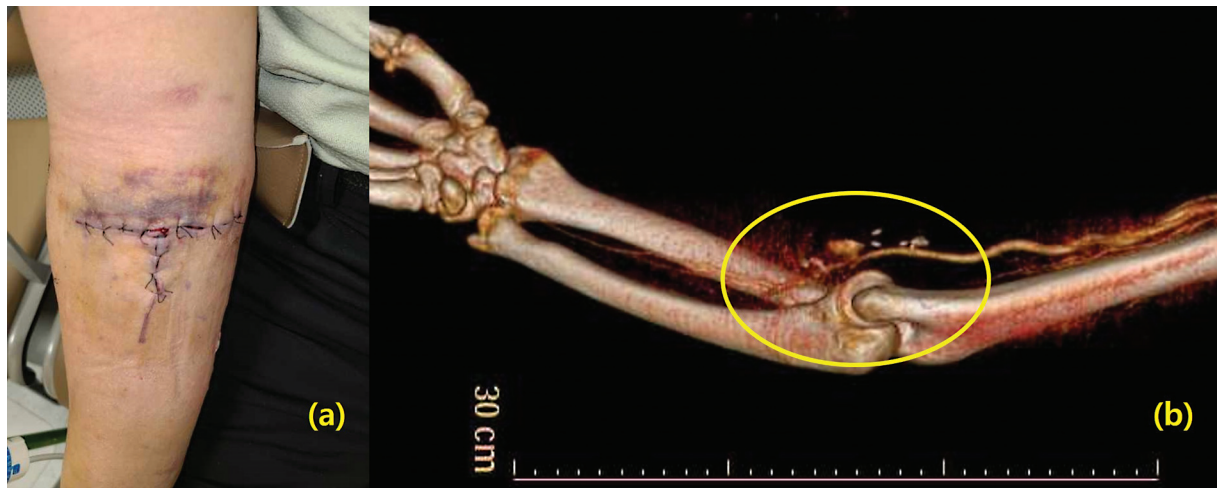
A pseudoaneurysm has recurred and capsule formation extended distally toward radial and ulnar arteries. Extensive capsulectomy and adhesiolysis were performed. Despite risk of massive hemorrhage and injury to surrounding neurovascular and muscular structure, complete excision of the pseudoaneurysm pouch was done to find the proximal ends of radial and ulnar artery and the distal end of brachial artery. This left about a 10-cm sized defect in the right brachial artery including the bifurcation point of brachial artery. A Y-shaped GORE-TEX artificial vessel graft was used for inter positioning between brachial artery and radial and ulnar artery for revascularization as shown in ►**Fig. 5**. Permanent biopsy result showed pseudoaneurysm and all microbial results were negative. Follow-up of the patient at 6 months showed no recurrences or wound problem as shown in ►**Fig. 6**. An invasive arteriography or CT angiography were not performed but a hand-held Doppler device patency of both the radial and ulnar side artificial vessel. The patient-reported partial sensual recovery.

## Discussion

Arterial aneurysm is defined as a region where 50% increase in diameter compared with its normal value of artery is



**Fig. 3** Great saphenous vein graft used to reconstruct excised aneurysm from brachial artery.



**Fig. 4** (A) Two months later, the patient presented with pain and limited range of motion of his elbow. Severe bruising and edema were present. (B) Computed tomography angiography after recurrent mass showing a 7 cm × 7 cm sized pseudoaneurysm in brachial artery.

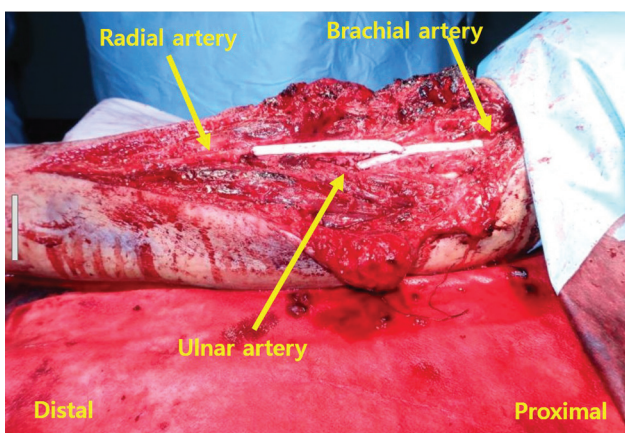
observed.<sup>6</sup> False aneurysms occur by hemorrhage and extravasation caused by traumatic puncture of vessels. Fibrosis of hematoma causes false aneurysms.<sup>6</sup> True aneurysms are formed when gradual increase in arterial diameter occurs due to vessel damage.<sup>6</sup> Brachial artery aneurysm is a rare disease. It usually occurs in the form of false aneurysm and its prevalence is reported as 0.5%.<sup>2</sup> It develops slowly from months to years for development of any clinical symptoms.<sup>6</sup> It is known to be caused secondarily by atherosclerosis, blunt/penetrating trauma, or other diseases such as neurofibromatosis, Kaposi's sarcoma, Kawasaki's disease, or Buerger's disease.<sup>2</sup> Penetrating trauma, such as stabbing, is more common while blunt trauma may also cause the disease in patients who are hemorrhagic.<sup>5</sup> Aneurysms arising after blunt trauma caused by humeral fracture has been reported.<sup>7</sup> In our case, the patient had preceding infective endocarditis after ascending and total arch replacement. The mass was first noticed by the patient 3 years after aorta replacement and 1 year after incidence of infective endocarditis.

Brachial mycotic pseudoaneurysm is an uncommon complication of infective endocarditis.<sup>1,3,4</sup> Among upper extrem-

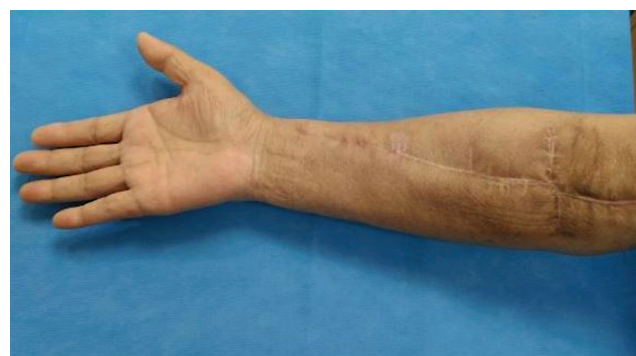ity mycotic pseudoaneurysm, brachial artery is the most commonly affected site. The most common risk factor is prosthetic valve endocarditis<sup>1</sup> which was the case in our patient. The pathophysiology of the disease is the formation of aneurysm by the occupation of arterial vasa vasorum wall by septic emboli coming from infective endocarditis.<sup>1</sup>

Patients may not show any symptoms when aneurysms are small. This is why our patient has presented with a palpable mass years after aorta replacement and infective endocarditis. The most common symptoms are pain, swelling, and neurological signs caused by compression of median nerve.<sup>8</sup> A pulsatile mass accompanying induration and erythema may present.<sup>6</sup> Bruit or thrill can be audible. If the lesion enlarges and compresses surrounding neurovascular structure, pain and edema of the extremity can develop. The symptoms can be relieved after complete resection of the aneurysm. If thromboembolism develops, limb ischemia may occur which may require distal amputation if treatment is delayed.<sup>8</sup>

Diagnosis can be done using imaging such as ultrasonography or CT angiography.<sup>2</sup> On diagnosis, intervention either open surgery or endovascular approach is recommended to avoid complication.<sup>2</sup> With open surgery approach, the lesion



**Fig. 5** Y-shaped GORE-TEX artificial vessel graft used as interposition graft connecting brachial artery with radial and ulnar arteries.



**Fig. 6** Follow-up clinical photo at 6 months without sign of recurrence.



can be approached simply with great exposure.<sup>2</sup> Delay in treatment may lead to upper limb ischemia, edema, hemorrhage, and neurological symptoms. The affected brachial artery with pseudoaneurysm should be resected along with debridement of any surrounding tissue accompanying infection or necrosis. Immediate revascularization should be done. Simple repair or end-to-end anastomosis with interrupted or running suture can be done with small lesions.<sup>1</sup> Too much tension may lead to thrombosis of anastomosis site. If the lesion is distal to the bifurcation point of brachial artery, the aneurysm can be simply ligated.<sup>5</sup> However, as in our case, if the aneurysm affects the bifurcation point, reconstruction is necessary for maintaining adequate vascularization to the distal extremity.<sup>5</sup> For large defects, interposition can be done using autologous vessel graft or prosthetic conduit.<sup>1</sup> Using prosthetic conduit may have long-term problems or potentially cause infection.<sup>8</sup>

If patients accompany with limb ischemia, embolectomy with Fogarty catheter can be considered. However, severe complications, such as limb amputation, brachial plexus injury, and flexion contracture, must be considered.<sup>1</sup> As opposed to surgery, endovascular procedure can be attempted to apply stent in the affected region if infection is not present. If infection is present, intravenous antibiotics and valve replacement of infected valve must be considered.<sup>1</sup> Injecting thrombogenic agents to block the aneurysm has been reported.<sup>8</sup> However, this may cause complications associated with vessel thrombosis.

In our case, the mass was first explored in open surgery. Despite successful removal of pseudoaneurysm and reconstruction with a 1.5-cm sized circumferential saphenous vein graft, a recurrent pseudoaneurysm appeared 2 months later. Autologous vein graft failure can be divided by three phases. Early failure occurs often within 1 month due to thrombosis. This may be due to endothelial injury during harvest procedure or exposure to arterial pressure that increases shear stress to the vein. Consequently, this leads to vein graft thrombosis. Intermediate failure occurs between 1 month and 1 year. As the vein graft is exposed to high arterial pressure, neointimal hyperplasia occurs which eventually cause graft luminal loss and atherosclerosis. Late failure occurs beyond 1 year due to progressive calcified atherosclerosis.<sup>9-11</sup> In our case, the pseudoaneurysm appeared 2 months later. Thus, a mixture of early and intermediate failure seems to be present. Due to the increased arterial pressure, the vein graft distended to appear as an aneurysm. This may have caused the remnant artery to further dilate toward the distal portion. The recurred pseudoaneurysm extended distally toward the radial and ulnar artery including the bifurcation point of brachial artery. The extended pseudoaneurysm and capsule formed after the first operation were totally removed. The reconstruction was challenging due to massive hemorrhage and due to the need for reconstruction of the bifurcation point to revascularize both ulnar and radial arteries. Reconstruction was successfully done using a Y-shaped GORE-TEX artificial artery graft. When comparing synthetic vessel graft with

autologous grafts, synthetic grafts have lower long-term patency and higher infection risk.<sup>12,13</sup> In our second operation, there was about a 10-cm Y-shaped defect. Because of the large defect required for reconstruction and initial failure of autologous vein graft, an artificial GORE-TEX vessel graft was chosen for reconstruction.

We present a rare case of brachial artery pseudoaneurysm with history of infective endocarditis following previous artificial vessel graft placement in the aorta. Pseudoaneurysm was removed successfully without injuring surrounding soft tissue including nerve, muscles, and tendon. The arterial defect caused by excision of pseudoaneurysm was reconstructed successfully with a bifurcated Y-shaped artificial vessel graft after recurrence of the aneurysm after initial reconstruction with saphenous vein graft.

#### Author Contributions

Conceptualization: S.E. and data curation and manuscript preparation: J.S.O.

#### Ethical Approval

The study was performed in accordance with the principles of the Declaration of Helsinki. Written informed consent was obtained.

#### Patient Consent

The patient provided written informed consent for the publication and the use of her images.

#### Conflict of Interest

None declared.

#### References

- 1 Stiru O, Geana RC, Valeanu L, Tulin A, Raducu L, Iliescu VA. Brachial mycotic pseudoaneurysms due to prosthetic valve infective endocarditis: a case report and review of the literature. *Heart Surg Forum* 2020;23(05):E617-E620
- 2 Mrad MB, Ghedira F, Ghorbel N, Denguir R, Khayati A. A true distal brachial artery aneurysm treated with a bifurcated saphenous vein graft. *Ann Vasc Surg* 2015;207:e9-e11
- 3 Zedtwitz-Liebenstein K, Gabriel H, Willinger B, Ehringer H, Polterauer P, Graninger W. Prosthetic valve endocarditis due to *Candida tropicalis* complicated by multiple pseudoaneurysms. *Infection* 2001;29(03):177-179
- 4 Nawaz DJH, Bonnez W. A cause of human endocarditis complicated by pseudoaneurysm. *J Clin Microbiol* 1996;34(03):756-758
- 5 Yetkin U, Gurbuz A. Post-traumatic pseudoaneurysm of the brachial artery and its surgical treatment. *Tex Heart Inst J* 2003;30(04):293-297
- 6 Jun Yong Lee HK, Kwon HJung S-N. Delayed rupture of a pseudoaneurysm in the brachial artery of a burn reconstruction patient. *World J Emerg Surg* 2013;21:21
- 7 Sungelo MJ, Sears BW. Delayed radial nerve injury from a brachial artery pseudoaneurysm following a four-part proximal humerus fracture: a case report and literature review. *JBJS Case Connect* 2019;9(03):e0165
- 8 Klonaris C, Patelis N, Doulaptis M, Katsargyris A. Hybrid treatment of large brachial artery pseudoaneurysms. *Ann Vasc Surg* 2016;32:20-24

- 9 Davies MG, Hagen PO. Pathophysiology of vein graft failure: a review. *Eur J Vasc Endovasc Surg* 1995;9(01):7–18
- 10 Peter McKavanagh BY, Zawadowski G, Cheema A. Management and prevention of saphenous vein graft failure: a review. *Cardiol Ther* 2017;6(02):203–223
- 11 Kim FY, Marhefka G, Ruggiero NJ, Adams S, Whellan DJ. Saphenous vein graft disease: review of pathophysiology, prevention, and treatment. *Cardiol Rev* 2013;21(02):101–109
- 12 Kampf S, Willegger M, Dawoud C, et al. Long-term outcome in pediatric surgical bypass grafting after traumatic injury and tumor resection: retrospective cohort analysis. *Sci Rep* 2021;11(01):16321
- 13 Veith FJ, Gupta SK, Ascer E, et al. Six-year prospective multicenter randomized comparison of autologous saphenous vein and expanded polytetrafluoroethylene grafts in infrainguinal arterial reconstructions. *J Vasc Surg* 1986;3(01):104–114