




Autologous Fat Transfer in Lupus Panniculitis Facial Lipoatrophy

Natthapong Kongkunnawat, MD¹  Jirapat Prathyajuta¹  Warangkana Tonaree, MD¹ 

¹Division of Plastic Surgery, Department of Surgery, Faculty of Medicine Siriraj Hospital, Mahidol University, Bangkok, Thailand

Address for correspondence Warangkana Tonaree, MD, Division of Plastic Surgery, Department of Surgery, Faculty of Medicine Siriraj Hospital, Mahidol University, 2 Wanglang Road, Bangkok Noi, Bangkok 10700, Thailand (e-mail: Teenybd@gmail.com).

Arch Plast Surg 2022;49:527–530.

Abstract

Lupus panniculitis (LP) often presents with tender nodules and intermittent ulcers that then heal with scarring and lipoatrophy. The current mainstay of treatment is medical treatment. Research regarding the treatment of lipoatrophy from LP with autologous fat grafting is limited. We would like to share our experience in this rare case, which was treated with autologous fat transfer. A 48-year-old female presented with erythematous plaque, tender nodules, and ulcers following by a depression of the lesion at the left temporal area. The patient also had indurated erythematous plaque at her left cheek. Both lesions were aggravated by sunlight exposure. After several investigations, she was diagnosed as LP with secondary lipoatrophy and tumid lupus erythematosus at her left temporal and left cheek, respectively. She received antimalarial drug and topical steroids. The patient underwent two sessions of autologous fat transfer. She was satisfied with the volume and contour improvement in the scar following the injection of 8 and 3.7 mL of fat. Furthermore, the patient reported the remission of tender nodules and ulcers since the first fat graft injection. In conclusion, the autologous fat transfer is a simple and effective treatment for lipoatrophy and scar secondary to LP with promising results.

Keywords

- ▶ lipoatrophy
- ▶ lupus panniculitis
- ▶ fat grafting
- ▶ autologous fat transfer

Introduction

Cutaneous lupus erythematosus (CLE) has a variety of manifestations, which can be divided into three categories: acute cutaneous lupus erythematosus (ACLE), subacute cutaneous lupus erythematosus (SACLE), and chronic cutaneous lupus erythematosus (CCLE). Lupus erythematosus panniculitis or lupus panniculitis (LP), which is a variant of CCLE, occurs from inflammation of the subcutaneous fat and leads to tender nodules and ulcerative lesions with a chronic relapse nature. Even though various kinds of medical treatment have been applied, LP often causes scarring and postinflammatory lipoatrophy with marked contour deficits.^{1,2}

Up to the present date, the current mainstay treatment for CLE is medical treatment, including topical corticosteroids and calcineurin inhibitors, systemic antimalarials, and systemic steroids. Other immunomodulators are considered for refractory disease or in cases of contraindication in systemic steroid usage.³

The treatment of atrophic cutaneous lupus lesion by injectables is avoided due to the theoretical risk of disease reactivation by tissue trauma.⁴ Indeed, a previous study involved the injection of hyaluronic acid and poly-L-lactic acid for the treatment of LP-induced facial lipoatrophy and found that the effect of the treatment was only temporary

DOI <https://doi.org/10.1055/s-0042-1751024>.
ISSN 2234-6163.

© 2022. The Korean Society of Plastic and Reconstructive Surgeons. All rights reserved.

This is an open access article published by Thieme under the terms of the Creative Commons Attribution-NonDerivative-NonCommercial-License, permitting copying and reproduction so long as the original work is given appropriate credit. Contents may not be used for commercial purposes, or adapted, remixed, transformed or built upon. (<https://creativecommons.org/licenses/by-nc-nd/4.0/>)

Thieme Medical Publishers, Inc., 333 Seventh Avenue, 18th Floor, New York, NY 10001, USA

and the reactivation of disease was suspected from the injected materials.⁵ However, the data from several studies have demonstrated satisfactory outcomes and favorable safety profile of fat grafting in LP lesions.^{6,7}

Autologous fat transfer, also known as fat grafting, has been used for volume restoration and contour defects in reconstructive surgery for decades. Autologous fat grafting not only involves volume replacement but also has the ability to regenerate itself. Several studies have demonstrated the presence of multipotent stem cells in the stromal vascular fraction of processed fat grafts, which can promote angiogenesis, alter the apoptosis process, and modulate immune responses.⁴⁻⁸

The keystone of potential treatment is the use of adipose-derived stem cells (ADSCs), that are capable of soft tissue regeneration and of restoring devitalized tissue, as seen in many studies, including wound healing promotion, antiaging treatment, and damaged skin rejuvenation.^{9,10} In this study, we aim to share our experience regarding the treatment of lipoatrophy secondary to LP with autologous fat transfer.

Case

A 48-year-old female presented with an atrophic lesion at her left temporal area for 2 years. The lesion was first occurred with erythematous plaque, tender nodules, and intermittent ulcers followed by depression of the lesion, which was progressive for a year then stabilized. The patient also had a rash at her left cheek, which was an ill-defined indurated erythematous plaque with sparing of the nasolabial fold. Both the rashes were aggravated by sunlight exposure and heat. The patient denied any underlying disease, current medications, or history of photosensitivity rash in other areas.

Physical examination showed locally subcutaneous atrophic lesion at the left temporal region and an ill-defined indurated erythematous plaque at the left cheek with sparing of the nasolabial fold, while no facial palsy, no bone deformity at the temporal area, no malocclusion, no other skin lesion, no arthritis, no oral ulcer, and no alopecia were found (→Figs. 1A and 2A).

The patient was sent to a rheumatologist and dermatologist for evaluation. Autoimmune panel tests were done. The patient had a positive antinuclear antibody with a fine-speckled pattern titer 1:320, positive anti-cytoplasmic antibody titer 1:100, and positive anti-Ro autoantibodies 2+, while the other antibody tests were unremarkable and there was no evidence of internal organ involvement. The diagnoses were tumid lupus erythematosus (tumid LE) for the indurated lesion at the cheek and LP with secondary lipoatrophy for the lesion at the left temporal area.

Unfortunately, the patient was unwilling to have a skin biopsy performed, which limited the confirmation of CLE pathologically. However, the erythematous plaque responded well to treatment with oral hydroxychloroquine 200 mg once daily and topical 0.1% mometasone furoate cream. The medical treatment had been continued for 10 months before the autologous fat grafting. The patient

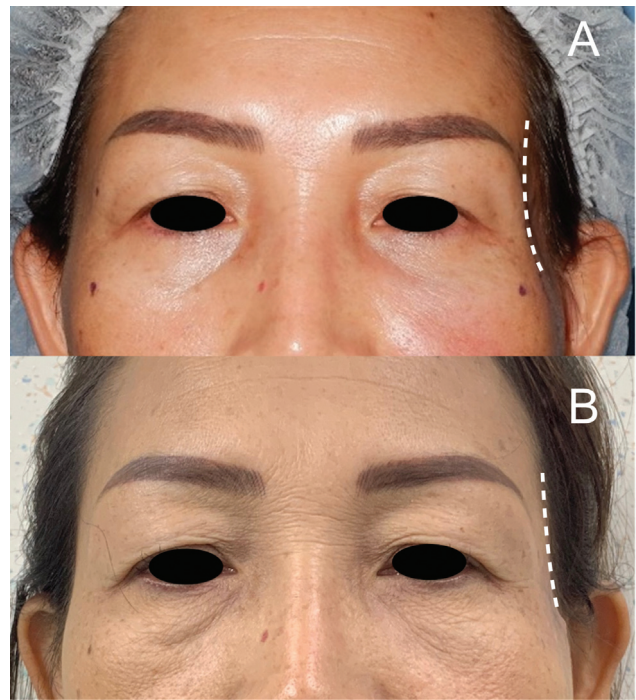


Fig. 1 The patient had an ill-defined erythematous plaque with local subcutaneous atrophy at the left temporal region and an ill-defined indurated erythematous plaque at the left cheek at the first visit (A). At 1 year after autologous fat transfer, the patient showed an improvement in the volume deficit at the left temporal region (B). All photographs were consented for publish by the patient.

was scheduled for operation after the disease was stabilized by medications as mentioned above to prevent the secondary damage to the donor site. None of surgical treatment and injectables was applied to the patient prior autologous fat grafting.

For the lipoatrophy at the left temporal area, the volume of fat grafting overcorrected the lesion volume for 20 to 30% excess to achieve the favorable outcome after fat resorption. The patient underwent autologous 8 mL fat transfer injection at the left temporal area. The fat grafting was harvested from a subcutaneous layer of the lower abdominal area using the tumescent technique and no donor site morbidity was reported.

At 2 months follow-up, the patient reported an improvement in the previously treated lesion at temporal area with a minimal volume loss of grafted fat. Furthermore, the tender nodule and intermittent ulcers were also resolved.

After 1 year of antimalarial and topical corticosteroids, the erythematous plaque at the left cheek and left temporal area was completely resolved. However, a depressed contour of left temporal area was still noted, and the patient asked for the second fat grafting procedure. The patient underwent the second session at a 16-month interval due to fat resorption from the hydroxychloroquine. She received 3.7 mL of autologous fat injection, which was harvested from subcutaneous fat of the lower abdomen with the tumescent technique. Neither an adverse event from the procedure nor reactivation of the disease was reported and the patient was satisfied with the volume restoration of the atrophic

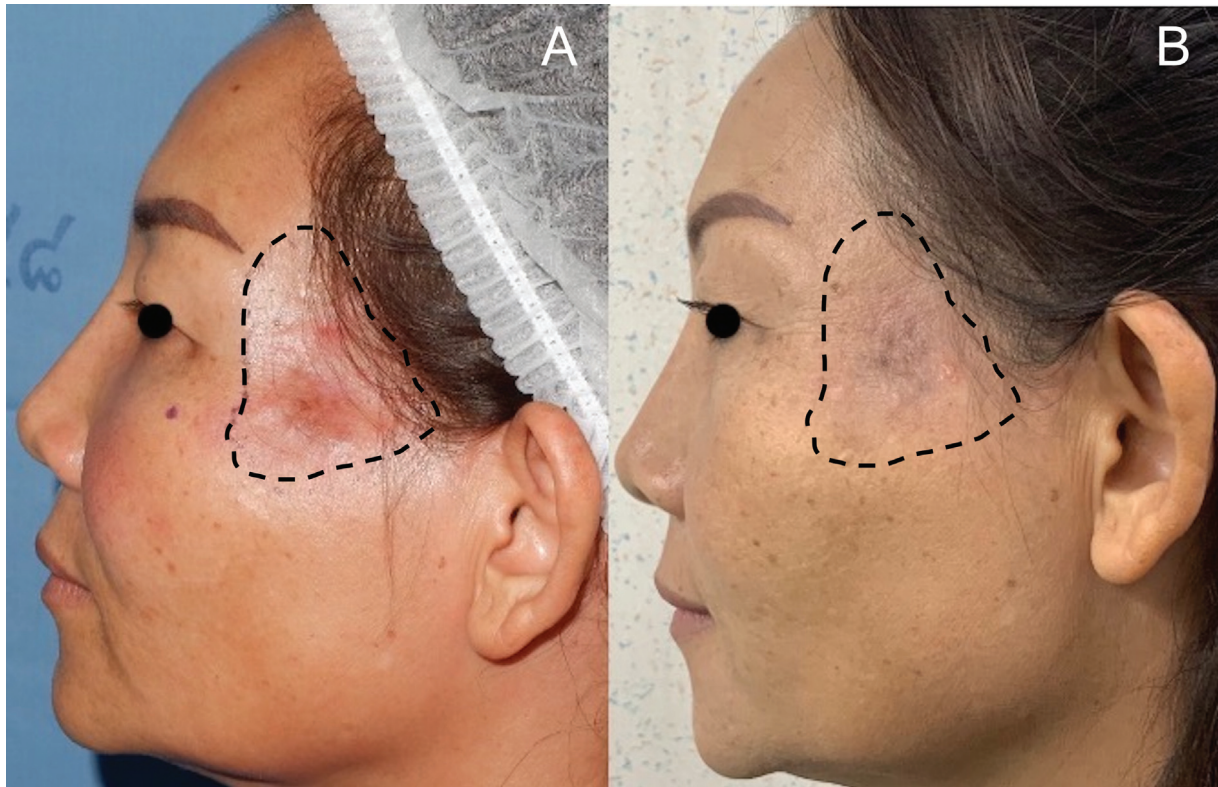


Fig. 2 The ill-defined erythematous plaque with local subcutaneous atrophy at the left temporal region before treatment (A). Improvements in the left temporal volume depletion and erythematous plaque together with the indurated plaque at the left cheek after 1 year of the first autologous fat transfer and medical treatment (B). All photographs were consented for publish by the patient.

lesion and remission of the tender nodule and intermittent ulcers at the temporal area (→ **Figs. 1B** and **2B**).

Discussion

Unlike other forms of CLE, LP commonly disturbs the patient not only from the inflammation during the active phase of disease but also from the scarring and lipoatrophy after inflammation subsides. Secondary lipoatrophy from LP can affect the appearance and contour of the patient's skin, which can lead to a disturbance of the patient's self-esteem and quality of life.

The current mainstay for CLE treatment is medical treatment. However, injectable treatment has been avoided as it carries a theoretical risk of disease reactivation by tissue trauma.⁴ The study of volume restoration in LP associated-lipoatrophy by dermal fillers provided satisfied results but there were risks of disease exacerbation and a granulomatous reaction from the antigenicity of the injectables.⁵

The treatment of LP with injectables should be avoided in active inflammatory phase since the LP can be exacerbated by trauma. Adequate medical treatment to control the disease activation before fat grafting is important.^{4,5} So, the autologous fat grafting should be done in the stable and non-inflammatory phase of disease.

In this report, the patient received autologous fat transfer for volume restoration of a lipoatrophic lesion. The results were promising and the patient was satisfied with the outcome. The patient reported that the reactivation of

the disease, which involved the spontaneous presence of tender nodules and intermittent ulcers, was gradually resolved after the first autologous fat transfer treatment. The patient was satisfied with the improvement in her disfigurement and the endurance of the fat grafting for over a year. Hence, autologous fat grafting should be considered as a safe and simple procedure with a positive long-lasting effect. However, a staged procedure might be required to achieve the target volume since the volume depletion of injected fat.

The functions of ADSCs has been proposed in several literatures such as promotion of angiogenesis, alteration the apoptosis process, and modulation of immune responses.⁸⁻¹⁰ Apart from the direct volume correction by fat grafting injection, we observed the disease stabilization of the intermittent ulcer at LP lesion after fat grafting injection. The quiescence of LP lesion might have resulted from immunomodulatory effects of the ADSCs, which suppress the inflammatory process of LP.

In summary, the treatment of secondary lipoatrophy from LP with autologous fat grafting shows promising long-lasting results in volume restoration and can alleviate spontaneous reactivation of the LP lesion without adverse events. This treatment should be done in the stable and quiescent phase of the disease.

Author Contributions

Conceptualization: W.T. and N.K. Data curation: W.T., N.K., and J.P. Visualization: W.T. and N.K. Writing-original

draft: W.T, N.K., and J.P. Writing-review & editing: W.T. and N.K. All authors read and approved the final manuscript.

Ethical Approval

The study was performed in accordance with the principles of the Declaration of Helsinki.

Patient Consent

Written informed consent for patient information and images to be published was obtained from the patient reported in the manuscript.

Conflict of Interest

None declared.

References

- 1 Al-Refu K, Goodfield M. Scar classification in cutaneous lupus erythematosus: morphological description. *Br J Dermatol* 2009; 161(05):1052–1058
- 2 Vasquez R, Wang D, Tran QP, et al. A multicentre, cross-sectional study on quality of life in patients with cutaneous lupus erythematosus. *Br J Dermatol* 2013;168(01):145–153
- 3 Fanouriakis A, Kostopoulou M, Alunno A, et al. 2019 update of the EULAR recommendations for the management of systemic lupus erythematosus. *Ann Rheum Dis* 2019;78(06):736–745
- 4 Creadore A, Watchmaker J, Maymone MBC, Pappas L, Vashi NA, Lam C. Cosmetic treatment in patients with autoimmune connective tissue diseases: best practices for patients with lupus erythematosus. *J Am Acad Dermatol* 2020;83(02):343–363
- 5 Eastham AB, Liang CA, Femia AN, Lee TC, Vleugels RA, Merola JF. Lupus erythematosus panniculitis-induced facial atrophy: effective treatment with poly-L-lactic acid and hyaluronic acid dermal fillers. *J Am Acad Dermatol* 2013;69(05):e260–e262
- 6 Gleeson CM, Lucas S, Langrish CJ, Barlow RJ. Acute fatal fat tissue embolism after autologous fat transfer in a patient with lupus profundus. *Dermatol Surg* 2011;37(01):111–115
- 7 Valdatta L, Cherubino M, Tamborini F, Pellegatta I, Maggiulli F. A case of facial lipoatrophy secondary to lupus profundus managed with lipofilling technique. *Case Rep Dermatol Med* 2012; 2012:720518
- 8 Coleman SR. Structural fat grafting: more than a permanent filler. *Plast Reconstr Surg* 2006;118(3, Suppl):108S–120S
- 9 Agay D, Scherthan H, Forcheron F, et al. Multipotent mesenchymal stem cell grafting to treat cutaneous radiation syndrome: development of a new minipig model. *Exp Hematol* 2010;38(10):945–956
- 10 Charles-de-Sá L, Gontijo-de-Amorim NF, Maeda Takiya C, et al. Antiaging treatment of the facial skin by fat graft and adipose-derived stem cells. *Plast Reconstr Surg* 2015;135(04):999–1009