



Zero-Profile Anchored Spacer (ROI-C) in the Treatment of Cervical Adjacent Segment Disease

Prasert Iampreechakul¹ Punpoom Choochaimangkhal¹ Wuttipong Tirakotai¹
Sunisa Hangsapruerk² Pimchanok Puthkhao³ Adisak Tanpun⁴

¹ Department of Neurosurgery, Prasat Neurological Institute, Bangkok, Thailand

² Department of Neuroradiology, Prasat Neurological Institute, Bangkok, Thailand

³ Department of Medical Services, Prasat Neurological Institute, Bangkok, Thailand

⁴ Division of Neurosurgery, Department of Surgery, Phichit Hospital, Phichit, Thailand

Address for correspondence Prasert Iampreechakul, MD, Department of Neurological Surgery, Prasat Neurological Institute, 312 Ratchawithi Road, Khwaeng Thung Phaya Thai, Bangkok, 10400, Thailand (e-mail: bangruad@hotmail.com).

AJNS 2022;17:209–217.

Abstract

Background Self-locking stand-alone cages have increasingly been used in anterior cervical discectomy and fusion (ACDF) cervical degenerative disc disease. We studied clinical and radiological outcomes of patients who underwent zero-profile anchored spacer (ROI-C)-assisted ACDF without anterior plate fixation in cervical adjacent segment disease.

Materials and Methods Fifteen patients suffering from cervical adjacent segment disease with various symptoms, such as radiculopathy, myelopathy, or both, were retrospectively evaluated. The cervical adjacent segment disease was confirmed by plain radiographs and magnetic resonance imaging. The patients underwent radiological evaluation to assess cervical curvature, intervertebral height, fusion, and subsidence. Clinical assessment was graded using a visual analog scale, Modified Japanese Orthopedic Association score, and the Neck Disability Index.

Results There were 19 levels of operation. Single-level ACDF was performed in 11 patients and two level in 4 patients. In the postoperative period, our study revealed significant improvement in the clinical outcome. The cervical curvature and intervertebral height were significantly improved at 12-months follow-up ($p < 0.05$). The fusion rate was 100%, whereas subsidence occurred in 5.3% but produced no symptoms. Of the 19 operated segment, 2 (5.3%) from 38 VerteBRIDGE plates had breakage. There was only one case of mild dysphagia, which resolved in less than 2 weeks.

Conclusion This study indicates that zero-profile anchored spacer (ROI-C) in the treatment of cervical adjacent segment disease provides improvement of clinical outcomes, restoration of lordosis, high fusion rate, and low incidence of dysphagia. However, subsidence and breakage of VerteBRIDGE plate occurred in 5.3% cases, but did not cause clinical symptoms.

Keywords

- ▶ cervical PEEK cage
- ▶ cervical interbody cage
- ▶ zero-profile anchored spacer
- ▶ ROI-C
- ▶ adjacent segment disease
- ▶ self-locking stand-alone cage

DOI <https://doi.org/10.1055/s-0042-1750837>.
ISSN 2248-9614.

© 2022. Asian Congress of Neurological Surgeons. All rights reserved.

This is an open access article published by Thieme under the terms of the Creative Commons Attribution-NonDerivative-NonCommercial-License, permitting copying and reproduction so long as the original work is given appropriate credit. Contents may not be used for commercial purposes, or adapted, remixed, transformed or built upon. (<https://creativecommons.org/licenses/by-nc-nd/4.0/>)

Thieme Medical and Scientific Publishers Pvt. Ltd., A-12, 2nd Floor, Sector 2, Noida-201301 UP, India

Introduction

Anterior cervical discectomy and fusion (ACDF) in degenerative disc disease has widely been accepted nowadays after modifications of surgical techniques originated by Smith and Robinson¹ and by Cloward.² Autologous bone graft use provides high percentage of fusion rate over allografts.³ However, autologous bone grafts obtained from the anterior iliac crest are associated with significant donor site morbidity and complications including severe acute pain, hematoma formation, infection, neuralgia paresthetica, and chronic pain.⁴

Cervical interbody cages have been developed and applied in clinical practice to eliminate complications at the donor site. There are two basic types of cages: threaded hollow cylindrical cages (Cloward type procedure) and rectangular cages (Smith–Robinson type procedure). The threaded cages are introduced and screwed through the endplates of the vertebral bodies, whereas the rectangular cages mimic the intervertebral space dimensions and in accordance with the anatomy of the endplates. The cages are made of titanium, carbon fiber, or polyetheretherketone (PEEK).^{5,6} Currently, PEEK cages have widely been used because the elastic modulus of the PEEK cage is similar to that of human cortical bone that may help to decrease stress shielding and increase bony fusion.⁷

Anterior plate system was added in ACDF using with autologous iliac crest graft or cages, especially in multilevel surgery, to increase fusion rates and reduce the problem of graft extrusion and collapse.⁸ Nonetheless, some studies reported complications such as plate migration, screw loosening, or back-out, soft tissue injury and dysphagia.^{9,10} Bioabsorbable anterior cervical plating then has been introduced to reduce some of the long-term complications and imaging artifacts associated with titanium instrumentation.¹¹ However, it is still not routinely used because of higher costs compared with the titanium plate.

Stand-alone cage concept, initiated by Bagby,¹² used in the human spine since 1988, was started with a stainless-steel basket implant for cervical spine surgery in horses, working with veterinarians. Stand-alone cages have been designed to avoid hardware-related complications as mentioned earlier. However, this concept was warned due to high incidence of subsidence, especially titanium cervical cage.¹³ Stand-alone cervical PEEK cage for single- to two-level degenerative disc disease has been used with accepted incidence of subsidence.¹⁴ Subsequently, zero-profile cage-plate device with locking screws has been developed and used clinically to reduce incidence of subsidence and dysphagia. However, there was some reports about device-related complications such as loosening of screws, and device malposition with a screw threatening the vertebral artery.^{15,16}

The ROI-C implant system (Zimmer Biomet, Austin, Texas, United States) is a new type of stand-alone anchored spacer designed for implant as an intervertebral spacer through the anterior cervical approach. This system is composed of an anatomical PEEK cage and two VerteBRIDGE self-locking plates.^{17,18}

The purpose of the present study was to assess clinical and radiological outcomes of the ROI-C device for cervical adjacent segment disease.

Materials and Methods

Subjects

The patients harboring cervical adjacent segment disease treated with zero-profile anchored spacer (ROI-C) were retrospectively reviewed. This study was approved by the ethical committee of our institute. All patients were operated on by a single neurosurgeon (P.I.). Indications for surgical treatment were radiculopathy, myelopathy, and radiculomyelopathy. Before surgery, all patients obtained magnetic resonance imaging and plain radiographs including anteroposterior (AP), lateral, lateral flexion, and extension views.

Surgical Technique

Surgical procedure was performed using standard Smith–Robinson approach. A transverse incision was performed onto right- or left-sided opposite to previous incision. Discectomy and decompression were performed under an operating microscope in all cases. The posterior longitudinal ligament was only explored in cases suspected free disc fragments according to preoperative imaging. Only the cartilaginous portion of the vertebral endplates was carefully removed with preservation of the bony layer of endplates. Under fluoroscopic guidance, the cage trial was used for sizing the cage. The chosen cage was filled with demineralized bone matrix (InterGro, Zimmer Biomet, Austin, Texas, United States) or Triosite bone graft (Zimmer Biomet, Austin, Texas, United States). Triosite bone graft substitute is a bioactive calcium phosphate ceramic composed of hydroxyapatite and tricalcium phosphate. After insertion of the cage, two VerteBRIDGE plates were inserted into cranial and caudal vertebral bodies along caudal and cranial slots through the implant holder, respectively. Following removal of the implant holder, fluoroscopy was used to confirm the appropriate position of the cage in AP and lateral views (►Fig. 1). The proper position of cage was confirmed by tantalum alloy radiologic position marker. Operative time and intraoperative blood loss were recorded.

Postoperatively, dexamethasone was administered as an intravenous preparation at a dose of 4 mg, every 6 hours for 1 day. Soft cervical collar was used in each patient for 1 to 2 weeks. Plain radiographs including AP, lateral, lateral flexion, and extension views were performed before discharge, at 6, and 12 months.

Radiological Measurements

The cervical curvature was assessed by modified method from the study of Profeta et al.¹⁹ A straight line (Line A) was drawn from the inner border of the odontoid tip to the inferoposterior border of C7. Another line (Line B) was drawn from the inner border of the odontoid tip to the inner border of middle part of the C4 body. The angle was measured in degree between the Line A and Line B on the pre- and postoperative images (►Fig. 2A). The intervertebral height

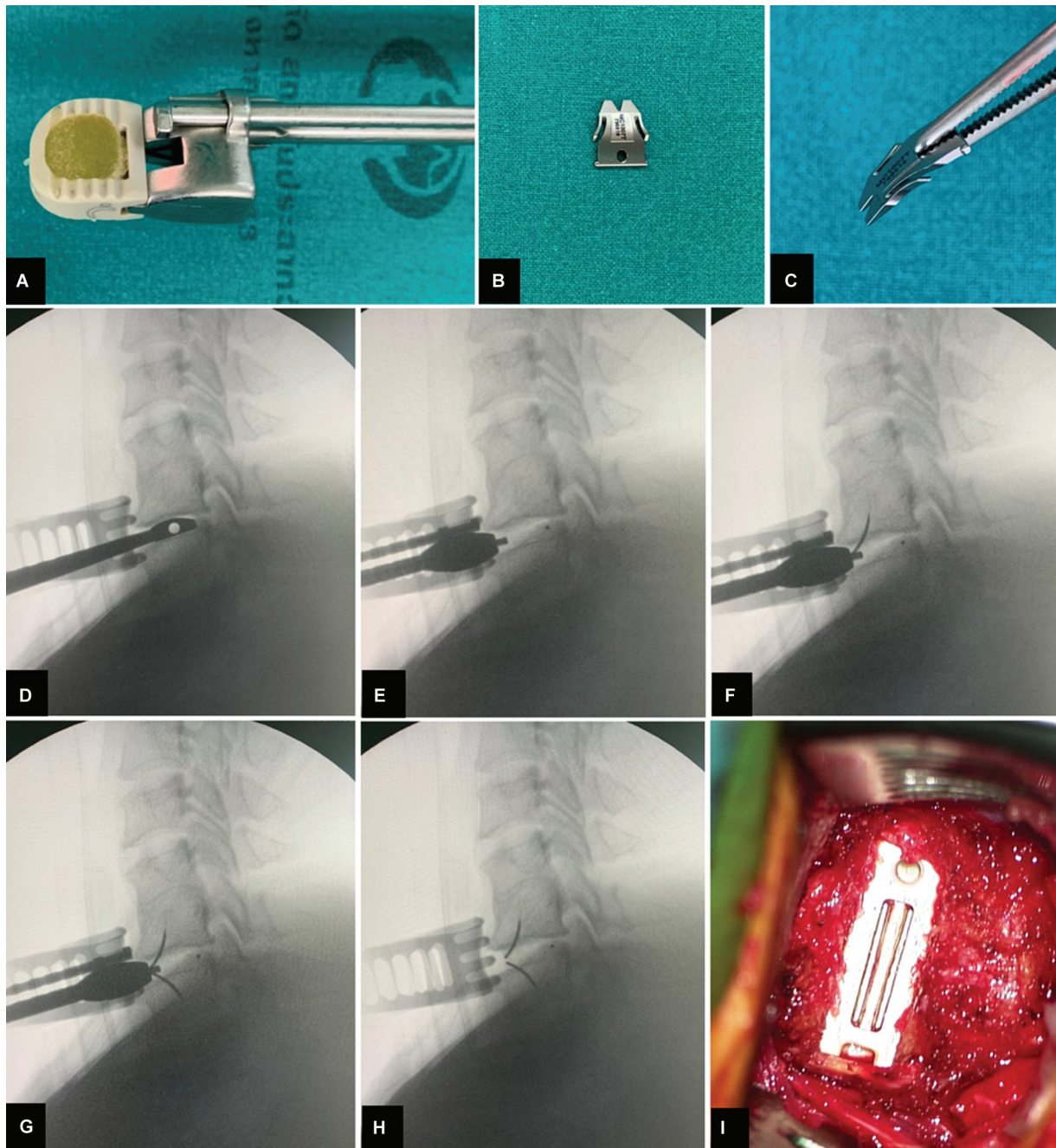


Fig. 1 Surgical technique of the ROI-C cervical cage with VerteBRIDGE plating technology. (A) Cervical cage filled with demineralized bone matrix (DBM). (B, C) VerteBRIDGE anchor plate. During insertion of (D) cage trial, (E) cervical cage (F) upper VerteBRIDGE, (G) lower VerteBRIDGE, and (H) removal of the implant holder under fluoroscopic guidance. (I) Intraoperative photograph shows complete insertion of two VerteBRIDGE plates into both cranial and caudal slots of cage.

(IH) was measured by drawing the line from the middle portion of inferior border of the upper level of correspondent cervical spine to the middle portion of the superior border of the lower level (Line C). The length of the inferior border of the C2 was used as the reference line (Line D). We calculated the proportion of the Line C/Line D (IH ratio). If the calculated proportion at the postoperative period was higher than the preoperative, then the calculated value inferred the increase of the segmental height at the postoperative period (► **Fig. 2B**). Fusion was defined according to the following

criteria: (1) the absence of motion on flexion–extension radiographs and the absence of any dark halo around a cage on both AP and lateral radiograph; (2) presence of bridging trabecular bone anterior or posterior to the cage. Cage subsidence was defined as migration of cage into the superior and/or inferior vertebral body of more than 2 mm. All images were evaluated independently by the experienced neuroradiologist (S.H) using Picture Archiving and Communication System (FUJIFILM, Stamford, Connecticut, United States).

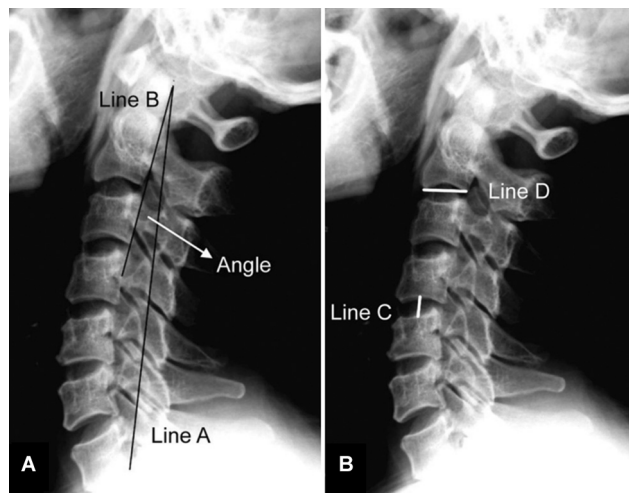


Fig. 2 (A) Scheme for the evaluation of the lordosis. A straight line is drawn from the posterior border of the C2 to the posterior-inferior border of C7 (Line A) and another line from the posterior border of C2 to the posterior border of C4. The angle between these two lines was measured. (B) Scheme for the evaluation of the intervertebral height. Line C is the line that drawn from the middle portion of inferior border of the upper level to the superior border of the lower level. Line D is the length

Clinical Evaluation

Clinical outcome was assessed before and after surgery using a 10-point visual analog scale (VAS) with endpoint anchors of “no pain” and “severe pain,” Modified Japanese Orthopedic Association (JOA) scoring system for cervical myelopathy,²⁰ and the Neck Disability Index (NDI).²¹ Independent observer reviewed hospital charts of all patients. Clinical scores were collected preoperatively, on the day before discharge, at 1, 3, 6, and 12 months. All probable complications including dysphagia, postoperative infection, hematoma, and other device-related complications were also reviewed.

Statistical Analysis

Statistical analysis was performed using Statistical Package for the Social Sciences (SPSS) for Windows, version 16.0 (SPSS Inc., Chicago, Illinois, United States). Age of patients, operative time, estimated blood loss, IH ratio, degree of cervical curvature, VAS, modified JOA, and NDI score were presented as median with interquartile range (p25–p75). Other variables were presented as frequencies and percentages. Comparison between preoperative and postoperative clinical and radiographic data were analyzed using Wilcoxon signed-ranks test. A probability value (*p*-value) less than 0.05 was considered statistically significant.

Results

Between January 2017 and June 2019, 15 patients, including 3 men (20%) and 12 women (80%) with median age 57 years, range 51 to 67 years, were diagnosed with cervical adjacent segment disease and treated by ACDF with the ROI-C systems. Patient demographics, symptoms, and operative characteristics are shown in ▶Table 1. Seven patients presented with radiculopathy, two with myelopathy, and six with

Table 1 Summary of preoperative and operative data

Preoperative characteristics	
Patients, <i>n</i>	15
Age (y), median (IQR)	57 (53–70)
Gender, <i>n</i> (%)	
Male	3 (20%)
Female	12 (80%)
Symptoms, <i>n</i> (%)	
Radiculopathy	7 (46.7%)
Myelopathy	2 (13.3%)
Radiculopathy and myelopathy	6 (40.0%)
Operative characteristics	
Type of previous surgery, <i>n</i> (%)	
Smith–Robinson procedure (iliac bone)	1 (6.7%)
Cloward procedure	5 (33.3%)
Cage-plate construct	8 (53.3%)
Stand-alone PEEK cage	1 (6.7%)
Number of operative levels	
One level, <i>n</i> (%)	11 (73.3%)
Two levels, <i>n</i> (%)	4 (26.7%)
Operated level	
C3–4, <i>n</i> (%)	4 (21.1%)
C4–5, <i>n</i> (%)	6 (31.5%)
C5–6, <i>n</i> (%)	1 (5.3%)
C6–7, <i>n</i> (%)	8 (42.1%)
Adjacent segment	
Supra-adjacent segment, <i>n</i> (%)	10 (52.6%)
Infra-adjacent segment, <i>n</i> (%)	9 (47.4%)
Operative time (minutes), median (IQR)	107 (89–105)
Estimated blood loss (mL), median (IQR)	10 (5–20)

Abbreviations: IQR, interquartile range; PEEK, polyetheretherketone.

radiculomyelopathy. Types of previous operation were Smith–Robinson procedure with iliac bone graft in one patient (▶Fig. 3), Cloward procedure in five (▶Fig. 4), cage-plate construct in eight (▶Fig. 5), and stand-alone PEEK cage in one patient. Single-level ACDF was performed in 11 patients, two-level (skip level) in 4 patients (▶Fig. 6), resulting in the treatment of 19 levels. The C3 to 4 segment was performed in four (21.1%) patients, C4 to 5 in six (31.5%), C5 to 6 in one (5.3%), and C6 to 7 in eight (42.1%) patients. All patients were followed up for at least 12 months after surgery. ACDF of supra-adjacent segment was performed in 10 levels, and infra-adjacent segment in 9 levels. Median operative time was 107 minutes (interquartile range [p25–p75]: 89–105 minutes) and median estimated blood loss was 10 (5–20) mL.

Comparison between preoperative and postoperative clinical and radiological outcomes was shown in ▶Table 2. The median pre- and postoperative VAS pain scores were

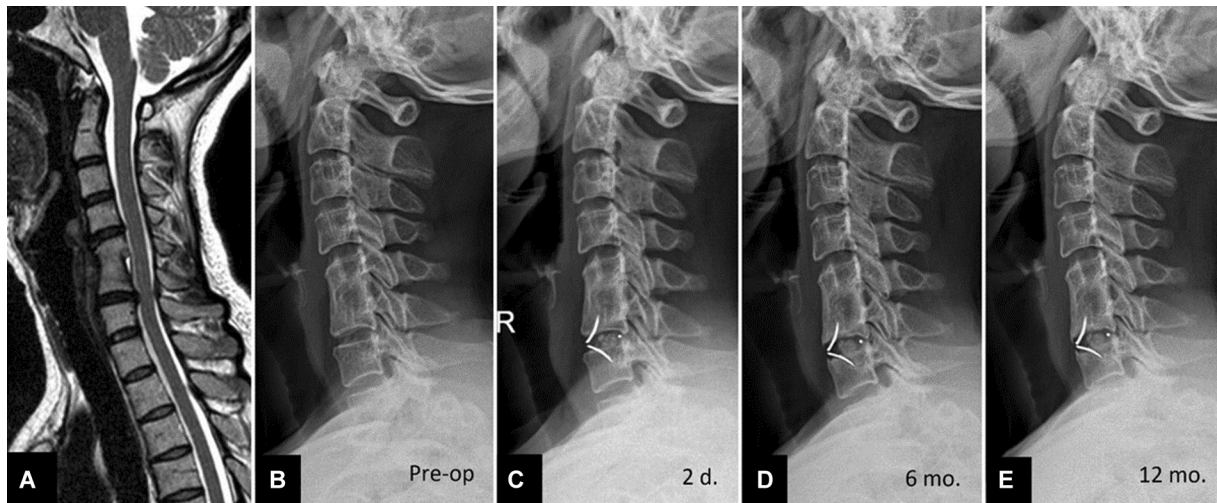


Fig. 3 Adjacent segment disease at C6 to 7 following Smith–Robinson procedure C5 to 6. (A) Sagittal T2-weighted magnetic resonance imaging of the cervical spine shows C6 to 7 disc herniation with compressing of the spinal cord. Sequential lateral radiographs of the cervical spine at (B) before surgery, (C) 2 days, (D) 6 months, and (E) 1 year after surgery reveal improvement in intervertebral disc height. The bony trabecular pattern of C6 to 7 level is noted.

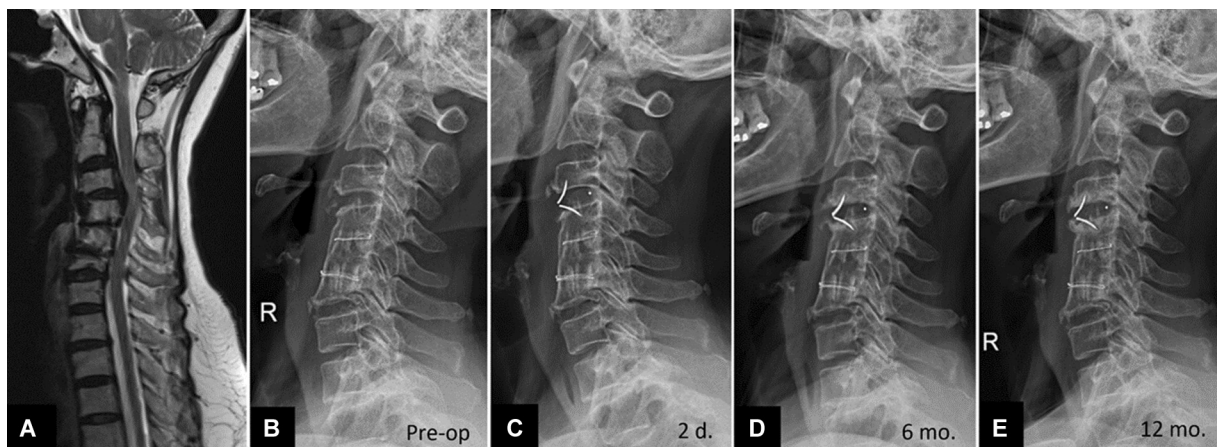


Fig. 4 Adjacent segment disease at C3 to 4 following Cloward's operation C4 to 6. (A) Sagittal T2-weighted magnetic resonance imaging of the cervical spine shows kyphotic change and C3 to 4 disc herniation compressing the spinal cord. Sequential lateral radiographs of the cervical spine at (B) before surgery, (C) 2 days, (D) 6 months, and (E) 1 year after surgery reveal improvement in lordotic curve. The bony trabecular pattern of C3 to 4 level is noted.

8.00 and 1.00, respectively. There was a significant relief of cervical pain after surgery ($p < 0.05$). The median preoperative modified JOA score was 12.00 and the mean postoperative scores increased to 16.50. The differences between the pre- and the postoperative JOA scores were statistically significant ($p < 0.05$). The median pre- and postoperative NDI scores were 17.00 and 3.00, respectively, which represented a significant improvement of the postoperative quality of life ($p < 0.05$).

Of the 15 patients, the median pre- and postoperative cervical lordosis was 4.00 and 5.00 degree, respectively. The difference was statistically significant ($p < 0.05$). In 19 operated levels, the median pre- and postoperative IH was 0.34 and 0.41, respectively. The difference of pre- and postoperative IH was statistically significant ($p < 0.05$).

Successful fusion was achieved in 15 patients (100%). Of 19 operated levels, subsidence occurred in 1 level (5.3%) and

breakage of VerteBRIDGE plate occurred in 2 (5.3%) from 38 plates but produced no symptom (► Figs. 6D, 7). There was only one case of mild dysphagia, which resolved in less than 2 weeks. One patient had dysphagia from the loosening of screw from previous surgery and resolved from symptoms after removal of this screw (► Fig. 5A). No esophageal injury occurred in our study.

Discussion

Self-locking stand-alone cages have been increasingly used in ACDF to avoid complications associated with anterior cervical plates.²² The ROI-C cage is a cervical interbody cage composed of radiolucent PEEK optima using the VerteBRIDGE double anchoring system for initial and long-term stability. It was designed for having zero profile without hardware protruding outside the vertebral bodies.²³

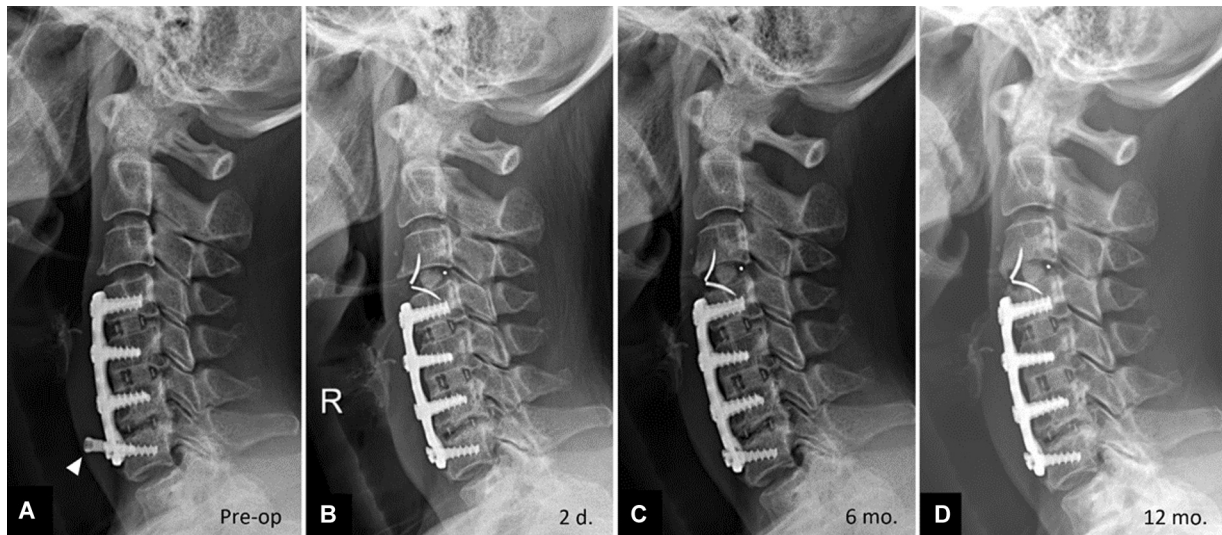


Fig. 5 Adjacent segment disease at C3 to 4 following anterior plate construction C5 to 7. Sequential lateral radiographs of the cervical spine at (A) before surgery, (B) 2 days, (C) 6 months, and (D) 1 year after surgery show improvement in intervertebral height. The bony trabecular pattern at C3 to 4 level is noted at 1 year after surgery. The screw dislodgement (arrowhead) at C7 vertebral body was noticed and was removed during the operation.

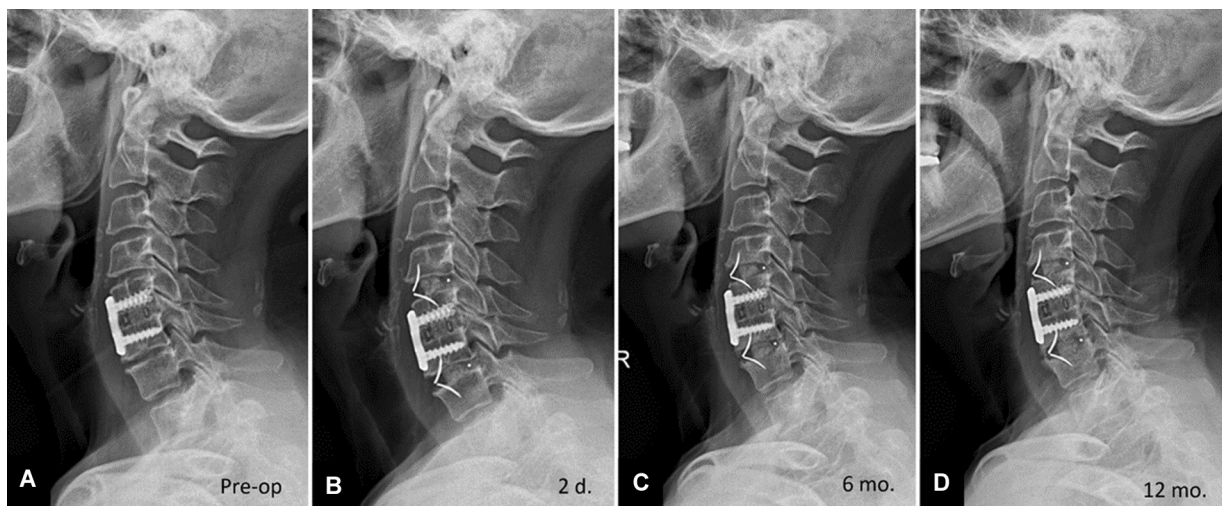


Fig. 6 Adjacent segment disease at C4 to 5 and C6 to 7 following anterior cage-plate construction C5 to 6. Sequential lateral radiographs of the cervical spine at (A) before surgery, (B) 2 days, (C) 6 months, and (D) 1 year after surgery show improvement of intervertebral heights and good lordosis. The bony trabecular pattern of both levels is noted. There is subsidence at C6 to 7 level.

Adjacent segment degeneration is defined as radiological changes at levels adjacent to a previous cervical fusion. However, adjacent segment disease refers to development of new symptoms correlating with adjacent segment degeneration.²⁴ Following the anterior cervical fusion, the predicted prevalence of symptomatic adjacent changes is 13.6% at 5 years and 25.6% at 10 years of follow-up.²⁵

The exact pathophysiologic mechanism of adjacent segment degeneration remains unclear. The use of plate and screws is likely to accelerate degenerative changes in adjacent segments.²⁶ Based on kinematics stimulation study in comparison between ACDF with zero-profile spacer and cage-plate construct by Li et al,²⁷ they found that cage-plate construct may have an impact on the biomechanics of the adjacent level after a single-level ACDF, probably explaining

the decreasing incidence of adjacent segment degeneration in patients using zero-profile spacer. Zhou et al²⁸ compared a self-locking stand-alone cage (ROI-C system) and anterior plate for ACDF in long-term follow-up and found that adjacent segment degeneration in cage group was significantly less than those in the plate group.

In case of previous ACDF with plate and screws and adjacent segment disease, the insertion of the ROI-C system is no need to remove or expose an existing adjacent plate.¹⁷ In the present study, two VerteBRIDGE plates could be inserted into the vertebral bodies with no need to remove an existing plate and screws in all patients underwent previous ACDF with cage-plate construct.

Several studies^{7,17,18,23,28-30} including our study demonstrated that the ROI-C interbody cage with VerteBRIDGE

Table 2 Summary of clinical and radiological data

	Pre-op	Post-op	p-Value ^a
VAS score, median (IQR)	8.00 (7.00–9.00)	1.00 (1.00–2.00)	0.001
Modified JOA score, median (IQR)	12.00 (10.75–13.00)	16.50 (16.00–17.00)	0.027
NDI score, median (IQR)	17.00 (16.00–23.00)	3.00 (2.00–5.00)	0.001
IH ratio, median (IQR)	0.34 (0.29–0.39)	0.41 (0.36–0.46)	< 0.001
Curvature (degree), median (IQR)	4.00 (2.00–7.00)	5.00 (2.00–8.00)	0.026

Abbreviations: IH, intervertebral height; IQR, interquartile range; JOA, Japanese Orthopedic Association; NDI, Neck Disability Index; PEEK, polyetheretherketone; VAS, visual analog scale.

^aWilcoxon signed ranks test.

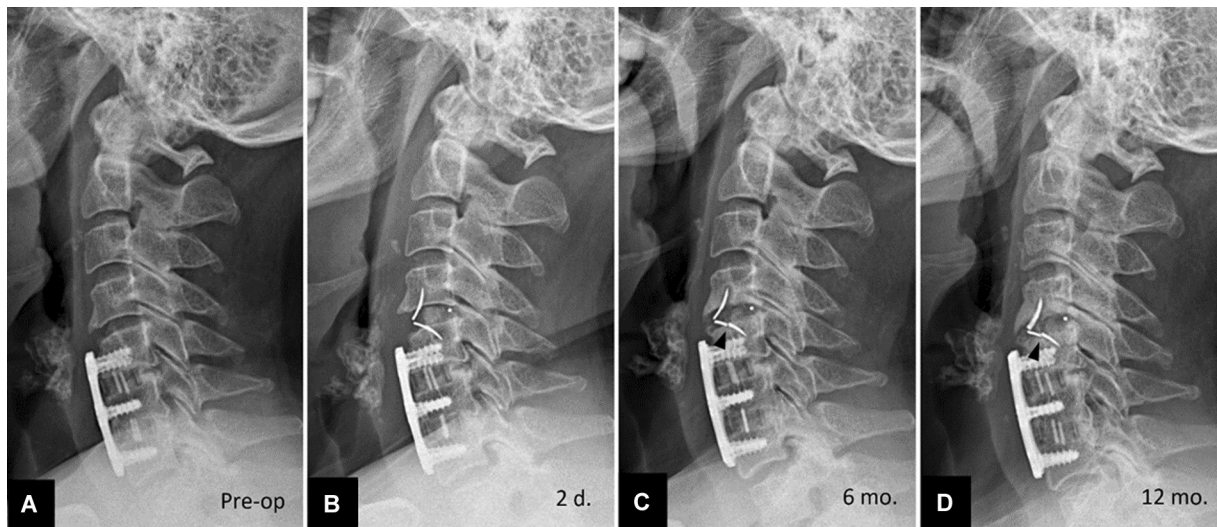


Fig. 7 Adjacent segment disease at C4 to 5 following anterior cage-plate construction C5 to 7. Sequential lateral radiographs of the cervical spine (A) before surgery, (B) at 2 days, (C) 6 months, and (D) 1 year after surgery. The breakage of the lower VertebroBRIDGE (arrowheads) is noted.

anchoring plates achieved a high rate of fusion. The top and bottom of the implant have teeth that fit into the bone, making the cage more stable.²⁸ The self-locking VertebroBRIDGE plates ensure excellent primary stability of implant and promote early fusion.⁷ Using the ROI-C implant, solid fusion was achieved at mean time of 4.5 to 6.9 months.^{28,30} In the current study, all patients achieved complete interbody fusion within 1 year follow-up.

Dysphagia is more common in patients treated with ACDF due to an interface with esophagus.¹⁴ From the comparison study between the ROI-C group and the anterior plate group in treatment one- or two-level cervical spondylosis at 3 months postoperatively by Wang et al,⁷ they revealed a significantly lower risk of dysphagia in the ROI-C group than that in the anterior plate group (0 vs. 27.3%). Similarly, Liu et al³¹ compared the ROI-C group and anterior plate group for multilevel cervical spondylotic myelopathy and showed a higher incidence of dysphagia of 21.9% in contrast with that of 3.6% with ROI-C device at final follow-up. Dysphagia after ACDF with cage-plate construct may occur due to longer static retraction time, excessive dissection of soft tissue, installation of prevertebral titanium plate, and inevitably stimulating the anterior structure after surgery.¹⁸ The ROI-C

system can be totally implanted into the intervertebral space so that it avoids implant contact with the soft tissue in front of the cervical spine and any mechanical irritation of the esophagus, probably explaining the low incidence of dysphagia.^{23,31} Compared with ACDF using a plate construction, the implant of ROI-C requires less dissection and less trauma to the surrounding soft tissue. The use of the curved anchoring plates instead of screws allows for smaller exposure.¹⁷ Therefore, the ROI-C device was found to be superior to the anterior plate group in terms of operative time and blood loss.^{7,28,31} Hofstetter et al²⁹ revealed significantly more swelling of the prevertebral space after implantation of an anterior locking plate compared with the ROI-C. Furthermore, the patients with postoperative dysphagia in the ROI-C group recovered more quickly than those in the plate group.²⁸ In our study, we avoided adhesion or scar from previous surgery by approach through the opposite site to previous incision. Fortunately, there was no esophageal complications in our series.

Subsidence seems to be a problem of concern with the use of stand-alone assisted interbody fusion cage.¹⁴ The use of the stand-alone titanium cage had a high rate of subsidence.¹³ The PEEK cage is more elastic than titanium,

reducing the possibility of subsidence of the cage into the vertebral body.⁸ Fujibayashi et al³² speculated that significant subsidence occurred only with the wedge-type cage in comparison with anatomical-type cage. It is probably important for the cage to have a contact surface that approaches the anatomical curvature of the involved endplates as much as possible. In addition, they found that an over-sized cage had a high rate of subsidence. The ROI-C device system, an anatomical PEEK cage and two VerteBRIDGE self-locking plates, is designed for the elimination of the basic disadvantage of stand-alone cage.¹⁷ Multiple studies,^{17,18,22,23,28,30,33} including our study, showed low subsidence rate. Most patients with cage subsidence did not experience any symptoms and they achieved fusion in the final follow-up. Importantly, preservation of bony endplates and avoiding over-sized cage are imperative factors to avoid subsidence in our surgical technique. However, postoperative cage subsidence should be aware in patients with multilevel ACDF using self-locking stand-alone cage.^{34,35}

According to the study of 90 patients who underwent ACDF with the ROI-C device by Lonjon et al,²² they reported anchoring plate fracture in 5 (2%) from 249 plates with no clinical consequence. The mechanism of anchoring plate fracture remains unknown. In our study, there was the breakage of anchoring plate in 5.3%. Similarly, this device-related complication produced no symptoms and did not require surgery.

The ROI-C implant was associated with a significant benefit in treating noncontinuous level of cervical degenerative disc disease.³¹ Lu et al¹⁸ compared the clinical and radiological results of the ROI-C device and cage-plate construct for the treatment of noncontiguous bilevel or skip-level of cervical degenerative disc disease and found that the ROI-C group had a shorter operative time and significant lower incidence of dysphagia. Similar to skip-level cervical degenerative disc disease, supra- and infra-adjacent segments in the same patient were treated with ACDF using the ROI-C implants in four patients in the present study.

According to a meta-analysis study of comparison between zero-profile devices and cage-plate construct in ACDF with a minimum 2 years of follow-up by Sun et al,³⁶ they found that the zero-profile implant and cage-plate construct achieved comparable mid-term and long-term clinical and radiological outcomes, including the fusion rate, in ACDF. Additionally, the zero-profile group has obvious advantages in reducing intraoperative blood loss, improving the cervical lordosis angle, and reducing the incidence of postoperative dysphagia and adjacent segment degeneration.

Limitations

Our study has some limitations including the observational study without control group, small sample size, and relatively short follow-up. More patients and longer follow-up are acquired to further investigate the efficacy of the ROI-C system for the treatment of cervical adjacent disease. Due to concerning about radiation exposure, reliable computed tomography scan was not performed for the assessment of

solid fusion in our study. However, the PEEK cage is radiolucent and easy to observe trabecular bone formation and evaluation of fusion status on radiographs.

Conclusion

The ROI-C implant system, a zero-profile interbody fusion cage with self-locking designed for stand-alone fusion without external plates and screws, is safe and effective for the treatment of cervical adjacent disease in patients with cervical radiculopathy and/or myelopathy. Significant improvement in clinical scores and low incidences of postoperative dysphagia and subsidence were obtained by this prosthesis. In addition, the ROI-C cage provides high rate of fusion, and restoration of the cervical lordosis and IH.

Funding

None.

Conflict of Interest

None declared.

References

- Smith GW, Robinson RA. The treatment of certain cervical-spine disorders by anterior removal of the intervertebral disc and interbody fusion. *J Bone Joint Surg Am* 1958;40-A(03):607-624
- Cloward RB. The anterior approach for removal of ruptured cervical disks. *J Neurosurg* 1958;15(06):602-617
- Bishop RC, Moore KA, Hadley MN. Anterior cervical interbody fusion using autogeneic and allogeneic bone graft substrate: a prospective comparative analysis. *J Neurosurg* 1996;85(02):206-210
- Sawin PD, Traynelis VC, Menezes AH. A comparative analysis of fusion rates and donor-site morbidity for autogeneic rib and iliac crest bone grafts in posterior cervical fusions. *J Neurosurg* 1998;88(02):255-265
- Matgé G. Cervical cage fusion with 5 different implants: 250 cases. *Acta Neurochir (Wien)* 2002;144(06):539-549, discussion 550
- Pavlov PW. Anterior decompression for cervical spondylotic myelopathy. *Eur Spine J* 2003;12(Suppl 2):S188-S194
- Wang Z, Jiang W, Li X, et al. The application of zero-profile anchored spacer in anterior cervical discectomy and fusion. *Eur Spine J* 2015;24(01):148-154
- Cho DY, Liao WR, Lee WY, Liu JT, Chiu CL, Sheu PC. Preliminary experience using a polyetheretherketone (PEEK) cage in the treatment of cervical disc disease. *Neurosurgery* 2002;51(06):1343-1349, discussion 1349-1350
- Cho DY, Lee WY, Sheu PC. Treatment of multilevel cervical fusion with cages. *Surg Neurol* 2004;62(05):378-385, discussion 385-386
- Riley LH III, Skolasky RL, Albert TJ, Vaccaro AR, Heller JG. Dysphagia after anterior cervical decompression and fusion: prevalence and risk factors from a longitudinal cohort study. *Spine* 2005;30(22):2564-2569
- Aryan HE, Lu DC, Acosta FL Jr, Hartl R, McCormick PW, Ames CP. Bioabsorbable anterior cervical plating: initial multicenter clinical and radiographic experience. *Spine* 2007;32(10):1084-1088
- Bagby GW. Arthrodesis by the distraction-compression method using a stainless steel implant. *Orthopedics* 1988;11(06):931-934
- Gercek E, Arlet V, Delisle J, Marchesi D. Subsidence of stand-alone cervical cages in anterior interbody fusion: warning. *Eur Spine J* 2003;12(05):513-516

- 14 Iampreechakul P, Srisawat C, Tirakotai W. Stand-alone cervical polyetheretherketone (PEEK) cage (cervios) for single to two-level degenerative disc disease. *J Med Assoc Thai* 2011;94(02):185–192
- 15 Barbagallo GM, Romano D, Certo F, Milone P, Albanese V. Zero-P: a new zero-profile cage-plate device for single and multilevel ACDF. A single institution series with four years maximum follow-up and review of the literature on zero-profile devices. *Eur Spine J* 2013;22(Suppl 6):S868–S878
- 16 Son DK, Son DW, Kim HS, Sung SK, Lee SW, Song GS. Comparative study of clinical and radiological outcomes of a zero-profile device concerning reduced postoperative dysphagia after single level anterior cervical discectomy and fusion. *J Korean Neurosurg Soc* 2014;56(02):103–107
- 17 Bucci MN, Oh D, Cowan RS, et al. The ROI-C zero-profile anchored spacer for anterior cervical discectomy and fusion: biomechanical profile and clinical outcomes. *Med Devices (Auckl)* 2017;10:61–69
- 18 Lu Y, Bao W, Wang Z, et al. Comparison of the clinical effects of zero-profile anchored spacer (ROI-C) and conventional cage-plate construct for the treatment of noncontiguous bilevel of cervical degenerative disc disease (CDDD): A minimum 2-year follow-up. *Medicine (Baltimore)* 2018;97(05):e9808
- 19 Profeta G, de Falco R, Ianniciello G, Profeta L, Cigliano A, Raja AI. Preliminary experience with anterior cervical microdiscectomy and interbody titanium cage fusion (Novus CT-Ti) in patients with cervical disc disease. *Surg Neurol* 2000;53(05):417–426
- 20 Japanese Orthopaedic Association. Scoring system for cervical myelopathy. *J Jpn Orthop Assoc* 1994;68:490–503
- 21 Vernon H, Mior S. The Neck Disability Index: a study of reliability and validity. *J Manipulative Physiol Ther* 1991;14(07):409–415
- 22 Lonjon N, Favreul E, Huppert J, Lioret E, Delhayé M, Mraidí R. Clinical and radiological outcomes of a cervical cage with integrated fixation. *Medicine (Baltimore)* 2019;98(03):e14097
- 23 Grasso G, Giambartino F, Tomasello G, Iacopino G. Anterior cervical discectomy and fusion with ROI-C peek cage: cervical alignment and patient outcomes. *Eur Spine J* 2014;23(Suppl 6):650–657
- 24 Hilibrand AS, Robbins M. Adjacent segment degeneration and adjacent segment disease: the consequences of spinal fusion? *Spine J* 2004;4(6, Suppl):190S–194S
- 25 Hilibrand AS, Carlson GD, Palumbo MA, Jones PK, Bohlman HH. Radiculopathy and myelopathy at segments adjacent to the site of a previous anterior cervical arthrodesis. *J Bone Joint Surg Am* 1999;81(04):519–528
- 26 Park JB, Cho YS, Riew KD. Development of adjacent-level ossification in patients with an anterior cervical plate. *J Bone Joint Surg Am* 2005;87(03):558–563
- 27 Li XF, Jin LY, Liang CG, Yin HL, Song XX. Adjacent-level biomechanics after single-level anterior cervical interbody fusion with anchored zero-profile spacer versus cage-plate construct: a finite element study. *BMC Surg* 2020;20(01):66
- 28 Zhou J, Li J, Lin H, Li X, Zhou X, Dong J. A comparison of a self-locking stand-alone cage and anterior cervical plate for ACDF: minimum 3-year assessment of radiographic and clinical outcomes. *Clin Neurol Neurosurg* 2018;170:73–78
- 29 Hofstetter CP, Kesavabhotla K, Boockvar JA. Zero-profile anchored spacer reduces rate of dysphagia compared with ACDF with anterior plating. *J Spinal Disord Tech* 2015;28(05):E284–E290
- 30 Luo J, Huang S, Gong M, Li L, Yu T, Zou X. Two-level anterior cervical discectomy and fusion using self-locking stand-alone polyetheretherketone cages with two anchoring clips placed in the upper and lower vertebrae, respectively. *Eur J Orthop Surg Traumatol* 2015;25(Suppl 1):S147–S153
- 31 Liu Y, Wang H, Li X, et al. Comparison of a zero-profile anchored spacer (ROI-C) and the polyetheretherketone (PEEK) cages with an anterior plate in anterior cervical discectomy and fusion for multilevel cervical spondylotic myelopathy. *Eur Spine J* 2016;25(06):1881–1890
- 32 Fujibayashi S, Neo M, Nakamura T. Stand-alone interbody cage versus anterior cervical plate for treatment of cervical disc herniation: sequential changes in cage subsidence. *J Clin Neurosci* 2008;15(09):1017–1022
- 33 Zhang J, Liu H, Bou EH, et al. Comparative study between anterior cervical discectomy and fusion with ROI-C cage and laminoplasty for multilevel cervical spondylotic myelopathy without spinal stenosis. *World Neurosurg* 2019;121:e917–e924
- 34 Chen Y, Lü G, Wang B, Li L, Kuang L. A comparison of anterior cervical discectomy and fusion (ACDF) using self-locking stand-alone polyetheretherketone (PEEK) cage with ACDF using cage and plate in the treatment of three-level cervical degenerative spondylopathy: a retrospective study with 2-year follow-up. *Eur Spine J* 2016;25(07):2255–2262
- 35 Zhou J, Li X, Dong J, et al. Three-level anterior cervical discectomy and fusion with self-locking stand-alone polyetheretherketone cages. *J Clin Neurosci* 2011;18(11):1505–1509
- 36 Sun Z, Liu Z, Hu W, Yang Y, Xiao X, Wang X. Zero-profile versus cage and plate in anterior cervical discectomy and fusion with a minimum 2 years of follow-up: a meta-analysis. *World Neurosurg* 2018;120:e551–e561