




Clinical Characteristics and Outcome of Patients with Multiple Intracranial Aneurysms from a University Hospital in Nepal

Mohan Raj Sharma¹  Prakash Kafle² Binod Rajbhandari¹ Amit Bahadur Pradhanang¹
Shrestha Dipendra Kumar¹ Gopal Sedain¹

¹Department of Neurosurgery, Institute of Medicine, Tribhuvan University Teaching Hospital, Kathmandu, Nepal

²Department of Neurosurgery, Nobel Medical College Teaching Hospital, Biratnagar, Nepal

Address for correspondence Mohan Raj Sharma, MD, Institute of Medicine, Tribhuvan University Teaching Hospital, Kathmandu 44600, Nepal (e-mail: mohanrajsharma@iom.edu.np).

AJNS 2022;17:268–273.

Abstract

Objective The risk factors, management strategies, and outcomes of patients with multiple intracranial aneurysms (MIAs) are different compared with that of patients with a single aneurysm. Data are scarce regarding patients with MIAs from developing countries. The objective of this study was to describe the clinical characteristics, management strategies, and outcomes of patients treated microsurgically from Nepal.

Methods The clinical records of patients confirmed to have MIAs and microsurgically clipped between July 2014 and December 2019 were retrospectively reviewed. Data on demographic and clinical characteristics, computed tomography findings, multiplicity and location of aneurysms, management strategies, and the 1-year outcome were abstracted and analyzed.

Results Two hundred cerebral aneurysms were microsurgically clipped in 170 consecutive patients during the study period. Twenty-six (13.0%) patients harbored 60 aneurysms. The mean age of the patients was 58.5 (43–73) years. Smoking and hypertension were found in 20 (76.9%) and 16 (61.5%) patients, respectively. The majority of patients [17 (65.4%)] were in good grades at presentation. Twenty-one patients had two aneurysms, four had three aneurysms, and one patient had five aneurysms. The middle cerebral artery was the commonest (20) followed by distal anterior cerebral artery (14) and anterior communicating artery (13) involved in multiplicity. A single-stage surgery was performed on 17 patients. Serial clipping was performed in six patients. In three patients, a single aneurysm on the contralateral side was left untreated for various reasons. The favorable outcome was achieved in 23 (88.5%) patients whereas three (11.5%) patients had an unfavorable outcome. One patient died.

Conclusion The demographic and clinical characteristics of patients in our series are comparable with those described in the published literature from other countries. With an individualized treatment strategy, an acceptable outcome can be achieved in the majority of the patients.

Keywords

- ▶ microsurgical clipping
- ▶ multiple intracranial aneurysms
- ▶ Nepal
- ▶ subarachnoid hemorrhage

DOI <https://doi.org/10.1055/s-0042-1750822>.
ISSN 2248-9614.

© 2022. Asian Congress of Neurological Surgeons. All rights reserved.

This is an open access article published by Thieme under the terms of the Creative Commons Attribution-NonDerivative-NonCommercial-License, permitting copying and reproduction so long as the original work is given appropriate credit. Contents may not be used for commercial purposes, or adapted, remixed, transformed or built upon. (<https://creativecommons.org/licenses/by-nc-nd/4.0/>)

Thieme Medical and Scientific Publishers Pvt. Ltd., A-12, 2nd Floor, Sector 2, Noida-201301 UP, India

Introduction

Depending on the completeness of the angiography, multiple intracranial aneurysms (MIAs) are detected in 15 to 34% of patients with subarachnoid hemorrhage (SAH).¹⁻⁶ Risk factors for multiplicity are the same for patients with a single aneurysm but are more apparent such as the increasing age, female sex, cigarette smoking, and the family history of cerebral aneurysms. Additional risk factors for multiplicity are high body mass index and connective tissue disorders such as Marfan's syndrome and systemic lupus erythematosus.^{3,7,8} Identifying and deciding on the best treatment regarding MIAs can be difficult when the treatment is complex and hazardous, and when there is more than one reasonable option.

Though endovascular treatment is gaining momentum, open surgery is still the mainstay of treatment especially in low- and middle-income countries where the cost of coiling is prohibitive for many. In addition, some complex and recurrent previously coiled aneurysms are also better suited for microsurgery.

In general, the patients with MIAs have a less favorable outcome than those with single-aneurysm due to complex management strategies during and after surgery.^{3,8} Added to this complexity is the risk of misdiagnosis of the ruptured aneurysm in MIAs.

Multiple aneurysms can be managed in single or multiple stages. The advantages of a single-stage surgery are (1) elimination of the need for a second surgery, (2) absolute certainty that the ruptured aneurysm has been obliterated, and (3) the opportunity to treat vasospasm aggressively. If planned to obliterate the aneurysms in two stages, it is crucial to identify the aneurysm causing SAH which will obviously be the target of the first surgery. Angiographic features of the ruptured aneurysm in the setting of multiplicity include: a focal collection of SAH, irregular contour, presence of "nipple," larger size, and serial change in the aneurysm shape and size.⁹

A decision on how to treat these aneurysms is based on many factors. These could be patient-related (comorbidities, life expectancy, etc.), aneurysm-related (morphometric characteristics and proximity of the multiple aneurysms), and the experience of the treating surgeon.

Though many studies are reported on MIAs from developed countries, very few studies have been published from south Asia and no such study has been published from Nepal.^{10,11} In this paper, the authors describe the clinical characteristics, management strategies, and outcomes of patients with MIAs operated in a university hospital from Nepal. We followed the Preferred Reporting Of Case Series in Surgery (PROCESS) guideline in conducting this case series.¹²

Methods

Permission from the Institutional Review Committee of our institute was obtained prior to the commencement of the data abstraction process of this study. We retrospectively reviewed our prospectively collected vascular database of

consecutive patients with aneurysmal SAH managed by microsurgical clipping by a single surgeon (M.R.S.) in our center from July 2014 to December 2019. At least 1 year of follow-up was taken as the end point of the study.

Clinical grading of each patient with confirmed SAH either by a positive computed tomography (CT) scan or a positive lumbar puncture was performed using Hunt and Hess scale at the time of admission.¹³ All patients subsequently underwent either a four-vessel cerebral digital subtraction angiography (DSA) or a CT angiography to confirm the presence of aneurysm(s). Patients were routinely admitted to the neurosurgical intensive care unit and managed as per the American Heart Association AHA guidelines 2012.¹⁴ In our institution during the study period, we did not have the capability of providing endovascular treatment to patients with cerebral aneurysm. Hence all patients were offered microsurgical clipping. Some patients who underwent serial surgery were offered the option of undergoing endovascular treatment in other centers or in India. But due to the increased cost, they chose open surgery for the remaining aneurysm also. Patients who were in good grades underwent microsurgical clipping in the early period (< 3 days) whereas for those with significant comorbidities or in poor grade, delayed surgery (> 8 days after the ictus) was performed. None of the patients in our series had features of connective tissue disorders such as Marfan's syndrome. So, work-up in that direction (testing for the presence of autoantibodies) was not performed.

Admission CT, CT angiography, DSA, and follow-up CT angiography or DSA were reviewed. We describe the following variables in this patient population: age, sex, history of hypertension and smoking, Hunt and Hess scale at admission, location and number of aneurysms, and the management strategy. The in-hospital rebleeding rate and the Glasgow outcome scale¹⁵ in 1 year were analyzed.

Results

During the 5.5 year period, 200 cerebral aneurysms were microsurgically clipped in 170 consecutive patients. Twenty-six (13.0%) patients harbored multiple aneurysms which were 60 in number. The CT scan was diagnostic of SAH in 23 patients whereas in two patients SAH was suspected due to classic history of severe explosive headache and the presence of crenated red blood cells in the cerebrospinal fluid from the lumbar tap. One patient presented with third nerve palsy. Twenty patients underwent CT angiography as the initial modality of diagnosis and six patients underwent DSA. In six patients additional DSA was obtained after initial CT angiography to further define the aneurysmal characteristics.

Demographic Characteristics

► **Table 1** shows the baseline characteristics of patients in this series. The age of the patients ranged from 43 to 73 years with a mean of 58 years. In patients with a single aneurysm ($n=174$), the mean was 54 years. There was a strong sex predilection (M: F 1.3:4). Smoking and hypertension were found in 20 (76.9%) and 16 (61.5%) patients, respectively.

Table 1 Baseline characteristics of the patients with MIAs ($n = 26$)

Characteristics	Parameters
Age (Years)	58 (43–73)
Sex M:F	1.3:4
Smoking	20 (76.9%)
Hypertension	16 (61.5%)

Abbreviation: MIAs, multiple intracranial aneurysms.

Table 2 Hunt and Hess grade of patients with MIAs ($n = 26$)

Hunt and Hess Grade	Number of patients
I	6
II	11
III	5
IV	4
V	0

Abbreviation: MIAs, multiple intracranial aneurysms.

Clinical Features

Admission Hunt and Hess grade of this patient population is shown in ►Table 2. Most patients [17 (65.4%) in I and II] were in good grades at presentation.

Imaging Characteristics

All patients with MIAs in our series had CT scans within 24 hours of ictus. All had aneurysms in the anterior circulation.

Twenty-one patients had two aneurysms, four had three aneurysms, and one patient had five aneurysms (►Fig. 1). The location of different aneurysms is shown in ►Table 3.

Based on this data, the middle cerebral artery (MCA) was the commonest (20) followed by distal anterior cerebral artery (DACA) (14) and anterior communicating artery (ACoM) (13) involved in multiplicity.

Management Strategy

Ten patients (38.5%) underwent surgery within 3 days of ictus whereas, in 16 patients (61.5%), the surgery was performed after 8 days. One patient rebled in the hospital while awaiting surgery but she had a good outcome (GOS 5) despite the second bleed. A single-stage microsurgical clipping of all aneurysms was performed in 17 patients. In one patient who had two aneurysms with an arteriovenous malformation (AVM), all aneurysms were clipped, and the AVM was excised in one stage (►Fig. 2). Serial clipping was performed in six patients (three patients with two bilateral ophthalmic aneurysms and three patients with bilateral MCA aneurysms). In three patients, a single aneurysm on the contralateral side was left untreated for various reasons. One patient had ipsilateral saccular and contralateral fusiform supraclinoid aneurysms. The ipsilateral aneurysm was clipped, and the contralateral fusiform aneurysm was deliberately left untreated. In two patients, the unruptured contralateral aneurysm was left untreated as patients refused a second surgery. One of them was the lady with five aneurysms and the other patient was with bilateral MCA aneurysms. Therefore, a total of 57 aneurysms were clipped in 26 patients.

In our institute we routinely obtain a cerebral CTA in all patients 6 weeks after the initial surgery and if it shows complete obliteration, no further routine angiography is

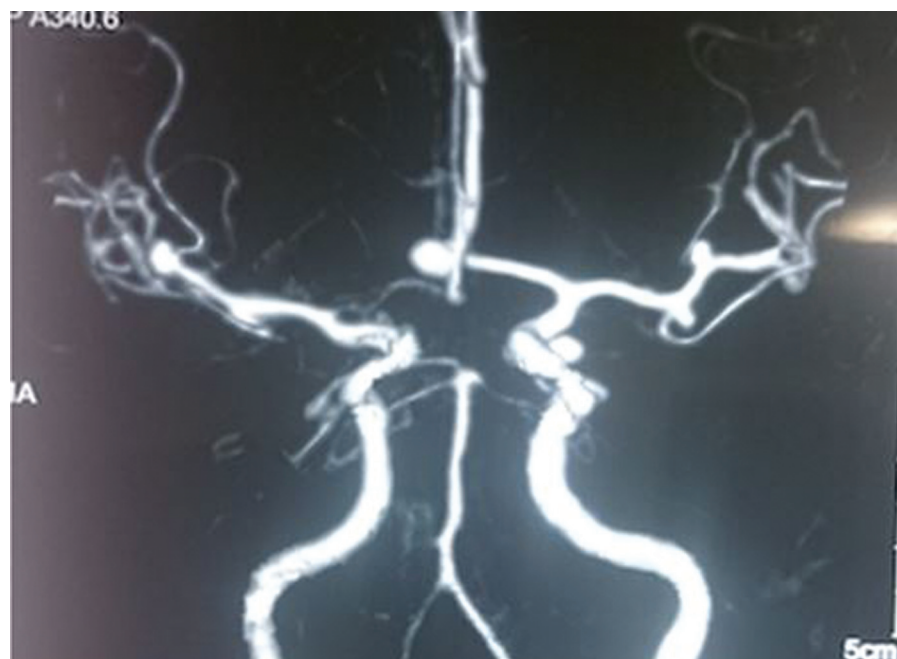
**Fig. 1** Computed tomography angiography of a 55-year old lady with recent SAH harboring five aneurysms. SAH, subarachnoid hemorrhage.

Table 3 Distribution of MIAs in the various location in the circle of Willis

Distribution of aneurysms	Number of patients
Patients with five aneurysms	
(Left PCoM, Left M ₂ , Left M ₃ , ACoM, and right M ₂)	1
Patients with three aneurysms	4
a. One ACoM and 2 DACAs	3
b. Right MCA, PCoM, and DACA one each	1
Patients with two aneurysms	21
a. ACoM and MCA	6
b. Bilateral MCA	5
c. DACA and DACA	3
d. Bilateral ophthalmic ICA	3
e. ACoM and PCoM	2
f. Bilateral supraclinoid (one side fusiform)	1
g. One ACoM and One DACA associated with AVM	1

Abbreviations: ACoM, anterior communicating artery; AVM, arteriovenous malformation; DACA, distal anterior communicating artery; M₂, M₂ segment of middle cerebral artery; M₃, M₃ segment of middle cerebral artery; MCA, middle cerebral artery; MIAs, multiple intracranial aneurysms; PCoM, posterior communicating artery.

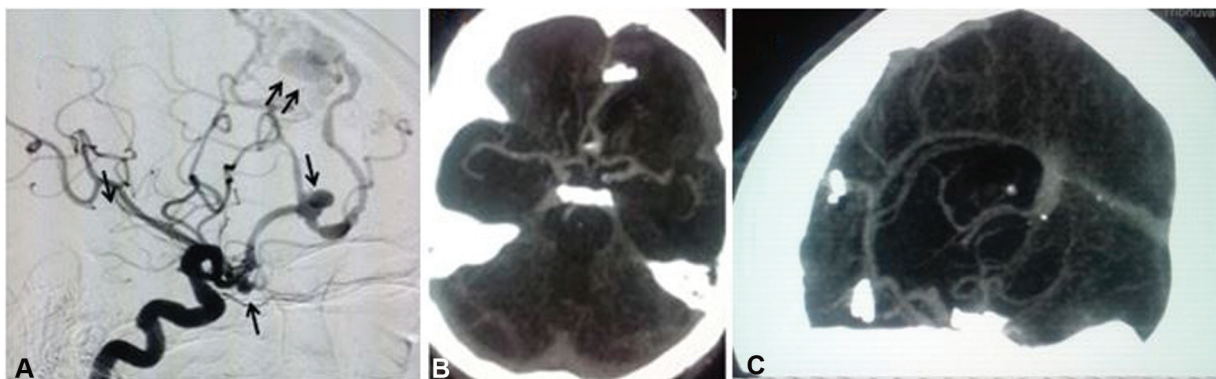


Fig. 2 Cerebral angiogram of the patient (A) with ACoM and DACA aneurysms (*single arrow*) and an AVM (*double arrows*). Postoperative CT angiography (B, C) showing complete obliteration of aneurysms and excision of the AVM. ACoM, anterior communicating artery; AVM, arteriovenous malformation; CT, computed tomography; DACA, distal anterior cerebral artery.

recommended. In patients with MIAs with untreated aneurysms, CTA is recommended yearly in patients with aneurysms less than three mm in size. In this series, all operated patients underwent CTA in six weeks and complete obliteration was achieved in all cases. One patient with the contralateral fusiform aneurysm had yearly CTA for three consecutive years with no change in the size of the aneurysm. Then she was lost to follow-up. Two patients had denied surgery for the remaining aneurysm. So, no further angiographic study was performed on them.

Outcome

The follow-up period ranged from 1 to 5 years. The favorable outcome (GOS IV and V) was achieved in 23 (88.5%) patients whereas three (11.5%) patients had an unfavorable outcome (GOS1, 2, 3). One patient died in our series. The unfavorable

outcome was noted in patients where multiple attempts were made to obliterate the aneurysms and in patients with associated comorbidities and poor GCS at admission. As our series is too small, statistical analysis of risk factors for poor outcome was not possible.

Discussion

In our series, MIAs were found in 13.1% of all patients with aneurysmal SAH, which is consistent with previously published reports ranging from 15 to 35%.¹⁻⁶

Demographic Characteristics and Risk Factors

The demographic characteristics of this study population were very similar to those observed in other series of patients with MIAs.¹⁻⁶ The median age is slightly higher in

MIAs compared with patients with a single aneurysm. As in patients with a single aneurysm, there is a stronger female sex predilection consistent with previously published studies.^{1,2,4-8} Hypertension and cigarette smoking were found in a significant proportion of our patients. In a study by Juvela, only regular cigarette smoking at any time was a significant risk factor for MIAs.⁵ Hypertension has not been found to be as strong a risk factor for MIAs.^{4,5}

Grading

Patients with MIAs generally present in poor Hunt and Hess grades.^{16,17} Our results contradict with previous studies in this regard since most patients presented with good grades. In the paper by Mont'alverne et al, 32% of patients were in grade I, 14% in grade II, and 36% in grade III.¹⁶ Wachter et al in their review of 121 patients with MIAs, found 67% patients in grades I-III and 29.8% in grade IV-V.¹⁷

Imaging

Twenty-three patients had SAH visible on a plain CT scan. Twenty-one patients had two aneurysms, four patients had three aneurysms, and one patient had five aneurysms. In our series, MCA, DACA, and ACoM arterial aneurysms were the commonest locations of MCAs. Nehls et al in their review of 69 patients found the posterior communicating artery (PCoM) (22%), MCA (21.5%), ACoM artery (12%), and ophthalmic artery (11%) to be the frequent locations.⁹

Surgical Management

In our series, a single-stage surgery was performed in 17 patients and staged clipping was performed in six patients. In three patients, a single contralateral aneurysm was left untreated either due to the patients' choice or the surgical unsuitability of the aneurysm. In patients with multiple aneurysms, the annual risk of rupture of an intact aneurysm is approximately 1% per year, and the mortality rate is said to be 4% over a 5-year period.^{18,19} How best to tackle the MIAs microsurgically is still debatable in the literature. Clipping MIAs in a single operation located either on the same side or opposite site demands manipulation of parent vessels and also prolongs the operative period which adds the risk of development of vasospasm. Many authors advocate one-stage surgery when MIAs are found on the same side and can be addressed through the same route.^{20,21} Some have recommended clipping of MIAs via a unilateral or bilateral craniotomy in the same setting.^{17,21,22} However, others suggest doing a delayed treatment of the unruptured aneurysm, if bilateral craniotomies are required for proper exposure.²³

The most important argument for clipping all accessible MIAs in a single setting is the certainty of securing all aneurysms including the ruptured one. The second argument is the opportunity to treat the vasospasm aggressively without worrying about the rupture of the unsecured aneurysm in the postoperative period. Another important factor relevant to a resource-constrained environment is the avoidance of the added cost of two surgeries at two different time points. However, getting the level one evidence will be

challenging due to the obvious ethical reasons of randomizing treatment in two groups in these vulnerable groups of patients.²⁴ Hence, the recommendation heavily relies on the retrospective series from experienced surgeons. The treatment plan as one-stage versus two-stage depends on aneurysm location, comorbidities, and status of other aneurysms(s) other than the ruptured one.

Outcome

The overall outcome of patients with MIAs in 1 year was favorable in our patient population. Twenty-three (88.5%) patients had good outcomes (GOS IV and V). These data are consistent with those published in the reported literature.^{8,10,11,21,25-28}

In a study by Rinne et al, the outcome was significantly unfavorable for patients with MIAs than for those with a single intracranial aneurysm.²⁷ The management mortality in all grades was 24% in patients with MIA. In the same study at 1-year follow-up, 66% of the patients with MIAs were independent. Those patients with aneurysms at the verte-brobasilar arteries had a relatively bad outcome.

In the series of 221 patients by Orz et al, 51.1% patients had excellent outcomes whereas 21.7% were disabled but independent, 14.5% were disabled and dependent and 12.7% died.²⁸

In the study of 41 patients by Sai Kiran et al, a good outcome was achieved in 87.2% of patients at a final follow-up of 6 months or longer.¹⁰ In the study of 63 patients by Sharma et al in India, age greater than 65 years, higher Hunt and Hess grades, PCoM aneurysms, hypertension, infarct, and hydrocephalus were associated with worse outcomes.

The 12.5% negative outcome in our series warrants clarification. One patient who died in our series had significant comorbid medical conditions. Though we cannot deny the fact that the insult of SAH and surgery could well have exacerbated the preexisting conditions, it is hard to justify all deaths due to intracranial insult per se.

Finally, the limitations of our study also deserve mention. This study is retrospective in nature, although data was acquired prospectively, and inherent biases associated with this cannot be ignored. This is also a single institutional study and therefore may not be fully generalizable. As our sample size was small, subgroup analysis and correlation between different factors and outcomes were not possible.

Conclusion

Identifying and deciding on the best treatment can be difficult in this highly complex disease and should be based on a careful balance between the natural history of the disease and the risk of intervention. Treatment of patients with MIAs needs to be individualized regarding a one-stage or a two-stage surgery. The overall outcome of patients with MIAs in 1 year was favorable in our patient population with 88.5% of patients having good outcomes. Clipping of accessible MIAs can be done safely in one stage with an acceptable outcome.

Funding

None.

Conflict of Interest

None declared.

References

- 1 Ostergaard JR, Høg E. Incidence of multiple intracranial aneurysms. Influence of arterial hypertension and gender. *J Neurosurg* 1985;63(01):49–55
- 2 Inagawa T. Multiple intracranial aneurysms in elderly patients. *Acta Neurochir (Wien)* 1990;106(3-4):119–126
- 3 Rinne J, Hernesniemi J, Puranen M, Saari T. Multiple intracranial aneurysms in a defined population: prospective angiographic and clinical study. *Neurosurgery* 1994;35(05):803–808
- 4 Qureshi AI, Suarez JI, Parekh PD, et al. Risk factors for multiple intracranial aneurysms. *Neurosurgery* 1998;43(01):22–26, discussion 26–27
- 5 Juvela S. Risk factors for multiple intracranial aneurysms. *Stroke* 2000;31(02):392–397
- 6 Ellamushi HE, Grieve JP, Jäger HR, Kitchen ND. Risk factors for the formation of multiple intracranial aneurysms. *J Neurosurg* 2001;94(05):728–732
- 7 McDowell MM, Zhao Y, Kellner CP, et al. Demographic and clinical predictors of multiple intracranial aneurysms in patients with subarachnoid hemorrhage. *J Neurosurg* 2018;128(04):961–968
- 8 Kaminogo M, Yonekura M, Shibata S. Incidence and outcome of multiple intracranial aneurysms in a defined population. *Stroke* 2003;34(01):16–21
- 9 Nehls DG, Flom RA, Carter LP, Spetzler RF. Multiple intracranial aneurysms: determining the site of rupture. *J Neurosurg* 1985;63(03):342–348
- 10 Sai Kiran NA, Raj V, Sivaraju L, Vidyasagar K, Mohan D, Hegde AS. Outcome of microsurgical clipping for multiple versus single intracranial aneurysms: a single-institution retrospective comparative cohort study. *World Neurosurg* 2020;143:e590–e603
- 11 Sharma P, Mehrotra A, Das KK, et al. Factors predicting poor outcome in a surgically managed series of multiple intracranial aneurysms. *World Neurosurg* 2016;90:29–37
- 12 Agha RA, Sohrawi C, Mathew G, Franchi T, Kerwan A, O'Neill NPROCESS Group. The PROCESS 2020 Guideline: updating Consensus Preferred Reporting Of Case Series in Surgery (PROCESS) Guidelines. *Int J Surg* 2020;84:231–235
- 13 Hunt WE, Hess RM. Surgical risk as related to time of intervention in the repair of intracranial aneurysms. *J Neurosurg* 1968;28(01):14–20
- 14 Connolly ES Jr, Rabinstein AA, Carhuapoma JR, et al; American Heart Association Stroke Council Council on Cardiovascular Radiology and Intervention Council on Cardiovascular Nursing Council on Cardiovascular Surgery and Anesthesia Council on Clinical Cardiology. Guidelines for the management of aneurysmal subarachnoid hemorrhage: a guideline for healthcare professionals from the American Heart Association/American Stroke Association. *Stroke* 2012;43(06):1711–1737
- 15 Jennett B, Bond M. Assessment of outcome after severe brain damage. *Lancet* 1975;1(7905):480–484
- 16 Mont'alverne F, Tournade A, Riquelme C, Musacchio M. Multiple intracranial aneurysms. Angiographic study and endovascular treatment. *Interv Neuroradiol* 2002;8(02):95–106
- 17 Wachter D, Kreitschmann-Andermahr I, Gilsbach JM, Rohde V. Early surgery of multiple versus single aneurysms after subarachnoid hemorrhage: an increased risk for cerebral vasospasm? *J Neurosurg* 2011;114(04):935–941
- 18 Sonobe M, Yamazaki T, Yonekura M, Kikuchi H. Small unruptured intracranial aneurysm verification study: SUAVe study, Japan. *Stroke* 2010;41(09):1969–1977
- 19 Brisman R. Management of multiple and asymptomatic aneurysms. In: Fein JM, Flamm ES, eds. *Cerebrovascular Surgery*. 3rd vol. New York: Springer; 1985:983–995
- 20 Mizoi K, Suzuki J, Yoshimoto T. Surgical treatment of multiple aneurysms. Review of experience with 372 cases. *Acta Neurochir (Wien)* 1989;96(1-2):8–14
- 21 de Oliveira E, Tedeschi H, Siqueira MG, et al. Anatomical and technical aspects of the contralateral approach for multiple aneurysms. *Acta Neurochir (Wien)* 1996;138(01):1–11, discussion 11
- 22 Edner G. One-session operation via bilateral craniotomies for multiple aneurysms after subarachnoid haemorrhage. *Br J Neurosurg* 1991;5(01):55–60
- 23 Heiskanen O. Risk of bleeding from unruptured aneurysm in cases with multiple intracranial aneurysms. *J Neurosurg* 1981;55(04):524–526
- 24 Vajda J. Multiple intracranial aneurysms: a high risk condition. *Acta Neurochir (Wien)* 1992;118(1-2):59–75
- 25 Cervoni L, Delfini R, Santoro A, Cantore G. Multiple intracranial aneurysms: surgical treatment and outcome. *Acta Neurochir (Wien)* 1993;124(2-4):66–70
- 26 Inagawa T. Surgical treatment of multiple intracranial aneurysms. *Acta Neurochir (Wien)* 1991;108(1-2):22–29
- 27 Rinne J, Hernesniemi J, Niskanen M, Vapalahti M. Management outcome for multiple intracranial aneurysms. *Neurosurgery* 1995;36(01):31–37, discussion 37–38
- 28 Orz Y, Osawa M, Tanaka Y, Kyoshima K, Kobayashi S. Surgical outcome for multiple intracranial aneurysms. *Acta Neurochir (Wien)* 1996;138(04):411–417